



Case report

Early simultaneous bilateral total hip arthroplasty for the management of bilateral acetabular fracture in an elderly patient

Christine Tempelaere, MD^{*}, Pierre Diviné, MD, Thierry Bégué, MD, PhD

Orthopaedic Department, CHU Antoine Béclère, Clamart, France

ARTICLE INFO

Article history:

Received 12 September 2018

Received in revised form

25 March 2019

Accepted 26 March 2019

Available online 3 May 2019

Keywords:

Simultaneous bilateral total hip arthroplasty

Epilepsy

Bilateral acetabulum fracture

ABSTRACT

Bilateral acetabular fractures in elderly patients due to seizures are very rare and management is a challenge. The standard treatment for acetabular fracture, open reduction with internal fixation, is not recommended for the elderly because of poor bone quality and the need for bed rest. In the acute phase, total hip arthroplasty may be the best treatment option because it allows early mobilization and avoids bed rest complications. We report the case of a 76-year-old man with a bilateral comminuted acetabular fractures and a left fracture dislocation of the shoulder, treated by immediate shoulder arthroplasty and a one-stage bilateral total hip arthroplasty procedure at 3 weeks, with a good result at 1-year follow-up. © 2019 Published by Elsevier Inc. on behalf of The American Association of Hip and Knee Surgeons. This is an open access article under the CC BY-NC-ND license (<http://creativecommons.org/licenses/by-nc-nd/4.0/>).

Introduction

During an epileptic episode, severe muscle contractions may lead to shoulder, hip, or vertebrae compression fractures [1]. Fractures as a consequence of convulsive seizures without direct trauma occur in only 0.3% of seizure cases [2] and have a high morbidity and mortality rate [2,3]. Diagnosis of these injuries and particularly acetabular fracture is often delayed due to a lack of clinical suspicion and appropriate investigation [1,4]. Once recognized, recovery options include treatments with limited weight-bearing for 6 weeks or more (closed management, open reduction with internal fixation, percutaneous fixation in situ), and those with immediate weight-bearing (acute or staged total hip arthroplasty [THA]) [5–7]. In patients over 60 years of age, acetabular fracture treatment remains challenging because of precarious general health, severe osteopenia, comminution, and associated femoral head damage [8]. In an elderly patient, a main objective is early mobilization prior to 6 weeks, so early THA is an alternative way to achieve a painless and stable hip [6].

One or more of the authors of this paper have disclosed potential or pertinent conflicts of interest, which may include receipt of payment, either direct or indirect, institutional support, or association with an entity in the biomedical field which may be perceived to have potential conflict of interest with this work. For full disclosure statements refer to <https://doi.org/10.1016/j.artd.2019.03.008>.

^{*} Corresponding author. 157 Rue de la Porte de Trivaux, 92140 Clamart, France. Tel.: +33 145374444.

E-mail address: chris.tempelaere@gmail.com

<https://doi.org/10.1016/j.artd.2019.03.008>

2352-3441/© 2019 Published by Elsevier Inc. on behalf of The American Association of Hip and Knee Surgeons. This is an open access article under the CC BY-NC-ND license (<http://creativecommons.org/licenses/by-nc-nd/4.0/>).

We report here a case of a 76-year-old male with simultaneous bilateral central acetabular fracture dislocation and posterior shoulder fracture dislocation, secondary to a grand mal seizure, to describe a unique surgical treatment with a successful outcome.

Case history

A 76-year-old male patient arrived in our emergency department following a generalized tonic-clonic seizure. He had a history of epilepsy, depression, and benign prostatic hyperplasia. His initial independence was complete with a Parker score of 9 [9]. His American Society of Anesthesiologists score was II. On clinical examination, the patient was hemodynamically stable with a left shoulder deformity and bilateral hip pain. Neurological examination and pulses in both upper and lower limbs were normal. Computed tomography of the brain was performed and found to be normal. Plain radiographs showed a bilateral central dislocation of the acetabulum (Fig. 1) and posterior shoulder dislocation associated with a comminuted Neer 4 fracture of the humeral head [10]. Computed tomography of the pelvis showed bilateral comminuted acetabular fractures: on the right side fractures of the anterior and medial walls and an anterior column fracture with a minimal displacement and on the left side a fracture of both anterior and posterior column with a superior and medial displacement (Figs. 2 and 3).

We opted to treat the shoulder immediately and then treated the acetabular fractures by bilateral THA 3 weeks later. The day after the trauma, left shoulder hemiarthroplasty (Ulys prosthesis;

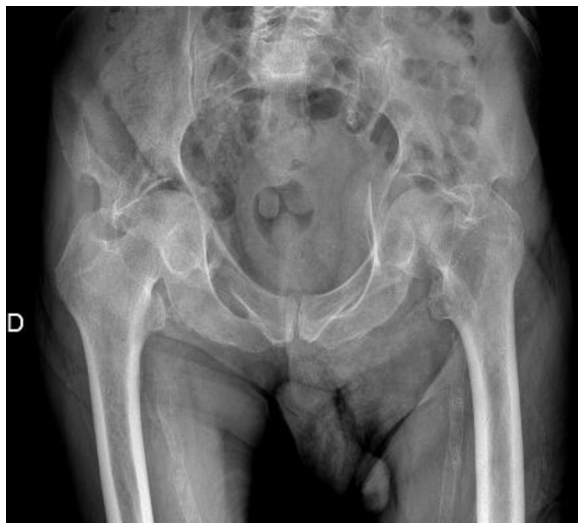

Figure 1. Anteroposterior pelvis radiograph showing bilateral acetabular fractures with subluxations of the femoral heads.

Ceraver, Roissy-en-France, France) was performed for the shoulder fracture dislocation by a deltopectoral approach, without any hemodynamic complications. During the post-operative period, passive shoulder mobilization started.

The bilateral central hip subluxations were treated conservatively initially without traction due to minor pain, but with some minimal physiotherapy of the lower limbs. Pain was controlled by medication and epilepsy treatment was reviewed by a neurologist.

Three weeks after his seizure a single-stage bilateral THA under general anesthesia was performed. We operated first on the right side and next on the left during the same anesthesia. The patient was supine with the 2 lower limbs in the operation area without a fracture table. The 2 surgeries were performed by 2 senior surgeons following the same steps and using the same instruments. A direct anterior approach (Hueter [11]) was used. A femoral neck cut allowed the head to be released easily. After removing the hematoma and fibrous callus from the acetabulum, only 1 reamer was used to remove cartilage and expose cancellous bone (the size was determined by the pre-operative planning). No fracture fixation was required. The bone defect caused by the central protrusion of the femoral head was filled by morselized and impacted graft from the resected bone without the need for a reinforcement ring. Finally, the acetabular implant was cemented on the cancellous graft. A cemented femoral stem was next implanted. The same

procedure and the same implants were used on the left side: cemented cup (DynaCup; Tornier, Montbonnot-Saint-Martin, France); metal head 28 mm; and cemented stem (Meije; Tornier) (Fig. 4). A plain radiograph was performed at the end of the surgery, which confirmed satisfactory implant positioning. No complications during the surgery were reported. Blood loss was estimated at 1300 mL for the 2 hips. The pre-operative hemoglobin level was 12.3 and 10.4 g/dL 1 day after surgery, without any need for transfusion.

The second day after surgery and for 2 weeks following, the patient walked with immediate weight bearing and with only 1 crutch on the right side. The patient lived alone at home and required physiotherapy in a rehabilitation center for 2 months.

Six weeks after surgery, the patient walked without any help and had no hip pain.

At the last follow-up (1 year), the patient was living alone at home, which matched the pre-trauma conditions. The patient was able to walk without crutches, except for long walks (more than 30 minutes) and without limping. He had slight pain but no compromised activity. On clinical examination, bilateral hip mobility was very good with 100° of flexion, full extension, 15° of abduction, 20° of adduction, 10° of external rotation, and 10° of internal rotation. For both hips, the Harris score [12] was 91/100 and the Western Ontario and McMaster Universities Arthritis Index score [12] was 90/100. Radiographs showed no evidence of loosening or osteolysis on either the cup or stem, nor on the shoulder hemiarthroplasty, and grade 1-2 [13] heterotopic calcification over the left greater trochanter (Fig. 5).

The patient consented to data concerning his case being submitted for publication.

Discussion

Various studies describe shoulder, hip joint, or vertebral fracture following an epileptic episode [1]. The force of muscular tonic contractions and bone resilience lead to fractures and dislocations [3,14]. Less than 1% of patients with epilepsy sustain fracture without direct traumatic events [1,2,15,16].

Since 1970, only 29 cases of acetabulum fracture dislocation have been described secondary to seizure from a variety of causes (Table 1). Fractures were bilateral in 16 cases and associated with shoulder fractures in 8 cases. In our study, a 76-year-old man without bone disease history had bilateral acetabular fracture and a left shoulder posterior fracture dislocation due to a seizure.

In elderly patients, most acetabular fractures are pathological due to osteoporotic bone. In the presence of osteoporosis, a simple fall or a seizure may result in a comminuted fracture.

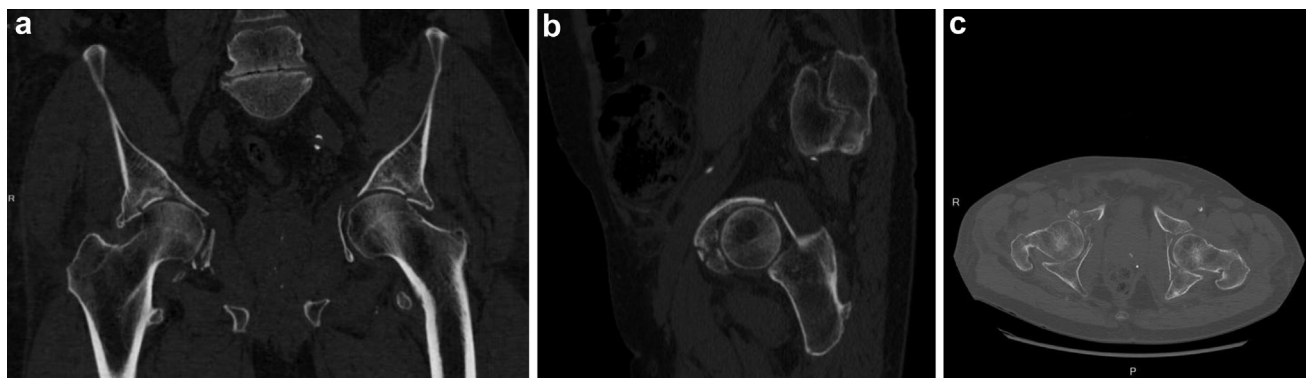

Figure 2. Pelvic computed tomography scan: coronal (a), sagittal (b), and axial (c) reconstructions on the right side of a fracture of the anterior and medial walls and an anterior column fracture with a minimal displacement and on the left side a fracture of both anterior and posterior column with a superior and medial displacement.

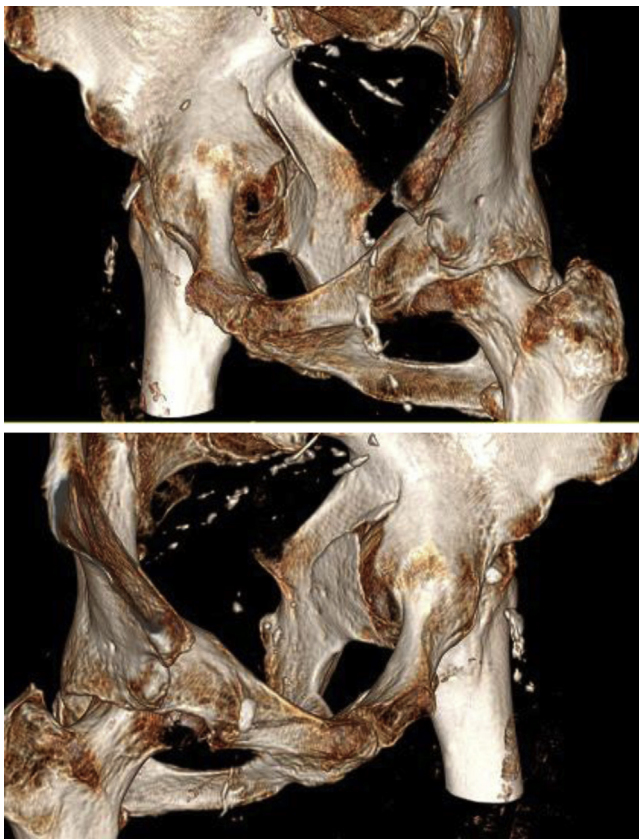


Figure 3. Three-dimensional reformat showing bilateral complex acetabular fracture.

Osteosynthesis in elderly patients may not be the best treatment option due to osteoporotic bone and the complications associated with the period of bed rest required. Overall, such an approach is associated with a poor prognosis and a higher rate of long-term complication [17].

Articular impaction of the medial roof or posterior wall, dislocation of the hip, comminuted posterior wall fractures, injury to the femoral head, and impaction of the acetabulum that involved more than 40% of the joint surface have all been associated with early failure after attempted reduction and internal fixation [8,17,18]. These radiological features have been correlated with a poor clinical outcome. Acute or delayed THA may be the most satisfactory option [17]. Benefits of THA must be balanced, however, against the

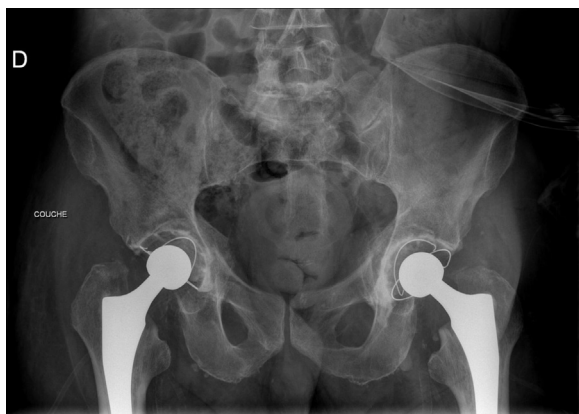

Figure 4. Anteroposterior pelvis post-operative pelvic radiographs demonstrating bilateral total hip arthroplasty.

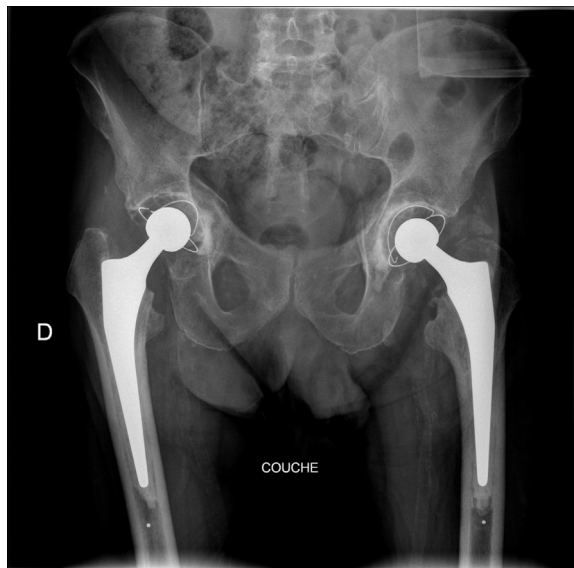


Figure 5. One year anteroposterior pelvis radiograph showing a hetero-topic ossification over the greater trochanter on the left side.

potential for increased mortality and morbidity in the elderly population. Decision to perform THA for an acetabulum fracture must be made collectively, with patient's families being informed of the technical challenges and potential risks. In our case, the patient was older than 65 years and had a bilateral comminuted acetabular fracture with an impaction of the medial roof that involved more than 40% of the joint surface. Based on these criteria we recommended bilateral THA surgery.

When considering a delay between a fracture and THA in the elderly, some authors agree that an acute surgery within 21 days after fracture is best, whereas others conclude that surgery should be delayed so that the fractured bones have time to heal. In elderly patients with severely displaced acetabular fractures with non-anatomical bone alignment or severe pain, early THA is an alternative way to achieve a painless and stable hip [6,7]. Functional treatment is recommended for 2 weeks, using light traction or immediate mobilization, so the fragments can mold themselves around the head [17]. Because our patient had a bilateral fracture with a shoulder fracture, a bilateral traction was considered to be very complicated for nursing care and the patient was therefore relieved with a combination of painkillers. Physiotherapy was started immediately without weight bearing to avoid muscular weakness. Surgery was delayed for 21 days to obtain partial healing and avoid significant blood loss in acute surgery.

THA for acetabular fractures is a surgical challenge and requires an experienced arthroplasty surgeon; successful THA is dependent on the stabilization of the displaced acetabular fragments to allow a solid fixation of the acetabular component [17]. No matter what technique is used, the primary stability of the cup must be good enough to allow immediate weight bearing. In case of a blowout of the anterior column and the medial wall, a cemented cup with or without a reinforcement ring is recommended. Morselized femoral head is used as a bulk bone graft to reinforce the acetabular reconstruction [6]. We used the femoral head for a bone graft in the acetabulum and then implanted a cemented cup with a solid fixation.

A metal-on-polyethylene couple without dual mobility was used in this 76-year-old patient. Some studies recommend using a dual mobility cup in elderly patients due to the increasing risk of dislocation associated with weaker musculature [19]. Prior to the

Table 1
Review of literature on acetabular fractures due to seizures.

Report	Age (y)	Sex	Acetabular fracture	Other fracture	Shock (fatal outcome)	Etiology of the seizure	Bone disease	Treatment
Moore TM, Hill JV, Harvey JP. Central acetabular fracture secondary to epileptic seizure. <i>J Bone Joint Surg Am</i> 1970;52(7):1459	43	Male	Bilateral					Post-operative
Shaw JL. Bilateral posterior fracture-dislocation of the shoulder and other trauma caused by convulsive seizures. <i>J Bone Joint Surg Am</i> 1971;53(7):1437	42	Male	Left	Shoulder vertebrae femur				Water intoxication
Krishnan SG, Shelton ML. Arthrokatachysis of hip following convulsive seizure. <i>N Y State J Med</i> 1975;75(8):1267	29	Female	Right		Yes	Brain metastases	Metastases (breast cancer)	
Eastwood JB, Parker B, Reid BR. Bilateral central fracture-dislocation of hips after myelography with meglumine iocarmate (Dimmer X). <i>Br Med J</i> 1978;1(6114):692	27	Female	Bilateral		Yes	Meglumine		
Berman AT, Metzger PC, Chinitz JL. Central acetabular fracture-dislocation secondary to an epileptic seizure in a chronic renal patient. <i>J Trauma</i> 1981;21(1):66	54	Female	Right		Yes	Metabolic (dialysis)	Renal osteodystrophy	
Varma AN, Seth SK, Verma M. Simultaneous bilateral central dislocation of the hip—an unusual complication of eclampsia. <i>J Trauma</i> 1981;21(6):499	25	Female	Bilateral			Eclampsia		
Schattner A, Green L, Malkin C. Multiple fracture with a central dislocation of the hip, due to convulsions in herpes encephalitis. <i>Isr J Med Sci</i> 1982;18(8):883	63	Female	Left	Vertebrae humerus		Encephalitis	Osteopenia	
Margulies JY, Rubinstein N, Fast A, Floman Y. Osteoporosis and seizures leading to central acetabular fracture dislocation. <i>Isr J Med Sci</i> 1983;19(1):85	40	Female	Right			Epilepsy	Osteoporosis steroid induced	
Lovelock JE, Monaco LP. Central acetabular fracture dislocations: an unusual complication of seizures. <i>Skeletal Radiol</i> 1983;10(2):91	83	Female	Right			Hyponatremia	Osteopenia	Non-operative
Remec PT, Everts CM. Bilateral central dislocation of the hip. A case report. <i>Clin Orthop</i> 1983;(181):118	72	Female	Bilateral			Hyponatremia	Osteopenia	Non-operative
Duus BR. Fractures caused by epileptic seizures and epileptic osteomalacia. <i>Injury</i> 1986;17(1):31	35	Male	Left	Humerus		Epilepsy	Osteomalacia	Non-operative
Aubart F, Fares J, Chaise F. [Acetabular fracture with intrapelvic luxation following an epileptic attack. Apropos of 2 cases including 1 bilateral case]. <i>Rev Chir Orthop Reparatrice Appar Mot</i> 1986;72(2):143	60 84	Male Male	Bilateral Left	Femur	Yes (10 d)			Non-operative Non-operative
Hertlein H, Mittlemeier T, Schurman M, Lob G. 2-pfeileracetabulumfraktur mit zentraler Hüftluxation und ipsilaterale Schenkelhalsfraktur beim epileptischen Anfall. <i>Chirurg</i> 1991;62:429	61	Male	Left	Femur, humerus		Cerebrovascular accident		Non-operative
Ribacoba-Montero R, Salas-Puig J. Simultaneous bilateral fractures of the hip following a grand mal seizure. An unusual complication. <i>Seizure</i> 1997;6(5):403	75	Male	Left	Femur		Epilepsy		Greater trochanter traction
Ovesen J, Madsen CF. [Multiple fractures following seizures in a pregnant woman]. <i>Ugeskr Laeger</i> 1998;160(36):5196	27	Female	Bilateral	Humerus		Eclampsia		Non-operative
Granhed HP, Karladani A. Bilateral acetabular fracture as a result of epileptic seizure: a report of two cases. <i>Injury</i> 1997;28(1):65	74 84	Male Male	Bilateral Bilateral			Cerebrovascular accident Cerebrovascular accident		Non-weight bearing 3 months Non-weight bearing 3 months
Foote GA, Koelmeyer TD, Eyre KE, Astley TM. Complications of epilepsy and a ruptured pyonephrosis: radiology to the rescue in the Brooks murder case. <i>Australas Radiol</i> 1998;42(2):130	64	Male	Right	Bilateral shoulder	Yes, 5 wk	Epilepsy		
Rosa MA, Maccauro G, D'Arienzo M. Bilateral acetabular fracture without trauma. <i>Int Orthop</i> 1999;23(2):120	70	Male	Bilateral			Epilepsy	Osteoporosis	Bilateral THA (6 wk after fracture)
Khalily C, Ilizaliturri Jr. VM, Lester DK. Bilateral pathologic fractures of the hip and acetabulum treated with cementless total hip arthroplasty. <i>J Arthroplasty</i> 2002;17(5):664	47	Female	Bilateral	Neck femur bilateral		Epilepsy	Metastasis (breast cancer)	Cementless bilateral THA (12 d after fracture)

Friedberg R, Buras J. Bilateral acetabular fractures associated with a seizure: a case report. <i>Ann Emerg Med</i> 2005;46(3):260	71	Male	Bilateral	Epilepsy	Non-weight bearing 3 months
Mader TJ, Booth J, Gaudet C, Hynds-Decoteau R. Seizure-induced acetabular fractures: 5-year experience and literature review. <i>Am J Emerg Med</i> 2006;24(2):230	74	Male	Right	Epilepsy	Surgical (no details)
Takahashi Y, Ohnishi H, Oda K, Nakamura T. Bilateral acetabular fractures secondary to a seizure attack caused by antibiotic medicine. <i>J Orthop Sci</i> 2007;12(3):308	86	Female	Right	Epilepsy	Non-weight bearing 3 months
Langenhan R, Hohendorff B, Trobisch P, Probst A. [Simultaneous bilateral humeral head dislocation and acetabular fracture. A rare manifestation after hypoglycemia-induced seizures]. <i>Unfallchirurg</i> 2014;117(8):747	45	Male	Bilateral	Antibiotic (cefotaxime)	Femoral traction 7 wk and non-weight bearing 4 wk
Meena UK, Meena DS, Behera P, Meel OS. Bilateral central acetabular fracture dislocation in a young patient due to seizure activity: a case report and review of the literature. <i>Chin J Traumatol</i> 2014;17(6):364	48	Male	Bilateral	Hypoglycemia	Osteosynthesis (4 d after fracture)
Sheth et al (2016) (14)	32	Male	Bilateral	Epilepsy	Traction 6 wk then non-weight bearing 4 wk
Tempelaere et al (2017) this study	72	Male	Bilateral	Epilepsy	Traction 3 mo
	76	Male	Bilateral	Epilepsy	One stage bilateral THA (21 d after trauma)

trauma the patient had very good musculature and the anterior approach has less risk of dislocation than any other approach [20]. Metal-on polyethylene is commonly used in patients older than 70 years, with good results.

Simultaneous bilateral THA was first reported by Jaffe and Charnley in 1971 [21]. The Swedish register demonstrates that there are no clinical differences between simultaneous THA and 2-time surgery [22]. The benefits of a 1-stage procedure include a single anesthesia, a shorter hospital stay, faster rehabilitation, and improved cost effectiveness, although concerns have been raised in the past regarding the potential for increased post-operative complications [23]. Recent studies show no significant difference between 1- and 2-stage intervention in terms of cardiopulmonary complications, thromboembolic events, stroke, surgical site infection, rate of allogenic transfusion, or prevalence of fat embolism [24]. Simultaneous sequential bilateral THA is a safe option for patients who are considered to be low risk according to their American Society of Anesthesiologists classification [25]. In the case of this patient, and after a multi-disciplinary staff meeting with anesthesiologists, orthopaedic surgeons, intensive care unit physicians and family was held, a 1-stage procedure was planned. The patient had only 1 general anesthetic with right THA being conducted first, followed by left THA.

Anterior approach THA has the advantage of a single supine position for bilateral simultaneous surgery, so it is appropriate in this case. A study showed that blood loss was significantly lower during an anterior approach rather than a lateral approach in a bilateral 1-stage surgery, as was the transfusion rate [26].

Acute THA in elderly patient with acetabular fracture allows patients to return to the previous daily life activity [27–29]. It is also associated with a shorter operating time and lower rate of mortality than osteosynthesis [30]. Patients have full functional recovery with immediate loading and excellent results in the short and medium term with minimal complications [27,28,31–33]. Mean time from fall to surgery remains to be between 1 day and 6 weeks to be considered as an early treatment [27,30,31]. In our case, surgery was done on the third week after fall with a good result and return to previous daily life activity.

Summary

In the elderly, bilateral acetabular fractures due to a seizure may be treated by 1-stage bilateral THA through an anterior approach with good results.

Acknowledgments

Thanks to Miss Sally Spurr for translation help.

References

- [1] O'connor-Read L, Bloch B, Brownlow H. A missed orthopaedic injury following a seizure: a case report. *J Med Case Rep* 2007;1:20.
- [2] Finelli PF, Cardi JK. Seizure as a cause of fracture. *Neurology* 1989;39(6):858.
- [3] Ferguson TA, Patel R, Bhandari M, Matta JM. Fractures of the acetabulum in patients aged 60 years and older: an epidemiological and radiological study. *J Bone Joint Surg Br* 2010;92(2):250.
- [4] Haronian E, Silver JW, Mesa J. Simultaneous bilateral femoral neck fracture and greater tuberosity shoulder fracture resulting from seizure. *Orthopedics* 2002;25(7):757.
- [5] Mouhsine E, Garofalo R, Borens O, et al. Cable fixation and early total hip arthroplasty in the treatment of acetabular fractures in elderly patients. *J Arthroplasty* 2004;19(3):344.
- [6] Guerado E, Cano JR, Cruz E. Fractures of the acetabulum in elderly patients: an update. *Injury* 2012;43(Suppl. 2):S33.
- [7] Salama W, Mousa S, Khalefa A, et al. Simultaneous open reduction and internal fixation and total hip arthroplasty for the treatment of osteoporotic acetabular fractures. *Int Orthop* 2017;41(1):181.

- [8] Park K-S, Moon J-Y, Oh C-S, Yoon T-R. Acetabular central fracture dislocation after generalized seizure during lumbar myelography with iohexol. *Case Rep Orthop* 2013;2013:190917.
- [9] Parker MJ, Palmer CR. A new mobility score for predicting mortality after hip fracture. *J Bone Joint Surg Br* 1993;75(5):797.
- [10] Neer CS. Displaced proximal humeral fractures. *J Bone Joint Surg Am* 1970;52(6):1090.
- [11] Connolly KP, Kamath AF. Direct anterior total hip arthroplasty: literature review of variations in surgical technique. *World J Orthop* 2016;7(1):38.
- [12] Nilsdotter A, Bremander A. Measures of hip function and symptoms: Harris Hip Score (HHS), Hip Disability and Osteoarthritis Outcome Score (HOOS), Oxford Hip Score (OHS), Lequesne Index of Severity for Osteoarthritis of the Hip (LISOH), and American Academy of Orthopedic Surgeons (AAOS) Hip and Knee Questionnaire. *Arthritis Care Res* 2011;63(Suppl. 11):S200.
- [13] Brooker AF, Bowerman JW, Robinson RA, Riley LH. Ectopic ossification following total hip replacement. Incidence and a method of classification. *J Bone Joint Surg Am* 1973;55(8):1629.
- [14] Friedberg R, Buras J. Bilateral acetabular fractures associated with a seizure: a case report. *Ann Emerg Med* 2005;46(3):260.
- [15] Shaw JL. Bilateral posterior fracture-dislocation of the shoulder and other trauma caused by convulsive seizures. *J Bone Joint Surg Am* 1971;53(7):1437.
- [16] Sheth H, Salunke AA, Panchal R, et al. Simultaneous bilateral shoulder and bilateral central acetabular fracture dislocation: what to do? *Chin J Traumatol* 2016;19(1):59.
- [17] Mears DC, Velyvis JH. Acute total hip arthroplasty for selected displaced acetabular fractures: two to twelve-year results. *J Bone Joint Surg Am* 2002;84-A(1):1.
- [18] Spencer RF. Acetabular fractures in older patients. *J Bone Joint Surg Br* 1989;71(5):774.
- [19] Acker A, Fischer J-F, Aminian K, Lécureux E, Jolles BM. Total hip arthroplasty using a cementless dual-mobility cup provides increased stability and favorable gait parameters at five years follow-up. *Orthop Traumatol Surg Res* 2017;103(1):21.
- [20] Tamaki T, Oinuma K, Miura Y, et al. Epidemiology of dislocation following direct anterior total hip arthroplasty: a minimum 5-year follow-up study. *J Arthroplasty* 2016;31(12):2886.
- [21] Jaffe WL, Charnley J. Bilateral Charnley low-friction arthroplasty as a single operative procedure. A report of fifty cases. *Bull Hosp Joint Dis* 1971;32(2):198.
- [22] Garland A, Rolfson O, Garellick G, Kärrholm J, Hailer NP. Early postoperative mortality after simultaneous or staged bilateral primary total hip arthroplasty: an observational register study from the Swedish Hip Arthroplasty Register. *BMC Musculoskelet Disord* 2015;16:77.
- [23] Berend KR, Lombardi AV, Adams JB. Simultaneous vs staged cementless bilateral total hip arthroplasty: perioperative risk comparison. *J Arthroplasty* 2007;22(6 Suppl. 2):111.
- [24] Yoshii H, Oinuma K, Tamaki T, et al. Comparison of patient satisfaction after unilateral or simultaneous bilateral total hip arthroplasty through a direct anterior approach: evaluation using the Japanese Orthopaedic Association Hip Disease Evaluation Questionnaire. *J Orthop Sci* 2016;21(3):332.
- [25] Kim Y-H, Kwon O-R, Kim J-S. Is one-stage bilateral sequential total hip replacement as safe as unilateral total hip replacement? *J Bone Joint Surg Br* 2009;91(3):316.
- [26] Parvizi J, Tarity TD, Sheikh E, et al. Bilateral total hip arthroplasty: one-stage versus two-stage procedures. *Clin Orthop* 2006;453:137.
- [27] Giunta J-C, Tronc C, Kerschbaumer G, et al. Outcomes of acetabular fractures in the elderly: a five year retrospective study of twenty seven patients with primary total hip replacement. *Int Orthop* 2018;1:1–7.
- [28] Jordá-Gómez P, Escribá-Urios I, Castro-Gil J, Aracil Silvestre J. Acute management of acetabular fractures by total hip arthroscopy using an anterior approach. *Rev Esp Cir Ortop Traumatol* 2019;63(2):104.
- [29] Iqbal F, Ullah A, Younus S, et al. Functional outcome of acute primary total hip replacement after complex acetabular fractures. *Eur J Orthop Surg Traumatol* 2018;28(8):1609.
- [30] Capone A, Peri M, Mastio M. Surgical treatment of acetabular fractures in the elderly: a systematic review of the results. *EFORT Open Rev* 2017;2(4):97.
- [31] Salar N, Bilgen MS, Bilgen ÖF, et al. Total hip arthroplasty for acetabular fractures: "Early application". *Ulus Travma Acil Cerrahi Derg* 2017;23(4):337.
- [32] Jouffroy P. Indications and technical challenges of total hip arthroplasty in the elderly after acetabular fracture. *Orthop Traumatol Surg Res* 2014;100(2):197.
- [33] Cochu G, Mabit C, Gougam T, et al. [Total hip arthroplasty for treatment of acute acetabular fracture in elderly patients]. *Rev Chir Orthop Reparatrice Appar Mot* 2007;93(8):818.