

Induced Apnea During Delayed Tracheostomy in Mechanically Ventilated Patients With COVID-19

A 2-center Early Experience

Alejandro Hernández-Solis, MD, MSc,* Benito Vargas-Abrego, MD,*
Erick Vidal-Andrade, MD,† José L. Sanjurjo-Martínez, MD, MEd,‡
Arturo Reding-Bernal, PhD,§
and Pablo Álvarez-Maldonado, MD, MHA, FCCP, FCCM*†

Key Words: COVID-19, SARS-CoV-2, ICU, percutaneous tracheostomy, bronchoscopy, apnea

(*J Bronchol Intervent Pulmonol* 2022;29:83–85)

Both conventional and modified tracheostomy techniques proposed for patients with COVID-19 (coronavirus disease 2019) entail a variable number of apnea periods^{1–4}; however, the duration and effects on patients and health care workers have been poorly described. Here, we performed an analysis of consecutive percutaneous dilatational tracheostomies (PDTs) performed in 2 hospitals' intensive care units (ICUs). We collected data from clinical records from March 25, 2020, to January 15, 2021.

The adopted PDT technique differed from the standard bronchoscopy-guided Ciaglia's Blue-Rhino technique⁵ in pausing mechanical ventilation during key steps and avoiding leaks. Both ICUs perform procedures within negative pressure rooms, and only 3 operators (2 surgeons, 1 intensivist) were present in the room. Should assistance be needed, an ICU nurse was available to enter the room. Personal protective equipment consisted of hair cover, surgical gown and boots, double gloves, goggles, and filtering facepiece N95 respirators. Patients were in a supine position under sedation, analgesia, and muscle paralysis; the intensivist was placed at the head of the bed for bronchoscopic guidance, to medicate the patient and monitor the clinical

condition; the procedure could be suspended or exchanged for an open tracheostomy without the use of apnea. Ventilator parameters were adjusted to meet at least two third of the baseline minute ventilation during the entire procedure in the pressure-controlled mode. Fraction of inspired oxygen (FiO₂) was set to 1.0 at 5 minutes before the PDT. During the first apnea period, we placed a disposable bronchoscope with a swivel connector, avoiding aspiration at any time. The ventilator was then turned on, and the endotracheal tube (ETT) was pulled back until the cuff had been placed in the subglottic space. Meanwhile, a 1.5 to 2.0 cm neck skin incision was made. To prevent aerosol output, a syringe with saline was used for tracheal needle puncture, and the needle was covered with gauze while the wire guide was inserted. A second apnea was performed at that point for passing the single dilator and the tracheostomy tube, and the stoma was covered with gauze during both maneuvers. The ETT was removed, the tracheostomy tube cuff was inflated, and the mechanical ventilator was reconnected and turned on. Finally, the tracheostomy was secured to the neck with ties and sutures.

Continuous variables are reported as mean ± SD and dichotomous variables are reported as absolute and relative numbers. One-way repeated-measures analysis of variance was performed to identify differences between oxygen saturation (SpO₂)% means before (prior preoxygenation), during, and (5 min) after PDT. The pairwise estimated marginal means were compared by adjusting with the Bonferroni method. A *P*-value < 0.05 was considered statistically significant. The institutional review boards approved this report, waiving the need for informed consent.

Of 580 ICU patients, 76 required tracheostomy. The patients' characteristics and ventilator parameters before PDT are shown in Table 1. The time from intubation to PDT was 20.2 ± 6.2 days. No

Received for publication April 21, 2021; accepted August 31, 2021.

From the *Department of Pulmonology and Thoracic Surgery; †Research Division, Mexico's General Hospital "Dr. Eduardo Liceaga"; ‡Intensive Care Unit; and ‡Department of Otolaryngology, Mexico's Spanish Hospital, Mexico City, Mexico.

Disclosure: There is no conflict of interest or other disclosures.

Reprints: Pablo Álvarez-Maldonado, MD, MHA, FCCP, FCCM, Dr. Balmis 148, Doctores, Cuauhtémoc, Ciudad de México 06720, México (e-mail: pamyacs@yahoo.com).

Copyright © 2021 Wolters Kluwer Health, Inc. All rights reserved.

DOI: 10.1097/LBR.0000000000000817

procedure was suspended or converted to open tracheostomy due to intolerance to apnea. PDT duration was 10.6 ± 3.4 minutes. The apnea periods lasted 12.5 ± 6.2 and 44.9 ± 18.3 seconds. The lowest SpO₂% values before, during, and after PDT was 92.6 ± 2.6 , 86.3 ± 5.1 , and 96.2 ± 3.5 , and the most significant decrease occurred during the second apnea ($P < 0.0001$) (Fig. 1). Two patients required a third apnea (14 and 16 s) to explore the airway through the tracheostomy because of suspicion of bleeding, which was subsequently ruled out endoscopically. Other complications were ETT decannulation in 1 patient (which was addressed by pushing forward the ETT over the bronchoscope) and rising blood pressure in another (which normalized soon after ventilation was started). No operator resulted positive (6 of 6 reverse transcription-polymerase chain reaction tested) 2 weeks after the last PDT or had any symptoms of severe acute respiratory syndrome coronavirus 2 (SARS-CoV-2) infection. Vaccination was available at our sites after the last PDT.

TABLE 1. Characteristics of Patients With COVID-19 Undergoing PDT

Variable	N = 76 [n (%)]
Age (mean \pm SD)	56 \pm 14
Male/female	55/21 (72/28)
SAPS-3 (mean \pm SD)	60 \pm 8
SOFA score (mean \pm SD)	6.8 \pm 2.4
Comorbidities	
Obesity (body mass index \geq 30)	33 (43)
Type 2 diabetes mellitus	25 (33)
Hypertension	19 (25)
End stage renal disease	4 (5)
Hypothyroidism	3 (4)
Puerperium	3 (4)
Chronic use of corticosteroids—other	3 (4)
HIV/AIDS	1 (1.3)
Underwent extubation attempt before PDT	37 (49)
Tracheal tube internal diameter (mean \pm SD) (mm)	8.0 \pm 0.3
Ventilator parameters before PDT	
Mode	
Pressure-controlled ventilation	33 (44)
Pressure support ventilation	25 (33)
Volume-controlled ventilation	14 (18)
Adaptive support ventilation	4 (5)
PEEP level (mean \pm SD) (cm H ₂ O)	6.6 \pm 1.7
FiO ₂ (mean \pm SD)	0.48 \pm 0.13
PaO ₂ /FiO ₂ (mean \pm SD)	224 \pm 75
Respiratory rate (mean \pm SD)	21 \pm 4
Ventilation (mean \pm SD) (L/min)	8.5 \pm 1.9

AIDS indicates acquired immunodeficiency syndrome; COVID-19, coronavirus disease 2019; FiO₂, fraction of inspired oxygen; HIV, human immunodeficiency virus; PDT, percutaneous dilatational tracheostomy; PaO₂, partial pressure of oxygen; PEEP, positive end-expiratory pressure; SAPS-3, Simplified Acute Physiology Score 3; SOFA, Sequential Organ Failure Assessment.

Recommendations for tracheostomy and proposals for modified techniques during this COVID-19 era use apnea periods to prevent aerosolization.¹⁻⁴ After the cycle of aerosol generation ceases with apnea, aerosols settle at the alveolar level, decreasing their concentration until becoming minor.⁶ With the airway system open, small amounts of aerosols may enter the surgical area from passive exhalation, owing to the thoracic elastic recoil. In a recent simulated PDT model study, Majid et al⁷ have shown that aerosol spillage is lower when intermittent ventilator pauses accompanied different techniques.

We used 2 apnea periods in all patients. The relatively short first period may be skipped if PDT is done with ultrasound guidance. The second period lasted 45 seconds on average; and, even though the most significant decrease in SpO₂ took place at this time, it proved to be safe with no major repercussions. SpO₂ decreases $> 20\%$ were observed in a mixed population series, including 10 patients with COVID-19,⁸ and a series of 28 COVID-19 patients⁴ when the apnea duration reached up to 4 minutes, with an average number of ventilator days before tracheostomy of 16 and 26 days, respectively. The rising blood pressure could have been due to an increase in partial pressure of carbon dioxide in 1 patient. We did not monitor end-tidal carbon dioxide because of inaccurate readings while the bronchoscope was used, although this measurement may potentially be useful.

Time from intubation to PDT could be considered as delayed tracheostomy.⁹ Most patients had come out of the critical phase of acute respiratory failure, and we planned to perform PDT because of ventilator dependence. Although some would disagree, this time may pose the lowest risk of operator exposure and provide significant patient benefit. Lower FiO₂ and positive end-expiratory pressure requirements make these patients more apt to tolerate short periods of apnea. It would be of interest to assess the impact of apnea in patients with higher FiO₂ and positive end-expiratory pressure or the early ICU stay as well.

Unless urgent, bronchoscopy is not recommended in COVID-19.¹⁰ We consider that its prudent use made PDT fast and safe in this patient series. Of concern is that even experienced bronchoscopists during short-term procedures can become infected, as shown in the early Spanish COVID-19 experience¹¹; but contrary to this report, we did not perform aspiration or sampling this series.

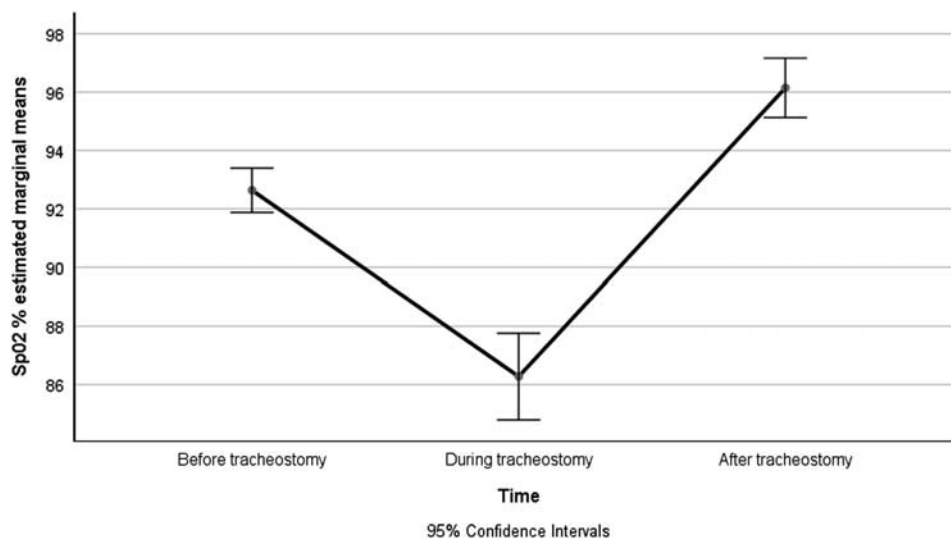


FIGURE 1. The estimated SpO₂% marginal means and 95% confidence intervals before, during, and after tracheostomy. Significant differences were observed among the marginal means, $P < 0.0001$. SpO₂ indicates oxygen saturation.

Besides being descriptive, the possibility that operators had acquired the disease without presenting symptoms is another study's limitation; in this regard, serum antibody testing would also have been useful. When we implemented the PDT protocol, some unknowns and no preliminary data regarding technical aspects and pathways were available; however, the body of evidence of COVID-19 and tracheostomy has changed substantially and will continue to do so.

Because most tracheostomy techniques proposed to date have used induced apnea to avoid aerosolization, this study offers clinically useful data regarding the safety of applying this maneuver in prolonged mechanically ventilated patients. PDT using brief apnea periods appears to be safe for both patients and operators without causing serious adverse events.

ACKNOWLEDGMENTS

The authors dedicate this letter to the memory of Dr Raul Cicero Sabido, pioneer of bronchoscopy in Mexico and our beloved mentor.

REFERENCES

- Lamb CR, Desai NR, Angel L, et al. Use of Tracheostomy during the COVID-19 pandemic: American College of Chest Physicians/American Association for Bronchology and Interventional Pulmonology/Association of Interventional Pulmonology Program Directors Expert Panel Report. *Chest*. 2020;158:1499–1514.
- Hashimoto DA, Axtell AL, Auchincloss HG. Percutaneous tracheostomy. *N Engl J Med*. 2020;383:e112.
- Bier-Laning C, Cramer JD, Roy S, et al. Tracheostomy during the COVID-19 Pandemic: comparison of international perioperative care protocols and practices in 26 countries. *Otolaryngol Head Neck Surg*. 2021;164:1136–1147.
- Weiss KD, Coppolino A III, Wiener DC, et al. Controlled apneic tracheostomy in patients with coronavirus disease 2019 (COVID-19). *JTCVS Tech*. 2021;6:172–177.
- Cook Medical, Education and Training. Procedural video series—Ciaglia Blue Rhino® G2 Advanced Percutaneous Tracheostomy Introducer. Available at: www.cookmedical.com/products/cc_ptis_webds/. Accessed November 20, 2020.
- Johnson GR, Morawska L. The mechanism of breath aerosol formation. *J Aerosol Med Pulm Drug Deliv*. 2009;22:229–237.
- Majid A, Ayala A, Uribe JP, et al. Protective strategies in a simulated model when performing percutaneous tracheostomies in the COVID-19 era. *Ann Am Thorac Soc*. 2020;17:1486–1488.
- Niroula A, Van Nostrand KM, Khullar OV, et al. Percutaneous tracheostomy with apnea during coronavirus disease 2019 era: a protocol and brief report of cases. *Crit Care Explor*. 2020;2:e0134.
- Chiang SS, Aboutanos MB, Jawa RS, et al. Controversies in tracheostomy for patients with COVID-19: the when, where, and how. *Respir Care*. 2020;65:1767–1772.
- Wahidi MM, Shojaee S, Lamb CR, et al. The use of bronchoscopy during the coronavirus disease 2019 pandemic: CHEST/AABIP guideline and expert panel report. *Chest*. 2020;158:1268–1281.
- Torrego A, Pajares V, Fernández-Arias C, et al. Bronchoscopy in patients with COVID-19 with invasive mechanical ventilation: a single-center experience. *Am J Respir Crit Care Med*. 2020;202:284–287.