

Optical Coherence Tomography and the Development of Antiangiogenic Therapies in Neovascular Age-Related Macular Degeneration

Philip J. Rosenfeld

Bascom Palmer Eye Institute, University of Miami Miller School of Medicine, Miami, Florida, United States

Correspondence: Philip J. Rosenfeld, Bascom Palmer Eye Institute, University of Miami Miller School of Medicine, Department of Ophthalmology, 900 NW 17th Street, Miami, FL 33136, USA; prosenfeld@miami.edu.

Submitted: May 21, 2016
Accepted: June 12, 2016

Citation: Rosenfeld PJ. Optical coherence tomography and the development of antiangiogenic therapies in neovascular age-related macular degeneration. *Invest Ophthalmol Vis Sci*. 2016;57:OCT14–OCT26. DOI:10.1167/iovs.16-19969

PURPOSE. To explain the pivotal role optical coherence tomography (OCT) imaging had in the development of antiangiogenic therapies for the treatment of neovascular age-related macular degeneration (nvAMD).

METHODS. A historical literature review was combined with personal perspectives from the introduction of OCT imaging and the early clinical use of vascular endothelial growth factor (VEGF) inhibitors.

RESULTS. At the time that OCT emerged, the gold standard for imaging of nvAMD was fluorescein angiography (FA), a time-consuming, dye-based, invasive technique that provided en face images of the retina and was used to characterize leakage, perfusion status, and the types of macular neovascularization (MNV). In comparison, OCT imaging was a fast, safe, noninvasive technique that complemented FA imaging by providing cross-sectional images of the macula. OCT was able to visualize and quantify the macular fluid that was associated with the presence of excess VEGF, which was identified by intraretinal fluid, subretinal fluid, and fluid under the retinal pigment epithelium (RPE). Clinicians quickly appreciated the benefits of OCT imaging for following macular fluid after anti-VEGF therapy. By observing the qualitative and quantitative changes in macular fluid depicted by OCT imaging, clinicians were empowered to compare anti-VEGF drugs and move from fixed-dosing regimens to patient-specific dosing strategies requiring fewer injections.

CONCLUSIONS. Optical coherence tomography imaging was adopted as a VEGF-meter, a method to detect excess VEGF, and evolved to become the gold standard imaging strategy for diagnosing nvAMD, assessing treatment responses to anti-VEGF drugs, deciding when to retreat, and evaluating disease progression.

Keywords: optical coherence tomography, neovascularization, anti-vascular endothelial growth factor, antiangiogenesis, exudation

The modern era of clinical optical coherence tomography (OCT) imaging and antiangiogenic therapy emerged and converged during the early years of the 21st century. This convergence of pharmaceutical and imaging technologies revolutionized the care of patients with exudative retinal diseases, most notably neovascular (wet) age-related macular degeneration (AMD), diabetic macular edema, proliferative diabetic retinopathy, and retinal vein occlusions. A common mediator of exudation in all these diseases turned out to be vascular endothelial growth factor (VEGF), and the development of VEGF inhibitors coincided with the commercial availability of the first commercially successful OCT instrument, known as the OCT III or Stratus OCT (Carl Zeiss Meditec, Dublin, CA, USA), a time-domain OCT (TD-OCT) instrument capable of performing six diagonal line scans at a rate of 400 A-scans per second. The first OCT descriptions of exudation performed with these Zeiss time-domain instruments provided revelatory insights as to the nature of fluid in the retina, under the retina, and under the retinal pigment epithelium (RPE) (Figs. 1–5).

Prior to OCT imaging, the gold standard was fluorescein angiography (FA), and to a lesser extent, indocyanine green

angiography (ICGA). These dye-based imaging strategies provided two-dimensional images of neovascularization and exudation, and if an examiner was schooled in the art of stereoscopic viewing, the relative location of the neovascular lesion and the magnitude of the exudation could be appreciated, although this information was hard to share with patients and colleagues unless they too could view the images stereoscopically. Much of our understanding of these exudative processes came from descriptions provided by experts using slit-lamp biomicroscopic viewing of the fundus followed by stereoscopic viewing of dye-based angiographic images.¹ As someone who spent his early career training residents and retina fellows on how to stereoscopically examine the fundus and view angiographic images, I was always uncertain whether the student truly saw what needed to be seen. With the development of OCT imaging, all that changed. Using TD-OCT, both ophthalmologist and patient could readily appreciate the anatomic nuances of exudation, and with each improvement in OCT technology, the image quality improved to the point where OCT is now the gold standard for imaging and managing patients with exudative macular diseases, especially when undergoing antiangiogenic therapies.

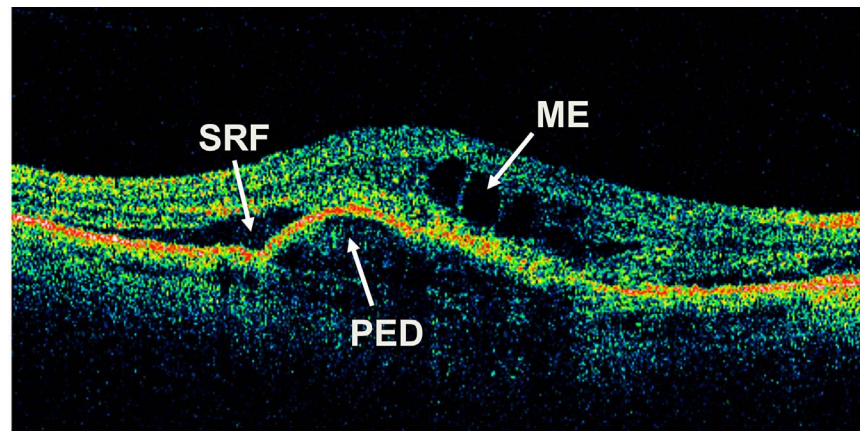


FIGURE 1. Time-domain optical coherence tomography B-scan through the central macula of an eye with neovascular age-related macular degeneration showing macular edema (ME), subretinal fluid (SRF), and a retinal pigment epithelial detachment (PED).

TD-OCT AND SD-OCT IMAGING OF NEOVASCULAR AMD

The Stratus TD-OCT had a scanning rate of 400 A-scans per second and generated a standard scanning pattern that consisted of six radial, concentric, 6-mm-long B-scans centered on the fovea and offset by 30°. Image quality often depended

on the cooperation of the patient and the skill of the operator, since tracking was not yet available and higher-density scans took longer to acquire. Over the past 15 years as OCT technology has evolved, TD-OCT has given way to spectral-domain OCT (SD-OCT). Spectral-domain OCT, a type of Fourier-domain OCT (FD-OCT) with scanning rates of approximately 27,000 to 70,000 A-scans per second, resulted in

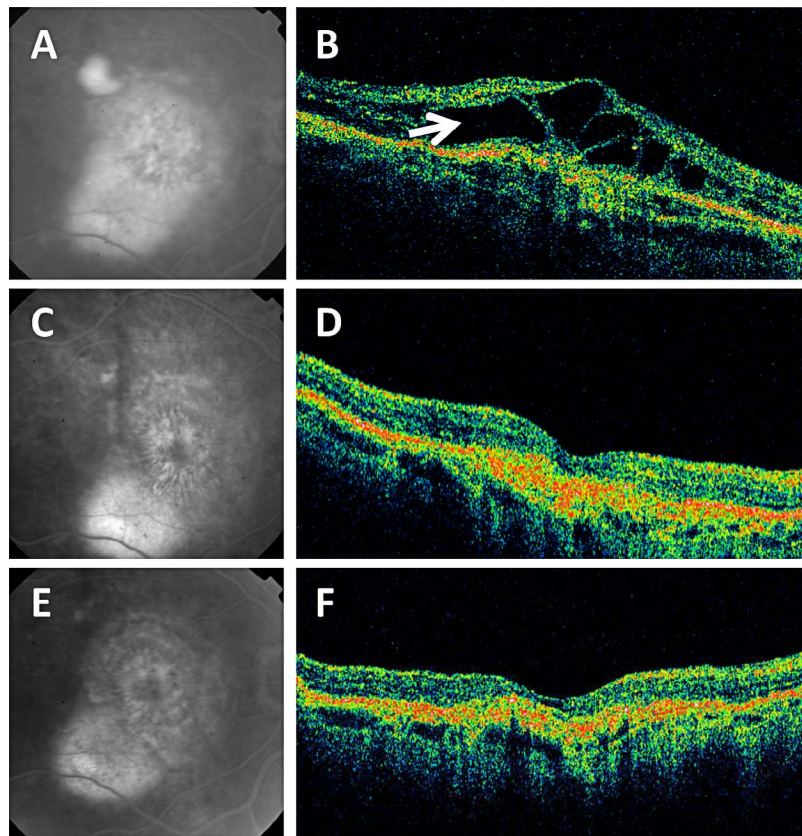


FIGURE 2. Late fluorescein angiographic (FA) images and time-domain optical coherence tomography (OCT) diagonal B-scans from a patient treated with intravitreal ranibizumab in the phase II study, then followed in the extension study with observation and no additional retreatments with ranibizumab.¹⁷ (A, C, E) Late FA images. (B, D, F) Diagonal OCT B-scans. (A) Baseline late FA image showing diffuse leakage. Visual acuity (VA) was 20/125. (B) Corresponding baseline OCT image showed cystic macular edema (arrow). (C) After eight injections over 140 days, the FA leakage had significantly diminished, and VA improved to 20/80. (D) Corresponding OCT B-scan showed resolution of the macular edema. (E) After an additional 22 months without any ranibizumab injections, VA improved to 20/32 and there was no evidence FA leakage. (F) Corresponding OCT B-scan showed a persistently dry macula.

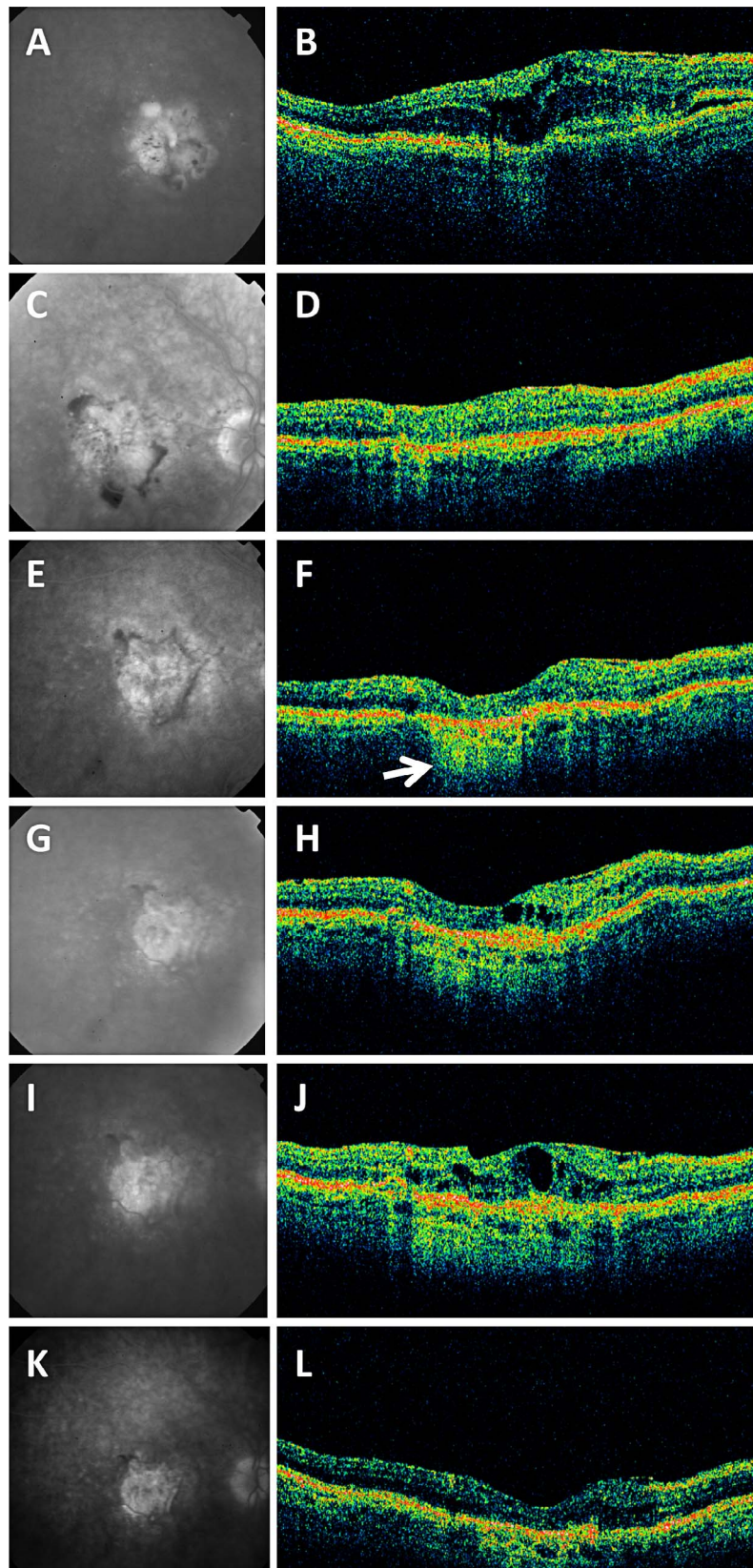


FIGURE 3. Late fluorescein angiographic (FA) images and time-domain optical coherence tomography (OCT) diagonal B-scans from a patient treated with intravitreal ranibizumab in the phase II study, then followed in the extension study with observation and retreatment with ranibizumab.¹⁷ (A, C, E, G, I, K) Late FA images. (B, D, F, H, J, L) Diagonal OCT B-scans. (A) Baseline late FA image showed diffuse leakage. Visual acuity (VA) was 20/200. (B) Baseline OCT image showed cystic macular edema. (C) Two weeks later, VA improved to 20/160, and the FA image showed significant reduction in leakage with focal areas of blocked fluorescence at the margin of the lesion consistent with hemorrhages. (D) Corresponding OCT B-scan with significant resolution of macular edema 2 weeks after the first injection. (E) After 140 days and 10 injections from baseline, VA improved

to 20/100, and late FA image showed no leakage with near-complete resolution of the hemorrhages. (F) Corresponding OCT B-scan showed resolution of the macular edema with evidence of macular atrophy as seen by the hypertransmission of light into the choroid (*arrow*). No treatment was given. (G) After 10 months without treatment, VA was stable at 20/100, but the late FA image showed minimal leakage. (H) Corresponding OCT B-scan showed the appearance of small intraretinal cysts indicative of recurrent macular fluid. No treatment was given. (I) After 4 months without treatment, VA remained unchanged at 20/100 but the patient was complaining of increasing distortion. The FA image showed increased leakage. (J) Corresponding OCT B-scan showed increased macular edema, and a ranibizumab injection was performed. (K) Five months after retreatment, VA improved to 20/63 and the FA image showed no leakage. (L) Corresponding OCT B-scan showed minimal macular thickening nasal to the fovea. Overall, OCT-guided retreatment improved VA, decreased FA leakage, and decreased the macular fluid.

denser, more varied scanning patterns, better image quality, better reproducibility, and large volumetric datasets that could be viewed using both the traditional cross-sectional approach and an en face approach.³ Compared with the more advanced SD-OCT technology now available in the clinics, the capabilities of the Stratus TD-OCT instrument now seem primitive, yet at the time, the images obtained using TD-OCT imaging provided a view of macular neovascularization (MNV) and exudation that would forever change the way we managed patients.

The B-scan image of a normal macula shows layers of differing reflectivity that approximate the major cellular layers of the retina and choroid.⁴ However, features of the choroidal anatomy were poorly visualized using TD-OCT imaging. Thus, by using TD-OCT, it was possible to obtain a crude optical biopsy of the macula and distinguish between a normal retina/RPE contour and an abnormal one, which was all that was needed for the retinal specialist to identify exudation. Moreover, one of the most commonly used quantitative parameters derived from OCT datasets was the retinal thickness measurement, which was obtained by segmenting the internal limiting membrane (ILM) and a boundary representing the RPE. This information was used to generate retinal thickness maps, and these maps proved useful for identifying and describing deviations from normal anatomy and how these deviations changed over time. However, it was the viewing of individual B-scans that provided the retina specialist with a powerful strategy for following disease progression and response to treatment.

While it came as no surprise that OCT imaging was extremely useful for detecting the macular edema expected in cases of diabetes and retinal vein occlusions, it was a surprise to most retina specialists that intraretinal fluid was commonly found as an early and prominent component of the exudation associated with neovascular age-related macular degeneration (nvAMD).⁵ The classification system previously developed for nvAMD was based on leakage patterns seen on dye-based angiography, and this leakage was thought to result in the accumulation of fluid under the retina and under the RPE. This made intuitive sense since the neovascularization was thought to arise under the retina from the choroidal circulation, so why would there be fluid in the retina? In retrospect, the detection of intraretinal fluid turned out to be one of the most novel and important observations made when using TD-OCT for imaging nvAMD. At the time, one explanation for the presence of intraretinal edema was that the subretinal exudation had extended into the retina, but the extension of subretinal fluid into the retina was not commonly seen in other conditions associated with subretinal fluid such as central serous chorioretinopathy (CSCR) and retinal detachment. Moreover, eyes with early CSCR and subretinal fluid, prior to the onset of fibrosis and photoreceptor disorganization, tended to have good best-corrected visual acuity while eyes with nvAMD and similar amounts of subretinal fluid always seemed to have worse vision due to the intraretinal fluid. An alternative explanation for the intraretinal exudation was that this fluid came from established mature retinal vessels, and the exudation was in response to

VEGF. After all, intraocular injections of VEGF into primate eyes had previously been shown to cause retinal edema and hemorrhages.^{6,7} Thus, the presence of macular fluid came to be appreciated as a useful surrogate measure for the presence of excess VEGF. Another explanation for intraretinal fluid was that the neovascularization could be arising from within the retina, and this neovascularization could be directly responsible for the intraretinal macular fluid. In the early days of OCT, this hypothesis seemed far-fetched, but now we know that type 3 MNV (known as retinal angiomatous proliferation) can arise from within the retina and is associated with intraretinal edema.⁸ While type 3 MNV accounts for a minority of neovascular lesions and macular edema is a common feature of all MNV, the most likely explanation for the presence of intraretinal fluid is that VEGF induces exudation from the mature retinal vessels in nvAMD.⁹ Thus, lessons learned from early OCT imaging of nvAMD included an appreciation that intraretinal fluid was one of the first signs of VEGF-mediated exudation (Figs. 2–5).

Not surprisingly, OCT imaging also revealed that macular fluid accumulated in the space between the RPE and the neurosensory retina. Serous exudate appeared on OCT imaging as a homogeneous hyporeflective space, while proteinaceous exudation appeared less homogeneous and was shown to contain reflective fibrinous membranes (Fig. 5). This proteinaceous material has been referred to as subretinal hyperreflective material (SHRM) or subretinal hyperreflective material exudate (SHRE) and is different from the hyperreflective fibrosis that can form in more advanced neovascular lesions.^{10–12} The SHRM/SHRE of particular concern is the material that accumulates between the retina and RPE as seen on OCT imaging (Fig. 5). Neovascular lesions with SHRM/SHRE have been associated with worse visual acuity (VA) outcomes due to the formation of fibrotic scars and photoreceptor atrophy. Usually, type 2 MNV, which grows in the subretinal space, has been shown to be associated with a larger volume of subretinal fluid compared with sub-RPE lesions or type 1 MNV. While these type 1 neovascular lesions have been associated with less subretinal fluid, they are associated with detachments of the RPE known as retinal pigment epithelial detachments (PEDs) (Figs. 4, 5), and early on, OCT imaging was shown to be a useful technique for identifying and characterizing PEDs.^{2,13} While the presence of a PED and blood was shown to serve as a poor prognostic sign in neovascular AMD, an even worse development, often associated with hemorrhage, was the formation of a RPE tear. Optical coherence tomography imaging of RPE tears was shown to reveal an area of RPE discontinuity with the free edge of the RPE often curled under the PED.¹⁴ Adjacent to the tear, OCT imaging has revealed areas with increased choroidal reflectivity with improved visualization of choroidal vessels due to the absence of the RPE. Typically, the overlying retina was found to be intact, but could be separated from the area of atrophy by subretinal fluid.

In all these examples of macular fluid, whether the fluid was in the retina, under the retina, or under the RPE, OCT imaging was the ideal technique for detecting the excess fluid and determining whether it had changed. Since most of the macular fluid occurred in response to excess VEGF, the stage

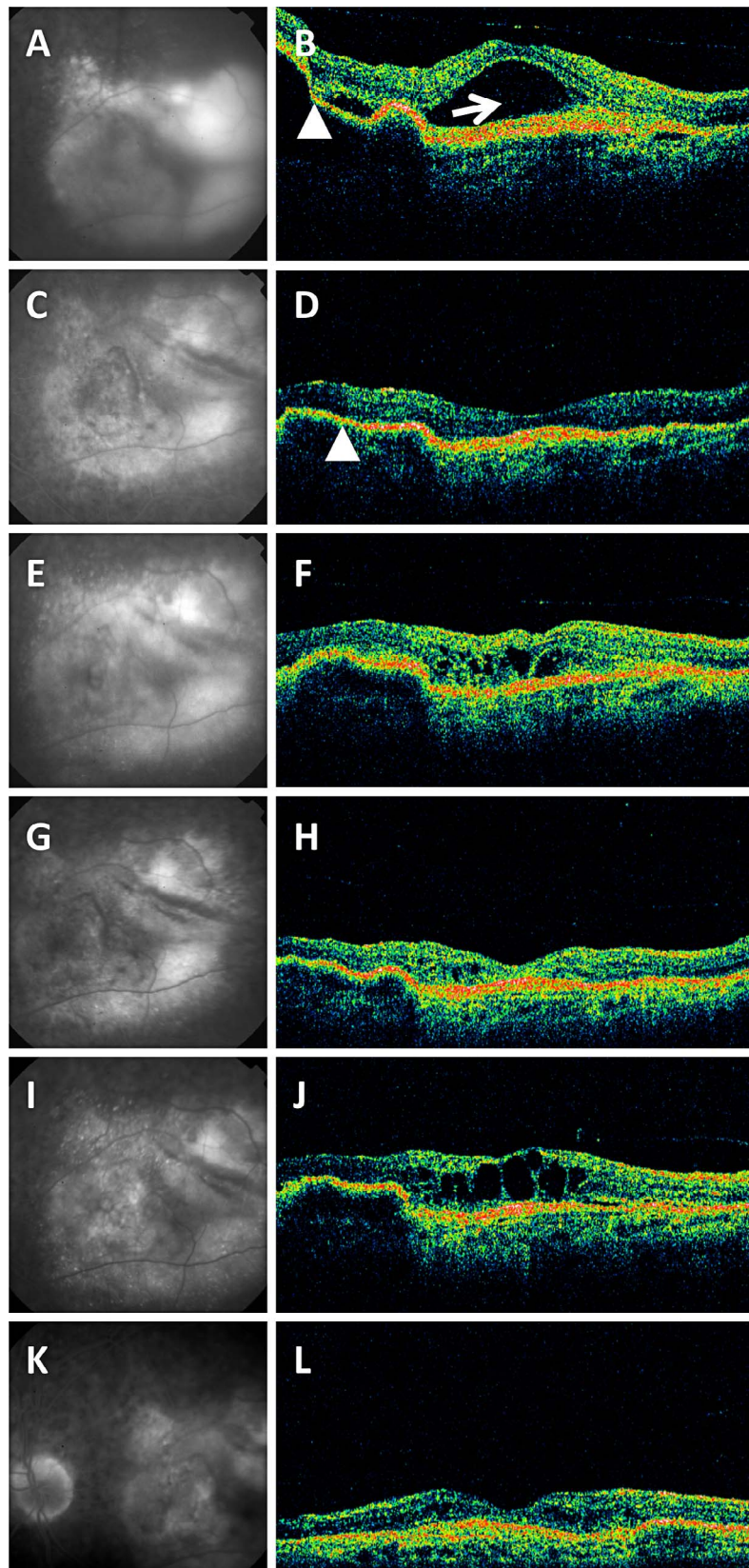


FIGURE 4. Late fluorescein angiographic (FA) images and time-domain optical coherence tomography (OCT) diagonal B-scans from a patient treated with intravitreal ranibizumab in the phase II study, followed in the extension study by observation and then retreatment with ranibizumab.¹⁷ (A, C, E, G, I, K) Late fluorescein angiographic images. (B, D, F, H, J, L) Diagonal OCT B-scans. (A) Baseline late FA image showed significant leakage. Visual acuity (VA) was 20/80. (B) Corresponding baseline OCT image showed subretinal fluid (*arrow*) and a retinal pigment epithelial detachment (PED, *arrowhead*). (C) After 140 days and six ranibizumab injections, VA improved to 20/50, and the FA image showed a marked reduction in leakage. (D) Corresponding OCT B-scan showed resolution of the subretinal fluid with a residual low-lying PED (*arrowhead*). (E) After 3 months

without an injection, VA decreased to 20/100, and the FA image showed a subtle increase in leakage. (F) Corresponding OCT B-scan showed recurrent cystic macular fluid. Ranibizumab was injected at this visit. (G) Three months after the ranibizumab injection, VA improved to 20/80, and the FA image showed a marked decrease in leakage. (H) Corresponding OCT B-scan showed only small intraretinal cysts, and no injection was given. (I) After 6 months without treatment, VA slowly decreased to 20/100 and the patient then complained of distortion. FA image showed increased leakage. (J) Corresponding B-scan showed increased macular fluid. (K) Over the next 12 months, the patient received two more ranibizumab injections, and the VA improved to 20/50. The FA image showed decreased leakage. (L) Corresponding OCT B-scan showed marked improvement in the macular fluid.

was now set for the convergence of an ideal imaging technique with an ideal treatment that would inhibit exudation and reduce the accumulation of fluid.

OCT IMAGING, THE RISE OF RANIBIZUMAB, AND PERSONALIZED TREATMENT REGIMENS FOR NVAMD

At the same time that the Stratus OCT was introduced into the clinic, the first VEGF inhibitor, previously known as rhuFabV2 and now known as ranibizumab (Lucentis; Genentech/Roche, South San Francisco, CA, USA), entered into a phase I clinical trial.¹⁵ In this phase I single-injection, dose-escalation, safety trial, OCT imaging was not available and FA imaging was used to characterize the neovascular lesions only at baseline. From this phase I trial, a maximum tolerated dose of 0.5 mg was identified based on dose-limiting inflammation that occurred at the 1.0-mg dose. While safety and VA outcomes were encouraging, it wasn't until the phase II study that OCT imaging was first used at the Bascom Palmer Eye Institute.

There were two phase II trials.^{16,17} One phase II trial studied the safety and tolerability of monthly repeated dosing of 0.3- or 0.5-mg ranibizumab through 6 months, and the second phase II trial explored a dose-escalation regimen in which the ranibizumab dose was sequentially increased from 0.3 to 2 mg and injected as frequently as every 2 weeks in eyes with nvAMD. While both phase II trials demonstrated VA improvement associated with ranibizumab therapy, OCT imaging unambiguously demonstrated that the improvement in VA was correlated with the resolution of macular fluid (Rosenfeld PJ, unpublished data, 2003). Moreover, in an extension program at the end of the phase II studies, retreatment with ranibizumab was permitted at the investigators' discretion once the fixed dosing was stopped. Investigators could base their retreatment on changes in VA, FA imaging, or OCT imaging. As these patients were being followed off treatment, OCT imaging identified the earliest recurrence of macular fluid in some patients even before FA imaging detected leakage and before VA was affected (Figs. 2–4). Some patients needed no additional treatment for up to 2 years while some patients

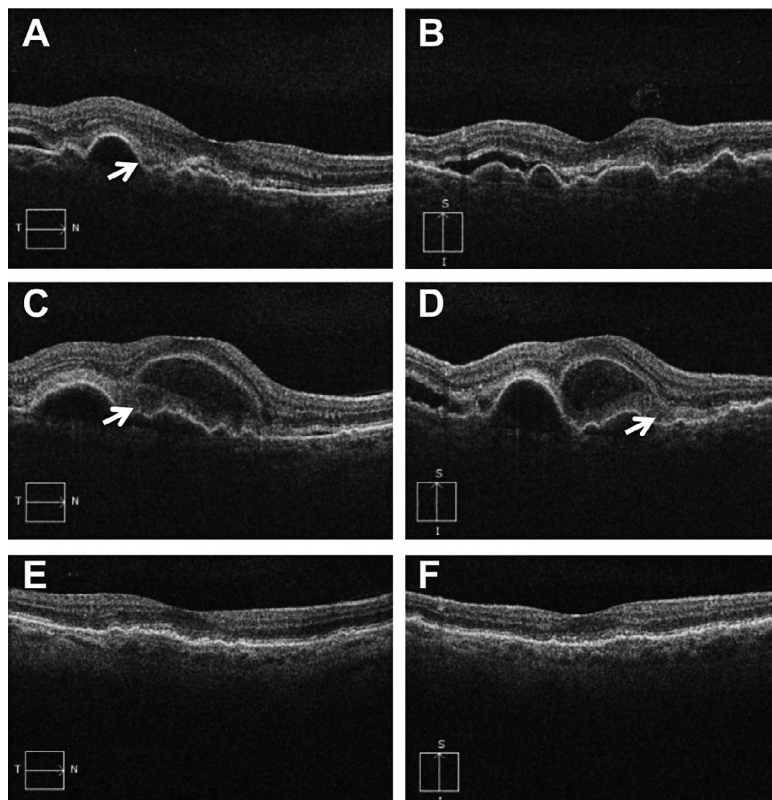


FIGURE 5. Macular neovascularization (MNV) with subretinal hyperreflective material/exudate (SRHM/SHRE). (A, C, E) Horizontal spectral-domain optical coherence tomography (SD-OCT) B-scans. (B, D, F) Vertical SD-OCT B-scans. (A, B) Patient with MNV secondary to age-related macular degeneration was seen in clinic and found to have macular fluid on SD-OCT imaging. Visual acuity (VA) was 20/30. The patient was asymptomatic. SRHM was evident on the horizontal B-scan (*arrow*). Patient was told to monitor her vision. (C, D) Two weeks later, the patient returned complaining of decreased vision. VA decreased to 20/50. SD-OCT imaging showed increased macular fluid and increased SRHM/SHRE (*arrows*). The first injection of a vascular endothelial growth factor (VEGF) inhibitor was given. (E, F) One month after the third of three monthly injections, VA improved to 20/30 with resolution of the macular fluid and SRHM/SHRE. A fourth anti-VEGF injection was given at this visit.

frequently developed recurrent macular fluid. This recurrent fluid first appeared as intraretinal cystic spaces or as subretinal fluid. The fluid that was initially detected by OCT imaging, if untreated, would then increase over time, resulting in subsequent vision loss. Thus, a small amount of fluid led to even more fluid and served as a harbinger of disease progression. As the macular fluid gradually reaccumulated in these subjects in the extension study, retreatment with ranibizumab once again resulted in resolution of the macular fluid; and in those patients with decreased VA associated with the recurrent fluid, VA improved once the fluid resolved. These were the first observations of how OCT imaging of macular fluid could serve as a surrogate marker for the presence of excess VEGF; how OCT imaging unambiguously demonstrated the profound effect of anti-VEGF therapy on macular fluid, and how OCT monitoring of macular fluid might serve as a strategy to determine the appropriate dosing interval used for the clinical management of nvAMD. These data were presented at the Retina Subspecialty Day before the American Academy of Ophthalmology meeting in 2004 and at other scientific meetings in an attempt to convince skeptical colleagues that OCT imaging rather than FA imaging could be used in the management of nvAMD patients. To convincingly demonstrate the benefits of OCT imaging for managing nvAMD patients, Genentech supported an investigator-sponsored trial known as the Prospective OCT Imaging of Patients with Neovascular AMD Treated with Intra-Ocular Ranibizumab (PrONTO) study.^{18,19}

In the 2-year PrONTO study, nvAMD patients received three monthly injections of 0.5-mg ranibizumab and continued to receive monthly injections as long as there was persistent macular fluid based on OCT imaging. However, once OCT imaging revealed a fluid-free macula, patients were followed monthly without injection until at least one of several retreatment criteria were met. These criteria included a VA loss of at least five letters with OCT evidence of fluid in the macula, an increase in OCT central retinal thickness of at least 100 μm , new macular hemorrhage, or a new area of classic MNV identified by FA imaging. The purpose of these criteria was to determine if OCT imaging was the most sensitive strategy for detecting the recurrence of macular fluid. After the first year of the study,¹⁸ it was obvious that OCT imaging was able to detect the need for retreatment long before leakage was detected on FA imaging, before vision loss occurred, and before hemorrhage appeared. At the time, retina specialists questioned why the OCT threshold for retreatment was set at an increased central retinal thickness measurement of 100 μm , and the reason for this threshold was to prove a point. We wanted to show our skeptical colleagues that when a small amount of fluid appeared and it was left untreated, even more fluid and vision loss would result. Once we proved our point, the threshold for retreatment was lowered in the second year of the study. A zero tolerance strategy was developed, and the protocol was amended to allow for retreatment once any fluid was detected after a dry macula was achieved.¹⁹ After 2 years, the VA outcomes would turn out to be very similar to the outcomes observed following monthly dosing with ranibizumab in the phase II and phase III trials, but unlike the situation with a fixed monthly dosing regimen, these patients in the PrONTO study required approximately half the number of injections.

The PrONTO study served as a model for subsequent studies investigating OCT-guided retreatment using a pro re nata (PRN) regimen for nvAMD.^{20,21} However, several of the smaller studies failed to appreciate two key features of the PrONTO study: the requirement for monthly exams and the amended requirement that retreatment be given if any macular

fluid was detected by OCT imaging once the macula was fluid-free. Moreover, retreatment was not decided by changes in VA, but only by changes in OCT imaging. While none of the phase III pivotal trials that led to Food and Drug Administration (FDA) approval for any of the anti-VEGF drugs used a pure OCT-guided PRN dosing regimen, monthly dosing versus OCT-guided PRN dosing has been studied in several large, well-controlled prospective clinical trials.²²⁻²⁷ The Comparison of Age-related Macular Degeneration Treatments Trials (CATT) and the Inhibition of VEGF in Age-related choroidal Neovascularization (IVAN) trial showed similar VA outcomes after 2 years when the same anti-VEGF drug was dosed monthly or discontinuously.²²⁻²⁵ However, the most convincing of these comparative trials is the pHase III, double-masked, multicenter, randomized, Active treatment-controlled study of the efficacy and safety of 0.5 mg and 2.0 mg Ranibizumab administered monthly or on an as-needed Basis (PRN) in patients with subfoveal neOvasculaR age-related macular degeneration (HARBOR) trial. The HARBOR trial used a PRN regimen similar to one employed in the PrONTO study.^{26,27} The two doses of ranibizumab were compared using a monthly versus an OCT-guided PRN dosing regimen in which patients received three monthly injections followed by monthly retreatment as long as there was persistent fluid. Once the macula became fluid-free, patients were followed monthly and retreated if any macular fluid was detected by OCT imaging. This study not only showed that monthly dosing and OCT-guided PRN dosing were equivalent, but did not even rely on a fundus exam when making the retreatment decision. The totality of the data suggest that a rigorously implemented OCT-guided PRN dosing strategy appears to be as beneficial as a fixed monthly dosing regimen, and as a result, this strategy has gained global acceptance. The greatest advantage of an OCT-guided PRN dosing strategy is that it improves and maintains VA while significantly decreasing the number of injections needed. However, monthly visits are still required.

Another dosing strategy for anti-VEGF drugs that has gained global acceptance is a regimen known as an OCT-guided treat-and-extend dosing.²⁸⁻³² This regimen also relies on OCT imaging to determine when the macula has become fluid-free, but then patients continue to be injected at each subsequent visit. However, once the macula is fluid-free, the patient is injected and the visit intervals are slowly extended to determine when and if macular fluid recurs. If OCT imaging detects the recurrence of fluid at a visit, then a treatment is given and the interval is shortened. Usually, visit intervals are lengthened or shortened by 2-week intervals depending on the status of macular fluid. While this OCT-guided strategy mandates that an injection be given even when the macula is dry, the advantage over other strategies is that it minimizes the overall number of visits. To date, only two prospective studies, known as the Lucentis Compared to Avastin Study (LUCAS)^{28,29} and Treat-and-Extend in AMD (Trex-AMD) study,³⁰ have used this treat-and-extend strategy, and the results appear to be similar to the outcomes from larger monthly dosing trials. Despite the limited prospective clinical trial data, clinicians and patients appear to prefer the treat-and-extend dosing regimen as a compromise between frequent monthly visits and monthly injections. On occasion, OCT monitoring of neovascular lesions has shown the importance of even more frequent injections with anti-VEGF drugs when monthly dosing proved unable to prevent the growth and worsening exudation of the neovascular lesions.³³ Thus, OCT monitoring allows clinicians to follow a “Goldilocks strategy” when managing patients, which is not too many injections, not too few injections, but just the right number of injections for that patient.

OCT IMAGING, THE DEMISE OF PEGAPTANIB, AND THE RISE OF BEVACIZUMAB

During the early to mid-2000s when OCT was being accepted into practices as an essential tool for monitoring patients with nvAMD, clinicians became empowered by their ability to monitor the real-time effectiveness of different therapeutic agents, whether it was verteporfin photodynamic therapy (PDT), intravitreal steroids, or anti-VEGF therapy. During this time, two anti-VEGF drugs for intraocular delivery were in clinical trials: ranibizumab (Lucentis, Genentech/Roche), an antibody fragment that binds all isoforms of VEGF-A³⁴; and pegaptanib sodium (Macugen; OSI/Eyetech, New York, NY, USA), an aptamer that binds VEGF₁₆₅ and larger isoforms.³⁵ As mentioned previously, OCT imaging was useful in demonstrating the anatomic improvements that followed ranibizumab therapy, and selected sites performed OCT imaging during the phase III ranibizumab trials for neovascular AMD known as the Minimally Classic/Occult Trial of the Anti-VEGF Antibody Ranibizumab in the Treatment of Neovascular AMD (MARINA)³⁶ and the Anti-VEGF Antibody for the Treatment of Predominantly Classic Choroidal Neovascularization in Age-Related Macular Degeneration (ANCHOR).^{37,38} In these trials, ranibizumab was dosed monthly for 2 years, and the OCT images that were obtained on a subset of subjects from these studies did confirm the drying effect of ranibizumab therapy.³⁹ In contrast, OCT imaging was never used in the pegaptanib trials, and after pegaptanib was approved in late 2004 and became commercially available in early 2005,⁴⁰ clinicians used OCT imaging on patients undergoing treatment with pegaptanib. Not surprisingly, the disappointing VA outcomes following pegaptanib therapy were found to correlate with persistent macular fluid following treatment, thus empowering clinicians to make an objective assessment of the drug's efficacy.⁴¹ As a result of this discrepancy between the OCT outcomes when using pegaptanib versus other anti-VEGF drugs, OCT imaging confirmed the need to suppress all VEGF isoforms to obtain the maximum drying effect from anti-VEGF therapy.

Optical coherence tomography imaging in the MARINA and ANCHOR trials with ranibizumab also revealed that the major cause of severe vision loss was not associated with persistent macular fluid or a scar; rather, severe vision loss was more commonly associated with a fluid-free macula.³⁹ For the first time, there was an appreciation that macular atrophy was a major cause of vision loss in treated eyes with nvAMD, rather than the more typical cause of severe vision loss prior to anti-VEGF therapy, which was the formation of a disciform scar.⁴² The formation of macular atrophy after anti-VEGF therapy was confirmed in the CATT and IVAN trials after 2 years, and in these trials, the monthly dosing groups had a higher incidence of macular atrophy compared with the discontinuous treatment groups.^{25,43,44} While this observation has raised questions about whether anti-VEGF therapy is responsible for the macular atrophy in some patients or whether the atrophy appears as a feature of normal disease progression and a consequence of suppressing neovascularization,⁴⁵⁻⁴⁷ it has become abundantly clear that OCT imaging is an invaluable tool for not only monitoring the presence of macular fluid, but also for monitoring the anatomic integrity of the outer retina and RPE as macular atrophy evolves (Fig. 6).⁴⁸⁻⁵²

During the clinical development of ranibizumab and pegaptanib, there were not only questions about the appropriate dose, dosing interval, and long-term effectiveness of these drugs; there was also uncertainty about the safety of repeated intravitreal injections and whether patients would tolerate intravitreal injections as a long-term drug delivery strategy. Due to these concerns about the safety and tolerability of repeated intravitreal injections, we investigated a third VEGF

inhibitor known as bevacizumab (Avastin; Genentech/Roche), a full-length humanized antibody against VEGF-A sharing a common clonal ancestry with an anti-VEGF murine monoclonal antibody that gave rise to ranibizumab; and like ranibizumab, bevacizumab was known to bind all the isoforms of VEGF-A.^{34,53} Since intravenous bevacizumab was being developed as a therapy for colon cancer, we decided to initiate a self-funded study using the same intravenous strategy for the treatment of nvAMD, and once again, OCT imaging proved pivotal in these bevacizumab studies.^{54,55} The Systemic Avastin in Neovascular AMD (SANA) study was initiated once bevacizumab was approved for colon cancer in February 2004. Twenty-four hours after the first systemic dose of bevacizumab in the first patient, OCT imaging unambiguously showed a profound benefit from intravenous bevacizumab. By May of 2005, OCT imaging had confirmed that systemic bevacizumab had a significant and sustained drying effect on the macula, and this drying effect was associated with VA improvement. However, during the course of the SANA study, the FDA added a black box warning describing the small but significant risk of thromboembolic events from the use of high-dose intravenous bevacizumab. While none of the patients in the SANA study experienced a thromboembolic event, they did experience mild hypertension that was easily controlled with oral medication. Due to these systemic safety concerns and the appreciation from the ranibizumab and pegaptanib studies that patients were able to tolerate repeated intravitreal injections, we decided to offer patients an off-label intravitreal dose of bevacizumab as salvage therapy. This dose was 500- to 1000-fold lower than the dose given intravenously, thus minimizing the systemic risk. Moreover, this intravitreal dose was capable of binding the same amount of intraocular VEGF as the intravitreal dose of ranibizumab. Once again, OCT imaging played a pivotal role in demonstrating the benefits of bevacizumab.^{56,57} When first used as salvage therapy in a nvAMD patient with a lesion that was enlarging despite treatments with PDT and pegaptanib, OCT imaging showed a remarkable improvement in the amount of macular fluid after intravitreal bevacizumab, and this improvement was associated with VA improvement. Since ranibizumab had not yet been approved, and would not be commercially available for another year in July 2006, the off-label use of intravitreal bevacizumab spread globally and became the treatment of choice in 2005 due to its perceived clinical efficacy, its widespread availability, its superiority over pegaptanib, and its low cost. In July 2006 when ranibizumab was commercially available for the treatment of nvAMD, clinicians had a choice between two drugs manufactured by Genentech that had a similar genetic lineage but differed with respect to size, affinity for VEGF, and cost. With the widespread use of OCT imaging, clinicians were now empowered to see for themselves that ranibizumab and bevacizumab were superior to pegaptanib and that ranibizumab appeared similar to bevacizumab with respect to its drying effect on the macula and improvement in VA following treatment. Without OCT imaging, it is unlikely that bevacizumab and OCT-guided retreatment would have gained worldwide popularity.

OCT IMAGING AND THE RISE OF AFLIBERCEPT FOR nvAMD

In 2011, a fourth drug, known as aflibercept (Eylea; Regeneron Pharmaceutical, Tarrytown, NY, USA), was FDA approved for the treatment of nvAMD. Aflibercept, a fusion protein combining the Fc portion of an antibody with VEGF-binding domains from VEGF receptors 1 and 2, has an even higher affinity for VEGF compared with ranibizumab and a molecular

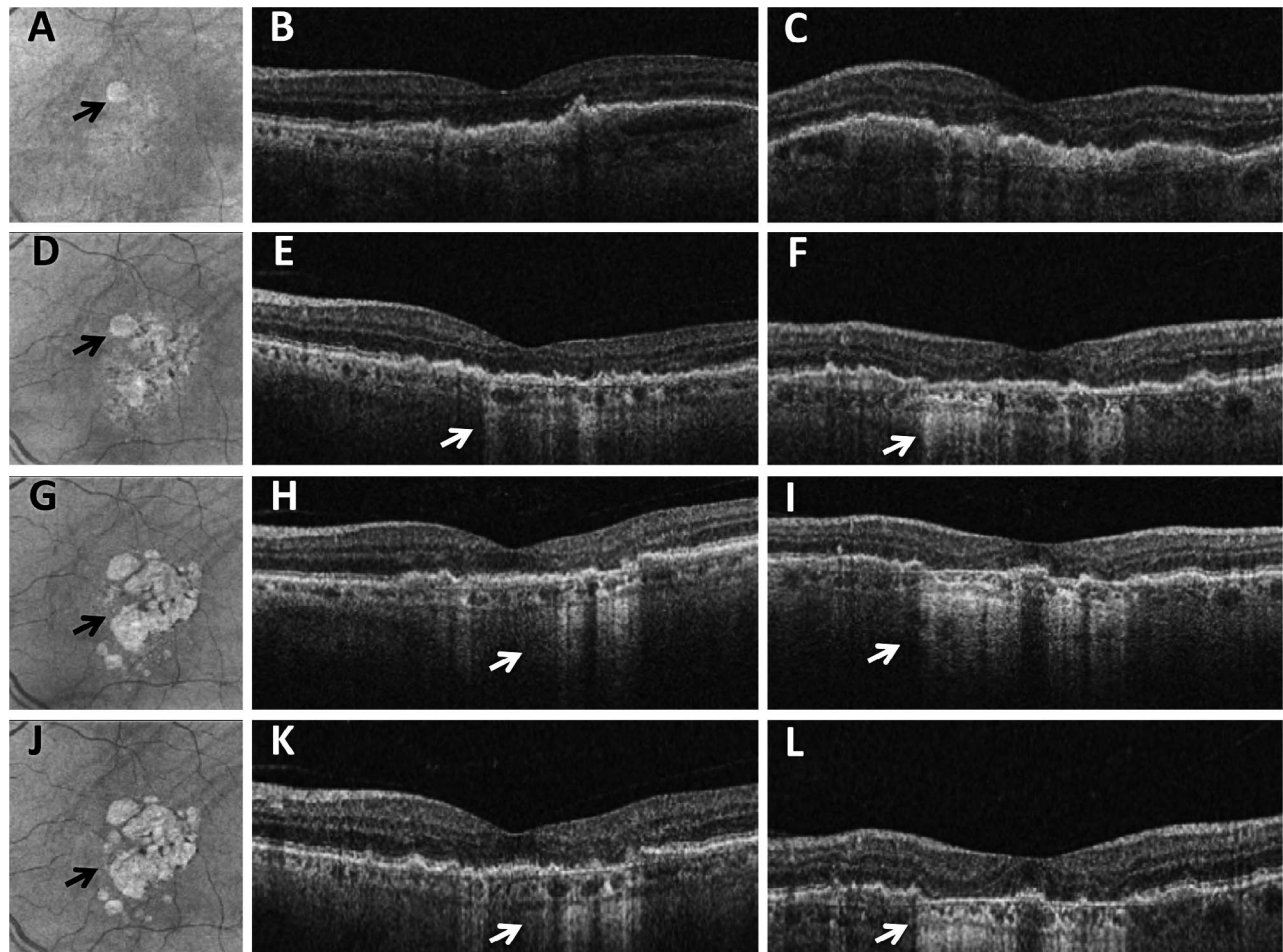


FIGURE 6. Macular atrophy developing after treatment with an inhibitor of vascular endothelial growth factor (VEGF). (A, D, G, J) Spectral-domain optical coherence tomography (SD-OCT) fundus images at sequential visits. (B, E, H, K) Horizontal SD-OCT B-scans. (C, F, I, L) Vertical SD-OCT B-scans. (A, B, C) One month after an anti-VEGF injection for a hemorrhagic fibrovascular retinal pigment epithelial detachment secondary to age-related macular degeneration. Visual acuity (VA) was 20/30. The OCT fundus image showed a small focus of atrophy as seen in (A) (*arrow*). The second anti-VEGF injection was given at this visit. (D, E, F) Two months after the second injection, VA was 20/25, but the area of atrophy was enlarging as shown in (D) (*arrow*) with evidence of hypertransmission shown on the horizontal (E) and vertical (F) B-scans. Disruption of the outer retinal layers can be appreciated in the areas with the hypertransmission defects. Another anti-VEGF injection was given. (G, H, I) A fourth injection was given 2 months after the third injection, and 2 months after the fourth injection, the patient returned with a VA of 20/25, but an even larger area of atrophy could be appreciated as shown in (G) (*arrow*) with evidence of even more hypertransmission as shown on the horizontal (H) and vertical (I) B-scans. The fifth anti-VEGF injection was given. (J, K, L) Three months after the fifth injection, the area of atrophy was slightly larger (J) (*arrow*) and prominent hypertransmission defects were appreciated as shown in (K) and (L). Disruption of the normal outer retinal structures was seen in the areas with the hypertransmission defect.

size in between those of bevacizumab and ranibizumab.⁵⁸ Moreover, it has the theoretical advantage of neutralizing placental growth factor, as well as all the isoforms of VEGF-A. In the phase III aflibercept trials known as the VEGF Trap-Eye: Investigation of Efficacy and Safety in Wet AMD (VIEW1 and VIEW2) trials, intravitreal injections of aflibercept every 2 months during the first year were shown to be equivalent to monthly injections of ranibizumab.⁵⁹ In the second year of the trials, subjects received a mandatory injection every 3 months, with OCT imaging performed during the intervening monthly visits.⁶⁰ If there was evidence of recurrent or persistent macular fluid using OCT imaging, then injections could be administered during these intervening visits. This modified-PRN regimen resulted in similar VA and OCT outcomes when aflibercept and ranibizumab were compared, but subjects receiving aflibercept required slightly fewer injections using OCT-guided therapy. Once again, OCT imaging proved valuable for detecting macular fluid and determining the need for retreatment in this prospective clinical trial setting. Since its

approval, aflibercept has gained popularity as an anti-VEGF drug with the ability to increase the retreatment interval while maintaining improved VA and a fluid-free macula in nvAMD patients. The perception that aflibercept provides increased durability arises not only from the dosing interval of every 2 months used in the phase III studies, but also from numerous research papers showing that when patients are switched from ranibizumab or bevacizumab to aflibercept, there is a tendency for investigators to report improved macular anatomy and extended fluid-free intervals based on OCT imaging.⁶¹⁻⁶⁴

A fifth drug, known as conbercept (Lumatin; Chengdu Kanghong Pharmaceutical Group, Chengdu, China), gained China FDA approval in 2013. Conbercept, which is a fusion protein similar to aflibercept and combines the binding domains of VEGF receptors 1 and 2 with an Fc portion of an antibody, has a molecular weight comparable to that of bevacizumab, but it is currently used only in China.⁶⁵⁻⁶⁷ Once again, OCT imaging correlated with the VA benefits observed during the conbercept clinical trials.

THE EVOLUTION OF OCT IMAGING FOR THE MANAGEMENT OF nvAMD

Now that TD-OCT has been surpassed by SD-OCT in the clinics, the next step in the commercial evolution of OCT imaging for the management of nvAMD is the development of OCT angiography (OCTA).⁶⁸⁻⁷² Optical coherence tomography angiography utilizes novel scanning patterns and algorithms to image blood flow in the retina and choroid without the use of exogenous dyes. Not only can blood flow be imaged, but also the scans provide detailed structural information comparable to or better than the images currently available from commercial SD-OCT instruments. Different OCTA platforms are being developed that use different scanning patterns and algorithms, but they can be broadly divided into SD-OCT and swept-source OCT (SS-OCT) instruments. Each platform will have certain advantages and disadvantages, but whether OCTA has advantages over conventional OCT imaging in the management of nvAMD patients remains to be determined. The ability to noninvasively visualize the appearance and growth of MNV should augment the routine OCT strategy of monitoring for the presence or absence of macular fluid when deciding to initiate anti-VEGF therapy and when to re-treat. Since exudation is the metric by which we currently measure VEGF activity and exudation can arise from both the neovascularization and the normal vasculature, there should be certain advantages of using OCTA to directly monitor changes in the neovascular lesion rather than just monitoring the level of exudation. Even if OCTA imaging does not influence our decision on when to treat, it will surely add to our understanding of disease onset, progression, and response to treatment. For example, OCTA can visualize the presence of type 1 MNV in eyes that were diagnosed with dry, intermediate AMD.⁷⁰ The presence of nonexudative neovascular lesions raises new questions about whether we can predict when exudation will arise and if there is a role for anti-VEGF therapy even before exudation occurs. If OCTA can now replace FA and ICGA imaging for most MNV, then OCTA imaging will provide all the structural and flow information needed for the diagnosis and management of MNV.

SUMMARY OF OCT IMAGING AND ANTIANGIOGENIC THERAPIES

With respect to their development, OCT imaging and antiangiogenic therapies have been inextricably linked. If OCT imaging had not been available when anti-VEGF therapies were developed, then clinicians and patients would have been chained to fixed-dosing regimens without the ability to easily and noninvasively assess whether the exudation from the neovascularization had been adequately controlled. In the era of PDT before anti-VEGF therapy, patients underwent invasive, time-consuming FA imaging every 3 months to determine whether leakage was present and treatment was needed. When intravitreal pegaptanib was approved, injections were given per protocol every 6 weeks, but when patients lost vision and additional OCT imaging was performed, the presence of persistent or worsening macular fluid was confirmed. In the era of OCT imaging and pan-VEGF blockade, OCT imaging unambiguously confirmed the effectiveness of anti-VEGF therapy in resolving macular fluid. Optical coherence tomography imaging empowered clinicians to personalize therapy by evaluating different drugs and dosing regimens. Clinicians were able to customize therapy to either minimize the number of injections or minimize the number of visits. Without the confidence that came from OCT imaging and the ability to demonstrate the beneficial effect of anti-VEGF therapy within

24 hours of treatment,¹⁸ it is unlikely that intravenous and then intravitreal bevacizumab therapy for the treatment of exudative eye diseases would have been developed in 2005, and it is unlikely that the global ophthalmologic community would have been convinced to rapidly adopt intravitreal bevacizumab as a viable treatment strategy. While significant cost savings have resulted from the use of OCT compared with FA imaging,⁷³ greater cost savings have resulted from the use of OCT-guided retreatment to avoid monthly dosing, and even greater cost savings have resulted from the use of off-label bevacizumab in lieu of the more expensive drugs. In the United States alone, over the past 10 years, the combined Medicare cost savings from the use of OCT⁷³ and bevacizumab⁷⁴ have exceeded \$20 billion when conservatively extrapolated from published utilization data for all forms of exudative eye diseases.

Globally, four intravitreal drugs dominate the market for anti-VEGF therapy in neovascular AMD, diabetic macular edema, and retinal vein occlusions: bevacizumab, ranibizumab, aflibercept, and conbercept. Despite differences in molecular size, affinity for VEGF, and intravitreal half-life, all four drugs have shown efficacy with improved VA and resolution of macular fluid. The most likely explanation for the effectiveness of these four drugs is that they bind all the biological isoforms of VEGF-A whereas pegaptanib inhibited only VEGF₁₆₅ and larger isoforms. Thus, this was the first example of how OCT imaging was able to distinguish between different therapeutic targets.

As new therapies and drug delivery strategies are developed to treat exudative eye diseases, OCT will once again play an important role. For example, anti-VEGF drugs are being delivered through implantable devices, as topical therapy, and as oral medication. Treatments that combine intravitreal anti-VEGF therapy along with inhibitors of platelet-derived growth factor (PDGF), angiopoietin 2, and tissue factor are being investigated, and topical squalamine is being combined with anti-VEGF therapy in clinical trials as well. Optical coherence tomography continues to be an integral part of all these trials, but the phase III trials for the PDGF inhibitor known as E10030 (Fovista; Ophthotech Corp., Princeton, NJ, USA) have incorporated a novel inclusion requirement for their treatment-naïve subjects with nvAMD; that requirement is the presence of SHRM (ClinicalTrials.gov Identifier: NCT01944839, NCT01940900, NCT01940887).

While improvement of VA remains the ultimate outcome that will determine the success or failure of any new treatment, there's so much more to the macula than VA, which measures only central foveal function. Unlike dye-based angiography, OCT imaging can identify macular abnormalities involving the photoreceptors, the RPE, and the choroid that can help explain visual function changes such as reduced reading speed, reduced microperimetric thresholds, and delayed dark adaptation.⁷⁵ While OCT is clearly the gold standard imaging strategy for predicting the success of any antiangiogenic treatment, it is also a valuable strategy for studying a wide range of anatomic changes that correlate with reduced visual function and disease progression. In summary, OCT is held in such high regard that clinicians will never be convinced of a treatment's efficacy until OCT imaging demonstrates an unambiguous anatomic benefit.

Acknowledgments

I thank Carmen Puliafito, MD, MBA, for his support and encouragement during the early to mid-2000s when both clinical OCT imaging and anti-VEGF therapies were being developed for clinical use. Without early access to OCT technology and his permission to pursue research into bevacizumab therapy for

exudative eye diseases, the current treatment landscape might have evolved very differently. I also thank my clinical research fellows (Stephan Michels, MD, MBA, Anne Fung, MD, Andrew Moshfeghi, MD, MBA, and Geeta Lalwani, MD) and my clinical coordinators (Maria Esquiabro, Belen Rodriguez, and Cristina Lage-Rodriguez) for their exceptional talents and assistance in managing patients and conducting these successful anti-VEGF clinical trials.

Supported by a grant from Carl Zeiss Meditec, Inc. (Dublin, CA, USA), the Macula Vision Research Foundation, a National Eye Institute Center Core Grant (P30EY014801), an unrestricted grant from Research to Prevent Blindness, and the Emma Clyde Hodge Memorial Foundation.

Disclosure: **P.J. Rosenfeld**, Achillion Pharmaceuticals (C), Acucela (C, F), Apellis (F, D), Boehringer-Ingelheim (C), Carl Zeiss Meditec, Inc. (F, R), Cell Cure Neurosciences (C), Chengdu Kanghong Biotech (C), CoDa Therapeutics (C), Digisight (D), Genentech (C, F), GlaxoSmithKline (F), Healios K.K. (C), F Hoffmann-La Roche Ltd. (C), MacRegen, Inc. (C), NGM Biopharmaceuticals (C), Neurotech (F), Ocata Therapeutics (C, F), OcuDyne (C), Regeneration (C), Stealth BioTherapeutics (C), Tyrogenex (C, F), Vision Medicines (C)

References

- Gass JDM. *Stereoscopic Atlas of Macular Disease. Diagnosis and Treatment*. 4th ed. St. Louis: Mosby-Year Book, Inc.; 1997: 130-147.
- Puliafito CA, Schuman JS, Hee MR, Fujimoto JG. *Optical Coherence Tomography of Ocular Diseases*. 2nd ed. Thorofare, NJ: Slack Inc., 2004.
- Gabriele ML, Wollstein G, Ishikawa H, et al. Optical coherence tomography: history, current status, and laboratory work. *Invest Ophthalmol Vis Sci*. 2011;52:2425-2436.
- Staurengi G, Sadda S, Chakravarthy U, Spaide RF; International Nomenclature for Optical Coherence Tomography Panel. Proposed lexicon for anatomic landmarks in normal posterior segment spectral-domain optical coherence tomography: the IN*OCT consensus. *Ophthalmology*. 2014;121: 1572-1578.
- Ting TD, Oh M, Cox TA, Meyer CH, Toth CA. Decreased visual acuity associated with cystoid macular edema in neovascular age-related macular degeneration. *Arch Ophthalmol*. 2002; 120:731-737.
- Tolentino MJ, Miller JW, Gragoudas ES, Chatzistefanou K, Ferrara N, Adamis AP. Vascular endothelial growth factor is sufficient to produce iris neovascularization and neovascular glaucoma in a nonhuman primate. *Arch Ophthalmol*. 1996; 114:964-970.
- Tolentino MJ, Miller JW, Gragoudas ES, et al. Intravitreal injections of vascular endothelial growth factor produce retinal ischemia and microangiopathy in an adult primate. *Ophthalmology*. 1996;103:1820-1828.
- Nagiel A, Sarraf D, Sadda SR, et al. Type 3 neovascularization: evolution, association with pigment epithelial detachment, and treatment response as revealed by spectral domain optical coherence tomography. *Retina*. 2015;35:638-647.
- Jung JJ, Chen CY, Mrejen S, et al. The incidence of neovascular subtypes in newly diagnosed neovascular age-related macular degeneration. *Am J Ophthalmol*. 2014;158:769-779, e762.
- Shah VP, Shah SA, Mrejen S, Freund KB. Subretinal hyperreflective exudation associated with neovascular age-related macular degeneration. *Retina*. 2014;34:1281-1288.
- Willoughby AS, Ying GS, Toth CA, et al. Subretinal hyperreflective material in the comparison of age-related macular degeneration treatments trials. *Ophthalmology*. 2015;122: 1846-1853, e1845.
- Charafeddin W, Nittala MG, Oregon A, Sadda SR. Relationship between subretinal hyperreflective material reflectivity and volume in patients with neovascular age-related macular degeneration following anti-vascular endothelial growth factor treatment. *Ophthalmic Surg Lasers Imaging Retina*. 2015;46: 523-530.
- Sato T, Iida T, Hagimura N, Kishi S. Correlation of optical coherence tomography with angiography in retinal pigment epithelial detachment associated with age-related macular degeneration. *Retina*. 2004;24:910-914.
- Chang LK, Sarraf D. Tears of the retinal pigment epithelium: an old problem in a new era. *Retina*. 2007;27:523-534.
- Rosenfeld PJ, Schwartz SD, Blumenkranz MS, et al. Maximum tolerated dose of a humanized anti-vascular endothelial growth factor antibody fragment for treating neovascular age-related macular degeneration. *Ophthalmology*. 2005;112:1048-1053.
- Heier JS, Antoszyk AN, Pavan PR, et al. Ranibizumab for treatment of neovascular age-related macular degeneration: a phase I/II multicenter, controlled, multidose study. *Ophthalmology*. 2006;113:633, e631-e634.
- Rosenfeld PJ, Heier JS, Hantsbarger G, Shams N. Tolerability and efficacy of multiple escalating doses of ranibizumab (Lucentis) for neovascular age-related macular degeneration. *Ophthalmology*. 2006;113:623, e621.
- Fung AE, Lalwani GA, Rosenfeld PJ, et al. An optical coherence tomography-guided, variable dosing regimen with intravitreal ranibizumab (Lucentis) for neovascular age-related macular degeneration. *Am J Ophthalmol*. 2007;143:566-583.
- Lalwani GA, Rosenfeld PJ, Fung AE, et al. A variable-dosing regimen with intravitreal ranibizumab for neovascular age-related macular degeneration: year 2 of the PrONTO Study. *Am J Ophthalmol*. 2009;148:43-58, e41.
- Pron G. Optical coherence tomography monitoring strategies for A-VEGF-treated age-related macular degeneration: an evidence-based analysis. *Ont Health Technol Assess Ser*. 2014;14:1-64.
- Schmucker CM, Rucker G, Sommer H, et al. Treatment as required versus regular monthly treatment in the management of neovascular age-related macular degeneration: a systematic review and meta-analysis. *PLoS One*. 2015;10:e0137866.
- CATT Research Group, Martin DF, Maguire MG, et al. Ranibizumab and bevacizumab for neovascular age-related macular degeneration. *N Engl J Med*. 2011;364:1897-1908.
- Martin DF, Maguire MG, Fine SL, et al; and the Comparison of Age-related Macular Degeneration Treatments Trials Research Group. Ranibizumab and bevacizumab for treatment of neovascular age-related macular degeneration: two-year results. *Ophthalmology*. 2012;119:1388-1398.
- Chakravarthy U, Harding SP, Rogers CA, et al. Ranibizumab versus bevacizumab to treat neovascular age-related macular degeneration: one-year findings from the IVAN randomized trial. *Ophthalmology*. 2012;119:1399-1411.
- Chakravarthy U, Harding SP, Rogers CA, et al. Alternative treatments to inhibit VEGF in age-related choroidal neovascularisation: 2-year findings of the IVAN randomised controlled trial. *Lancet*. 2013;382:1258-1267.
- Busbee BG, Ho AC, Brown DM, et al. Twelve-month efficacy and safety of 0.5 mg or 2.0 mg ranibizumab in patients with subfoveal neovascular age-related macular degeneration. *Ophthalmology*. 2013;120:1046-1056.
- Ho AC, Busbee BG, Regillo CD, et al. Twenty-four-month efficacy and safety of 0.5 mg or 2.0 mg ranibizumab in patients with subfoveal neovascular age-related macular degeneration. *Ophthalmology*. 2014;121:2181-2192.
- Berg K, Pedersen TR, Sandvik L, Bragadottir R. Comparison of ranibizumab and bevacizumab for neovascular age-related macular degeneration according to LUCAS treat-and-extend protocol. *Ophthalmology*. 2015;122:146-152.
- Berg K, Hadzalic E, Gjertsen I, et al. Ranibizumab or Bevacizumab for Neovascular Age-Related Macular Degenera-

- tion According to the Lucentis Compared to Avastin Study Treat-and-Extend Protocol: Two-Year Results. *Ophthalmology*. 2016;123:51-59.
30. Wyckoff CC, Croft DE, Brown DM, et al. Prospective Trial of Treat-and-Extend versus Monthly Dosing for Neovascular Age-Related Macular Degeneration: TREX-AMD 1-Year Results. *Ophthalmology*. 2016;100:914-917.
 31. Chin-Yee D, Eck T, Fowler S, Hardi A, Apte RS. A systematic review of as needed versus treat and extend ranibizumab or bevacizumab treatment regimens for neovascular age-related macular degeneration. *Br J Ophthalmol*. 2015;.
 32. Rayess N, Houston SK III, Gupta OP, Ho AC, Regillo CD. Treatment outcomes after 3 years in neovascular age-related macular degeneration using a treat-and-extend regimen. *Am J Ophthalmol*. 2015;159:3-8, e1.
 33. Stewart MW, Rosenfeld PJ, Penha FM, et al. Pharmacokinetic rationale for dosing every 2 weeks versus 4 weeks with intravitreal ranibizumab, bevacizumab, and aflibercept (vascular endothelial growth factor trap-eye). *Retina*. 2012;32:434-457.
 34. Chen Y, Wiesmann C, Fuh G, et al. Selection and analysis of an optimized anti-VEGF antibody: crystal structure of an affinity-matured Fab in complex with antigen. *J Mol Biol*. 1999;293:865-881.
 35. Ng EW, Shima DT, Calias P, Cunningham ET Jr, Guyer DR, Adamis AP. Pegaptanib, a targeted anti-VEGF aptamer for ocular vascular disease. *Nat Rev Drug Discov*. 2006;5:123-132.
 36. Rosenfeld PJ, Brown DM, Heier JS, et al. Ranibizumab for neovascular age-related macular degeneration. *N Engl J Med*. 2006;355:1419-1431.
 37. Brown DM, Kaiser PK, Michels M, et al. Ranibizumab versus verteporfin for neovascular age-related macular degeneration. *N Engl J Med*. 2006;355:1432-1444.
 38. Brown DM, Michels M, Kaiser PK, et al. Ranibizumab versus verteporfin photodynamic therapy for neovascular age-related macular degeneration: two-year results of the ANCHOR study. *Ophthalmology*. 2009;116:57-65, e55.
 39. Rosenfeld PJ, Shapiro H, Tuomi L, Webster M, Elledge J, Blodi B. Characteristics of patients losing vision after 2 years of monthly dosing in the phase III ranibizumab clinical trials. *Ophthalmology*. 2011;118:523-530.
 40. Gragoudas ES, Adamis AP, Cunningham ET Jr, Feinsod M, Guyer DR. Pegaptanib for neovascular age-related macular degeneration. *N Engl J Med*. 2004;351:2805-2816.
 41. Emerson GG, Flaxel CJ, Lauer AK, et al. Optical coherence tomography findings during pegaptanib therapy for neovascular age-related macular degeneration. *Retina*. 2007;27:724-729.
 42. Hogg R, Curry E, Muldrew A, et al. Identification of lesion components that influence visual function in age related macular degeneration. *Br J Ophthalmol*. 2003;87:609-614.
 43. Grunwald JE, Daniel E, Huang J, et al. Risk of geographic atrophy in the comparison of age-related macular degeneration treatments trials. *Ophthalmology*. 2014;121:150-161.
 44. Grunwald JE, Pistilli M, Ying GS, et al. Growth of geographic atrophy in the comparison of age-related macular degeneration treatments trials. *Ophthalmology*. 2015;122:809-816.
 45. Channa R, Sophie R, Bagheri S, et al. Regression of choroidal neovascularization results in macular atrophy in anti-vascular endothelial growth factor-treated eyes. *Am J Ophthalmol*. 2015;159:9-19, e11-e12.
 46. Tanaka E, Chaikitmongkol V, Bressler SB, Bressler NM. Vision-threatening lesions developing with longer-term follow-up after treatment of neovascular age-related macular degeneration. *Ophthalmology*. 2015;122:153-161.
 47. Xu L, Mrejen S, Jung JJ, et al. Geographic atrophy in patients receiving anti-vascular endothelial growth factor for neovascular age-related macular degeneration. *Retina*. 2015;35:176-186.
 48. Hassenstein A, Ruhl R, Richard G. Optical coherence tomography in geographic atrophy—a clinicopathologic correlation [in German]. *Klin Monbl Augenbeilkd*. 2001;218:503-509.
 49. Lujan BJ, Rosenfeld PJ, Gregori G, et al. Spectral domain optical coherence tomographic imaging of geographic atrophy. *Ophthalmic Surg Lasers Imaging*. 2009;40:96-101.
 50. Bearely S, Chau FY, Koreishi A, Stinnett SS, Izatt JA, Toth CA. Spectral domain optical coherence tomography imaging of geographic atrophy margins. *Ophthalmology*. 2009;116:1762-1769.
 51. Yehoshua Z, Rosenfeld PJ, Gregori G, et al. Progression of geographic atrophy in age-related macular degeneration imaged with spectral domain optical coherence tomography. *Ophthalmology*. 2011;118:679-686.
 52. Yehoshua Z, Garcia Filho CA, Penha FM, et al. Comparison of geographic atrophy measurements from the OCT fundus image and the sub-RPE slab image. *Ophthalmic Surg Lasers Imaging Retina*. 2013;44:127-132.
 53. Ferrara N, Hillan KJ, Novotny W. Bevacizumab (Avastin), a humanized anti-VEGF monoclonal antibody for cancer therapy. *Biochem Biophys Res Commun*. 2005;333:328-335.
 54. Michels S, Rosenfeld PJ, Puliafito CA, Marcus EN, Venkatraman AS. Systemic bevacizumab (Avastin) therapy for neovascular age-related macular degeneration twelve-week results of an uncontrolled open-label clinical study. *Ophthalmology*. 2005;112:1035-1047.
 55. Moshfeghi AA, Rosenfeld PJ, Puliafito CA, et al. Systemic bevacizumab (Avastin) therapy for neovascular age-related macular degeneration: twenty-four-week results of an uncontrolled open-label clinical study. *Ophthalmology*. 2006;113:2002, e2001-e2012.
 56. Rosenfeld PJ, Moshfeghi AA, Puliafito CA. Optical coherence tomography findings after an intravitreal injection of bevacizumab (Avastin) for neovascular age-related macular degeneration. *Ophthalmic Surg Lasers Imaging*. 2005;36:331-335.
 57. Rosenfeld PJ, Fung AE, Puliafito CA. Optical coherence tomography findings after an intravitreal injection of bevacizumab (Avastin) for macular edema from central retinal vein occlusion. *Ophthalmic Surg Lasers Imaging*. 2005;36:336-339.
 58. Holash J, Davis S, Papadopoulos N, et al. VEGF-Trap: a VEGF blocker with potent antitumor effects. *Proc Natl Acad Sci U S A*. 2002;99:11393-11398.
 59. Heier JS, Brown DM, Chong V, et al. Intravitreal aflibercept (VEGF trap-eye) in wet age-related macular degeneration. *Ophthalmology*. 2012;119:2537-2548.
 60. Schmidt-Erfurth U, Kaiser PK, Korobelnik JF, et al. Intravitreal aflibercept injection for neovascular age-related macular degeneration: ninety-six-week results of the VIEW studies. *Ophthalmology*. 2014;121:193-201.
 61. Thorell MR, Nunes RP, Chen GW, et al. Response to aflibercept after frequent re-treatment with bevacizumab or ranibizumab in eyes with neovascular AMD. *Ophthalmic Surg Lasers Imaging Retina*. 2014;45:526-533.
 62. Seguin-Greenstein S, Lightman S, Tomkins-Netzer OA. Meta-analysis of studies evaluating visual and anatomical outcomes in patients with treatment resistant neovascular age-related macular degeneration following switching to treatment with aflibercept. *J Ophthalmol*. 2016;2016:4095852.
 63. Pfau M, Fassnacht-Riederle HM, Freiberg FJ, et al. Switching therapy from ranibizumab and/or bevacizumab to aflibercept in neovascular age-related macular degeneration (AMD): one-year results [in German] [published ahead of print April 28, 2016]. *Klin Monbl Augenbeilkd*. doi:10.1055/s-0042-101348.
 64. Barthelmes D, Campain A, Nguyen P, et al. Effects of switching from ranibizumab to aflibercept in eyes with

- exudative age-related macular degeneration [published ahead of print March 18, 2016]. *Br J Ophthalmol*. doi:10.1136/bjophthalmol-2015-308090.
65. Zhang M, Zhang J, Yan M, et al. A phase 1 study of KH902, a vascular endothelial growth factor receptor decoy, for exudative age-related macular degeneration. *Ophthalmology*. 2011;118:672-678.
 66. Li X, Xu G, Wang Y, et al. Safety and efficacy of conbercept in neovascular age-related macular degeneration: results from a 12-month randomized phase 2 study: AURORA study. *Ophthalmology*. 2014;121:1740-1747.
 67. Nguyen TT, Guymer R. Conbercept (KH-902) for the treatment of neovascular age-related macular degeneration. *Exp Rev Clin Pharmacol*. 2015;8:541-548.
 68. Waheed NK, Moulton EM, Fujimoto JG, Rosenfeld PJ. Optical coherence tomography angiography of dry age-related macular degeneration. *Dev Ophthalmol*. 2016;56:91-100.
 69. Souied EH, El Ameen A, Semoun O, Miere A, Querques G, Cohen SY. Optical coherence tomography angiography of type 2 neovascularization in age-related macular degeneration. *Dev Ophthalmol*. 2016;56:52-56.
 70. Roisman L, Zhang Q, Wang RK, et al. Optical coherence tomography angiography of asymptomatic neovascularization in intermediate age-related macular degeneration. *Ophthalmology*. 2016;123:1309-1319.
 71. Querques G, Miere A, Souied EH. Optical coherence tomography angiography features of type 3 neovascularization in age-related macular degeneration. *Dev Ophthalmol*. 2016;56:57-61.
 72. Lafe NA, Phasukkijwatana N, Sarraf D. Optical coherence tomography angiography of type 1 neovascularization in age-related macular degeneration. *Dev Ophthalmol*. 2016;56:45-51.
 73. Schneider EW, Mruthyunjaya P, Talwar N, Harris Nwanyanwu K, Nan B, Stein JD. Reduced fluorescein angiography and fundus photography use in the management of neovascular macular degeneration and macular edema during the past decade. *Invest Ophthalmol Vis Sci*. 2014;55:542-549.
 74. Erie JC, Barkmeier AJ, Hodge DO, Mahr MA. High variation of intravitreal injection rates and Medicare anti-vascular endothelial growth factor payments per injection in the United States. *Ophthalmology*. 2016;123:1257-1262.
 75. Schaal KB, Rosenfeld PJ, Gregori G, Yehoshua Z, Feuer WJ. Anatomic clinical trial endpoints for nonexudative age-related macular degeneration. *Ophthalmology*. 2016;123:1060-1079.