



## Brief Report

## Adrenocorticotrophic hormone analogue as novel treatment regimen in ocular cicatricial pemphigoid

Yael Sharon<sup>a,\*</sup>, David S. Chu<sup>a,b</sup><sup>a</sup> Metropolitan Eye Research and Surgery Institute, Palisades Park, NJ, USA<sup>b</sup> Institute of Ophthalmology and Visual Science, New Jersey Medical School, Rutgers University, Newark, NJ, USA

## ARTICLE INFO

## Keywords:

Adrenocorticotrophic hormone  
Ocular cicatricial pemphigoid  
Clinical outcome

## ABSTRACT

**Purpose:** To report the clinical outcome of a patient with ocular cicatricial pemphigoid, treated with adrenocorticotrophic hormone gel.

**Observations:** A 75-year-old female with a biopsy proven ocular cicatricial pemphigoid (OCP) presented with bilateral conjunctival inflammation, fornix shortening, subepithelial fibrosis and corneal scarring. The patient was previously treated with topical steroids, topical cyclosporine and lubricating drops, and had undergone several amniotic membrane transplants due to recurrent corneal erosions. Once OCP diagnosis was established, the patient was started on oral corticosteroids (60 mg daily). In order to wean the patient off from systemic steroids, other immunomodulatory agents had been tried, including mycophenolate mofetil (1000 mg twice daily) and methotrexate (up to 25 mg weekly). However, none of these agents adequately controlled the ocular surface inflammation, and the patient experienced bilateral progressive cicatrization and corneal decompensation, as well as the development of side effects from the systemic corticosteroids, methotrexate and mycophenolate mofetil therapies. Treatment with twice weekly subcutaneous adrenocorticotrophic hormone (ACTH) gel was initiated, along with tapering of systemic corticosteroids. During the 19 months treatment period, the patient demonstrated significant improvement in the ocular surface inflammation, visual acuity was stable and no significant adverse effects were observed. Systemic corticosteroids dosage was successfully reduced from 10 mg/day to none at last follow up.

**Conclusions and importance:** ACTH gel has shown to be an effective and safe treatment option for chronic, refractory and progressive ocular inflammatory disease. To the best of our knowledge, this is the first case report of a patient with OCP, treated successfully with ACTH gel. This case report may encourage ophthalmologists to employ ACTH gel in the management of OCP.

## 1. Introduction

Ocular cicatricial pemphigoid (OCP) is a specific entity in a group of chronic inflammatory mucocutaneous blistering conditions, called mucous membrane pemphigoid.<sup>1</sup> The disease is characterized by scarring and shrinkage of the conjunctiva as well as in extraocular mucous membranes, such as the oral mucosa, esophagus, larynx, and skin.<sup>1,2</sup> The disease commonly affects females with an average age of onset of 65 years.<sup>3</sup> OCP is diagnosed by linear antibody and complement deposition at the epithelial basement membrane of the involved mucosa. The earliest clinical finding is a chronic, recurrent, papillary conjunctivitis. Recurrent attacks of conjunctival inflammation can lead to destruction of goblet cells, lacrimal gland ductule obstruction, entropion, trichiasis and corneal abrasions, vascularization and ulceration. Progressive cicatrization is common, as well as remissions and

exacerbations periods with therapy.

Treatment for the majority of OCP patients utilizes systemic immunomodulatory therapies in order to prevent cicatrization. Systemic treatments include corticosteroids, and steroid-sparing agents, such as cyclophosphamide, mycophenolate mofetil, azathioprine, methotrexate (MTX), and diaminodiphenylsulfone (dapson).<sup>4–7</sup> Usually, monotherapy with corticosteroids, along with its adverse events, is not sufficient to produce long-term remission, nor able to achieve an adequate level of sustained immunosuppression in OCP patients. Furthermore, the later the stage of disease upon initiation of therapy, the more likely it will progress and not respond to therapy. However, the use of steroid-sparing medications also carries potential risks and side effects. Cyclophosphamide can cause leukopenia, anemia, bone marrow suppression, and bladder carcinoma.<sup>2</sup> Common side effects of mycophenolate mofetil are nausea, diarrhea, abdominal pain, fever and anemia. MTX

\* Corresponding author.

E-mail address: [yael@mersieye.com](mailto:yael@mersieye.com) (Y. Sharon).

may cause hepatotoxicity, pneumonitis, pulmonary fibrosis, pancytopenia, and malignancy. In some patients with reluctant disease, immunomodulatory treatments, such as intravenous immunoglobulin (IVIg) and rituximab, have shown some success.<sup>8,9</sup>

Adrenocorticotropic hormone (ACTH) is a member of a group of molecules called melanocortins (MCs), derived from the precursor proopiomelanocortin (POMC) and endogenously produced in the hypothalamic-pituitary pathway. ACTH acts primarily to stimulate and regulate steroids production. ACTH has recently been shown to have anti-inflammatory effects beyond endogenous steroid production.<sup>10,11</sup>

ACTH gel was approved by the United States Food and Drug Administration (FDA) in 1952 for a variety of autoimmune and inflammatory conditions. ACTH gel is indicated for severe acute and chronic allergic and inflammatory ocular processes including keratitis, iridocyclitis, diffuse posterior uveitis and choroiditis, optic neuritis, chorioretinitis and anterior segment inflammation.<sup>12</sup> It also has shown efficacy in various systemic inflammatory diseases including systemic lupus erythematosus,<sup>13</sup> multiple sclerosis,<sup>14</sup> nephrotic syndrome,<sup>15</sup> infantile spasms,<sup>16</sup> dermatomyositis, and polymyositis.<sup>17</sup>

To the best of our knowledge, treatment of ocular cicatricial pemphigoid with ACTH gel has never been reported. In this case report, we describe the clinical course and outcome of a patient with ocular cicatricial pemphigoid, treated with ACTH gel.

## 2. Case report

A 75-year-old woman was referred in April, 2015 due to chronic conjunctival redness, foreign body sensation, irritation and blurred vision in both eyes. She had previously been treated with topical steroids, topical cyclosporine (0.05%) and frequent use of lubricating eye drops. The patient had undergone amniotic membrane transplants in both eyes due to persistent corneal epithelial defects. She has a history of open-angle glaucoma, exudative age-related macular degeneration and cataract surgery in her right eye. The best corrected visual acuity (BCVA) was counting fingers (CF) in both eyes at the time of initial presentation. Slit-lamp examination revealed trichiasis, conjunctival injection, fornix shortening and subconjunctival fibrosis, as well as corneal scarring in both eyes. Serology testing was performed in order to exclude other infectious and autoimmune diseases and was negative. Ocular cicatricial pemphigoid (OCP) was confirmed using conjunctival biopsy with direct immunofluorescence testing of the conjunctiva. Based on the clinical findings, her disease was graded as stage 3.<sup>18</sup>

The patient was started on oral corticosteroids (prednisone 60 mg daily). Following initiation of oral corticosteroids, there was interval improvement in the ocular surface inflammation in both eyes. However, the patient developed multiple side effects attributed to systemic steroids including nervousness, moon facies, fatigue, ecchymoses, joint pain, swelling, and muscle weakness. In order to wean the patient off from systemic corticosteroids, initiation of immunomodulatory therapy was planned.

Mycophenolate mofetil was started (1000 mg twice daily), however, the patient had discontinued treatment after two months due to severe fatigue and persistent conjunctival inflammation after gradually tapering systemic corticosteroids dose. Methotrexate (MTX) was then initiated (15 mg weekly) and systemic corticosteroids were slowly tapered. After three months of MTX therapy, recurrence of bilateral conjunctival inflammation was observed and corneal ulcer had developed in the left eye. Methotrexate dose was increased to 30 mg weekly and the corneal ulcer was treated with topical antibiotics until resolved. However, the patient was still experiencing active conjunctival inflammation, recurrent corneal epithelial defects and systemic side effects from increasing MTX dose. These side effects included anemia, poor appetite, nausea, abdominal pain, skin rash, hair loss, recurrent urinary tract infections and was hospitalized due to pneumonia. Adalimumab and rituximab were suggested as alternative options, however, were not initiated because of denial for coverage for OCP by

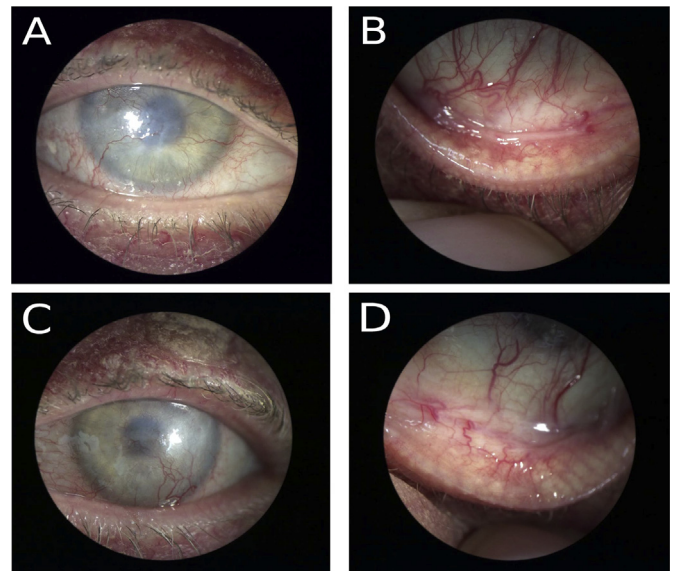


Fig. 1. Anterior segment photograph of both eyes under ACTH gel treatment. Right eye with corneal haze and vascularization (A), as well as inferior fornix shortening and subepithelial scarring, without active inflammation (B). Left eye with corneal scarring and vascularization (C), inferior fornix shortening and subepithelial scarring, without active inflammation (D).

her insurance.

The patient was started on twice weekly subcutaneous H.P. Acthar<sup>®</sup> Gel (repository corticotropin injection; Mallinckrodt Pharmaceuticals, St. Louis, MO), (80 units/ml), in June, 2016. On ocular examination, BCVA was CF in her right eye and hand motion (HM) in her left eye. Slit-lamp examination revealed active disease, characterized by conjunctival injection in both eyes. Following initiation of ACTH gel, MTX dose was gradually decreased, as well as the systemic corticosteroids. The patient remained under adequate control with ACTH gel and MTX. The conjunctiva remained scarred, but was no longer inflamed (Fig. 1). Following 6 months of treatment with ACTH gel, the patient had cataract surgery and penetrating keratoplasty (PKP) in her left eye, due to corneal scarring and vascularization that affected her vision.

On March, 2017, nine months after ACTH gel was started, the patient stopped treatment for 3 months (due to loss of coverage) and immediately flared up upon treatment cessation. Visual acuity in the left eye has decreased from 20/100 to CF and conjunctival inflammation was observed in both eyes. Corneal graft rejection and ulceration were noted in the left eye (as shown in Fig. 2), both of which subsided after resuming ACTH gel, but had left a scar in the corneal graft. PKP was later performed in the right eye as well, due to visually significant corneal scarring. On the last follow-up, after 19 months of treatment with ACTH gel, the BCVA was CF in the right eye and 20/200 in the left eye, no signs of inflammation were observed and corneal grafts were stable in both eyes. MTX was maintained on 25 mg weekly dose, and

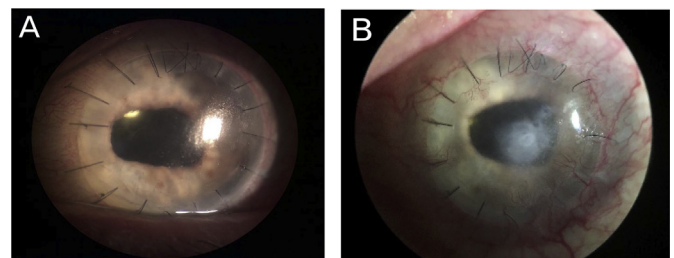


Fig. 2. Anterior segment photograph of the left eye, previously underwent penetrating keratoplasty with clear corneal graft, and on ACTH gel treatment (A). The patient stopped ACTH gel for 3 months and immediately flared up upon treatment cessation, with corneal graft rejection and ulceration (B).

was well tolerated. The patient did not develop any side effects to ACTH gel treatment, and is being continued on ACTH gel and MTX regimen, with good compliance and sufficient control of the disease.

### 3. Discussion

OCP is a devastating autoimmune blistering disease that frequently involves the conjunctiva and causes progressive scarring. Although the exact mechanism remains unknown, the pathogenesis includes circulating autoantibodies that bind to antigens within the basement membrane and activate the complement cascade, with further recruitment of inflammatory cells and cytokine secretion. The release of cytokines results in cytotoxic destruction of the conjunctival membrane, bulla formation and fibroblast activation with later progression to mucosal scarring. In the conjunctiva, recurrent inflammation causes loss of goblet cells and obstruction of lacrimal gland ductules, leading to aqueous and mucous tear abnormalities. These tear abnormalities, along with conjunctival scarring at the eyelid margin and mechanical trauma from eyelid changes, further cause corneal epithelial damage.<sup>19</sup> The clinical course and severity of OCP is variable. Without treatment, the disease progresses in up to 75% of patients.<sup>20</sup> Treatment of OCP is challenging; topical and subconjunctival agents are used only as an adjunctive measure with systemic immunomodulatory treatments, since they are ineffective in controlling and halting disease progression.<sup>6,21</sup>

ACTH induces cortisol production as well as stimulating anti-inflammatory processes by targeting melanocortin receptors present on immune cells.<sup>10</sup> Melanocortin receptors are expressed on a range of immune cells throughout the body, including T cells, macrophages, B cells, monocytes, neutrophils, and mast cells. Studies addressing the anti-inflammatory effects of  $\alpha$ -melanocyte-stimulating hormone ( $\alpha$ -MSH), a part of the melanocortin family, focus on the suppressive effect of the peptide on expression of pro-inflammatory cytokines.<sup>22</sup>

H.P Acthar Gel is an injectable formulation consisting of ACTH analogue. Since there are no guidelines regarding the recommended dosage for treatment of ocular diseases, we use a dose of 80 units/ml, administered subcutaneously twice weekly, as indicated for other FDA approved systemic diseases.<sup>12</sup> Although ACTH gel is approved by the FDA for a wide range of ophthalmologic indications, it is rarely used for either of these indications, due to a lack of data and the high cost of treatment. Possible adverse effects are related primarily to its steroidogenic action and include increased susceptibility to infection or reactivation of latent infection, fluid retention, altered electrolyte balance, increase in blood glucose, systemic hypertension, behavioral and mood changes, weight gain, and cushingoid features, among others.<sup>12</sup> In our case, the patient experienced multiple side effects from systemic corticosteroids, yet did not develop any of these side effects while on ACTH gel treatment.

In the current case, we reported the clinical course of a patient with progressive OCP, refractory and/or intolerant to several immunomodulatory agents. Initiation of ACTH gel treatment resulted in significant improvement of the conjunctival inflammation as well as of the patients' symptoms. ACTH gel provided adequate control and the disease remained inactive while the systemic corticosteroids dose was successfully tapered. A flare-up that occurred during treatment was attributed to ACTH gel treatment cessation, and resolved upon resuming treatment.

### 4. Conclusions

OCP can be challenging to treat, due to persistent inflammatory processes that cause progressive scarring and subsequent complications. Treatment is further complicated by the development of side effects to various therapies. According to our experience with ACTH gel treatment in a patient with OCP for more than a year, it may play a role in the management of patients with OCP. Better understanding the

physiological and pharmacological mechanisms of action of ACTH gel and involvement of the melanocortin system, is necessary in order to establish its role. ACTH gel may be repurposed for new indications in the ophthalmology field, including OCP, as it appears to be safe and can be used as long-term treatment option for patients with chronic ocular inflammatory diseases.

### Patient consent

The study and data accumulation were carried out with approval from the appropriate Institutional Review Board (IRB).

### Funding

Financial interest: This study was funded in part by Mallinckrodt Pharmaceuticals as a medical writing grant (#3840).

### Conflicts of interest

The following authors have no financial disclosures: Dr. Yael Sharon.

Dr. David S. Chu serves as a consultant for Mallinckrodt Pharmaceuticals, AbbVie, Aldeyra Therapeutics, Allakos Inc., and Santen Pharmaceuticals.

### Authorship

All authors attest that they meet the current ICMJE criteria for Authorship.

### Acknowledgements

None.

### References

- Schmidt E, Zillikens D. Pemphigoid diseases. *Lancet*. 2013;381(9863):320–332. [http://dx.doi.org/10.1016/S0140-6736\(12\)61140-4](http://dx.doi.org/10.1016/S0140-6736(12)61140-4).
- Kirzhner M, Jakobiec FA. Ocular cicatricial pemphigoid: a Review of clinical features, immunopathology, differential diagnosis, and current management. *Semin Ophthalmol*. 2011;26(4-5):270–277. <http://dx.doi.org/10.3109/08820538.2011.588660>.
- Foster CS. Cicatricial pemphigoid. *Trans Am Ophthalmol Soc*. 1986;84:527–663 <http://www.ncbi.nlm.nih.gov/pubmed/3296406> Accessed August 10, 2017.
- Thorne JE, Woreta FA, Jabs DA, Anhalt GJ. Treatment of ocular mucous membrane pemphigoid with immunosuppressive Drug therapy. *Ophthalmology*. 2008;115(12):2146–2152. <http://dx.doi.org/10.1016/j.ophtha.2008.08.002> e1.
- Saw VPJ, Dart JKG, Rauz S, et al. Immunosuppressive therapy for ocular mucous membrane pemphigoid strategies and outcomes. *Ophthalmology*. 2008;115(2):253–261. <http://dx.doi.org/10.1016/j.ophtha.2007.04.027> e1.
- Neff AG, Turner M, Mutasim DF. Treatment strategies in mucous membrane pemphigoid. *Therapeut Clin Risk Manag*. 2008;4(3):617–626 <http://www.ncbi.nlm.nih.gov/pubmed/18827857> Accessed September 16, 2017.
- Queisi MM, Zein M, Lamba N, Meese H, Foster CS. Update on ocular cicatricial pemphigoid and emerging treatments. *Surv Ophthalmol*. 2016;61(3):314–317. <http://dx.doi.org/10.1016/j.survophthal.2015.12.007>.
- Sami N, Letko E, Androudi S, Daoud Y, Foster CS, Ahmed AR. Intravenous immunoglobulin therapy in patients with Ocular–Cicatricial pemphigoid. *Ophthalmology*. 2004;111(7):1380–1382. <http://dx.doi.org/10.1016/j.ophtha.2003.11.012>.
- Foster CS, Chang PY, Ahmed AR. Combination of rituximab and intravenous immunoglobulin for recalcitrant ocular cicatricial pemphigoid. *Ophthalmology*. 2010;117(5):861–869. <http://dx.doi.org/10.1016/j.ophtha.2009.09.049>.
- Montero-Melendez T. ACTH: the forgotten therapy. *Semin Immunol*. 2015;27(3):216–226. <http://dx.doi.org/10.1016/j.smim.2015.02.003>.
- Getting SJ. Targeting melanocortin receptors as potential novel therapeutics. *Pharmacol Ther*. 2006;111(1):1–15. <http://dx.doi.org/10.1016/j.pharmthera.2005.06.022>.
- Full Prescribing Information HP. *Acthar Gel (Repository Corticotropin Injection)*. 2015; 2015 [www.acthar.com/pdf/acthar-pi.pdf](http://www.acthar.com/pdf/acthar-pi.pdf) <https://www.acthar.com/> Accessed August 8, 2017.
- Fiechtner JJ, Montroy T. Treatment of moderately to severely active systemic lupus erythematosus with adrenocorticotropic hormone: a single-site, open-label trial. *Lupus*. 2014;23(9):905–912. <http://dx.doi.org/10.1177/0961203314532562>.
- Simsarian J, Saunders C, Smith M. Five-day regimen of intramuscular or

- subcutaneous self-administered adrenocorticotrophic hormone gel for acute exacerbations of multiple sclerosis: a prospective, randomized, open-label pilot trial. *Drug Des Dev Ther.* 2011;5:381. <http://dx.doi.org/10.2147/DDDT.S19331>.
15. Madan A, Mijovic-Das S, Stankovic A, Teehan G, Milward AS, Khastgir A. Acthar gel in the treatment of nephrotic syndrome: a multicenter retrospective case series. *BMC Nephrol.* 2016;17:37. <http://dx.doi.org/10.1186/s12882-016-0241-7>.
  16. Baram TZ, Mitchell WG, Tournay A, Snead OC, Hanson RA, Horton EJ. High-dose corticotropin (ACTH) versus prednisone for infantile spasms: a prospective, randomized, blinded study. *Pediatrics.* 1996;97(3):375–379 <http://www.ncbi.nlm.nih.gov/pubmed/8604274> Accessed June 27, 2017.
  17. Levine T. Treating refractory dermatomyositis or polymyositis with adrenocorticotrophic hormone gel: a retrospective case series. *Drug Des Dev Ther.* 2012;6:133. <http://dx.doi.org/10.2147/DDDT.S33110>.
  18. Foster CS. Cicatricial pemphigoid. *Trans Am Ophthalmol Soc.* 1986;84:527–663 <http://www.ncbi.nlm.nih.gov/pubmed/3296406> Accessed March 11, 2018.
  19. Ahmed M, Zein G, Khawaja F, Foster CS. Ocular cicatricial pemphigoid: pathogenesis, diagnosis and treatment. *Prog Retin Eye Res.* 2004;23(6):579–592. <http://dx.doi.org/10.1016/j.preteyeres.2004.05.005>.
  20. Mondino BJ. Cicatricial pemphigoid and erythema multiforme. *Ophthalmology.* 1990;97(7):939–952 <http://www.ncbi.nlm.nih.gov/pubmed/2199891> Accessed August 10, 2017.
  21. Elder MJ, Bernauer W, Leonard J, Dart JK. Progression of disease in ocular cicatricial pemphigoid. *Br J Ophthalmol.* 1996;80(4):292–296 <http://www.ncbi.nlm.nih.gov/pubmed/8703876> Accessed August 10, 2017.
  22. Brzoska T, Luger TA, Maaser C, Abels C, Böhm M.  $\alpha$ -Melanocyte-Stimulating hormone and related tripeptides: biochemistry, antiinflammatory and protective effects *in vitro* and *in vivo*, and future perspectives for the treatment of immune-mediated inflammatory diseases. *Endocr Rev.* 2008;29(5):581–602. <http://dx.doi.org/10.1210/er.2007-0027>.