

Submitted: 11/08/2017

Accepted: 07/12/2017

Published: 31/12/2017

Cloacal impaction with cloacolith in a black-legged seriema (*Chunga burmeisteri*)

Dante Luis Di Nucci* and Martin Pablo Falzone

Temaikèn Foundation, Ruta 25 Km 0,700 Belén de Escobar, Buenos Aires Province, Argentina

Abstract

A 5-year-old intact female black-legged seriema (*Chunga burmeisteri*) was presented for behavioral changes and slight decrease in activity (minor vocalization and less mobility in enclosure). Physical examination revealed a firm, moderate dilation in the caudal coelom. A semi-spherical mass of greater radiodensity than soft tissues was observed in the region of the cloaca on radiographs. A cloacolith measuring approximately 4x3.7x3 cm was extracted manually. Cloacoliths are uncommon conditions in birds, and this case is the first record of cloacolith in *Chunga burmeisteri*.

Keywords: Avian, Black-legged seriema, *Chunga burmeisteri*, Cloacolith, Impaction.

Introduction

The black-legged seriema (*Chunga burmeisteri*), classified as “Least Concern” by International Union for Conservation of Nature (IUCN; Bird Life International, 2016), is one of only two species in the distinctive family Cariamidae, which is endemic in the Chaco region in Bolivia, Argentina, and Paraguay. The diet is specialized, mostly eating snakes and lizards, but can be omnivorous and will consume seeds and large insects (Schulenberg, 2017).

The avian cloaca is an organ consisting of three chambers (coprodeum, urodeum and proctodeum) that receive the contents of the rectum, the ureters, the left oviduct (in females) or paired ductus deferens (in males). The cloaca contains the cloacal bursa (bursa of Fabricius), a critical part of the developing immune system in juvenile birds (Taylor, 2016). Many diseases (primary or secondary) affect the cloaca of different avian species; and cloacoliths are considered relatively uncommon and poorly described (Taylor, 2016). There are few descriptive reports on diseases or medical care in captivity seriema (AZA, 2013) and this case report is the first published description of cloacal impaction with cloacolith in black-legged seriema.

Case Details

A 5-year-old intact female, captive hatched, black-legged seriema (*Chunga burmeisteri*) (1,360 kg body weight, body score 3/5) presented for manifesting a behavioral change with a slight decrease in activity (minor vocalization and less mobility in enclosure). The bird was not actively reproductive and had no history of digestive tract disorders or egg binding.

The animal was housed in a mixed immersion exhibitor with exuberant vegetation (surface 616m², height 5.50m, volume 3.388 m³) with blue-and-gold macaws (*Ara ararauna*) (n=4), green-winged macaws (*Ara*

chloroptera) (n=8), chestnut-fronted macaws (*Ara severa*) (n=2) and a red-fronted macaw (*Ara rubrogenys*) (n=1) for the last two years. It was fed a daily mixture of 10 g of Eukanuba Adult Medium Breed dog food plus 100 g of ground beef supplemented with calcium carbonate and 20g of seed mixture (split pea, sorghum, corn and wheat). Two times per week, 3 mice or 3 baby chickens (freshly killed) and live insect variety were offered as enrichment.

On physical examination, moderate dilation was observed in the caudal portion of the coelom. Palpation revealed a firm mass. There was a putrid smell coming from the cloaca and presence of petechiae in the oral cavity. No other abnormalities were observed.

The bird was anesthetized to perform diagnostic procedures. It was induced with 5% isoflurane (Isoflurane, Nicholas Piramal, Bedford, Bedfordshire, UK) administered by mask and subsequently maintained with isoflurane between 2% - 3%. Full-body radiographs revealed (Pimax HF Vet, Rayos Pimax SRL, Buenos Aires, Argentina & CR 30-X Digitizer, Agfa Healthcare, Peissenberg, Weilheim-Schongau, Bavaria, Germany) a semi-spherical mass of greater radiodensity than soft tissues in the region of the cloaca and reduction of caudal air sac space (Fig. 1). After the radiographs, the cloacal lumen was opened using a stainless steel speculum. Inflammation of the cloacal mucosa (hyperemia and slight mucosal thickening) and a mass were visualized. During the inspection of the cloaca a cotton swab was inserted to assess the mobility of the mass.

Results of a complete blood count and serum chemistry panel did not reveal any abnormalities as compared to reference individuals from Temaikèn Foundation (n=6) (unpublished data).

*Corresponding Author: Dante Luis Di Nucci. Temaikèn Foundation, Ruta 25 Km 0,700 Belén de Escobar, Buenos Aires Province, Argentina. Email: dinucciondante@gmail.com

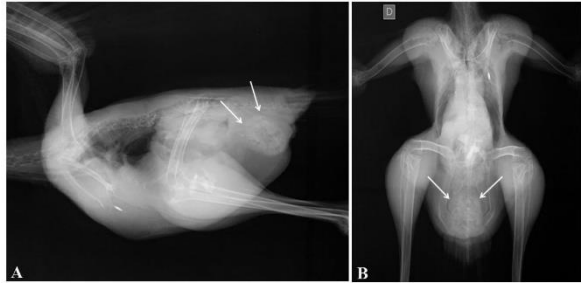


Fig. 1. Lateral (A) and ventrodorsal (B) radiographs of a black-legged seriema. The cloacolith is visible in caudal coelomic cavity. Observed as increased soft tissue density (arrows).

Packed cell volume 41% (reference values: Mean 40,83 \pm 3,13 / Range 35-44), Red blood cell 2.36 x 10⁶/ μ l (reference values: Mean 2.248 \pm 505 / Range 1.790 - 3.050), white blood cell 9,020 cells/ μ l (reference values: Mean 10.253 \pm 1650 / Range 8140 - 12320), Total protein 4 g / dL (reference values: Mean 3.94 \pm 0.55 / Range 3.27 - 4.8), Albumin 2,296 g/dL (reference values: Mean 1,744 \pm 0,580 / Range 1,123 - 2,605), Uric acid 0.999 mg / dL (reference values: Mean 1.66 \pm 1.17 / Range 0.590-3.21). After the radiographs and still under anesthesia, the bird was treated with oxytetracycline (75mg/kg SC, SID 7 days, Kuramicina LA, Laboratorios König SA, Avellaneda, Buenos Aires, Argentina), carprofen (4mg/kg IM, SID 3 days, Carprobay, Bayer SA, Munro, Buenos Aires), subcutaneous fluids (Ringer's Lactate Solution 50 ml/kg/ day SC, B. Braun Medical SA, Mar del Plata, Buenos Aires, Argentina), and tramadol (2 mg/kg IM, SID 3 days, Algen 20, Richmond Vet Pharma, Grand Bourg, Buenos Aires, Argentina). An enema of 10 ml of warm sterile saline solution was administered followed by 5 ml of vaseline (Liquid Vaseline Medicinal FNA, Drogal SACIFI, Buenos Aires, Argentina). Subsequent to lubrication with vaseline, the mass was extracted manually. The recovered mass (approximately 4x3.7x3 cm) was malodorous, of hard consistency with a rough appearance and deposits of urates on its surface (Fig. 2). Treatment with 5 ml of vaseline in the diet (mixed with the ground beef) was prescribed for one week. Radiographs were obtained after removal of the cloacolith and confirmed the complete extraction of the this mass. Three days later, a physical examination of the cloaca was performed. The cloacal mucosa appeared normal. After four years, the clinical problem did not recur.

Discussion

Little is known about nutrition, behavior management and veterinary care of *Chunga burmeisteri* in captivity (AZA, 2013). In this case, we have described a diagnosis of cloacolith via radiography, manual palpation and direct observation within the cloaca.

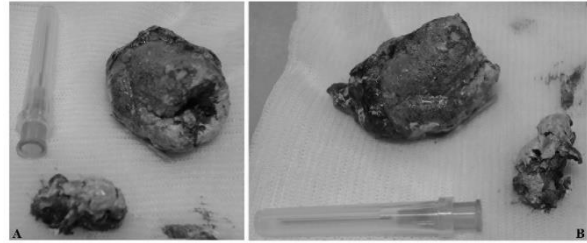


Fig. 2. Two views (A and B) for the cloacolith removed from the black-legged seriema. The cloacolith measured approximately 4x3.7x3 cm.

Treatment consisted of manual removal and management of the secondary cloacitis with systemic antibiotic, nonsteroidal anti-inflammatory and synthetic opioid analgesic. Cloacoscopy has also been reported for a diagnosis of cloacolith in birds (Beaufriere *et al.*, 2010; Taylor, 2016).

Primary diseases of the cloaca include, infectious (Bacterial - including mycobacteriosis; Viral - avian bornavirus, herpesvirus-related papillomas; Fungal; Parasitic/protozoal – including Sarcocystis), trauma, and neoplasia (including lymphosarcoma, squamous cell carcinoma, hemangioma and fibrosarcoma). Secondary diseases of cloaca include diseases of the reproductive tract (dystocia, salpingitis, chronic hormone stimulation, chronic oviposition), diseases of the urinary tract (cloacoliths, urolithiasis), diseases of the gastrointestinal tract (enteritis, intussusception, obstruction, hypermotility disorders) and miscellaneous diseases (cloacal atony due to nerve injury) (Lee *et al.*, 2014; Taylor, 2016).

Clinical signs indicative of cloacal disorders may include flatulence, tenesmus, and hematochezia, soiled pericloacal area, protruding tissue from the cloaca and foul-smelling feces (Lumeij, 1994).

Impaction of the cloaca can result from a variety of causes including failure to pass an egg (retained necrotic eggs), foreign bodies, cloacolith, secondary to cloacal infections, intrinsic disease of the cloacal wall, and loss of muscle tone caused by viral-induced ganglioneuritis (PDD) (Lumeij, 1994; Schmidt, 1999). Cases of impaction of the cloaca have been reported in psittacine birds (Schmidt, 1999), in galliformes with foreign bodies (potato chunks) (Lumeij, 1994), in New Zealand wood pigeon (*Hemiphaga novaeseelandie*) (Nikaun Palm seeds) (Boardman, 1994) and in cattle egret (*Bubulcus ibis*) (normal-shelled egg) (Keymer, 1980).

Cloacoliths are firm, rough-surfaced aggregations of urates. They will at times also contain fecal material (Gelís, 2006). They are uncommon, and the pathogenesis is unclear, but is believed to involve impaired defecation with retention of urates that may cause dehydration.

This may solidify and chemically alter the urate mass, causing it to form a solid structure (Forbes, 2002; Gelis, 2006). Cloacoliths have been observed in a number of psittacine birds, particularly macaws, Amazon parrots (*Amazona sp*) (Roskopf and Woerpel, 1989; Lumeij, 1994; Beaufreere *et al.*, 2010), African grey parrot (*Psittacus erithacus*) (Christen and Hatt, 2006), as well as some raptors (Forbes, 2002) and an African black-footed penguin (*Spheniscus demersus*) (Jones *et al.*, 2014). Also, two cases of cloacoliths in raptors with cloacal prolapse have been reported. One of them in a laggar falcon (*Falco jugger*) whose etiology was a vertebral injury and the second in a Harris hawk (*Parabuteo unicinctus*) with secondary cloacitis by prolonged egg incubation (Dutton *et al.*, 2016). Recurrence of cloacoliths has been observed (Gelis, 2006). A report described that the cloacoliths have been encountered most frequently in carnivorous birds, especially in birds that have recently undergone extended nesting or brooding behavior, such that they may not have voided feces as frequently as normal (Forbes, 2002). Most avian cloacoliths are composed of uric acid (Beaufreere *et al.*, 2010; Taylor, 2016). This case is the first record of cloacolith in *Chunga burmeisteri*. The definitive cause for the cloacolith formation was not determined. However, as has been suggested, possible contributing factors include a shifts in cloacal bacterial flora composition, improper diet (eg excessive dietary calcium or excessive protein), concurrent cloacal problems (e.g., stricture), behavioral reluctance to eliminate and dehydration (Beaufreere *et al.*, 2010; Burgos-Rodriguez, 2010).

Acknowledgements

The authors thank Maria de las Mercedes Guerisoli for the edition of photographs and Javier Nevarez for helpful for english revision and edits of this manuscript.

Conflict of interest

The authors declare that there is no conflict of interest.

References

- AZA Red-legged Seriema SSP. 2013. Red-legged Seriema (*Cariama cristata*) Care Manual. Association of Zoos and Aquariums, Silver Spring, MD.
- Beaufreere, H., Nevarez, J. and Tully, T. 2010. Cloacolith in a blue-fronted Amazon parrot (*Amazona aestiva*). J. Avian Med. Surg. 24(2), 142-145.
- Bird Life International. 2016. *Chunga burmeisteri*. The IUCN Red List of Threatened Species 2016: e.T22692208A93341490.
<http://dx.doi.org/10.2305/IUCN.UK.2016-3.RLTS.T22692208A93341490.en>. Accessed on 10 August 2017.
- Boardman, W. 1994. Cloacal impaction in a New Zealand wood pigeon. Kokako. 1(1), 7.
- Burgos-Rodriguez, A.G. 2010. Avian renal system: clinical implications. Vet. Clin. North Am. Exot. Anim. Pract. 13, 393-411.
- Christen, C. and Hatt, J.M. 2006. What is your diagnosis? J. Avian Med. Surg. 20(2), 129-131.
- Dutton, T.A.G., Forbes, N.A. and Carrasco, D.C. 2016. Cloacal prolapse in raptors: review of 16 cases. J. Avian Med. Surg. 30(2), 133-140.
- Forbes, N.A. 2002. Avian gastrointestinal surgery. Semin. Avian Exotic Pet Med. 11(4), 196-207.
- Gelis, S. 2006. Evaluating and Treating the Gastrointestinal System. In: Harrison, G.J., Lightfoot, T.L, eds. Clinical Avian Medicine. Palm Beach, FL: Spix Publishing, Inc., pp: 411-440.
- Jones, K.L., Field, C.L., Stedman, N.L. and Mac Lean, R.A. 2014. Cloacolithiasis and intestinal lymphosarcoma in an african black-footed penguin (*Spheniscus demersus*). J. Zoo Wildl. Med. 45(2), 446-449.
- Keymer, I.F. 1980. Disorders of the avian female reproductive system. Avian Pathol. 9(3), 405-419.
- Lee, A., Lennox, A. and Reavill, D. 2014. Diseases of the Cloaca: A Review of 712 Cloacal Biopsies. Proc. Annu. Conf. Assoc. Avian Vet. pp: 51-60.
- Lumeij, J.T. 1994. Gastroenterology. In: Ritchie, B.W., Harrison, G.J., Harrison, L.R., eds. Avian Medicine: Principles and Application. Lake Worth, FL: Wingers Publishing, pp: 482-521.
- Roskopf, W.J and Woerpel, R.W. 1989. Cloacal conditions in pet birds with a cloacapexy update. Proc. Assoc. Avian Vet. pp: 156-163.
- Schmidt, R.E. 1999. Pathology of Gastrointestinal Diseases of Psittacine Birds. Semin. Avian Exotic Pet Med. 8(2), 75-82.
- Schulenberg, T.S. 2017. Black-legged Seriema (*Chunga burmeisteri*), Neotropical Birds Online (T.S. Schulenberg, Editor). Ithaca: Cornell Lab of Ornithology; retrieved from Neotropical Birds <https://neotropical.birds.cornell.edu/Species-Account/nb/species/bllser1>
- Taylor, W.T. 2016. Clinical Significance of the Avian Cloaca: Interrelationships with the Kidneys and the Hindgut. In: Speer, B.L. Current Therapy in Avian Medicine and Surgery. Elsevier, Inc., pp: 329-344.