



Contents lists available at ScienceDirect

International Journal of Surgery Case Reports

journal homepage: www.casereports.com

Closed reduction and percutaneous “periarticular” single K-wire fixation for displaced unstable transverse fractures of the proximal phalanx in elderly osteoporotic women: A case series of five patients

Abdulaziz Alazzam^a, Mohammad M. Al-Qattan^{a,b,*}

^a Department of Surgery at King Saud Bin Abdulaziz University for Health Sciences, Riyadh, Saudi Arabia

^b Division of Plastic and Hand Surgery at King Saud University, Riyadh, Saudi Arabia

ARTICLE INFO

Article history:

Received 8 June 2017

Received in revised form 8 August 2017

Accepted 8 August 2017

Available online 10 August 2017

Keywords:

K-wire
Fixation
Fractures
Proximal phalanx
Elderly
Osteoporosis

ABSTRACT

INTRODUCTION: A literature review did not reveal any study investigating the results of surgical management of fractures of the proximal phalanx in elderly osteoporotic women. We present a case series of five patients.

PATIENTS AND METHODS: Five consecutive cases with seven fractures of the shaft/base of the proximal phalanx were retrospectively reviewed. The mean age of the study group was 72.4 years (range, 70–76 years). All patients were on treatment for osteoporosis at the time of injury. All patients were treated with closed reduction and percutaneous “periarticular” single K-wire fixation followed by immediate active mobilization of all joints.

RESULTS: Two minor complications were seen: superficial pin tract infection in one case; and slight fracture displacement after K-wire removal resulting in malunion in the other case. After a mean follow-up of 4 months, the total active motion was considered excellent in 5 fingers and good in 2 fingers.

CONCLUSION: We demonstrate a favorable outcome following closed reduction and percutaneous “periarticular” single K-wire fixation for displaced unstable transverse fractures of the proximal phalanx in elderly osteoporotic women.

© 2017 The Author(s). Published by Elsevier Ltd on behalf of IJS Publishing Group Ltd. This is an open access article under the CC BY-NC-ND license (<http://creativecommons.org/licenses/by-nc-nd/4.0/>).

1. Introduction

Out of all extra-articular fractures of the adult hand, displaced unstable transverse fractures of the proximal phalanx are known to have the worst outcome because of postoperative stiffness [1]. Hence, these fractures have been called the ‘no man’s land’ fractures of the hand [2]. Closed reduction and percutaneous K-wire fixation remains the most popular method of treating these fractures. There are two main techniques of K-wire fixation: the trans-articular (also known as the trans-metacarpal) and the periarticular techniques. In the former, one or two K-wires are inserted through the metacarpal head and the flexed metacarpophalangeal joint [3–5]. In the latter, the K-wires are inserted through the radial or ulnar base of the proximal phalanx without going through the metacarpal head; and hence all finger joints are free [6–9].

An extensive review of the literature did not reveal any study investigating the results of percutaneous K-wire fixation of proximal phalangeal fractures in elderly osteoporotic women. Other

upper limb fractures in this subset of patients are known to be more difficult to treat and are also known to have a guarded outcome [10,11]. We present a case series of five patients. The case series is compliant with the PROCESS Guidelines [12].

2. Methods

This retrospective case series is in accordance with the declaration of Helsinki. Over a seven-year period (2010–2017), five elderly osteoporotic women were treated by the senior author (MMA). All patients were on treatment for osteoporosis at the time of injury. Their demographic data are shown in Table 1. The mean age was 72.4 years (range, 70–76 years). One patient had multiple finger fractures and the remaining four had involvement of a single finger. The fracture involved the base or shaft of the proximal phalanx. No phalangeal neck fractures were seen. The mechanism of injury was either entrapment in a door or a direct blow from a heavy object falling on the fingers. All patients presented to the senior author (MMA) within 6 h of injury and were treated within 24 h with closed reduction and periarticular single K-wire fixation. Preoperatively, all patients had medical assessment, prophylactic antibiotics, and pneumatic leg compression for deep vein thrombosis (DVT) prophylaxis.

* Corresponding author at: Division of Plastic Surgery and Hand Surgery at King Saud University, Riyadh, Saudi Arabia.

E-mail addresses: alazzamaziz@gmail.com (A. Alazzam), moqattan@hotmail.com (M.M. Al-Qattan).

Table 1

Demographic data of five elderly osteoporotic women with transverse fractures of the proximal phalanx and who were treated with percutaneous “periarticular” K-wire fixation.

Patient Number	Age and Sex	Pre-existing disease	Site of the proximal phalangeal fracture	Other injures in the same hand
1	73, F	Osteoporosis, hyperlipidemia, hypertension, diabetes	Middle finger (shaft), ring finger (base), little finger (base)	Partial extensor tendon injury of the middle finger ^a
2	71, F	Osteoporosis, hypertension, ischemic heart disease	Little finger (shaft)	No
3	70, F	Osteoporosis, hypertension, diabetes, ischemic heart disease	Little finger (shaft)	Hematoma at the proximal interphalangeal joint of the adjacent ring finger
4	72, F	Osteoporosis, diabetes, lower limb atherosclerosis	Index finger (base)	No
5	76, F	Osteoporosis, hypertension, history of transient ischemic attacks	Little finger (base)	Partial extensor tendon injury of the injured finger ^a

^a Partial tendon injuries were not repaired.

2.1. Surgical technique

Surgery was performed by a senior Hand Surgeon (MMA) at large Government Hospitals. Using the intraoperative image intensifier, the metacarpophalangeal joint was flexed and a single K-wire (size 1.2–1.4 mm) was placed through the radial or ulnar base of the fractured proximal phalanx. Care is given to avoid the extensor tendons and metacarpal head during K-wire placement. Once the K-wire has purchased the proximal fracture fragment, finger traction in the intrinsic plus position is done to obtain fracture reduction. Once reduced, the K-wire is drilled further into the medullary canal of the distal fragment. Drilling continues till a purchase of the subchondral bone of the head of the proximal phalanx is obtained. The K-wires are left protruding outside the skin and covered with iodine-soaked gauze.

2.2. Postoperative care and rehabilitation

No splint is applied after surgery. Active and passive exercises of all finger joints were started on the first postoperative day. Exercises were done not only by the physiotherapist at the hospital, but also by the patient at home. Pin site care was done twice weekly. The wires were removed 6–7 weeks after surgery.

2.3. Assessment

Complications such as pin tract infection, complex regional pain syndrome, osteomyelitis, mal-union and non-union) were documented. At final follow-up, the total active motion at the metacarpophalangeal and interphalangeal joints were also documented. The outcome was considered excellent, good, fair and poor if the total active motion was >260°, 250°–259°, 210°–249° and <210°, respectively.

3. Results

One patient (Case #4) developed superficial pin tract infection which responded to oral antibiotics; and this did not require premature removal of the K-wire. All patients demonstrated clinical evidence of fracture union (no tenderness at the fracture site) at the time of K-wire removal 6–7 months after injury. Radiographic union with bony coalition at the fracture site was seen at a mean of 55 days (range 45–70 days). One fracture (Case #3) slightly displaced after K-wire removal; but the resulting malunion did not result in scissoring or loss of range of motion (when compared to the range of motion just prior to K-wire removal).

Follow-up ranged from 3 to 5 months (mean of 4 months). The results of total active motion at final follow-up are shown in Table 2. All fractures qualified for an excellent or a good outcome. Fig. 1

Table 2

Total active motion of the finger at final follow-up in 5 treated patients.

Patient Number	Total active motion	Outcome ^a
1	Middle finger: 270° Ring finger: 270° Little finger: 270°	Excellent Excellent Excellent
2	- Little finger: 260°	Excellent
3	- Little finger: 250°	Good
4	- Index: 255°	Good
5	- Little finger: 265°	Excellent

^a The outcome was considered excellent, good, fair and poor if the total active motion was >260°, 250° – 259°, 210° – 249, and <210°.

demonstrates an excellent outcome (Case #1). Fig. 2 demonstrates a good outcome (Case #3); and this case also demonstrates fracture displacement that occurred after removal of the K-wire. The supplementary video demonstrates that early active motion exercises (with the K-wires in place) are well tolerated.

4. Discussion

The current series is the first series in the literature that specifically investigates the outcome of surgical management of transverse fractures of the proximal phalanx in elderly osteoporotic women. The study also demonstrates a favorable outcome using closed reduction and ‘periarticular’ single K-wire fixation. Immediate active mobilization of all finger joints was well tolerated despite the protruding K-wires (Supplementary video). Our study population is prone to stiffness because of the advanced age. Yet, a favorable outcome was obtained in all patients. We think that this is probably related to two main factors: the periarticular technique leaves all joints free to move, and the employment of early mobilization of all joints starting the first postoperative day.

The periarticular K-wire technique in the management of fractures of the proximal phalanx was first introduced in the literature by Joshi in 1976 [13]. However, the technique did not gain popularity until its recent utilization by Al-Qattan in transverse fractures of the neck, shaft and base of the proximal phalanx [6,7,14]. Al-Qattan recommended the use of a single periarticular K-wire and immediate postoperative active mobilization of all joints. Following Al-Qattan, other authors also utilized the periarticular K-wire fixation [8,9]; but their technique and postoperative rehabilitation were different. These authors recommended using two relatively thin K-wires instead of a single relatively thick K-wire [8,9]. Furthermore, they recommended a gradual protocol of active mobilization as follows: complete immobilization for 5–7 days followed by splinting of the metacarpophalangeal joints or 3–4 weeks [8,9]. This meant that early mobilization was only employed to the inter-

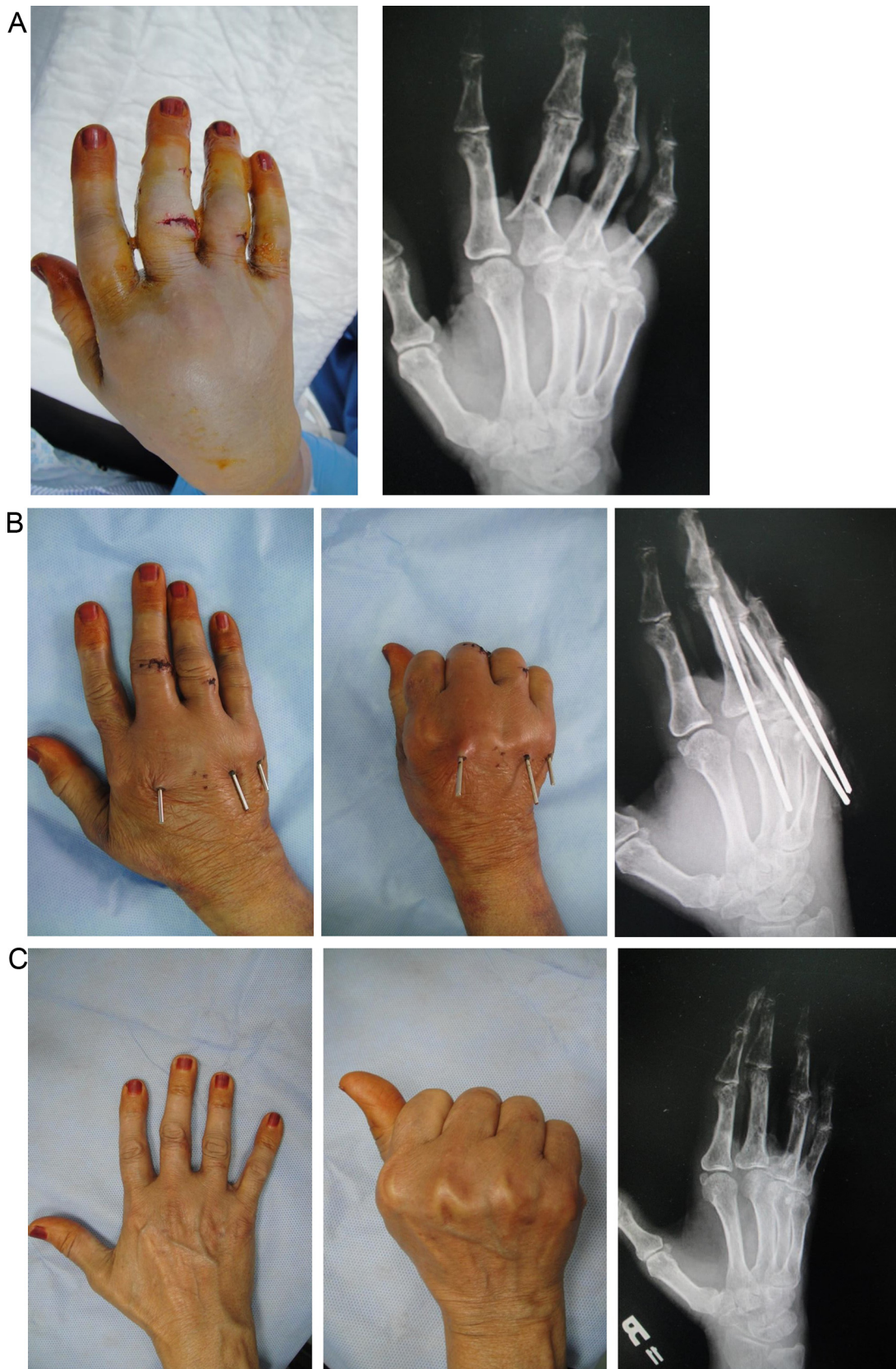


Fig. 1. Case #1. A: Preoperative appearance and X-ray. B: Range of motion and X-ray at 10 days. C: Range of motion and X-ray at 3 months.

phalangeal joints. In our series, we have utilized the technique as per Al-Qattan's recommendations.

There are many other techniques described in the literature for managing displaced unstable transverse fractures of the proximal phalanx. Jehan et al. [15] showed excellent/good outcomes in 81%

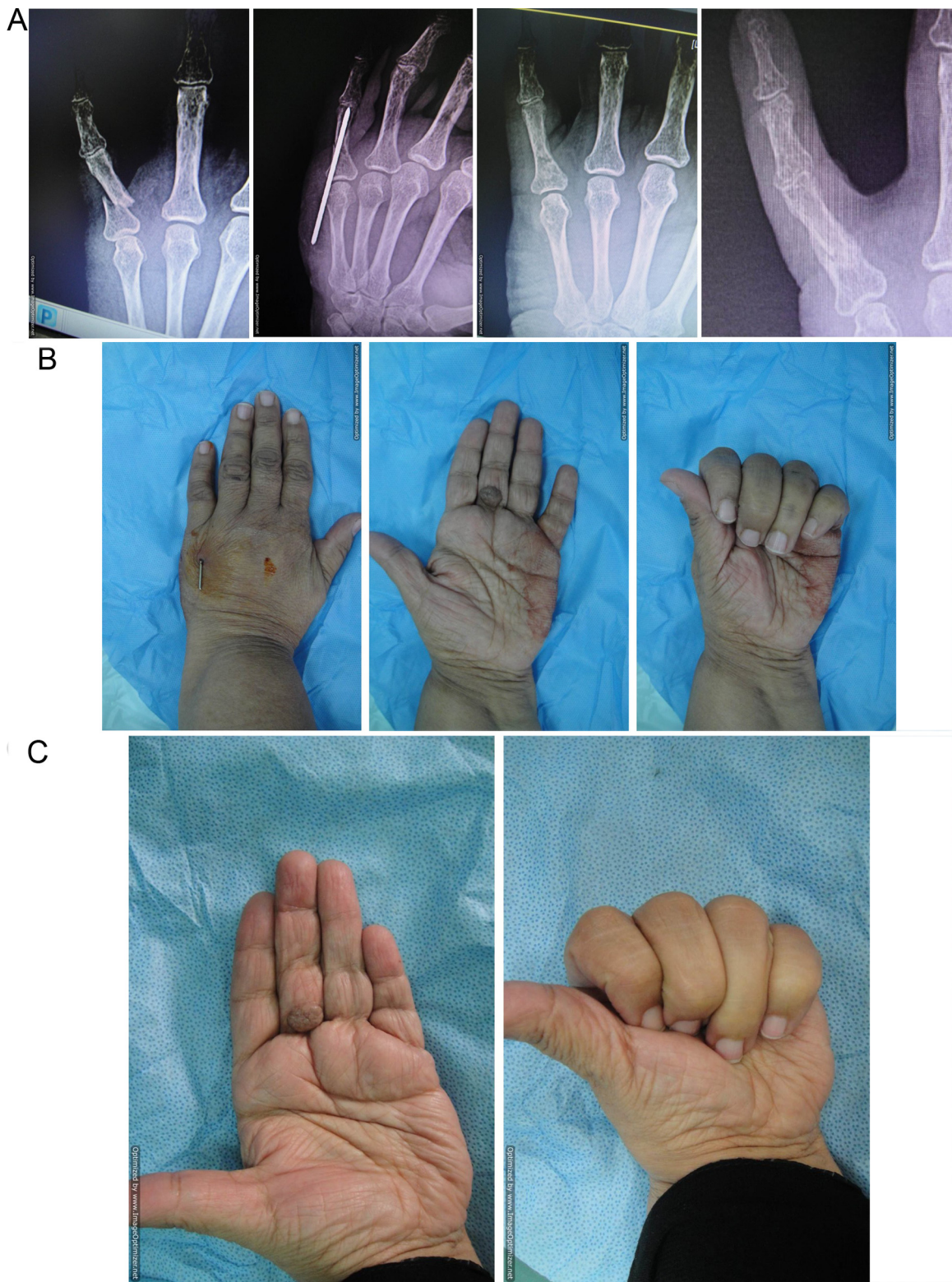


Fig. 2. Case #3.

A: From right to left: X-ray at the time of injury, X-ray with the K-wire in place, and X-ray at 6 weeks (immediately following K-wire removal). There was clinical evidence of union with no fracture displacement. The last x-ray on the left is the X-ray at 3 months showing the malunion; indicating fracture displacement after removal of the K-wire.

B: Range of motion at 5 days.

C: Range of motion at 3 months.

of cases using a non-operative technique known as the “finger nail traction” technique. However, the technique requires the constant application of a digital splint which is expected to result in stiffness

in the elderly. Similarly, the trans-metacarpal insertion of K-wires is associated with a high rate of significant stiffness (24% of fair/poor outcome as reported by Elmaraghy et al. [4]) because the wires go

through the metacarpophalangeal joints and the extensor mechanism. Open reduction and plate fixation is generally not ideal for osteoporotic bones and the technique is known to be associated with a high rate of poor outcome when utilized in fractures of the proximal phalanx [16]. Other techniques such as the “bouquet” multiple intramedullary wiring [17], external fixation [18], and tension bands [19] may give a good outcome; but the single K-wire fixation is much simpler than these techniques.

5. Conclusion

We demonstrate a favorable outcome following closed reduction and percutaneous “periarticular” single K-wire fixation for displaced unstable transverse fractures of the proximal phalanx in elderly osteoporotic women. However, a comparative study is required to compare the results of this technique of fixation to other techniques in the elderly.

Conflict of interest

None.

Funding

The work was supported by the College of Medicine Research Center, Deanship of Scientific Research, King Saud University, Riyadh, Saudi Arabia.

Ethical approval

The study was approved by the Research Committee of National Hospital (Riyadh Care) Riyadh, Saudi Arabia.

Consent

Written informed consent was obtained from the patients for publication. A copy of the written consent is available for review by the Editor-In-Chief of this journal on request.

Author's contribution

All authors contributed significantly and in agreement with the content of the manuscript. The first author did the literature review, and wrote the initial draft. The senior author performed the surgery and wrote the final draft.

Guarantor

M M Al-Qattan.

Appendix A. Supplementary data

Supplementary data associated with this article can be found, in the online version, at <http://dx.doi.org/10.1016/j.ijscr.2017.08.006>.

References

- [1] S.P. Chow, W.K. Pum, Y.C. So, et al., A prospective study of 245 open digital fractures of the hand, *J. Hand Surg. Br.* 16 (1991) 137–140.
- [2] G. Rajesh, W.Y. Ip, S.P. Chow, B.K. Fung, Dynamic treatment for proximal phalangeal fracture of the hand, *J. Orthop. Surg.* 15 (2007) 211–215.
- [3] E.E. Honbach, M.S. Cohen, Closed reduction and percutaneous pinning of fractures of the proximal phalanx, *J. Hand Surg. Br.* 26 (2001) 45–49.
- [4] M.W. ElMaraghy, A.W. ElMaraghy, R.S. Richards, et al., Transmetacarpal intramedullary K-wire fixation of proximal phalangeal fractures, *Ann. Plast. Surg.* 41 (1998) 125–130.
- [5] M.R. Belsky, R.G. Eaton, L.B. Lane, Closed reduction and internal fixation of proximal phalangeal fractures, *J. Hand Surg. Am.* 9 (1984) 725–729.
- [6] M.M. AlQattan, Phalangeal neck fractures of the proximal phalanx of the fingers in adults, *Injury* 41 (2010) 1084–1089.
- [7] M.M. AlQattan, Displaced unstable transverse fractures of the shaft of the proximal phalanx of the fingers in industrial workers: reduction and K-wire fixation leaving the metacarpophalangeal and proximal interphalangeal joints free, *J. Hand Surg. Eur. Vol* (2011) 577–583.
- [8] S. Faruqu, P.J. Stern, T.R. Kilfhaber, Percutaneous pinning of fractures in the proximal third of the proximal phalanx: complications and outcomes, *J. Hand Surg.* 37 (2012) 1342–1343.
- [9] K.R. Eberlin, A. Babushkina, J.R. Neira, C.S. Mudgel, Outcome of closed reduction and periarticular pinning of base and shaft fractures of the proximal phalanx, *J. Hand Surg. Am.* 39 (2014) 1524–1528.
- [10] J.E. Foote, T.D. Rozental, Osteoporosis and upper extremity fragility fractures, *J. Hand Surg. Am.* 37 (2012) 165–167.
- [11] S.K. Fitzpatrick, N.E. Casemyr, D. Zurakouski, C.S. Day, T.D. Rozental, The effect of osteoporosis on outcome of operatively treated distal radius fractures, *J. Surg. Am.* 37 (2012) 2027–2034.
- [12] R.A. Agha, A.J. Fowler, S. Rajmohan, I. Barai, D.P. Orgill for the PROCESS Group, Preferred reporting of case series in surgery; the PROCESS guidelines, *Int. J. Surg.* 36 (2016) 319–323.
- [13] B. Joshi, Percutaneous internal fixation of fractures of the proximal phalanges, *Hand* 8 (1976) 86–92.
- [14] M.M. AlQattan, A.M. AlQattan, A review of phalangeal neck fracture in children, *Injury* 46 (2015) 935–944.
- [15] S. Jehan, T. Chandrapakasan, S. Thanbiraj, Management of proximal phalangeal fractures of the hand using finger nail traction and a digital splint: a prospective study of 43 cases, *Clin. Orthop. Surg.* 4 (2012) 156–162.
- [16] U. Nalbantoglu, A.G. Ereli, F. Cilli, B.Y. Ucar, M. Tunkmen, Open reduction and low-profile plate and/or screw fixation in the treatment of phalangeal fractures, *Acta Orthop. Traumatol. Turc.* 43 (2009) 317–323.
- [17] M.H. Gonzalez, C.M. Igran, R.F. Hall, Intramedullary nailing of proximal phalangeal fractures, *J. Hand Surg. Am.* 20 (1995) 808–812.
- [18] K. Margic, External fixation of closed metacarpal and phalangeal fractures of the digits. A prospective study of one hundred consecutive patients, *J. Hand Surg. Br.* 31 (2006) 30–40.
- [19] Y. Safoury, Treatment of phalangeal fractures by tension band wiring, *J. Hand Surg. Br.* 26 (2001) 50–52.

Open Access

This article is published Open Access at sciendo.com. It is distributed under the [IJSCR Supplemental terms and conditions](#), which permits unrestricted non commercial use, distribution, and reproduction in any medium, provided the original authors and source are credited.