

Received: 2010.08.05
Accepted: 2011.02.14

Lipomas of the central nervous system in the newborns – a report of eight cases

Kinga Gradowska¹, Justyna Czech-Kowalska¹, Elżbieta Jurkiewicz²,
Justyna Komornicka², Anna Dobrzańska¹

¹ Department of Neonatology, Neonatal Pathology and Intensive Care, Children's Memorial Health Institute, Warsaw, Poland

² Department of Diagnostic Imaging, Children's Memorial Health Institute, Warsaw, Poland

Author's address: Kinga Gradowska, Department of Neonatology, Neonatal Pathology and Intensive Care, Children's Memorial Health Institute, Dzieci Polskich 20 St., 04-713 Warsaw, Poland, e-mail: kina2002@wp.pl

Summary

Background:

Central nervous system lipomas are rare tumours. In most of the cases they are located in corpus callosum of the brain. The ultrasonographic image of lipomas tends to be quite characteristic. Final diagnosis is however done on a basis of brain resonance. The purpose of this work is to present proceeding in case of central nervous system lipomas with particular attention to diagnostic imaging. This work is based on own research.

Case Report:

There are eight patients with central nervous system lipomas described in this work. The ultrasonographic imaging performed upon patients' birth revealed features of agenesis of corpus callosum with presence of hyperechoic structure in the area of median line within corpus callosum. This image correlated with Nuclear Magnetic Resonance examination results. Our research confirms that patients with central nervous system lipomas represent rare diagnostic and therapeutic cases. Due to characteristic results of ultrasonographic imaging of the brain, recognition of agenesis of corpus callosum would not cause difficulties. However the presence of hyperechoic structure without vascular flow which may suggest lipomas of corpus callosum would require final verification of the diagnosis and wider assessment of brain with NMR examination. We did not recognize any relation between corpus callosum pathology and neuroinfection of cytomegalovirus etiology. In all of the eight research cases there were malformations diagnostics conducted. There were genetic irregularities in case of two of the neonates only. Until today, all of the patients remain under neurological care. Their psychomotor development is regularly controlled.

Conclusions:

Taking into consideration that numerous malformations occur altogether with brain lipomas, it is recommended to conduct appropriate diagnostics, to inform parents on an essence of diagnosis and on necessity of observing child's psychomotor development. Obviously, it is crucial to secure a patient with paediatric and neurological care.

Key words:

corpus callosum • choroid plexus • lipomas • brain resonance • psychomotor development

PDF file:

<http://www.polradiol.com/fulltxt.php?ICID=882148>

Background

Central nervous system (CNS) lipomas are benign, congenital, slow-growing tumors. They consist of mature fat cells enclosed within fibrous tissue and vessels that surround and infiltrate the neural structures, making radical neurosurgery impossible to carry out. In some cases, lipomas may be surrounded by a connective tissue capsule.

Cerebral lipomas represent 0.1–1.7% of CNS tumors ascertained *in vivo*, 0.08–0.45% in post mortem examinations, and 4% in prenatal testing [1–3]. A higher predisposition to these tumors was found in males, approximately 51–60%. CNS lipomas are situated mainly in supratentorial midline (approximately 80% of cases), usually in corpus callosum. Another locations of lipomas include: basal cistern, cerebral hemispheres, tectal plate, pontocerebellar angle and

Table 1. Defects coexisting with cerebral lipoma, depending on the location.

Lipoma of corpus callosum	Agenesis of corpus callosum, hypoplasia of the mamillary bodies. Thalamic adhesion, agenesis of septum lucidum	[8,11]
Lipoma of cerebral and cerebellar hemispheres	Hypoplasia, dysplasia, schizencephaly with malformed blood vessels within dysplastic areas	[7]
Dorsal brain stem lipoma	Not coexistent with corpus callosum lipomas	[4]
Lipoma of choroid plexuses (very rarely isolated)	Corpus callosum lipoma	[9]
Lipoma of tectal plate and cerebellum coexisting with hypoplasia of these structures	Tectocerebellar dysraphia	[12]
Interhemispheric lipoma	Upper lip cleft and polypos of facial skin - Pai syndrome	[10]
Posterior fossa lipomas	Dandy-Walker syndrome and Arnold Chiari malformation	[12,13]

spinal, cervical cord, respectively, considering the frequency of incidence. CNS lipomas are often found in more than one location (Table 1).

The exact etiology of lipomas remains uncertain. One of the theories point out the role of genetically determined disturbances of mechanisms controlling tissue differentiation. The early stage of neural tube differentiation is assumed to be the period of CNS lipoma formation [4].

Hence, a lipoma is often accompanied by other CNS pathologies (Table 1). Also a congenital cytomegalovirus infection is considered to be a potential cause of agenesis (ACC) and lipomas of the corpus callosum [5].

Diagnosing brain lipomas is nowadays possible in the prenatal period. However, many a time the diagnosis is made after a postnatal ultrasonography performed for other indications. Verification is based on nuclear magnetic resonance imaging (MRI), and in selected cases computed tomography (CT) may be needed. A confirmed presence of CNS lipoma is an indication for further diagnostics considering possible coexistence of other congenital defects.

Neurological symptoms that affect more than 50% of patients with CNS lipomas may appear at different age, but rarely in the neonatal period [1]. The presence of symptoms and their nature depend on the tumor size and location. The most common symptoms of CNS lipomas include seizures, impaired psycho-motor development, hormonal disturbances secondary to hypopituitarism and vision disturbances.

Surgery is undertaken very rarely and only in symptomatic cases. The decision on lipoma resection should take into account tumor location and its position relative to the surrounding tissue. Because of the nature of tumor growth, the aim of surgery is to decompress rather than to resect the tumor completely [1]. After surgery, histological verification of every removed lipoma is required. Although the risk of malignancy is very low, it should always be taken into account [6,7].

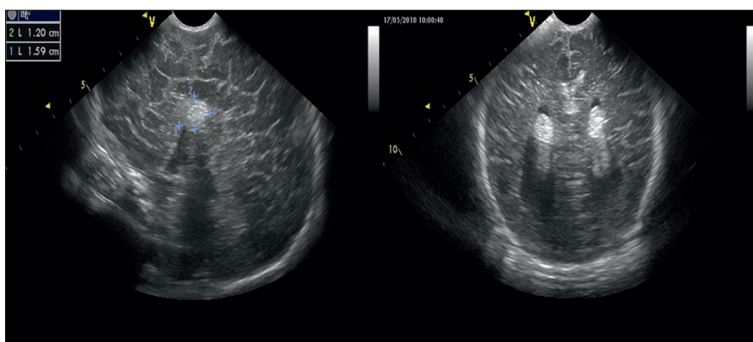
Widespread access to ultrasonography and an increasingly frequent use of USG in pregnancy and neonatal period (from various indications), enhanced the likelihood of an early CNS lipoma detection, even before the clinical manifestations, and enabled to arrange an appropriate specialist care for the baby. The aim of the study was to present recommendations for management (based on own experience) in case of a suspected CNS lipoma in a newborn, with particular emphasis on diagnostic imaging.

Cases Report

In the years 2007–2010 in the Neonatology, Neonatal Pathology and Intensive Care Clinic of the Children's Memorial Health Institute in Warsaw, 8 patients diagnosed with lipoma of the central nervous system were hospitalized (six patients with brain lipoma and two with extramedullary lipoma). Detailed characteristics of patients were presented in Table 2. Patients with brain lipoma were referred to the Clinic due to abnormalities in neonatal transfontanelle ultrasound imaging requiring further diagnostics. Only two cases of brain anomalies were detected with ultrasonography in the prenatal period, however relatively late (week 31 and 36 of pregnancy). In the postnatal ultrasound, the features of corpus callosum agenesis with coexistent midline hyperechogenic structure near corpus callosum prevailed (Figures 1, 2). Only in one case, the lesion was isolated (patient 5), whereas in other cases, similar hyperechogenic structures were reported also in lateral ventricles, in choroid plexuses (patient 1,2,3,4), in cingulate gyrus (patient 2) or in the frontal area (patient 4) (Figures 1–4). Ultrasound results correlated with images obtained in MRI. In case of patient 4, due to an ambiguous picture on MRI scans, suggesting a potential vascular anomaly, an additional angio-CT was performed, which excluded vascular malformation and confirmed corpus callosum agenesis with the presence of lipoma of the corpus callosum and additional lipomas in the right choroid plexus, roof of the third ventricle, and the medial right frontal lobe (Figure 4). Before angio-CT results, because of diagnostic doubt, the patient was consulted by an oncologist and tumor markers were determined (negative results).

Table 2. The characteristics of patients with nervous system lipomas.

	Sex	Weight (kg)	GA	Prenatal diag.	MRI	CT	Location	Corpus call.	Karyotype	Neurologic symptoms
1.	M	3.75	40	No	Yes	No	Within corpus callosum Bodies of lateral ventricle	Agenesis	No	Hypertonia of upper limbs
2.	M	3.10	40	No	Yes	No	Anterior part of corpus callosum Bodies of lateral ventricles Cingulate gyrus	Agenesis	No	Normal
3.	M	3.35	41	31 week	Yes	No	Anterior part of corpus callosum Bodies of lateral ventricles	Agenesis	No	Normal
4.	M	3.45	39	36 week	Yes	Yes	Medial part of the right frontal lobe; choroid plexus of the right lateral ventricle; third ventricle ceiling	Agenesis	Correct	Hypertonia of upper limbs
5.	F	2.80	39	No	No	Yes	Anterior part of corpus callosum	Agenesis	Trisomia 8	Hypertonia of lower limbs abnormal reflexes
6.	M	3.17	40	No	Yes	No	Two in peripontine cisterns in the area of trigeminal nerve and multiple intradural extramedullary in the dorsal part of spinal canal	Present, thinned	Correct	Axial hypotonia with limb hypertonia
7.	M	3.04	39	No	Yes	No	Spinal canal L1-L5, adjacent to spinal cord taper; developmental malformation of sacrum	Present	No	Normal
8.	F	2.60	37	No	Yes	No	Protruding into spinal canal at L5 level with tethering of spinal cord into lipoma and a linear layer of fat tissue along posteriori part of spinal cord.	Present	No	Normal

**Figure 1.** Lipoma of corpus callosum and choroid plexuses of the lateral ventricles – USG (patient 2).

In all patients, further assessment was carried out to exclude the coexistence of other congenital defects. The three patients with agenesis of the corpus callosum, and callosal lipoma did not have any other congenital defects or symptoms that would require genetic verification (patient 1,2,3). Patients 4, 5 and 6, because of coexisting defects and/or dysmorphic features were referred to genetic testing. In the physical examination of patient 5, characteristic dysmorphic features (microphthalmia, narrow palpebral fissures, recessed mandible) and the deep hand- and footprints

were noted. Further diagnostics showed no other developmental abnormalities. In neurological examination, the patient presented: hypertonia of the lower limbs, increased deep tendon reflexes, incomplete Moro reflex, excessive Galant reflex, a tendency for opisthotonus in Landau reflex. Trisomy of chromosome 8 was detected prenatally. Patient 6 was admitted to hospital due to multiple developmental malformations. Facial dysmorphia with hypertelorism, a number of lumps in the skin of the eyelids, hydrocephalic cranial bones, widely spaced nipples, hypospadias and

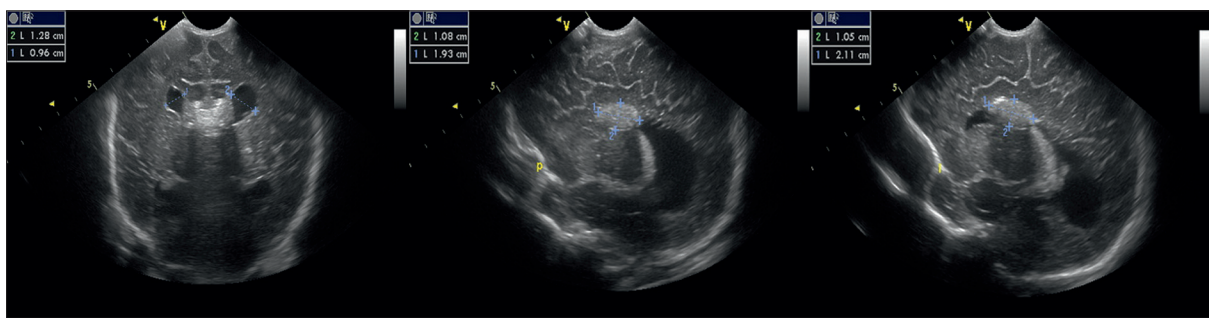


Figure 2. Corpus callosum lipoma – USG (patient 1).

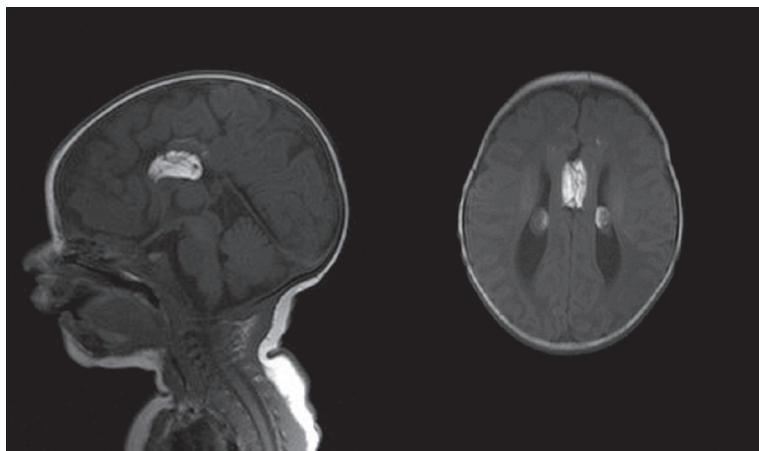


Figure 3. Corpus callosum lipoma and intraventricular lipomas – MRI scan (patient 2).

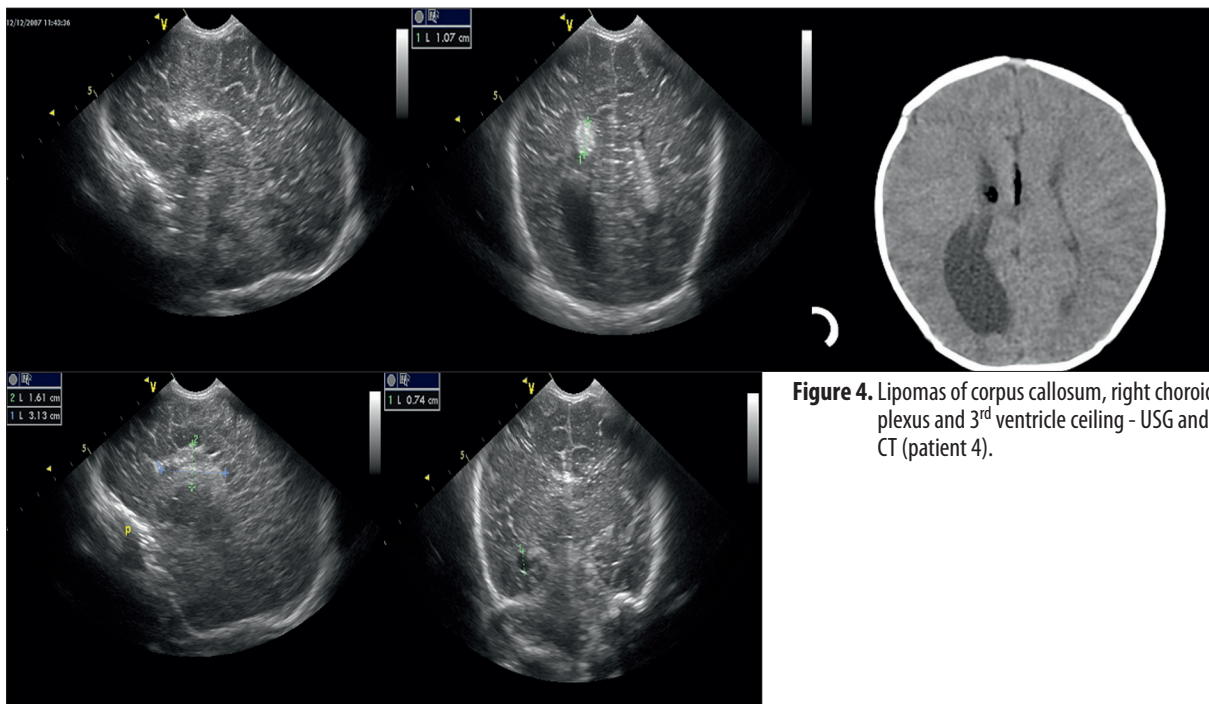


Figure 4. Lipomas of corpus callosum, right choroid plexus and 3rd ventricle ceiling - USG and CT (patient 4).

cardiac arrhythmia were observed. Brain ultrasonography also revealed features of hydrocephalus. In addition, cerebellar vermis hypoplasia was suspected and hyper-echogenic circumventricular areas were detected. Basing on ultrasonography, CNS lipomas were not suspected. MR of the brain and spinal cord was performed that revealed asymmetric hydrocephalus, the presence of developed, but

thinned corpus callosum, two lipomas in peripontine cisterns near the trigeminal nerve, multiple intradural-extramedullary lipomas in the dorsal part of the spinal canal, cord relocated and pressed against the anterior wall of the spinal canal (Figure 5). Based on the results of performed diagnostic examinations and clinical picture, the patient was finally diagnosed with encephalocraniocutaneous

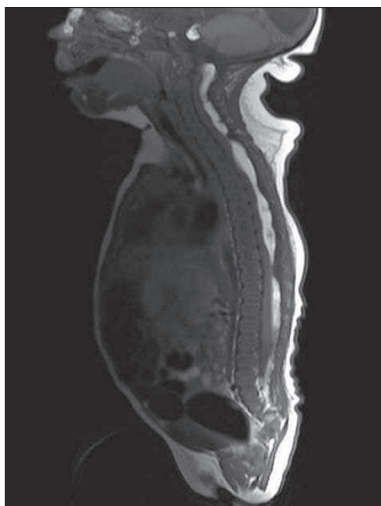


Figure 5. Multiple intradural, extramedullary lipomas in the dorsal part of the spinal canal (patient 6).

lipomatosis (ECCL), so called, Haberland syndrome. Because of the location of lipomas, the patient will likely manifest a neurological syndrome and will require neurological treatment, possibly even a neurosurgical intervention.

Two other patients were admitted to the clinic because of sacral region abnormality (soft, palpable tumor) detected in the physical examination. In these patients, it was decided to perform the MRI of the spinal cord without initial ultrasound diagnostics. Patient 7 had intrathecal lipoma, adjacent to the spinal cord taper and developmental defect of the sacrum (Figure 6). In patient 8, MRI revealed extrathecal lipoma protruding into the spinal canal, with cord tethering inside the lipoma and a linear layer of fat tissue alongside the posterior cord.

Discussion

According to our knowledge and observation, central nervous system lipomas constitute a very rare diagnostic and therapeutic problem. The ratio of patients with CNS lipoma hospitalized in our clinic was 0.21, which undoubtedly is a high result as compared to the incidence in general population, which is of course associated with specialization of our clinic. Among the presented patients, male gender predominated (75%), which correlates with data reported by others [8].

Among CNS lipomas the most frequent are the lipomas of the corpus callosum, coexisting with corpus callosum hypogenesis/agenesis. It was also confirmed in our observation (62.5% – 5 patients with corpus callosum agenesis and lipomas). In our study, relatively frequently (in 4 out of 6 patients) lipomas of corpus callosum coexisted with lipomas in choroid plexuses. Similarly, Sener et al. reported that isolated choroid plexus lipomas occur extremely rarely (9). In case of interhemispheric location with coexisting cleft of the upper lip and polyps of the facial skin, the patient is diagnosed with Pai syndrome [10]. However, in our patient, no additional abnormalities were observed.

Corpus callosum agenesis was not difficult to diagnose due to its characteristic features in transfontanelle USG.

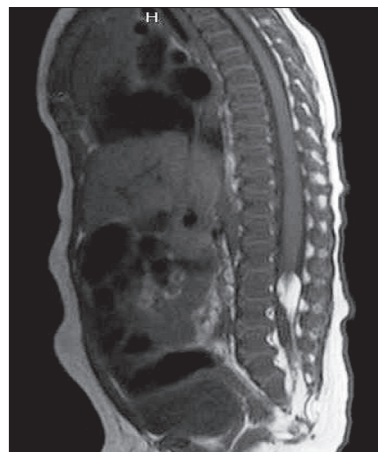


Figure 6. Spinal canal lipoma at L1-L5 level, adjacent directly to the spinal cord taper (patient 7).

However, the presence of an additional hyperechogenic lesion without vascular flows suggests corpus callosum lipoma. Small lipomas, located outside the corpus callosum, particularly in the posterior cranial fossa, are much more difficult to detect in transfontanelle ultrasonography. MRI is recommended for a final verification of the diagnosis and more comprehensive assessment of the brain regarding additional congenital malformations. Except for one case (patient 5), in which only CT was possible to perform, each of patients had brain MRI during spontaneous sleep. However, in one case (patient 4), because of the detected vascular structures of the lesion found in the area of hypoplastic corpus callosum, CT angiography was performed additionally, to exclude vascular malformations. Based on the analysis of 8 presented cases of neonates with CNS lipomas, it should be noted that MRI allows for obtaining a much more accurate image of midline structures, with a precise assessment of the corpus callosum. MRI in newborns can be performed in spontaneous sleep with no need for general anesthesia and without exposing the child to the X-rays. Thus, the use of CT in suspected CNS lipomas is limited only to situations in which the MRI is equivocal. Similar conclusions also appear in reports by other authors [1,3].

Since TORCH infection may lead to CNS malformations, serological testing, and in some cases, additional PCR were performed in our patients (except for one patient with spinal cord lipoma) to exclude congenital cytomegalovirus and *Toxoplasma gondii* infection. There is a theory indicating a relationship between corpus callosum pathology and CMV neuroinfection [5]. However, no such link was found among our patients, which contradicts the above hypothesis. An additional argument may be that over many years, none of the patients hospitalized in our clinic due to cytomegalovirus neuroinfection had lesions suggestive of CNS lipoma.

In two of the presented patients, CNS abnormalities had been previously suspected during the prenatal period, but not before week 30 of pregnancy. This seems to confirm the observations of other authors that CNS tumors in prenatal ultrasound are diagnosed relatively late because of the period of their formation/grow [2]. However, this contradicts the theory of brain lipoma formation in early embryogenesis.

Due to the detected brain developmental pathology, it is recommended to perform diagnostics towards other congenital defects, as well as to provide continuous neurological care and observation of psychomotor development [1]. All presented patients were diagnosed for other congenital defects. Only in two newborns (patients 5 and 6), genetic abnormalities were found: trisomy of 8 chromosome in one case and Haberland syndrome in the other.

During hospitalization, four out of six patients with cerebral lipomas (66%) manifested neurological abnormalities in the neonatal period. However, these were predominantly mild disturbances in the distribution of muscle tension. None of the patients had seizures. Although, in the patient with encephalocraniocutaneous lipomatosis (ECCL) due to the lipoma location, symptoms of compression of n. V and spinal cord can be expected in the future. All patients remain under neurological care and their psychomotor development is monitored in their local clinics. Apart from the delay in speech development in the patient with encephalocraniocutaneous lipomatosis, a normal psychomotor development is observed in all other children. As for now, the follow-up period is relatively short and amounts to 1–4 years, depending on the case.

References:

1. Strzyżewski K, Hauber Z, Jarmusz K et al: Tuszczaki mózgu u dzieci. Rzadko występujące guzy centralnego układu nerwowego. *Neuroskop*, 2004; 6: 77–82 [in Polish]
2. Respondek-Liberska M: Nowotwory ośrodkowego układu nerwowego u płodu. *Aktualności Neurologiczne*, 2009; 9: 164–82 [in Polish]
3. Tagliatalata G, Galasso R, Tagliatalata G et al: Lipoma of corpus callosum. *Neuroanatomy*, 2009; 8: 39–42
4. Catala M, Lazareth JP, Coquille F et al: Dorsal mesencephalic lipoma with inferior collicular hypoplasia: a case report and review of literature. *Clin Neurol Neurosurg*, 1997; 99(4): 271–75
5. Mehta NM, Hartnoll G: Congenital CMV with callosal lipoma and agenesis. *Pediatric Neurology*, 2001; 24(3): 222–24
6. Sasaki H, Yoshida K, Wakamoto H et al: Lipomas of the frontal lobe. *Clin Neurol Neurosurg*, 1996; 98(1): 27–31
7. Ahmeto A, Aynaci F, Ahmet Sari A: Sylvian fissure lipoma associated with cortical dysplasia and abnormal vascularity. *European Journal of Radiology Extra*, 2003; 46(2): 43–46
8. Kurt G, Dogulu F, Kaymaz M et al: Hypothalamic lipoma adjacent to mammillary bodies. *Child's Nervous System*, 2002; 18(12): 732–34
9. Sener RN: Isolated choroid plexus lipomas. *Computerized Medical Imaging Graphics*, 1995; 19(5): 423–26
10. Al-Mazrou KA, Al-Rekabi A, Alorainy IA et al: Pai syndrome: a report of a case and review of the literature. *Int J Pediatr Otorhinolaryngol*, 2001; 61(2): 149–53
11. Toshiki T, Kenzo H, Hitoshi T: Corpus callosum lipoma and complex partial seizures. *Brain and Development*, 1995; 17(5): 365–66
12. Dehdashti AR, Abouzeid H, Momjian S: Occipital extra- and intracranial lipoencephalocoele associated with tectocelebellar dysraphia. *Childs Nerv Syst*, 2004; 20(4): 225–28; discussion 229–38
13. Kai Y, Amano T, Inamura T et al: An infant with an intradural lipoma of the cervical spine extending into the posterior fossa. *J Clin Neurosci*, 2003; 10(1): 127–30

It should be noted that due to the location of lipomas, patient 6 will probably present with neurological symptoms and require treatment or even neurosurgical intervention in the future.

Conclusions

The diagnosis of cerebral lipoma can be made with high probability basing on transfontanelle ultrasonography (especially in the case of lipomas of the corpus callosum). However, final diagnosis should be confirmed in MRI. In case of spinal canal lipomas, MRI is the method of choice. Brain CT should be reserved only for cases of doubt, due to high radiation dose and less precision in the assessment of the corpus callosum.

Considering the fact of coexistence of different congenital defects along with brain lipomas, it is recommended to perform appropriate diagnostic procedures, provide parents with comprehensive information on the diagnosis and on the need for continuous monitoring of child's development and adequate pediatric and neurological care.

Neurosurgical intervention is needed in exceptional cases, in patients manifesting compression symptoms.