




# Endocapsular artificial iris implantation for iris defects: Reducing symptoms, restoring visual function and improving cosmesis

Alexandra Z. Crawford MD, FRANZCO<sup>1,2</sup> | Simone E. N. Freundlich MBChB<sup>1,2</sup>  |  
Joevy Lim MBChB<sup>1,2</sup>  | Charles N. J. McGhee DSc FRCOphth<sup>1,2,3</sup> 

<sup>1</sup>Department of Ophthalmology, New Zealand National Eye Centre, Faculty of Medical and Health Sciences, The University of Auckland, Auckland, New Zealand

<sup>2</sup>Department of Ophthalmology, Greenlane Clinical Centre, Auckland District Health Board, Auckland, New Zealand

<sup>3</sup>Eye Institute, Auckland, New Zealand

## Correspondence

Charles N. J. McGhee, Department of Ophthalmology, The University of Auckland, Auckland, New Zealand.  
Email: [c.mcgee@auckland.ac.nz](mailto:c.mcgee@auckland.ac.nz)

## Funding information

Dr Simone E. N. Freundlich was funded by a Maurice and Phyllis Paykel Trust unrestricted Corneal Research fellowship in Ophthalmology. Dr Joevy Lim was funded by an unrestricted University of Auckland Doctoral Scholarship and a Joan Ready Ophthalmology Futures Research Scholarship.

## Abstract

**Background:** To investigate repair of iris defects by endocapsular implantation of an artificial iris, in relation to visual outcomes, safety profile and patient satisfaction.

**Methods:** Retrospective, consecutive case series from Greenlane tertiary teaching hospital and Eye Institute, Auckland, New Zealand. Medical records of patients implanted with an endocapsular artificial iris were reviewed and followed for minimum 3 months. Patient characteristics, surgical management, clinical outcomes and subjective responses were recorded.

**Results:** Nineteen artificial irises were implanted in 18 patients. Etiologies were iris melanotic lesion excision (73.7%), trauma (10.5%), congenital aniridia (10.5%) and Urrets-Zavalía syndrome (5.3%). During postoperative follow-up [ $14.1 \pm 12.4$  months (range: 3 to 59 months)], best corrected visual acuity (BCVA) and intraocular pressure (IOP) did not change significantly [BCVA, 0.23 logarithm of the minimum angle of resolution (logMAR) (20/32 Snellen) preoperatively vs. 0.18 logMAR postoperatively (20/25 Snellen) ( $Z = -0.222$ ,  $p = 0.824$ ); IOP, 15 mmHg preoperatively vs. 17 mmHg postoperatively ( $Z = 1.377$ ,  $p = 0.1447$ )]. Mild or self-limiting complications included: elevated IOP (42.1%), cystoid macular oedema (15.8%); persisting postoperative uveitis (15.8%) and minor vaulting of the prosthesis (15.7%). Moderate or severe complications included significant vaulting of prosthesis requiring surgical revision (5.3%) and a single eye (5.3%) with trabeculectomy and corneal graft failure. 94.4% of patients were very satisfied with the cosmesis and would be highly likely to have the procedure again.

**Conclusions:** This study confirms that endocapsular insertion of an artificial iris is typically associated with good functional and cosmetic results and a relatively low risk of significant complications.

This is an open access article under the terms of the [Creative Commons Attribution-NonCommercial-NoDerivs](https://creativecommons.org/licenses/by-nc-nd/4.0/) License, which permits use and distribution in any medium, provided the original work is properly cited, the use is non-commercial and no modifications or adaptations are made.

© 2022 The Authors. *Clinical & Experimental Ophthalmology* published by John Wiley & Sons Australia, Ltd on behalf of Royal Australian and New Zealand College of Ophthalmologists.

**KEYWORDS**

artificial endocapsular iris implant, artificial iris, iris colour, iris defect, iris melanoma

## 1 | INTRODUCTION

Patients with iris defects report significant functional visual impairment and cosmetic disfigurement.<sup>1</sup> The iris has important optical functions such as modulating light and accommodative miosis. Compromise or loss of these functions may result in visual disturbances such as photophobia, glare, difficulty reading, altered contrast sensitivity and increased higher-order aberrations.<sup>2</sup> Furthermore, the appearance of the eyes is central to how we distinguish and interpret human faces, and eyes have an important role in conveying social cues such as direction of gaze and emotion.<sup>3</sup> The human gaze is highly sensitive to subtle alterations in eye appearance,<sup>4</sup> and perceived abnormalities may result in social stigma and a negative psychological impact.<sup>5</sup>

The modern armamentarium for the treatment of iris defects includes cosmetic contact lenses, focal corneal tattoos, direct iris suturing/pupilloplasty, partial aniridia segment ring (with or without pupilloplasty) or full artificial iris implants.<sup>6</sup> The current study considered the HumanOptics CustomFlex<sup>®</sup> Artificial Iris (HumanOptics, Erlangen, Germany) which is a customised, flexible silicone iris prosthesis and is currently the only US food and Drug Administration (FDA) approved intraocular iris prosthesis. While several early studies have published encouraging functional and cosmetic results,<sup>1,2,7,8</sup> these devices have been associated with a wide spectrum of postoperative complications such as elevated intraocular pressure (IOP), recurrent bleeding, capsular fibrosis, corneal decompensation, cystoid macular oedema (CMO), iris device dislocation and retinal detachment.<sup>1,2,7,8</sup> However, these complications must be interpreted in the context of the high prevalence of pre-existing ocular comorbidities that frequently occur in concert with acquired iris defects.<sup>8</sup> A significant learning curve is also observed with this device, and this approach is not recommended in low volume settings.<sup>9</sup>

The method of device fixation exhibits a gradient of complexity with scleral suture fixation techniques being significantly more challenging than implantation into the sulcus or capsular bag.<sup>6</sup> Moreover, eyes with intact capsular support are inherently likely to have less ocular comorbidity compared with eyes with a disorganised anterior segment requiring suture fixation techniques. Early reports suggest that endocapsular device fixation techniques may be associated with fewer complications than other device fixation techniques, though data on

larger numbers are lacking.<sup>1,8</sup> Indeed, it has been postulated that the intraoperative and postoperative complications after endocapsular techniques may be comparable to those in standard intraocular lens (IOL) implantation.<sup>1</sup> Our centre provides a tertiary service for anterior segment trauma and anterior segment ocular tumours, specifically iris and ciliary body tumours.<sup>10</sup> Our team is therefore regularly involved in all aspects of iris reconstruction. Here we report the results of, to our knowledge, the largest consecutive series to date of endocapsular placement of the HumanOptics CustomFlex<sup>®</sup> Artificial Iris.

## 2 | METHODS

Nineteen silicone iris prostheses (HumanOptics CustomFlex<sup>®</sup> artificial iris) were implanted in the capsular bag together with an IOL in combination with crystalline lens extraction between November 2016 and April 2021. All procedures were performed by a single senior cornea and anterior segment sub-specialist at either Eye Institute, Auckland or at the Ophthalmology Department, Greenlane Clinical Centre, Auckland District Health Board, New Zealand.

Patient characteristics, surgical management and clinical outcomes associated with the implantation procedure or the implant itself were investigated for all patients with a follow-up time of at least 3 months to a maximum of 5 years.

To be eligible for an artificial iris, patients had to be 18 years or older, and have a significant iris defect with an associated visual and/or cosmetic disturbance that was not amenable to correction with nonsurgical options. Patients under the age of 50 were specifically counselled about the loss of accommodation following crystalline lens extraction. The silicone prosthetic iris was customised for each patient based on a photograph of the healthy iris of the fellow eye. One patient had congenital aniridia and the iris prosthesis was modelled on a photograph of her father's eyes.

This retrospective, interventional, non-randomised, consecutive series was conducted according to the tenets of the Declaration of Helsinki, and approval by the Institutional Review Board was obtained from the Auckland Health Research Ethics Committee (reference number AH22023).

## 2.1 | IOL power calculation

Biometry measurements were obtained using a Lenstar LS900 (Haag-Streit, Bern, Switzerland) or IOL Master 500 (Carl Zeiss Meditec AG, Jena, Germany). Lens power calculation was performed using the Barrett Universal II formula. A low myopic target of  $\sim -0.50\text{D}$  was chosen to offset the small hyperopic refractive shift anticipated from the posterior displacement, within the capsular bag, of the IOL by the overlying artificial iris.

## 2.2 | Surgical technique

All surgeries were performed under general anaesthesia. A standard cataract extraction/lensectomy was performed using a minimum incision size of 2.8 mm. The capsular bag was stained with 0.06% trypan blue ophthalmic solution (VisionBlue, Dutch Ophthalmic Research Company) to enhance visualisation of the capsule during device insertion. A moderately larger diameter capsulorhexis ( $\sim 5.50\text{--}6.00\text{ mm}$ ) was performed to facilitate manipulation of the iris prosthesis into the capsular bag. Initially, a capsular tension ring (CTR) was only placed in eyes with suspected zonular weakness, however, from January 2020 a CTR was routinely placed in all eyes to minimise postoperative capsule shrinkage and potential displacement of the prosthesis. The IOL [SA60AT IOL implant (Alcon Laboratories Inc., Fort Worth, TX)] was always implanted into the capsular bag after the CTR and prior to the insertion of the artificial iris. A sutured capsular tension segment (Morcher GmbH Type 6E) was also placed in one eye with a background of severe trauma and extensive zonular loss.

Sizing of the device was performed according to the manufacturer's instructions; the diameter of the evacuated capsular bag minus 0.5 mm. Trephination was performed using a manual corneal trephine on a flat surface cutting block. Fibre-free iris devices were used in all cases. The device was inserted into the capsular bag either with forceps<sup>11</sup> or tri-folded into a cartridge and injected using the AccuJect injector (HumanOptics, AG). The prosthesis was inserted anterior to the IOL.

## 2.3 | Postoperative management

Routine postoperative treatment consisted of chloramphenicol 0.5% ophthalmic solution administered four times per day for 2 weeks and prednisolone acetate 1% ophthalmic suspension administered four times per day for 1 month. Three doses of oral acetazolamide 250 mg were routinely administered in the first 24 h postoperatively. Glaucoma

treatment drops were continued or added, if necessary, based on IOP measurements.

## 2.4 | Data collection

Data recorded included demographic information, the preoperative state of the eye including the status of the cornea, lens and posterior segment and surgical details. Postoperative follow-up examinations were conducted at 1 day, 1 week and 1, 3, 6, and 12 months after surgery. Additional appointments were scheduled as required. Best corrected visual acuity (BCVA, Snellen chart) and IOP were recorded at each visit.

Safety measures included loss of BCVA, IOP elevations, intraoperative and postoperative complications and secondary surgical interventions. Postoperative IOP elevation was defined as an IOP  $\geq 24\text{ mmHg}$ . Unexpected events and complications during the postoperative period were grouped into "none" (uneventful postoperative course), "mild" (unexpected events requiring non-invasive intervention with full recovery), "moderate" (unexpected events requiring invasive intervention with full recovery), and "severe" (unexpected or expected events without full recovery).<sup>9</sup>

Patients with prior iris excision for iris melanoma underwent on-going surveillance for tumour recurrence. Placement of the artificial iris device within the capsular bag provided on-going visual access to the angle, residual iris, ciliary processes and ciliary body (Figure 1).

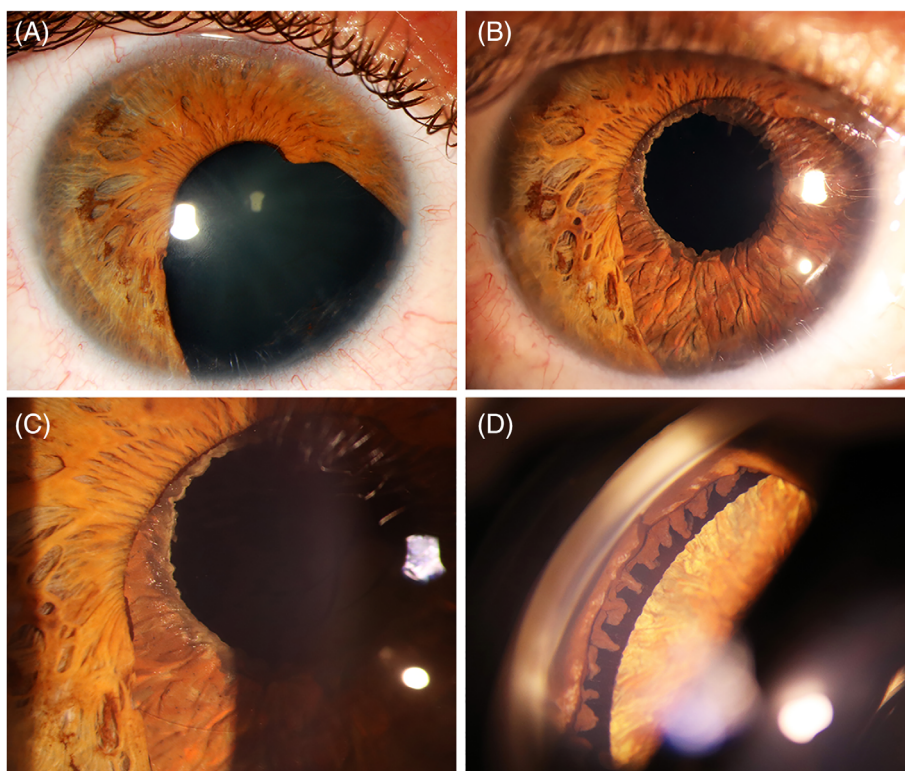
Subjective measurements were assessed using a questionnaire. Subjective improvement in daytime glare was assessed by asking patients to rate their postoperative symptoms on a scale of 0 (no improvement) to 5 (very significant). Postoperative cosmesis and visual acuity were graded on a scale of 0 (very dissatisfied) to 5 (very satisfied). Patients were asked to rate whether they would have the surgery again on a scale from 0 (never) to 5 (highly likely).

## 2.5 | Statistical analysis

Statistical analysis was conducted on SPSS software version 22. Sample characteristics are presented using numbers ( $n$ ) and percentages for categorical variables; and means and  $SD$  or median and interquartile range (IQR) for continuous variables, as appropriate. The Shapiro-Wilk test was used to test for normality. The Shapiro-Wilk test showed non normal distribution of the BCVA and IOP data. Therefore, the Wilcoxon signed rank test was used to compare the preoperative and postoperative BCVA and IOP data. Statistical significance was set as a  $p$ -value  $< 0.05$ .



**FIGURE 1** The right eye of a single patient. (A) A large iris defect following excision and radiotherapy for a large iris melanoma. (B) Appearance following phacoemulsification surgery with insertion of an IOL and an endocapsular customised artificial iris. (C) Juxtaposition of natural iris and the endocapsular artificial iris at higher power. (D) Gonioscopy for on-going surveillance showing periphery of the artificial iris with a clear view of the residual iris root and the ciliary processes



### 3 | RESULTS

#### 3.1 | Patient characteristics

A total of 19 artificial irises were implanted in 18 patients. Average duration of follow up was  $14.1 \pm 12.4$  months (range: 3 to 59 months). Patient demographics and descriptive data are provided in Table 1. Mean preoperative BCVA using logarithm of the minimum angle of resolution (logMAR) units was  $0.23 \pm 0.25$  LogMAR (range  $-0.1$  to  $0.7$  LogMAR), equivalent to 20/32 Snellen. Mean preoperative IOP was  $15.4 \pm 3.5$  mmHg (range 10 to 22 mmHg).

#### 3.2 | Surgical details

Surgical information is summarised in Table 2.

#### 3.3 | Outcomes

Postoperative details and safety outcomes are summarised in Table 3. By the final postoperative examination, BCVA improved in 8 eyes (42.1%), was unchanged in 10 eyes (52.6%), and decreased in 1 eye (5.3%). The average change in BCVA was  $-0.05 \pm 0.26$  logMAR (range  $-0.6$  to  $0.8$  logMAR). There was no statistically significant difference in preoperative and postoperative BCVA ( $Z = -0.222$ ,  $p = 0.824$ ). The median BCVA pre-op was 0.23 logMAR

(20/32 Snellen) and postop was 0.18 logMAR (20/25 Snellen). There was no significant difference in IOP before surgery (mean preoperative IOP 15.3 mmHg) and after artificial iris implantation (mean postoperative IOP 17.2 mmHg) ( $Z = 1.377$ ,  $p = 0.1447$ ).

Most of the postoperative safety events encountered were monophasic and treatable. Minor complications occurred in 12 patients (63.2%). The most common postoperative complication was a temporary elevation in IOP ( $n = 8$ , 42.1%) that was successfully managed with medical therapy [6 eyes (31.6%) exhibited a day 1 postoperative pressure spike, whereas 5 eyes (26.3%) had a hypertensive steroid response]. Other than subjects who were prescribed antihypertensive treatment for glaucoma preoperatively, no subject required long term ocular antihypertensive treatment postoperatively.

Other minor complications included transient CMO ( $n = 3$ , 15.8%) and transient postoperative low-grade uveitis ( $n = 3$ , 15.8%). The cases of uveitis were mild and medically controlled by increasing and then slowly tapering the topical corticosteroid regimen. Of the three eyes (15.8%) that developed CMO, two occurred in the immediate postoperative period ( $<6$  weeks), and one occurred at 5 months following surgical revision of the artificial iris (see below). The final BCVA in these cases of CMO was 20/25 in two eyes and 20/20 in one eye.

Vaulting of the artificial iris prosthesis was observed in four eyes (21.1%), with the majority developing only minor vaulting. Only one of these four eyes had a CTR



TABLE 1 Patient demographics and descriptive data

Number of patients ( <i>n</i> = 18)	
Age (years)	50.8 ± 18.5 (range: 18 to 83)
Gender	
Male	6 (33.3%)
Female	12 (66.6%)
Number of eyes ( <i>n</i> = 19)	
Eye colour	
Blue	14 (73.7%)
Green	1 (5.3%)
Brown	2 (10.5%)
Aniridic	2 (10.5%)
Eye side	
Right	8 (42.1%)
Left	11 (57.9%)
Iris defect	
Iris lesion excision <sup>a</sup>	14 (73.7%)
Iris melanoma	8 (57.1%)
Melanocytic lesion of uncertain malignant potential	4 (28.6%)
Benign iris naevus	2 (14.3%)
Trauma	2 (10.5%)
Congenital (aniridia)	2 (10.5%)
Urrets-Zavalía	1 (5.3%)
Ocular co-morbidities	
Previous IOP elevation	5 (26.3%)
POAG	1 (20%)
Secondary glaucoma <sup>b</sup>	3 (60%)
Previous trabeculectomy	1 (20%)
Steroid responder <sup>c</sup>	2 (40%)
Pre-existing corneal pathology	3 (15.8%)
Limbal stem cell deficiency	2 (10.5%)
Fuchs endothelial dystrophy with previous DSAEK	1 (5.3%)
Foveal hypoplasia	2 (10.5%)
Lens status	
Clear lens	5 (26.3%)
Lens opacity	14 (73.7%)

Abbreviations: DSAEK, Descemet's stripping automated endothelial keratoplasty; IOP, intraocular pressure; POAG, primary open angle glaucoma.

<sup>a</sup>Average interval between iris excision and artificial iris implantation was 9.7 months (range: 5 to 24 months).

<sup>b</sup>Secondary glaucoma was related to iris melanoma in two eyes, and chronic inflammation in one eye with a complex ocular history including Fuchs endothelial dystrophy and a previous endothelial keratoplasty. This latter eye had previously undergone a trabeculectomy.

<sup>c</sup>Both steroid responders were detected in the postoperative period following the excision of the iris melanoma.

inserted at the time of surgery. Minor antero- or retro-vaulting of the prosthesis was only visible with slit-lamp biomicroscopy, did not affect pupillary or iris alignment, nor the close relationship of the artificial iris to the anterior IOL surface, within in the capsular bag. This phenomenon was presumed to relate to the relative size of the artificial iris and compressive forces within the capsular bag on the artificial iris and IOL complex. Significant vaulting in one case caused elevation of the artificial iris, creating a 1 mm gap between the posterior iris surface and anterior IOL surface, with displacement of the iris and pupil within the capsular bag. Significant vaulting necessitating surgical revision occurred in this one eye (no CTR). A triangular wedge of artificial iris was excised and a 'pupilloplasty' was performed to reapproximate the cut edges of artificial iris with a 9/0 prolene suture—restoring shape and position.

Only one eye in this series experienced severe postoperative complications with a decline in vision. This eye developed an inflamed and scarred trabeculectomy site in the postoperative period and required bleb needling and mitomycin C injections to control an increased IOP. The eye, which had a compromised DSAEK prior to surgery, subsequently developed corneal endothelial graft failure presumed secondary to poor IOP control. Minor vaulting of the prosthesis was also observed (as noted in previous paragraph). This eye, unlike others in this study, had a complex ocular history prior to surgery including previous inflammation, Fuchs endothelial dystrophy, DSAEK and secondary glaucoma. It is therefore difficult to ascertain the extent to which the artificial iris implantation may have influenced the outcome of the trabeculectomy. The subject awaits a repeat endothelial keratoplasty.

An area of conjunctival pigmentation developed adjacent to the original iris excision site in an eye that had previously undergone excision for iris melanoma. A conjunctival biopsy was performed, and histology identified recurrent iridociliary spindle cell melanoma extending through the sclera to the conjunctiva. The patient subsequently underwent plaque radiotherapy with complete resolution of disease at latest follow-up.

During the follow-up period, posterior capsular opacification (PCO) treated with laser-assisted capsulotomy occurred in 2 eyes (10.5%), at 4 and 30 months, respectively. Anterior capsular fibrosis was minimal and had minimal effect on the iris appearance in this series. Figure 2 provides two illustrative images of the capsule and iris prosthesis 4 years post-surgery.

Complete subjective qualitative data was obtained for 17 of the 19 eyes. One patient returned incomplete data (subjective cosmesis and likelihood of having the surgery again) and one patient declined to provide subjective data. The cosmesis score was recorded as '5' (very



TABLE 2 Surgical details and accompanying procedures

Eye	Size (mm)	Mode of insertion	IOL power	CTR	Accompanying procedures	Comments
1	10	Injected	24	No	No	No
2	10	Injected	17	No	No	No
3	10	Injected	22	No	No	No
4	10	Injected	23.5	14C	No	Zonular loss <sup>a</sup>
5	10	Injected	26	No	No	No
6	10	Manual	25	No	No	No
7	10	Injected	18.5	No	No	No
8	10	Manual	22	No	No	No
9	10.5	Injected	21.5	No	No	No
10	10	Injected	24.5	14C	No	No
11	9.75	Manual secondary insertion <sup>b</sup>	23.5	No	No	Failed injection with reinsertion
12	9.75	Manual	23	No	No	No
13	10	Injected	18	14C	5-FU to bleb, synechiolysis	Pre-existing extensive PAS
14	10	Injected	23.5	14C	No	No
15	10	Injected	24.5	14C	No	No
16	10	Injected	21.5	14C	sCTR	No
17	10	Injected	25	14C	No	No
18	10	Injected	24	14C	No	No
19	9.75	Injected	28	14C	No	No

Abbreviations: 14C, Morcher Type 14C; CTR, capsular tension ring; sCTR, sutured capsular tension segment Morcher GmbH Type 6E; Size, iris trephination size.

<sup>a</sup>Zonular weakness corresponding to the previous area of iris excision was noted intraoperatively during cataract extraction.

<sup>b</sup>Failed injection converted to manual insertion.

satisfied) by 94.4% ( $n = 17$ ) of responding participants, with one participant (5.5%) recording a '4'. The mean postoperative subjective visual acuity score was 4.3 (range: 1 to 5) and the mean postoperative subjective improvement in glare was 4.5 (range: 2 to 5). Two patients returned both a subjective visual acuity and glare score  $\leq 3$ , and one patient returned a subjective visual acuity  $\leq 3$ . All three of these patients were pre-presbyopic prior to surgery and the effect on near vision may have influenced their perception. Notably, final distance BCVA was 20/25 in two of these eyes and 20/16 in the other. Seventeen patients (94.4%) recorded a score of '5' indicating that they would be highly likely to have the same surgery again, and one patient (5.5%) recorded a '4'.

## 4 | DISCUSSION

The surgical reconstruction of eyes with iris defects is typically challenging.<sup>6</sup> The encouraging functional and

cosmetic outcomes offered by customised, flexible, artificial irises are tempered by the potential difficulties of device insertion and the profile of postoperative complications. However, the endocapsular mode of device implantation may beneficially influence the burden of postoperative complications.<sup>9</sup> Endocapsular device insertion has comprised a relatively small number of cases reported in previous studies exploring the outcomes of artificial iris devices. We believe this study, involving a total of 19 eyes, is the largest consecutive series of endocapsular placement of the HumanOptics CustomFlex<sup>®</sup> Artificial Iris.

Previous studies have reported a high burden (14.7% to 25.5%) of severe postoperative complications such as retinal detachment, corneal decompensation, glaucoma, synechiae, and device dislocation.<sup>7-9</sup>

Endocapsular device insertion has been hypothesised to be associated with a lower complication rate compared with other implantation techniques for several reasons: the technique is simpler and avoids the need for scleral suture placement; it represents a natural extension of a cataract

TABLE 3 Postoperative details and safety outcomes

Eyes	Indication	BCVA (LOGMAR)			Postoperative complications					
		Preoperative	Postoperative	$\Delta$ BCVA	IOP	CMO	Prosthesis	Uveitis	PCO	CD <sup>a</sup>
1	Iris melanoma	0.1	0.10	0.00	IOP 1,2	No	No	No	No	No
2	Iris melanoma	0	0.00	0.00	No	No	No	No	No	No
3	Iris melanoma	0.2	0.20	0.00	No	No	No	No	No	No
4	Iris naevus	0.1	0.10	0.00	IOP 1	No	No	Mild	No	No
5	Iris naevus	0.2	0.10	-0.10	IOP 1	CMO 1	No	No	No	No
6	Iris melanoma	0.3	0.10	-0.20	IOP 2	No	No	No	No	No
7	Iris melanoma	0.2	0.10	-0.10	IOP 1,2	CMO 2	No	Mild	No	No
8	Iris melanoma	0	0.00	0.00	IOP 2	No	No	No	No	No
9	Iris naevus	0	0.00	0.00	No	CMO 3	Vault <sup>b</sup>	No	No	No
10	Trauma	0	0.00	0.00	IOP 1	No	No	No	No	No
11	Aniridia	0.6	0.50	-0.10	No	No	Slight vault	No	No	No
12	Aniridia	0.70	0.50	-0.20	No	No	Slight vault	No	YAG	No
13	Urrets-Zavalía	0.50	1.30	0.80	IOP 3	No	Slight vault	No	No	Yes
14	Iris melanoma	0.30	0.30	0.00	No	No	No	No	No	No
15	Iris melanoma	-0.10	-0.10	0.00	No	No	No	No	No	No
16	Trauma	0.70	0.10	-0.60	No	No	No	No	YAG	No
17	Iris melanoma	0.30	0.00	-0.30	No	No	No	Mild	No	No
18	Iris melanoma	0.00	0.00	0.00	No	No	No	No	No	No
19	Iris melanoma	-0.10	0.10	-0.20	IOP 1,2	No	No	No	No	No

Abbreviations: BCVA, best corrected visual acuity; CMO 1, cystoid macular oedema resolved with topical drops; CMO 2, recurrent and recalcitrant CMO resolved with oral prednisone and intravitreal triamcinolone; CMO 3, recurrent CMO resolved with topical drops; CMO, cystoid macular oedema; IOP 1, postoperative day 1 elevation in intraocular pressure; IOP 2, steroid response elevation in intraocular pressure; IOP 3, pre-existing glaucoma with previous trabeculectomy; IOP, intraocular pressure; PCO, posterior capsular opacification; YAG, Yttrium aluminium garnet (YAG) capsulotomy performed, retraction.

<sup>a</sup>CD, corneal decompensation (occurred in eye with DSAEK and pre-existing corneal compromise).

<sup>b</sup>Posterior retraction of the device requiring wedge excision of the prosthesis.

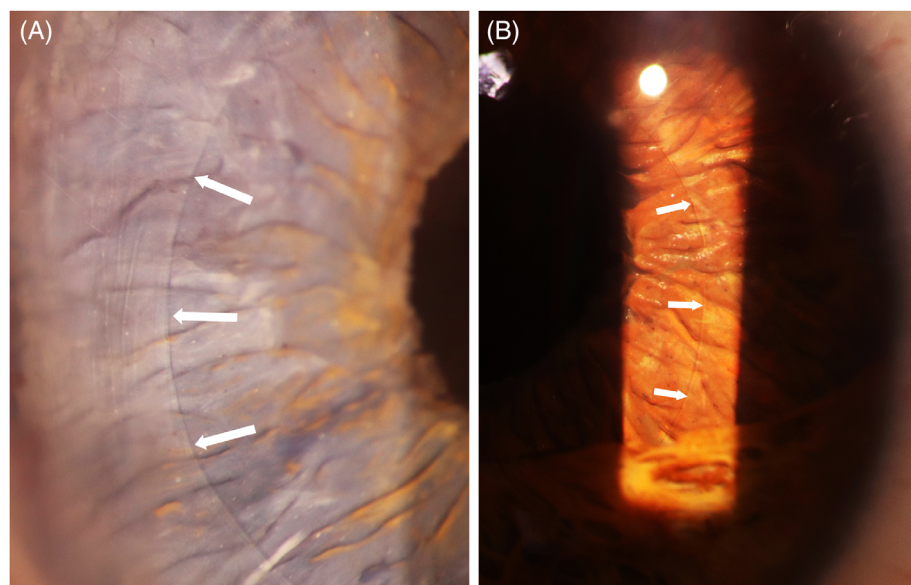
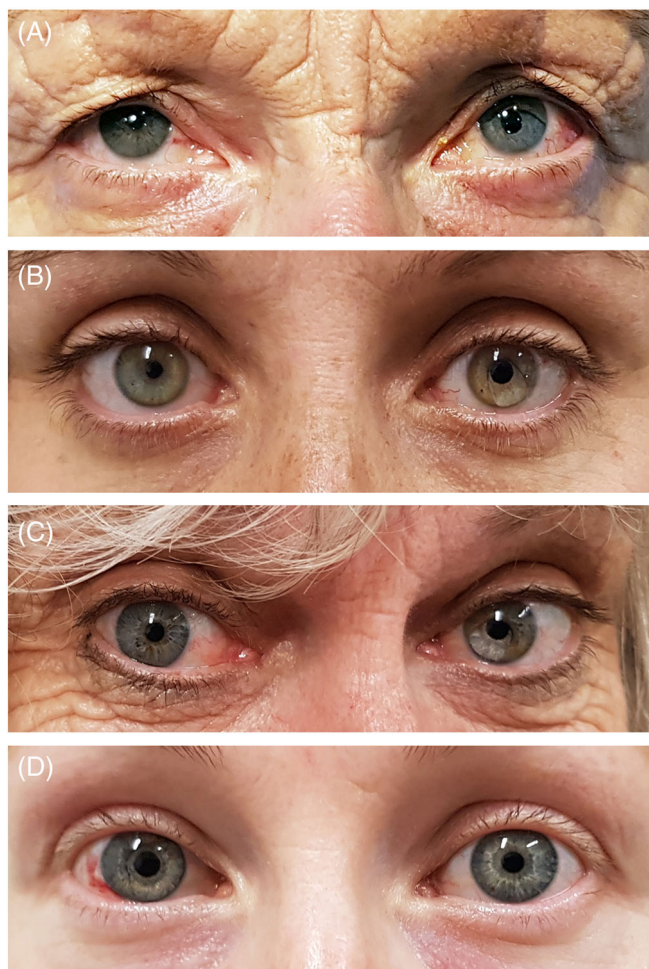


FIGURE 2 High magnification, illustrative images of the capsule with (A) blue and (B) brown endocapsular iris prostheses at 48 months post-insertion. The capsulorrhexis is highlighted by white arrows and there is no significant alteration in the apparent iris prosthesis colour within the capsule compared with the region exposed by the capsulorrhexis at 4 years, despite a degree of overlying capsule fibrosis that is more marked in A than B

surgeon's skill-set; and placement in the capsular bag avoids contact with uveal tissue with reduced risk of uveitis-glaucoma-hyphaema syndrome. Importantly, endocapsular

implantation employs a flexible fibre-free iris implant and long-term complications such as glaucoma, pigment dispersion and secondary surgery, have been associated with





**FIGURE 3** Four cases of endocapsular artificial iris implantation following excision of melanotic iris lesions. (A–C) Show eyes ~3 months post phacoemulsification with insertion of IOL and customised artificial irises (all left eyes) compared with normal right irises. (D) Shows the appearance 24 h post-surgery of a case with a right artificial for a 6–7 clock hour nasal iridectomy

integrated fibre mesh implants but not fibre free implants.<sup>7</sup> Finally, eyes with a more intact crystalline lens-zonule complex are inherently likely to have fewer ocular comorbidities than in eyes with a more disorganised anterior segment. In the current series of endocapsular procedures, only one eye (5.3%), with significant co-morbidity preoperatively, had a postoperative event that fulfilled the criteria for a severe complication—an unexpected event without full recovery.

Transient ocular hypertension was the most common postoperative complication in our series. These early transient postoperative IOP rises, and steroid response related IOP rises were easily controlled with ocular antihypertensive eye drops and systemic carbonic anhydrase inhibitors. There were no significant changes in IOP in the postoperative period. Previous reports have estimated the postoperative onset of glaucoma following artificial iris insertion at 0% to 9%.<sup>7</sup> However, given the complex

ocular history of many eyes undergoing device implantation, the relationship between device implantation and raised IOP is unclear and might relate more to the initial pathology or subsequent operations.<sup>8</sup>

A greater incidence of CMO (15.8%) was observed in our series compared with previous studies (5% and 5.9%).<sup>1,8</sup> This outcome appears somewhat paradoxical as endocapsular iris implant placement avoids uveal contact and should theoretically be less inflammatory compared with passive or sutured ciliary sulcus placement. We postulate two explanations. Firstly, cataract surgery per se is an established risk factor for CMO and all patients in our series underwent cataract surgery plus an artificial iris implant as opposed to a minority in other series. Two of the cases developed CMO around 5 weeks postoperatively which is the typical peak time for post cataract CMO.<sup>12</sup> The incidence of clinical CMO after cataract surgery is reported as 0.1%–7.0%,<sup>13,14</sup> though it is well established that the observed incidence is much higher when eyes are routinely assessed with imaging modalities (as in this series) compared with eyes that are assessed after the development of patient's visual complaints.<sup>13</sup> Secondly, in our series, CMO occurred exclusively in eyes that had previously undergone iris excision for suspected iris melanoma within 9 months of the artificial iris insertion. The pathophysiology of CMO is thought to be mediated by inflammation, especially as inflammation may disrupt the blood-retinal and blood aqueous barriers.<sup>13,14</sup> We hypothesise that the increased incidence of CMO observed in our case series may be in part secondary to disruption of the blood-aqueous barrier caused by the relatively recent, prior, iris surgery.

Postoperative, forward vaulting of the artificial iris occurred in four cases necessitating a surgical intervention in only one eye. Postulated mechanisms for this effect include shrinkage of the capsular bag or over-sizing of the prosthesis relative to the capsular bag.<sup>1</sup> These four cases had a trephinated iris diameter of 9.75, 9.75, 10, 10.5 mm, respectively. Only one of these three eyes had a CTR placed at the time of surgery. However, it is not known whether a CTR does indeed prevent shrinkage of the capsule,<sup>1</sup> especially with both an IOL and an artificial iris in the bag. Interestingly, the eye that developed significant vaulting of the artificial iris (diameter of 10.5 mm) and capsular retraction had previously sustained a total hyphaema following the excision of the original iris lesion (occurring after the patient lifted a heavy weight during a period of 'bed rest'). We postulate that the prolonged hyphaema may have caused the capsule to have a greater propensity for fibrosis and contraction after what was initially a perfectly sized and positioned iris implant.



While a significant change in mean BCVA following surgery was not observed, BCVA improved in 8 eyes (42.1%) and remained unchanged in 10 eyes (52.6%). There was a single case (5.3%) of decline in postoperative BCVA in an eye with significant preoperative comorbidities. It is therefore difficult to ascertain the relative contribution of the artificial iris implantation to the decline in vision in this eye. Fortunately, overall, our cohort had a lower prevalence of preoperative comorbidities compared with other studies and the percentage of patients experiencing vision loss in our study was much lower than that reported in other studies, range 8.8% to 30%.<sup>7,8</sup> This finding supports the proposition that the burden of postoperative complications reported in association with artificial iris implantation is likely to be largely related to the underlying complexity of the eye rather than the artificial iris itself.

Around a quarter of patients (26.3%) gained more than two lines of vision. Other studies have reported higher rates of significant improvements in vision, Rickman 47.1% and Meyer 42.2%, though paradoxically these studies also reported higher rates of significant loss 8.8% and 28.8%, respectively.<sup>7,9</sup> A possible explanation for this is that the mean preoperative baseline BCVA was excellent in our study with most patients (78.9%) achieving BCVA  $\geq 0.3$  logMAR ( $>20/40$  Snellen). Consequently, there was limited latitude for postoperative improvement in visual acuity. Conversely, the mean postoperative baseline BCVA was typically poorer in other studies, range 0.7 to 1.5 logMAR (20/100 to 20/840 Snellen).<sup>7,8,15</sup> Furthermore, patients with aphakia or corneal opacification were highly prevalent in other studies.<sup>7-9</sup> Reversal of these pathological states by procedures accompanying artificial iris insertion such as keratoplasty or IOL insertion would account for the greater potential for improvements in visual acuity.

The aims of the artificial iris are to improve cosmesis (Figure 3) and reduce visual disturbances.<sup>15</sup> The artificial iris was highly successful in improving cosmesis in our study, with 94.4% of responding patients reporting that they were very satisfied with the aesthetic outcome. Previous studies have also reported high levels of patient satisfaction with ocular cosmesis.<sup>8,15</sup> Overall, most patients reported improved light sensitivity (78.9%) and high levels of satisfaction with postoperative visual acuity outcomes (mean 4.3/5.0 with 73.7% very satisfied). Typically, those who were less satisfied were in the pre-presbyopic age group and despite distance BCVA of  $\geq 20/25$  and careful preoperative counselling these responses may well reflect sudden loss of monocular accommodation in younger patients. Interestingly, 94.4% of subjects stated

they would be highly likely to undergo the same surgery again in relation to their outcomes.

Ultimately, endocapsular insertion of an iris prosthesis uses a small incision approach that enables good centration and sequestration of the prosthesis from surrounding ocular structures but requires appropriate sizing and careful endocapsular insertion and unfolding without damage to the capsulorrhexis or zonules. Ciliary Sulcus fixation is a relatively simple small incision option if there is stable residual capsule, or a capsule IOL complex and moderate residual iris, but requires very careful sizing, placement and centration of the iris prosthesis. Due to direct contact with surrounding structures this approach may be more predisposed to uveitis, chafing of residual iris or even UGH syndrome.<sup>8</sup> In more complex eyes with loss of capsular support the iris prosthesis can be sutured into the ciliary sulcus. This is typically the more complex surgical approach using a less flexible prosthesis and a larger incision. There may be difficulty in prosthesis and pupil centration, intraoperative bleeding, risks of malposition or corneal endothelial damage common to all approaches, and in addition a relatively high incidence of severe postoperative complications.<sup>1,7,8</sup>

## 4.1 | Conclusion

Endocapsular insertion of the custom-tailored HumanOptics Artificial iris is an effective therapeutic option for the treatment of iris defects. Severe postoperative complications are less common with this mode of implantation, though this must be interpreted in the context of innate differences in the study populations. Furthermore, the percentage of patients experiencing vision loss in our study was much lower than that reported in other studies. Subjective data from our series suggests that artificial iris implantation achieves high levels of patient satisfaction. The findings of this study suggest that endocapsular placement of a customised iris is a safe and effective technique of iris reconstruction in suitable patients.

## ACKNOWLEDGEMENTS

We are grateful to Dr Jay Meyer and Dr Mohammed Ziaei, Senior Lecturers in Ophthalmology, who were involved in the care of a number of these patients while completing Anterior Segment Fellowships at the University of Auckland. Open access publishing facilitated by The University of Auckland, as part of the Wiley - The University of Auckland agreement via the Council of Australian University Librarians.




## CONFLICT OF INTEREST

The author declares that there is no conflict of interest.

## ORCID

Simone E. N. Freundlich  <https://orcid.org/0000-0003-3321-3101>

Joey Lim  <https://orcid.org/0000-0001-6186-6922>

Charles N. J. McGhee  <https://orcid.org/0000-0001-7048-0706>

## REFERENCES

1. Mayer C, Tandogan T, Hoffmann AE, Khoramnia R. Artificial iris implantation in various iris defects and lens conditions. *J Cataract Refract Surg*. 2017;43(6):724-731.
2. Yildirim TM, Khoramnia R, Masyk M, Son HS, Auffarth GU, Mayer CS. Aesthetics of iris reconstruction with a custom-made artificial iris prosthesis. *PLoS One*. 2020;15(8):e0237616.
3. Barton JJ, Radcliffe N, Cherkasova MV, Edelman J, Intriligator JM. Information processing during face recognition: the effects of familiarity, inversion, and morphing on scanning fixations. *Perception*. 2006;35(8):1089-1105.
4. Weissberg E, Suckow M, Thorn F. Minimal angle horizontal strabismus detectable by lay observers. *Optom Vis Sci*. 2004;81(7):505-509.
5. Mohny BG, McKenzie JA, Capo JA, Nusz KJ, Mrazek D, Diehl NN. Mental illness in young adults who had strabismus as children. *Pediatrics*. 2008;122(5):1033-1038.
6. Crawford A, Freundlich S, Zhang J, McGhee CNJ. Iris reconstruction: a perspective on the modern surgical armamentarium. *Oman J Ophthalmol*. 2021;14(2):69-73.
7. Rickmann A, Szurman P, Januschowski K, et al. Long-term results after artificial iris implantation in patients with aniridia. *Graefes Arch Clin Exp Ophthalmol*. 2016;254(7):1419-1424.
8. Bonnet C, Miller KM. Safety and efficacy of custom foldable silicone artificial iris implantation: prospective compassionate-use case series. *J Cataract Refract Surg*. 2020;46(6):893-901.
9. Mayer CS, Laubichler AE, Khoramnia R, et al. Challenges and complication Management in Novel Artificial Iris Implantation. *J Ophthalmol*. 2018;2018:3262068.
10. Meyer JJ, Krishnan T, McGhee CN. Minimal iris touch excision: a novel surgical technique for local excision of iris melanoma. *Clin Experiment Ophthalmol*. 2018;46(3):298-299.
11. Ziaei M, Kim BZ, Hadden PW, McGhee CN. Battle-axe fold: surgical technique for in-the-bag implantation of an artificial iris implant. *Clin Experiment Ophthalmol*. 2017;45(8):831-834.
12. Munk MR, Jampol LM, Simader C, et al. Differentiation of diabetic macular edema from pseudophakic cystoid macular edema by spectral-domain optical coherence tomography. *Invest Ophthalmol Vis Sci*. 2015;56(11):6724-6733.
13. Hollo G, Aung T, Cantor LB, Aihara M. Cystoid macular edema related to cataract surgery and topical prostaglandin analogs: mechanism, diagnosis, and management. *Surv Ophthalmol*. 2020;65(5):496-512.
14. Han JV, Patel DV, Squirrel D, McGhee CN. Cystoid macular oedema following cataract surgery: a review. *Clin Experiment Ophthalmol*. 2019;47(3):346-356.
15. Mayer CS, Reznicek L, Hoffmann AE. Pupillary reconstruction and outcome after artificial iris implantation. *Ophthalmology*. 2016;123(5):1011-1018.

**How to cite this article:** Crawford AZ, Freundlich SEN, Lim J, McGhee CNJ. Endocapsular artificial iris implantation for iris defects: Reducing symptoms, restoring visual function and improving cosmesis. *Clin Experiment Ophthalmol*. 2022;50(5):490-499. doi:[10.1111/ceo.14083](https://doi.org/10.1111/ceo.14083)