

## Brief Report

**Cite this article:** Schroder J, Lund MAV, Vejlstrop N, Juul K, and Nygaard U (2021). Left ventricular thrombus in multisystem inflammatory syndrome in children associated with COVID-19. *Cardiology in the Young*, page 1 of 4. doi: [10.1017/S1047951121002456](https://doi.org/10.1017/S1047951121002456)

Received: 19 May 2021  
Revised: 27 May 2021  
Accepted: 28 May 2021


### Keywords:

thrombus; autoimmune; echocardiography; haemodynamics; cardiac magnetic resonance

### Author for correspondence:

Jakob Schroder, MD, PhD, Department of Pediatric Cardiology, Rigshospitalet, University of Copenhagen, Blegdamsvej, Denmark.  
Tel: +45 23820896.  
E-mail: [jakob.arnborg.schroeder.02@regionh.dk](mailto:jakob.arnborg.schroeder.02@regionh.dk)

# Left ventricular thrombus in multisystem inflammatory syndrome in children associated with COVID-19

Jakob Schroder<sup>1</sup> , Morten Asp Vonsild Lund<sup>2</sup>, Niels Vejlstrop<sup>2</sup>, Klaus Juul<sup>1</sup> and Ulrikka Nygaard<sup>3</sup>

<sup>1</sup>Department of Pediatric Cardiology, Rigshospitalet, University of Copenhagen, Blegdamsvej, Denmark;

<sup>2</sup>Department of Cardiology, Rigshospitalet, University of Copenhagen, Blegdamsvej, Denmark and <sup>3</sup>Department of Pediatrics and Adolescent Medicine, Rigshospitalet, University of Copenhagen, Blegdamsvej, Denmark

## Abstract

A 17-year-old adolescent with severe multisystem inflammatory syndrome in children (MIS-C) associated with coronavirus disease-2019 developed reduced left ventricular function and left ventricular thrombus. With treatment, his condition improved and the thrombus was dissolved. This case illustrates the risk of severe intra-cardiac thrombotic complications in patients with MIS-C.

Severe acute respiratory syndrome-coronavirus-2 was initially regarded as a mild infection in children, but with the emergence of multisystem inflammatory syndrome in children (MIS-C), it has now been recognised as a virus with far more serious implications.<sup>1,2</sup> Although MIS-C has now been described in more than 2000 children and half of the patients have biochemical signs of coagulopathy, thrombotic complications have only rarely been described with venous thromboembolisms in four children and cerebral artery thrombosis in one child.<sup>3</sup> Further, two children who received extracorporeal membrane oxygenation developed right atrial thrombus and cerebral artery infarction.<sup>4</sup>

Due to the novelty of MIS-C and resulting limited evidence, current treatment recommendations regarding antithrombotic prophylaxis are mainly founded on expert consensus. In patients with severe ventricular dysfunction anticoagulation prophylaxis is encouraged to reduce the risk of intra-cardiac thrombosis, a known but rare complication of severe non-coronavirus disease-related myocarditis.<sup>5,6</sup>

This case report describes the clinical and imaging features of a patient with MIS-C and left ventricular thrombus. To our knowledge, this is the only described case of left ventricular thrombus in a patient with MIS-C and illustrates the risk of severe intra-cardiac thrombotic complications in MIS-C.

## History of presentation

A 17-year-old otherwise healthy Caucasian male adolescent fulfilled the case definition criteria for MIS-C by the Centers for Disease Control and Prevention and the World Health Organization. He presented to a paediatric emergency department in January 2021 with fever for 4 days, nausea, and abdominal pain. The physical examination revealed severe abdominal tenderness and a temperature of 39.7°C but no rash, mucous membrane change, or conjunctival injection. His initial blood pressure was 113/61 mmHg, heart rate was 104 beats/min, respiratory rate 18 breaths/min, and blood oxygen saturation by pulse oximetry was 99%.

Despite general supportive measures, his condition deteriorated in the following 48 hours with worsening epigastric pain, headache, emesis, and haemodynamic compromise (blood pressure 75/40, heart rate 125 beats/min, oliguria). On hospital day 3, he was transferred to a tertiary paediatric intensive care facility for further investigations and treatment.

## Past medical history

There was no significant medical history.

## Differential diagnosis

Presumed diagnosis was MIS-C due to previous severe acute respiratory syndrome-coronavirus-2 infection. Other considered differential diagnoses were bacterial sepsis, toxic shock syndrome, and Kawasaki disease.

## Investigations

A 12-lead electrocardiogram showed flattening of T-waves and insignificant ascending ST-depression in the inferior extremity leads. Laboratory results showed elevated inflammatory markers and abnormal coagulation studies (Table 1). Serial chest radiographs were normal, and abdominal ultrasound indicated mesenteric lymphadenitis.

A bedside focused transthoracic echocardiogram on hospital day 2 prior to haemodynamic shock showed left ventricular ejection fraction 55%, normal right ventricular systolic function, and no valvular disease.

A transthoracic echocardiogram on hospital day 3 revealed global reduction of left ventricular ejection fraction, global longitudinal strain, and stroke volume index with normal diastolic function parameters (Table 2). Marked left ventricular spontaneous echo contrast was noted. In the 4- and 2-chamber views, a mural thrombus measuring  $2.6 \times 1.0$  cm was identified near the posteromedial papillary muscle in the left ventricular apex (Fig 1, Online Video 1). The thrombus was more consolidated near the ventricular wall, while thinner strings of thrombus mass were swinging from its luminal head. There was a minor pericardial effusion. The dimension of the proximal coronary arteries was normal.

## Management

Immediate treatment on hospital day 1 was isotonic fluid, antibiotics, and prophylactic doses of tinzaparin. On hospital day 3, dopamine infusion at high concentrations was necessary to attain acceptable organ perfusion. Multisystem inflammatory syndrome in children treatment with intravenous immunoglobulin, anakinra, methylprednisolone, and acetylsalicylic acid was instituted. The left ventricular thrombus was treated with therapeutic doses of tinzaparin and monitored with daily echocardiograms. On hospital day 5, clinical status improved, left ventricular ejection fraction increased to 50%, and the mural thrombus was nearly dissolved. There were no findings suggestive of systemic thromboembolism from the left ventricular thrombus.

## Follow-up

The patient was discharged on hospital day 9. Both inflammatory and cardiac biomarkers had decreased but were still moderately elevated. A transthoracic echocardiogram demonstrated normalisation of left ventricular function, complete absence of left ventricular spontaneous echo contrast, and no signs of intra-cardiac thrombus (Table 2, Fig 1). On follow-up 20 days after discharge, the patient and his parents reported a return to normal activities. Testing for inherited thrombophilia was negative.

Cardiac MRI was performed 30 days after discharge and showed normal left ventricular volumes, left ventricular ejection fraction, and stroke volume index but a reduction in both global longitudinal and circumferential strain and minor pericardial effusion. Dimensions of the proximal coronary arteries were normal. No late enhancement following gadolinium contrast and normal native T1, ECV, and T2 values was observed in all AHA segments, indicating no signs of myocardial injury or oedema (Table 2, Online Video 2).

## Discussion

This represents the only reported case of left ventricular thrombus in a MIS-C patient and provides direct evidence of potential serious

**Table 1.** Clinical laboratory results, hospital day 3

Laboratory Test	Result	Normal range
Blood and immune system		
C-reactive protein, mg/l	301	<10
Procalcitonin, ng/ml	51.4	≤0.08
Ferritin, ng/ml	610	30–400
White cell count, $\times 10^3/\mu\text{l}$	19.4	5.2–13.4
Absolute neutrophil count, $\times 10^3/\mu\text{l}$	12.7	1.9–7.4
Absolute lymphocyte count, $\times 10^3/\mu\text{l}$	0.41	1.0–3.9
Platelet count, $\times 10^3/\mu\text{l}$	143	150–400
Haemoglobin, g/dl	12.35	13.2–17.0
Basic metabolic panel		
Sodium, mmol/l	132	136–145
Potassium, mmol/l	3.6	3.5–5.1
Blood urea nitrogen, mg/dl	17.64	9–23
Calcium (ionised), mg/dl	4.21	4.4–5.2
Creatinine, mg/dl	0.26	0.7–1.3
Glucose, mmol/l	135.1	65–140
Hepatic function		
Albumin, g/dl	2.6	3.2–4.8
Bilirubin, mg/dl	1.46	0.3–1.2
Aspartate aminotransferase, U/l	39	≤33
Alanine aminotransferase, U/l	53	10–49
Alkaline phosphatase, U/l	45	46–116
Coagulation profile		
Activated partial thromboplastin time, s	44	24–35
International normalised ratio	1.6	0.9–1.1
Fibrinogen, mg/dl	748	150–450
D-dimer, ng/ml	3800	<500
Arterial blood gas		
pH	7.39	7.36–7.41
Partial pressure of carbon dioxide, mmHg	42.8	40–45
Arterial lactate, mmol/l	1.8	0.50–2.20
Cardiac biomarkers		
N-terminal pro-B-type natriuretic peptide, pg/ml	17,957	23–327
Troponin T, ng/l	2180	<22

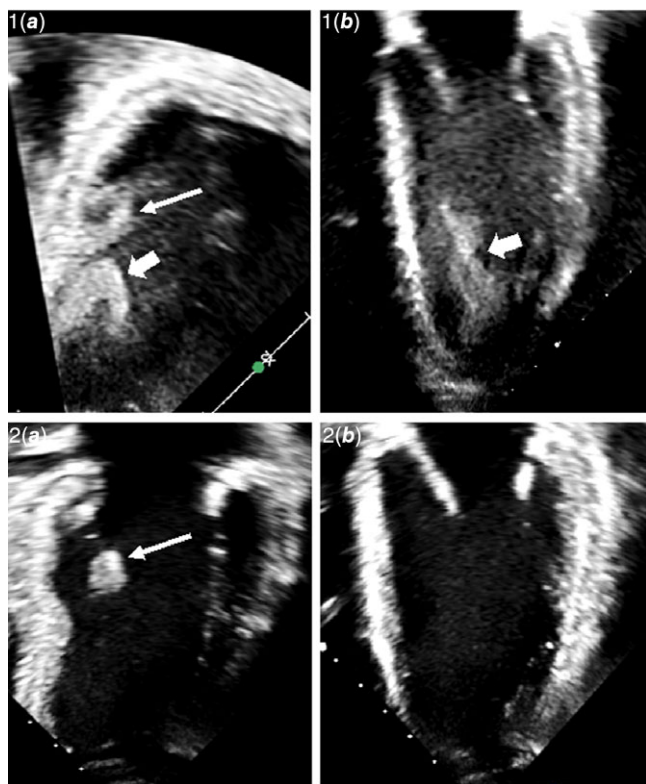
thrombotic complications despite prophylactic anticoagulant treatment. A previously healthy adolescent developed acute illness, cardiac dysfunction, and left ventricular thrombus. After treatment, he recovered and returned to normal activities without any signs of residual thrombus mass or arterial thromboembolic complications.

The pathogenesis of MIS-C remains poorly understood. The fact that the disease develops coinciding with the acquired immune response to severe acute respiratory syndrome-coronavirus-2 and most children have negative severe acute respiratory syndrome-

**Table 2.** Cardiac imaging

Parameter	Echocardiography		Cardiac MRI 30 days after discharge	
	Hospital Day 3	Day 11 follow-up	Parameter	Value
Left ventricular ejection fraction, %	32	65	iLVEDV, ml/m <sup>2</sup>	78
Global longitudinal strain, %	-11.4	-23.2	iLVESV, ml/m <sup>2</sup>	30
Fractional shortening, %	17.8	43.0	iLVSV, ml/m <sup>2</sup>	48
Stroke volume index, ml/m <sup>2</sup>	23.6	n/a	Left ventricular ejection fraction, %	61
E/A ratio	n/a	1.8	iWall mass, g/m <sup>2</sup>	61
E/e' ratio	4.2	5.3	Native T1, ms	1025
Inferior caval vein diameter, cm	2.2	1.6	Extracellular volume, %	28
TAPSE, cm	1.5	2.2	T2, ms	48.4
Left atrial volume index, cm <sup>3</sup> /m <sup>2</sup>	30.7	28.3	LGE pattern	none
Mitral regurgitation, degree	Mild	none	Pericardial effusion	minor
LMCA proximal diameter, z score	-0.96	-0.04	Peak circumferential strain, %	-16.5
RCA proximal diameter, z score	0.35	-0.33	Peak longitudinal strain, %	-15.3

iLVEDV = indexed left ventricular end-diastolic volume; iLVESV = indexed left ventricular end-systolic volume; iLVSV = indexed left ventricular stroke volume; LGE = late gadolinium enhancement; LMCA = left main coronary artery; n/a = not available; RCA = right coronary artery; TAPSE = tricuspid annular plane systolic excursion.



**Figure 1.** Echocardiogram images demonstrating left ventricular thrombus and subsequent dissolution. **1, Hospital Day 3.** Reduced left ventricular function, notable spontaneous echo contrast and left ventricular thrombus near the posteromedial papillary muscle. 1A: 2-chamber view, 1B: 4-chamber view. **2, Hospital day 11.** Normal left ventricular function, no spontaneous echo contrast, and absence of left ventricular thrombus with clear detection of endocardial border. 2A: 2-chamber view, 2B: 4-chamber view. **Markers.** Thin arrow = posteromedial papillary muscle. Wide arrow = Left ventricular thrombus.

coronavirus-2 RNA on presentation supports the hypothesis that MIS-C is caused by immune-mediated systemic inflammation. Given almost half of all children with MIS-C have elevated d-dimer and fibrinogen,<sup>1,2</sup> inflammation-induced hypercoagulopathy could conceivably contribute to the multiple organ involvement in MIS-C.

In adult patients with primary severe acute respiratory syndrome-coronavirus-2 infection, procoagulant abnormalities have been associated with an increased risk of thrombotic complications, possibly due to a specific coronavirus disease 2019-associated coagulopathy. The incidence of venous thromboembolic events in critically ill severe acute respiratory syndrome-coronavirus-2 patients admitted to the ICU has been reported to be as high as 27% despite standard anticoagulant prophylaxis, and arterial vascular events up to 4%.<sup>7</sup> Biochemical evidence of a similar hypercoagulable state in MIS-C patients has led to consensus-based guidelines recommending low-dose anticoagulation prophylaxis.<sup>5,6</sup> Nevertheless, thrombotic events seem to be rare in patients with MIS-C. One study found that 4 of 186 children and adolescents had a venous thromboembolism, but the largest published MIS-C case series have not reported thrombotic complications.<sup>1-3</sup>

In our patient, notable spontaneous echo contrast was noted on the transthoracic echocardiogram. This finding has been strongly correlated with intra-cardiac thrombus and is thought to represent erythrocyte aggregation under slow blood flow conditions in the left ventricle in patients with severe left ventricular dysfunction.<sup>8</sup> Two previous echocardiographic studies in patients with MIS-C found median left ventricular ejection fraction was 55 to 57%.<sup>9,10</sup> In comparison, our patient had a more pronounced reduction in left ventricular ejection fraction from 55 to 32% in less than 48 hours perhaps resulting in particularly sluggish blood flow. It may be speculated that the risk of developing left ventricular mural thrombus is especially high in patients with MIS-C coagulopathy and large areas of poorly contracting left ventricular wall.

At follow-up, there was normalisation of echocardiographic parameters, while a mild reduction in global strain on cardiac MRI persisted. This is consistent with a previous study in 20 MIS-C patients in which all patients exhibited persisting abnormal strain patterns on cardiac MRI, possibly due to protracted but resolving myocardial inflammation.<sup>10</sup>

In conclusion, this case demonstrates the genuine potential for intra-cardiac thrombus formation in MIS-C patients with coagulopathy and reduced left ventricular ejection fraction, even during treatment with prophylactic dose anticoagulants.

#### Learning objectives.

- To understand that the coagulopathy in multisystem inflammatory syndrome in children (MIS-C) may lead to intra-cardiac thrombotic complications in rare cases.
- To be aware of the value of serial echocardiographic evaluations of possible thrombotic complications in MIS-C patients with haemodynamic shock.

**Acknowledgements.** The authors thank the patient and his parents for allowing us to share their story. They also thank all doctors and nursing staff at the Pediatric Emergency Department, Pediatric Intensive Care Unit, and Pediatric Cardiology Department for their efforts and care.

**Financial support.** This research received no specific grant from any funding agency, commercial, or not-for-profit sectors.

**Conflicts of interest.** None.

**Supplementary material.** To view supplementary material for this article, please visit <https://doi.org/10.1017/S1047951121002456>

#### References

1. Belay ED, Abrams J, Oster ME, et al. Trends in geographic and temporal distribution of US children with multisystem inflammatory syndrome during the COVID-19 pandemic. *JAMA Pediatr* 2021; 30333: 1–9.
2. Feldstein LR, Tenforde MW, Friedman KG, et al. Characteristics and outcomes of US children and adolescents with multisystem inflammatory syndrome in children (MIS-C) compared with severe acute COVID-19. *JAMA* 2021; 02115: 1–14.
3. Feldstein LR, Rose EB, Horwitz SM, et al. Multisystem inflammatory syndrome in U.S. children and adolescents. *N Engl J Med* 2020; 383: 334–346.
4. Minen F, Hands C, Mustafa MR, Pienaar A, Lillie J. Thrombophilia in pediatric patients with multisystem inflammatory syndrome in children secondary to Coronavirus disease 2019 Supported on Extracorporeal Membrane Oxygenation. *ASAIO J* 2021; 67: 7–11.
5. Henderson LA, Canna SW, Friedman KG, et al. American college of rheumatology clinical guidance for multisystem inflammatory syndrome in children associated with SARS-CoV-2 and hyperinflammation in pediatric COVID-19: version 1. *Arthritis Rheumatol* 2020; 72: 1791–1805.
6. Goldenberg NA, Sochet A, Albisetti M, et al. Consensus-based clinical recommendations and research priorities for anticoagulant thromboprophylaxis in children hospitalized for COVID-19-related illness. *J Thromb Haemostasis* 2020; 18: 3099–3105.
7. Connors JM, Levy JH. Thromboinflammation and the hypercoagulability of COVID-19. *J Thromb Haemostasis* 2020; 18: 1559–1561.
8. Black IW, Chesterman CN, Hopkins AP, Lee LCL, Chong BH, Walsh WF. Hematologic correlates of left atrial spontaneous echo contrast and thromboembolism in nonvalvular atrial fibrillation. *J Am Coll Cardiol* 1993; 21: 451–457.
9. Matsubara D, Kauffman HL, Wang Y, et al. Echocardiographic findings in pediatric multisystem inflammatory syndrome associated with COVID-19 in the United States. *J Am Coll Cardiol* 2020; 76: 1947–1961.
10. Theocharis P, Wong J, Pushparajah K, et al. Multimodality cardiac evaluation in children and young adults with multisystem inflammation associated with COVID-19. *Eur Heart J – Cardiovasc Imaging* 2020: 1–8.