

Comparative Evaluation of Mineral Trioxide Aggregate Pulpotomy and Laser-Assisted Mineral Trioxide Aggregate Pulpotomy: An Original Research Article

Saurabh Satyarth, Ahmed Mansour Alkhamis¹, Hessah Fahad Almunahi², Malak Omar Abdulaziz Alsuahaymi², Hima Bindu Vadde³, Navaneet Senapathi S⁴, Ahmed Omar Shami⁵, Reema Fahad Aldrewesh², Abhishek Singh Nayyar⁶

Department of Dentistry, Government Medical College, Bettiah, Bihar, India, ¹General Dental Practitioner, Ministry of Health, Arar, Kingdom of Saudi Arabia, ²College of Dentistry, Jouf University, Sakaka, ³Intern, College of Dentistry, Jazan University, Jazan, Kingdom of Saudi Arabia, ⁴Consultant Pedodontist, Midas ENT Head and Neck Super Speciality Hospital, Hyderabad, Telangana, ⁵Department of Pedodontics and Preventive Dentistry, Sri Sai Dental College and Research Institute, Srikakulam, Andhra Pradesh, ⁶Department of Oral Medicine and Radiology, Saraswati Dhanwantari Dental College and Hospital and Post-graduate Research Institute, Parbhani, Maharashtra, India

Abstract

Context and Aim: Formocresol has been used as the material of choice (gold standard) for pulpotomy procedures because of the ease of use but was discouraged due to its potential immune sensitization and mutagenic effects. Laser irradiation was first applied for pulpotomy procedure in the year 1985. Recently, diode lasers have been used for pulpotomy in primary teeth and have shown clinical success rates comparable to formocresol. The present *in vivo* study was carried out to compare the clinical and radiographic success rates of mineral trioxide aggregate (MTA) pulpotomy and diode laser-assisted pulpotomy in human primary molars. **Materials and Methods:** The present study was a randomized clinical trial in design wherein 40 primary teeth requiring pulpotomy treatment which met the selection criteria (clinical and radiographic) were divided into two groups, Group 1 ($n = 20$) wherein the pulpotomy was performed with MTA alone and Group 2 ($n = 20$) wherein laser-assisted pulpotomy was performed with MTA (L-MTA). The patients were recalled after 3, 6, and 9 months, respectively and evaluated clinically and radiographically. **Statistical Analysis Used:** The data were analyzed using the Statistical Package for the Social Sciences (SPSS) Version 22 (IBM corporation, Washington DC, United States). Descriptive statistics were used to analyze the data while the Pearson's correlation coefficient test was used to analyze the statistical correlation between the overall success rates observed in the clinical and radiographic findings of both the groups. $P < 0.05$ was considered statistically significant. **Results:** The clinical success rate in the MTA group was 90%, 84.21%, and 88.23% at 3, 6, and 9 months, respectively, with no clinical signs or, symptoms reported at the said follow-up visits while the radiographic success rate was found to be 85%, 84.21%, and 82.3%, respectively. On the contrary, the clinical success rate in the L-MTA group was found to be 95%, 94.74%, and 94.44% at 3, 6, and 9, months, respectively with the radiographic success rate reported being 90%, 89.47%, and 88.89%, respectively. **Conclusion:** The combination of diode laser and MTA yielded better clinical and radiographic success rates over the pulpotomy procedures done with the help of MTA alone, thereby, concluding that lasers may be considered as adjuvant alternatives for vital pulp therapy on human primary teeth.

Keywords: Diode lasers, mineral trioxide aggregate, pulpotomy

INTRODUCTION

The goals of an ideal pulpotomy procedure are removal of pulpal inflammation, maintenance of arch length, and masticatory function. Formocresol has been used as the material of choice (gold standard) for pulpotomy procedures because

of the ease of use but was discouraged due to its potential immune sensitization and mutagenic effects.^[1] Alternative

Address for correspondence: Dr. Abhishek Singh Nayyar,
44, Behind Singla Nursing Home, New Friends' Colony, Model Town,
Panipat - 132 103, Haryana, India.
E-mail: singhabhishekndls@gmail.com

Received: 12-09-2019 Revised: 17-06-2020
Accepted: 22-06-2020 Published: 09-02-2021

Access this article online

Quick Response Code:



Website:
<http://www.jmau.org/>

DOI:
10.4103/JMAU.JMAU_54_19

This is an open access journal, and articles are distributed under the terms of the Creative Commons Attribution-NonCommercial-ShareAlike 4.0 License, which allows others to remix, tweak, and build upon the work non-commercially, as long as appropriate credit is given and the new creations are licensed under the identical terms.

For reprints contact: reprints@medknow.com

How to cite this article: Satyarth S, Alkhamis AM, Almunahi HF, Abdulaziz Alsuahaymi MO, Vadde HB, Senapathi SN, *et al.* Comparative evaluation of mineral trioxide aggregate pulpotomy and laser-assisted mineral trioxide aggregate pulpotomy: An original research article. J Microsc Ultrastruct 2021;9:7-11.

medicaments such as glutaraldehyde, ferric sulfate, mineral trioxide aggregate (MTA), bone morphogenic proteins, dentin bonding agents, enamel matrix derivatives, freeze dried bone, growth factors, and various techniques such as electrosurgery and lasers have been tried with variable clinical, radiological, and histological success rates. MTA has the ability to stimulate cytokine release from the bone cells indicating that it actively promotes hard tissue formation to provide an enhanced seal over the vital pulp and is nonresorbable.^[2] Furthermore, MTA was reported to have superior biocompatibility, better sealing ability, dentinal bridge inducing materials and is relatively less cytotoxic than other materials currently used for pulp therapies.^[2-4] Lasers have been used for carrying out pulpotomy procedures in primary teeth as they maintain a sterile environment and reduce inflammation. Laser irradiation was first applied for pulpotomy procedure by Shoji *et al.*,^[5] in the year 1985. Lasers, also, possess hemostatic, antimicrobial, and cell-stimulating properties with added advantages of an improved wound healing and no mechanical damage on the remaining pulp tissue. For the said reasons, laser irradiation was suggested as a promising alternative to the conventional pharmacotherapeutic strategies.^[6] Lasers that have been tested and have demonstrated predictable outcomes in pulpotomy procedures include CO₂, Nd:YAG and Er:YAG lasers. Recently, diode lasers have been used for pulpotomy in primary teeth and have shown clinical success rates comparable to formocresol. The choice of laser use on pulp tissue is dependent on the tissue-resistant temperature (TRT) values of the pulp. The TRT values are tissue specific and directly related to the water content and vascularity. Diode laser suits the TRT values of pulp due to high absorbance at 810 nm wavelength avoiding excessive heating and charring of pulp. The present *in vivo* study was carried out to compare the clinical and radiographic success rates of MTA pulpotomy and diode laser-assisted pulpotomy in human primary molars.

MATERIALS AND METHODS

The present *in vivo* study was designed as a randomized clinical trial planned to compare the clinical and radiographic success rates of MTA pulpotomy and diode laser assisted pulpotomy in human primary molars. The study protocol was approved from the institutional ethics committee. The inclusion criteria for the study were children aged between 6 and 8 years with deeply carious primary molars (maxillary or mandibular) with vital pulp and with no history of spontaneous pain or, any other clinical or, radiographic evidence of an abscess or, sinus opening and with the absence of internal and external root resorption, inter-radicular and/or, furcal bone destruction and with the possibility of proper restoration of the teeth. Forty primary teeth requiring pulpotomy treatment which met the selection criteria (clinical and radiographic) were selected randomly from 60 children who had attended the Department of Pedodontics and Preventive Dentistry and were divided into two groups, Group 1 ($n = 20$) wherein the pulpotomy

was performed with MTA alone and Group 2 ($n = 20$) wherein laser-assisted pulpotomy was performed with MTA (L-MTA).

Procedure

After anesthetizing the tooth, isolation was done with the help of rubber dams of the required sizes. Caries and unsupported enamel/dentin were removed with spoon excavator. Pulp chamber was approached using a round bur and further, caries was removed and coronal access was made using a no. 245 bur (Dentsply, USA). Coronal pulp was removed to the canal orifices with a round spoon excavator. Pulp chamber was irrigated with saline to remove debris. Hemostasis was obtained with a moistened cotton pellet gently pressed against the amputated pulp tissues. In the MTA group, after achieving hemostasis, MTA was mixed as per the prescribed manufacturer's instructions and placed on the amputated pulp tissues with plastic filling instrument. A wet cotton pellet was, then, placed over MTA for approximately 10 min. In the L-MTA group, after achieving primary hemostasis, the root canal orifices were exposed to the Diode Laser (Picaso, Germany) of 810 nm with continuous mode of application for approximately 2 s delivered by 200 microns optical fiber tip in contact mode at 1.5W power [Figure 1]. All the individuals and operator wore appropriate eye protection wears during application of the laser. In both the groups, the treated teeth were restored with GIC Type IX (GC 9) followed by stainless steel crowns. The patients were recalled after 3, 6, and 9 months, respectively, and evaluated clinically and radiographically [Figure 2]. The clinical symptoms assessed included spontaneous pain, draining sinus, swelling or, abscess, mobility, premature exfoliation while the radiological symptoms assessed were evidence of interradicular radiolucency, periodontal ligament space widening, periapical radiolucency, and internal and/or external root resorption.

Statistical analysis used

The data were analyzed using the Statistical Package for the Social Sciences (SPSS) Version 22 (IBM corporation, Washington DC, United States). Descriptive statistics were used to analyze the data while the Pearson's correlation coefficient test was used to analyze the statistical correlation between the overall success rates observed in the clinical and radiographic findings of both the groups. $P < 0.05$ was considered statistically significant.

RESULTS

The mean age of patients in the present study was 7.08 years in the MTA group and 6.92 years in the L-MTA group. In the MTA group, male patients accounted for 40% and female patients were 60% while in the L-MTA group, male and female patients were equal in distribution. A total of 23 left and 17 right mandibular molars were treated in the MTA group while 13 left and 7 right mandibular molars were treated in the L-MTA group [Table 1]. The clinical success rate in the MTA group was

90%, 84.21%, and 88.23% at 3, 6, and 9 months, respectively, with no clinical signs or, symptoms reported at the said follow-up visits while the radiographic success rate was found to be 85%, 84.21%, and 82.3%, respectively [Table 2]. On the contrary, the clinical success rate in the L-MTA group was found to be 95%, 94.74%, and 94.44% at 3, 6, and 9 months, respectively, with the radiographic success rate reported being 90%, 89.47%, and 88.89%, respectively [Table 3].

DISCUSSION

The vital pulpotomy procedures have always been a topic of

debate. Diode laser have been considered to be the most apt for pulpotomy procedures because it suits best the TRT values of the pulp tissue due to high absorbance at 810 nm wavelength avoiding excessive heating and charring of pulp. Mareddy *et al.*^[6] reported 810 nm at 2W for 1- and 3-s applications to be the most ideal for diode laser pulpotomy procedures as most of the specimens showed intact odontoblasts. Thus, in the present study, also, Diode Laser (Picaso, Germany) of 810 nm with continuous mode of application for approximately 2 s delivered by 200 µ optical fiber tip in contact mode at 1.5W power was used. Furthermore, MTA is a material which is known to have proven therapeutic advantages in various endodontic procedures of primary teeth. In the present study, the clinical success rate in the MTA group was found to be 90%, 84.21%, and 88.23% at 3, 6, and 9 months' respectively with no clinical signs or, symptoms reported at the said follow-up visits while the radiographic success rate was found to be 85%, 84.21%, and 82.3%, respectively. The clinical success rate of the present study was in accordance with the studies conducted by Agamy *et al.*^[7] wherein a clinical success rate of 84.2% was found at 12 months' follow-up. The results of the present study, though, were in contrast with the studies conducted by Peng *et al.*,^[8] Subramaniam *et al.*^[9] and Kabaktchieva and Gateva^[10] who reported 95%, 95%, and 90.9% success rates respectively in their studies. Furthermore, amongst the 20 teeth studied, 2 teeth revealed tenderness on percussion, 1 teeth showed pathological mobility while 2 teeth showed furcal and periapical radiolucencies. The noncompliance of the patients and patient drop-outs might be the reasons for the relatively low success rate seen in the

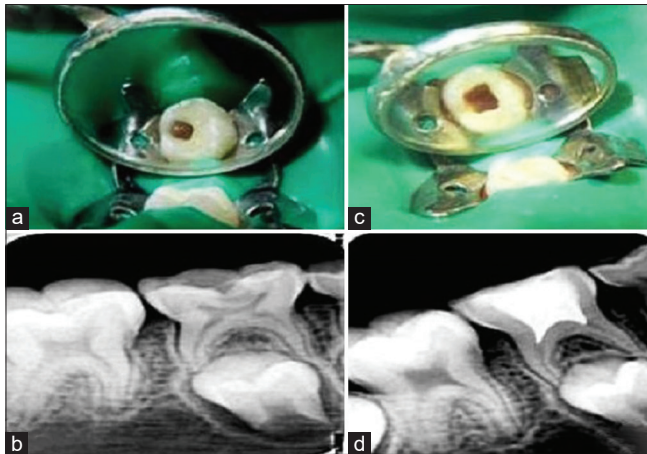


Figure 1: L-mineral trioxide aggregate group: (a) preoperative photograph (b) preoperative radiograph (c) postoperative photograph (d) postoperative radiograph

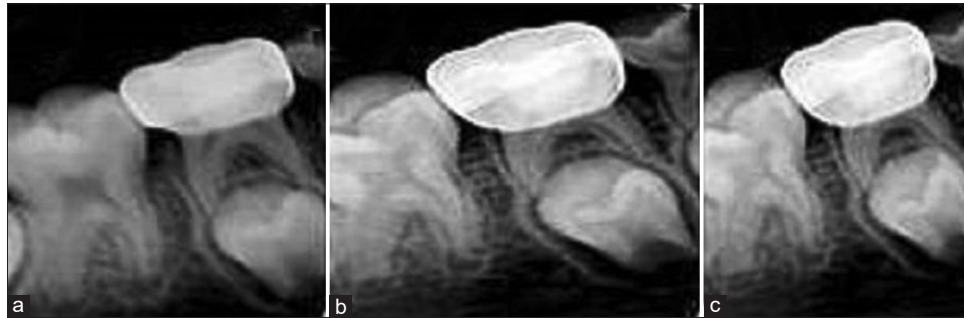


Figure 2: L-mineral trioxide aggregate group: (a-c) 3, 6 and 9 months follow-up radiographs

Table 1: Distribution of pulpotomized teeth according to mean age and gender in the two groups

Parameters	Groups		Total
	MTA pulpotomy	Laser-MTA pulpotomy	
Mean age (years)	7.08	6.92	7.00
Gender (%)			
Male	8 (40)	10 (50)	18 (45)
Female	12 (60)	10 (50)	22 (55)
Total	20	20	40 (100)
Left mandibular molar (75) (%)	10 (43.47)	13 (56.52)	23 (57.5)
Right mandibular molar (85) (%)	10 (58.82)	7 (41.18)	17 (42.5)

MTA: Mineral trioxide aggregate

Table 2: Clinical and radiographic evaluation of pulpotomized teeth using mineral trioxide aggregate at various follow-up intervals

Clinical findings	Clinical evaluation		
	3 months	6 months	9 months
No sign/symptom	18 (90)	16 (84.21)	15 (88.23)
Symptoms of pain	1 (5)	0 (0)	1 (5.88)
Tenderness to percussion	1 (5)	2 (10.53)	1 (5.88)
Swelling and/or, sinus opening	0 (0)	0 (0)	0 (0)
Pathological tooth mobility	0 (0)	1 (5.26)	0 (0)
Total	20 (50)	19 (50)	17 (48.57)
<i>P</i>	0.149	0.136	0.145

Radiographic findings	Radiographic evaluation		
	3 months	6 months	9 months
No abnormal radiographic finding	17 (85)	16 (84.21)	14 (82.35)
External root resorption	0 (0)	0 (0)	0 (0)
Periodontal ligament space widening and furcation radiolucency	2 (1)	2 (10.53)	2 (11.76)
Internal root resorption	0 (0)	0 (0)	0 (0)
Furcation and/or, periapical radiolucency	1 (5)	1 (5.26)	1 (5.88)
Total	20 (50)	19 (50)	17 (48.57)
<i>P</i>	0.138	0.136	0.132

Table 3: Clinical and radiographic evaluation of pulpotomized teeth using mineral trioxide aggregate and laser at various follow-up intervals

Clinical findings	Clinical evaluation		
	3 months	6 months	9 months
No sign/symptom	19 (95)	18 (94.74)	17 (94.44)
Symptoms of pain	0 (0)	1 (5.26)	1 (5.56)
Tenderness to percussion	1 (5)	0 (0)	0 (0)
Swelling and/or, sinus opening	0 (0)	0 (0)	0 (0)
Pathological tooth mobility	0 (0)	0 (0)	0 (0)
Total	20 (50)	19 (50)	18 (51.43)
<i>P</i>	0.149	0.161	0.175

Radiographic findings	Radiographic evaluation		
	3 months	6 months	9 months
No abnormal radiographic finding	18 (90)	17 (89.47)	16 (88.89)
External root resorption	0 (0)	0 (0)	0 (0)
Periodontal ligament space widening and furcation radiolucency	1 (5)	2 (10.53)	1 (5.56)
Internal root resorption	0 (0)	0 (0)	0 (0)
Furcation and/or, periapical radiolucency	1 (5)	0 (0)	1 (5.56)
Total	20 (50)	19 (50)	18 (51.43)
<i>P</i>	0.149	0.149	0.146

present study as compared to the said studies. Furthermore, the clinical success rate in the L-MTA group was found to be 95%, 94.74%, and 94.44% at 3, 6, and 9 months, respectively, with the radiographic success rate reported being 90%, 89.47%, and 88.89%, respectively. The clinical success rate in the L-MTA group in the present study was found to be distinctly higher than the other studies conducted by Cuadros-Fernández *et al.*,^[11] Uloopi *et al.*,^[12] and Vahid Golpayegani *et al.*^[13] who reported 73.3%, 80%, and 100% success rates, respectively, in their studies. The higher clinical success rate of 94.44% at 9 months in the present study could be attributed to the strict

aseptic/sterilization protocol and the settings of the laser used in the study which might have been responsible for a faster and efficient healing of the pulpal tissue. Nonetheless, compliance of the patients is an important attribute to the success of any procedure done. Furthermore, human clinical trials that compare laser pulpotomies with existing pulpotomy techniques have, also, shown conflicting results with any variation in the laser application parameters including the power, frequency, exposure time, and water/air dry-mode bringing variations in the response of the pulpal tissues varying

the clinical and radiographic outcomes.^[14] In the said group in the present study, clinical failure in the form of tenderness on percussion was seen in 1 tooth at 3 months follow-up while the radiographic failures in the form of periodontal ligament space widening and furcation radiolucency was seen in 1, 2, and 1 teeth at 3, 6, and 9 months' follow-up. Failures of pulpotomy procedures are attributed to several reasons one of which is the failure in diagnosing chronically inflamed pulp as noninflamed and noninfected with the lesions being silent in the process of chronic inflammation. More accurate diagnostic methods might be the prerequisite in a proper case selection of teeth with healthy radicular pulps for successful clinical outcomes of pulpotomy procedures. Durmus B and Tanboga I^[14] reported diode laser pulpotomy to be a promising alternative to the conventional pharmacotherapeutic pulpotomy procedures. In the said study, 97% clinical success rate was reported for formocresol-based pulpotomy procedures as against 95% success rate for ferric sulfate and 100% for the diode laser at 12 months follow-up. Vahid Golpayegani *et al.*^[13] compared the effectiveness of LLLT and conventional formocresol in pulpotomy of primary molars and reported 100% success rate in both the groups after 6 and 12 months' follow-up with no statistically significant difference observed in both the groups. The difference in the results obtained in the various studies conducted, though, is due a number of factors that decide the long-term success of the procedures starting from a proper case selection to a strict aseptic protocol, parameters of the laser being used and last, but not the least, the compliance of the patient for the procedure performed.

Limitations

Despite the promising findings regarding the use of the combination of diode laser and MTA in the present study, the follow-up period was relatively short because of which it was difficult to predict the long-term outcomes of the said therapy and procedures. Furthermore, the present study did not take into consideration the evaluation of histological changes in the pulp and relied solely on the clinical and radiographic findings which might be misleading in certain situations mandating the need for further studies to be conducted in this regard taking into consideration the said limitations of the present study.

CONCLUSION

Within the limitations of the present study, combination of diode laser and MTA yielded better clinical and radiographic success rates over the pulpotomy procedures done with the help of MTA alone, though, considering certain factors like the cost, the clinical set-up required for lasers and ease of manipulation make the use of lasers a little restricted. Furthermore, due to the limited number of high-quality clinical research work done on laser-assisted pulpotomies in the literature, different types of lasers, various methodologies used for laser application and different follow-up periods, reaching a net consensus is still

challenging. The present study, thus, mandates the need for further studies including more randomized clinical trials with the same methodology followed to achieve a better consensus.

Acknowledgment

To all the patients who contributed in the study without whom this study would not have been feasible.

Financial support and sponsorship

Nil.

Conflicts of interest

There are no conflicts of interest.

REFERENCES

- Peng L, Ye L, Guo X, Tan H, Zhou X, Wang C, *et al.* Evaluation of formocresol versus ferric sulphate primary molar pulpotomy: A systematic review and meta-analysis. *Int Endod J* 2007;40:751-7.
- Holan G, Eidelman E, Fuks AB. Long-term evaluation of pulpotomy in primary molars using mineral trioxide aggregate or formocresol. *Pediatr Dent* 2005;27:129-36.
- Saltzman B, Sigal M, Clokie C, Rukavina J, Titley K, Kulkarni GV. Assessment of a novel alternative to conventional formocresol-zinc oxide eugenol pulpotomy for the treatment of pulpally involved human primary teeth: Diode laser-mineral trioxide aggregate pulpotomy. *Int J Paediatr Dent* 2005;15:437-47.
- Smail-Faugeron V, Courson F, Durieux P, Muller-Bolla M, Glenny AM, Fron Chabouis H. Pulp treatment for extensive decay in primary teeth. *Cochrane Database Syst Rev* 2014;CD003220. doi: 10.1002/14651858.CD003220.pub2. Update in: *Cochrane Database Syst Rev*. 2018 May 31;5:CD003220. PMID: 25099759.
- Shoji S, Nakamura M, Horiuchi H. Histopathological changes in dental pulps irradiated by CO2 laser: A preliminary report on laser pulpotomy. *J Endod* 1985;11:379-84.
- Mareddy A, Mallikarjun SB, Shetty PV, Rao VV, Chandru TP. Histological evaluation of diode laser pulpotomy in dogs. *J Oral Laser Appl* 2010;10:7-16.
- Agamy HA, Bakry NS, Mounir MM, Avery DR. Comparison of mineral trioxide aggregate and formocresol as pulp-capping agents in pulpotomized primary teeth. *Pediatr Dent* 2004;26:302-9.
- Peng L, Ye L, Tan H, Zhou X. Evaluation of the formocresol versus mineral trioxide aggregate primary molar pulpotomy: A meta-analysis. *Oral Surg Oral Med Oral Pathol Oral Radiol Endod* 2006;102:e40-4.
- Subramaniam P, Konde S, Mathew S, Sugnani S. Mineral trioxide aggregate as pulp capping agent for primary teeth pulpotomy: 2 year follow up study. *J Clin Pediatr Dent* 2009;33:311-4.
- Kabaktchieva R, Gateva N. Vital pulpotomy in primary teeth with Mineral Teeth With Mineral Trioxide Aggregate (MTA). *JIMAB- Annual Proceeding (Scientific Papers)*. Book 2.; 2009.
- Cuadros-Fernández C, Lorente Rodríguez AI, Sáez-Martínez S, García-Binimelis J, About I, Mercadé M. Short-term treatment outcome of pulpotomies in primary molars using mineral trioxide aggregate and Biodentine: A randomized clinical trial. *Clin Oral Investig* 2016;20:1639-45.
- Uloopi KS, Vinay C, Ratnaditya A, Gopal AS, Mrudula KJ, Rao RC. Clinical evaluation of low level diode laser application for primary teeth pulpotomy. *J Clin Diagn Res* 2016;10:ZC67-70.
- Vahid Golpayegani M, Ansari G, Tadayon N. Clinical and radiographic success of low level lasertherapy (LLLT) on primary molars pulpotomy. *Res J Biol Sci* 2010;5:51-5.
- Durmus B, Tanboga I. *In vivo* evaluation of the treatment outcome of pulpotomy in primary molars using diode laser, formocresol, and ferric sulphate. *Photomed Laser Surg* 2014;32:289-95.