

## Open laminoforaminotomy: A lost art?

Nancy E. Epstein

Department of NeuroScience, Winthrop Neuroscience, Winthrop University Hospital, Mineola, NY, USA

E-mail: \*Nancy E. Epstein - [nancy.epsteinmd@gmail.com](mailto:nancy.epsteinmd@gmail.com)

\*Corresponding author

Received: 19 September 15 Accepted: 22 September 15 Published: 25 November 15

### Abstract

**Background:** Open cervical laminoforaminotomy (CLF) provides safe and effective decompression/excision of lateral/foraminal disc herniations/spurs contributing to nerve root compression. CLF's advantages over anterior cervical discectomy/fusion (ACDF) include the lack of risk to anterior structures (esophagus, trachea, carotid, and recurrent laryngeal nerve) and the avoidance of a fusion. Further, advantages over minimally invasive surgery CLF (MIS CLF) include a lower incidence of dural tears, infections, and neural injury. Furthermore, complications are now more often reported in medicolegal suits rather than the spinal surgical literature.

**Methods:** Here, in a select review of the spinal literature in which we specifically focused on the benefits, risks, and complication of open CLF versus the various MIS CLS techniques.

**Results:** Open CLF is a unique posterior cervical surgical technique that is technically demanding. When using an MIS CLF approach that provides limited visualization and maneuverability while incurring greater morbidity (e.g., risks more dural tears, infection, and neural damage).

**Conclusions:** Why not utilize open CLF, adequately and safely, to decompress lateral/foraminally compromised cervical nerve roots, and avoid the risks of MIS CLF or ACDF? Presently, too many spine surgeons automatically choose MIS CLF or ACDF over open CLF; is this because it is a "lost art"?

**Key Words:** Limit morbidity, lost art, minimally invasive surgery: Anterior cervical discectomy/fusion, open laminoforaminotomy

#### Access this article online

**Website:**

[www.surgicalneurologyint.com](http://www.surgicalneurologyint.com)

**DOI:**

10.4103/2152-7806.170435

**Quick Response Code:**



### INTRODUCTION

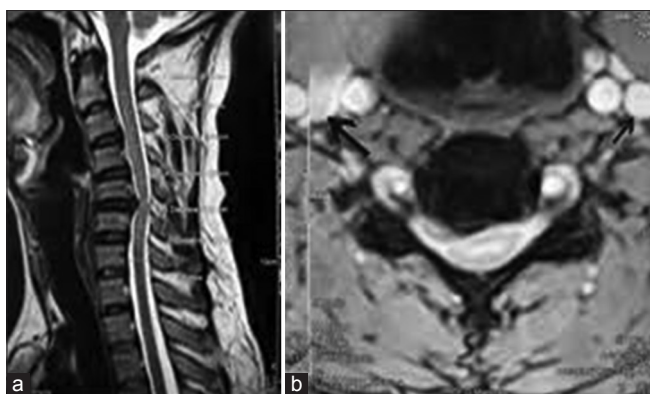Although it provides safe and effective decompression of lateral/foraminally compromised cervical nerve roots, open cervical laminoforaminotomy (CLF) appears to be a lost art [Figures 1-6]. Unfortunately, it is increasingly fashionable to promote minimally invasive surgical (MIS) CLF techniques, including endoscopic or microscope-assisted procedures, despite their inherent increased risks of dural/neural injury attributed to decreased visualization and maneuverability [Tables 1 and 2]. Furthermore, despite pathology warranting open CLF procedures, anterior cervical discectomy/fusions (ACDFs) are still being performed at higher rates than warranted, posing increased

risks to anterior structures (esophagus, trachea, carotid, and recurrent laryngeal nerve) and requiring fusions. Here, we selectively reviewed the literature regarding the pros and cons of open versus MIS CLS techniques. Our aim was to highlight the value of open CLF; a technically demanding technique that should not be abandoned in favor of higher

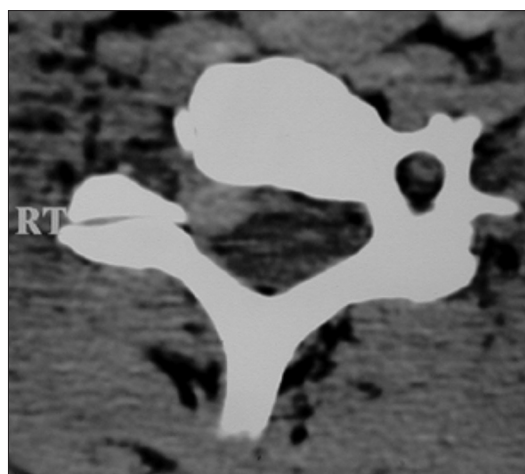
This is an open access article distributed under the terms of the Creative Commons Attribution-NonCommercial-ShareAlike 3.0 License, which allows others to remix, tweak, and build upon the work non-commercially, as long as the author is credited and the new creations are licensed under the identical terms.

**For reprints contact:** [reprints@medknow.com](mailto:reprints@medknow.com)

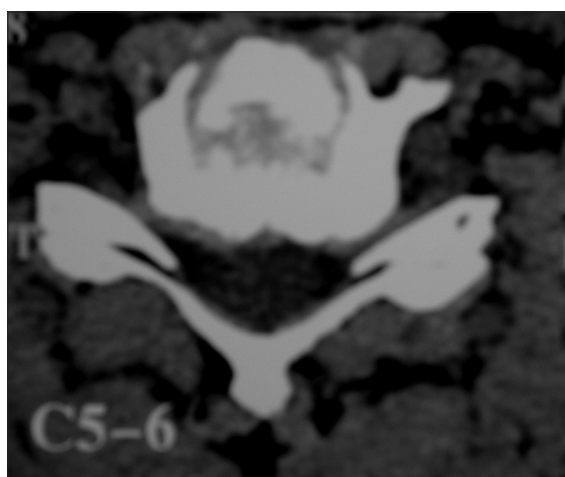
**How to cite this article:** Epstein NE. Open laminoforaminotomy: A lost art?. *Surg Neurol Int* 2015;6:S600-7.  
<http://surgicalneurologyint.com/Open-laminoforaminotomy:-A-lost-art?/>



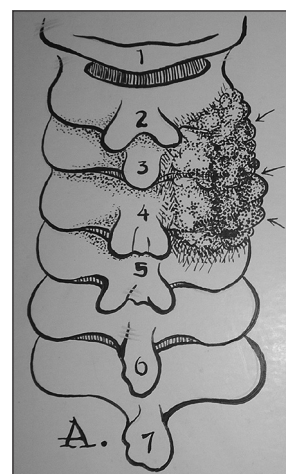
**Figure 1:** Sagittal and axial T2-weighted magnetic resonance images documented a right sided lateral spur (arrow) with soft foraminal discal component. This lesion could be accessed utilizing a unilateral laminoforaminotomy



**Figure 2:** This rotated non contrast CT taken at the C5–C6 level showed a right foraminal soft disc herniation that could be removed utilizing a unilateral laminoforaminotomy



**Figure 3:** This noncontrast axial computed tomography obtained at the C5–C6 level documents bilateral lateral/foraminal compression attributed to laminar shingling which could be decompressed utilizing either bilateral laminoforaminotomy (especially if only involving one level) or a laminectomy



**Figure 4:** This illustration (Joseph A. Epstein/copyright-copyright Nancy E. Epstein) documents a dorsal view of hypertrophic changes involving the right sided C2–C3, C3–C4, and C4–C5 facet joints overlying the right sided laminae C2–C5

risk MIS CLF or unnecessary ACDF. Furthermore, we tabulated and compared the risks/complication rates for open versus MIS CLF, noting, however, that much of the morbidity for the latter MIS CLF procedures now appear in the medicolegal system rather than the spine literature.

### TEACHING VERSUS NONTEACHING HOSPITAL SETTINGS IMPACT CERVICAL SURGICAL OUTCOMES

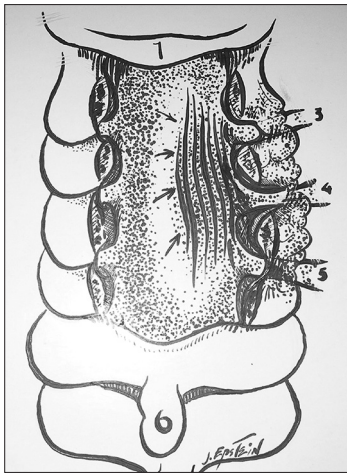
#### Outcomes of cervical spine surgery depend on hospital setting

The premise of this study was that the extent/severity of cervical spine operations performed in teaching versus nonteaching hospitals likely differ. To better evaluate this, Fineberg *et al.* in 2013, compared the outcomes of 212,385 cervical spine operations (anterior/posterior fusion, decompressions [LF, laminectomy,

laminoplasty]) performed for myelopathy/radiculopathy within both of these settings utilizing a national population-based database (2002–2009).<sup>[9]</sup> Notably, 54.6% of cases were performed at teaching hospitals, and correlated with: more multilevel fusions, posterior procedures, males, higher costs, longer length of stay (LOS), and higher in-hospital mortality rates (e.g., correlated with patients over 65 years old, with multiple comorbid factors).

#### Resident training for cervical laminoforaminotomy

Recognizing that most neurosurgical programs do not adequately provide training in open CLF, Ghobrial *et al.* in 2015 developed a skill simulation course for training residents.<sup>[10]</sup> The 22 neurosurgical residents involved filled out two 20-question pretests, next took a “faculty-directed skills simulation course,” and finally, filled out a 20 question posttest. They found that there



**Figure 5:** This illustration (Joseph A. Epstein/copyright-copyright Nancy E. Epstein) shows a laminectomy performed from C2 to C5. On the left medial facetectomy/foraminotomy is illustrated at C2–C3, C3–C4, C4–C5, and C5–C6 levels, sufficient to expose the foraminally exiting nerve roots. Additionally illustrated on the right is (multiple arrows) is decompression of the dura/theal sac at multiple levels where there was prior compression, while also demonstrating more extensive partial facetectomies at the C2–C3, C3–C4, C4–C5, and C5–C6 levels

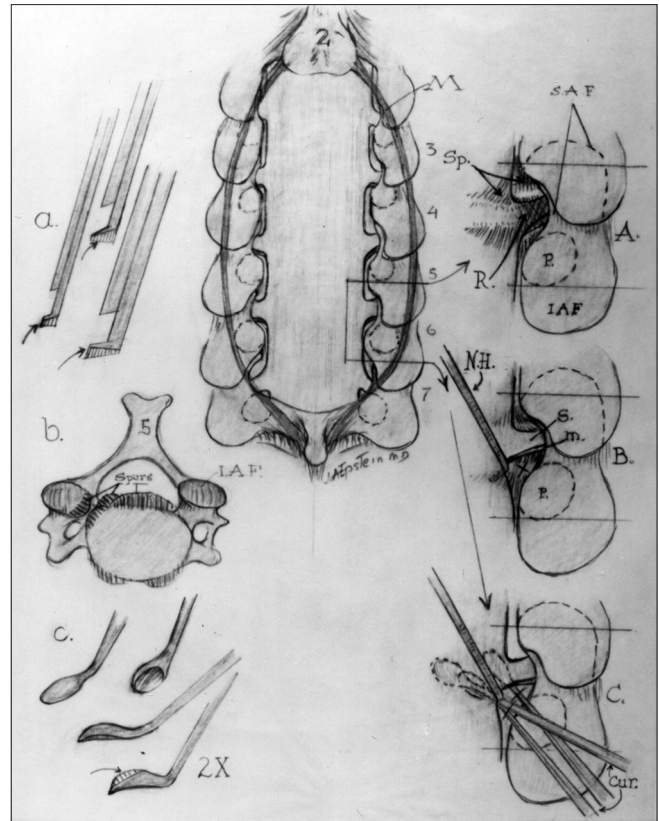
was a “trend” toward higher scores for more advanced residents, but this was not “significant.”

### SAFETY/EFFICACY OF OPEN CERVICAL LAMINOFORAMINOTOMY

In 1993, Zeidman and Ducker emphasized the safety/efficacy of performing CLF in the sitting position for 172 patients with radiculopathy [Table 1].<sup>[19]</sup> They noted that CLF was “not only acceptable, but in certain cases is preferable to the anterior approach.” The CLF was optimal for managing lateral or foraminal nerve root compression, but not appropriate for more anterior lesions actively compressing the cord. In their opinion, “...physicians advocating either procedure exclusively are not providing the patient with the optimal level of care.”

In 2003, Harrop *et al.* evaluated the safety/efficacy of managing 19 patients with cervicothoracic radiculopathy/disc disease utilizing LFs [Table 1].<sup>[11]</sup> Seven women and 12 men had 20 procedures (1 patient required separate bilateral foraminotomies). Patients averaged 54.8 years of age (range 38–73 years), and were followed from 23 to 62 postoperative months. Symptom included typical radicular pain; motor deficits resolved postoperatively in 8 of 11 patients. The authors concluded that cervicothoracic LF “... was a safe and effective procedure in the treatment of patients with laterally located disc herniations.”

In 2009, Heary *et al.* in conjunction with the Joint Section on Disorders of the Spine and Peripheral Nerves of the American Association of Neurological Surgeons



**Figure 6:** In Figure 5, the central image illustrates laminectomy from C2 to C6 was illustrated (illustrator Joseph A. Epstein-copyright Nancy E. Epstein MD) accompanied by bilateral medial facetectomy/foraminotomy C2–C3, C3–C4, C4–C5, C5–C6, and C6–C7. Also noted is facet/wiring/fusion that has since been replaced by other fusion techniques. (a) The Kerrison rongeurs utilized to perform cervical laminoforaminotomies must be filed down so that the footplate does not damage the exiting nerve root. (b) The typical axial view of a central/ventral spur. (c) The Epstein down-biting curette used to remove sequestered lateral/foraminal cervical disc fragments and spurs. (A) Keyhole foraminotomy illustrated documenting the extent of medial resection of the superior articular facet and inferior articular facet, which often requires some drilling down of the medial aspect of the pedicle. This affords adequate visualization of the spinal cord (Sp.) and foraminally exiting nerve root (R.) (B) With a micro dissector/nerve hook (N.H.), the inferior axillary portion of the exiting nerve root (motor [m.] and sensory [s.] branches) is freed exposing the disc space. (C) Using the down-biting curette (curr.) and often the nerve hook as well multiple small burst sequestered disc fragments or spur can be removed through the axillary exposure of the exiting nerve root

and Congress of Neurological Surgeons, performed an evidence-based evaluation of the efficacy of CLF (LF) for managing cervical radiculopathy [Table 1].<sup>[12]</sup> They utilized the National Library of Medicine and Cochrane Database (note all studies were Class III) to document that LF correlated with improvement for patients with cervical radiculopathy attributed to soft lateral/foraminal discs or spondylosis. Nevertheless, they found multiple major flaws in the study designs.

In 2014, Church *et al.* reported (in 2014) on the safety/efficacy of CLF (foraminotomy [FOR]) for treating 1085

**Table 1: Studies utilizing laminoforaminotomy**

Author (reference) year	Number of patients	Operation: Open CLF ^	Outcomes	Complications
Zeidman and Ducker <sup>[19]</sup> 1993	172	Open CLF ^		
Harrop <i>et al.</i> <sup>[11]</sup> 2003	19	Open cervical-thoracic LF ^ ^		
Church <i>et al.</i> <sup>[4]</sup> 2014	338	Open CLF ^	Outcomes 90% improved pain 93% returned to work	Complications 3.3% reoperations 6.2% over average 4.15 years 24.3% over average 10 years
Bydon <i>et al.</i> <sup>[2]</sup> 2014	151	Open CLF ^	Reoperation rate 9.9% (15 patients) Reoperation time Average 2.4 years Reoperation levels Same level: 6.6% (10 patients) Adjacent level: 1.3% (2 patients) Distant level: 1.9% (3 patients)	Second surgery ACDF** 80% Repeat PCF*** 6.7% Laminectomy/posterior fusion 13.3%
Tomaras <i>et al.</i> <sup>[16]</sup> 1997	183 (outpatient)	Open CLF ^	Outcomes Good/excellent 92.8% no WC* 77.8% with WC*	No complications

\*WC: Workers' compensation, ^CLF: Cervical laminoforaminotomy, ^^LF: Laminoforaminotomy, \*\*ACDF: Anterior cervical discectomy/fusion, \*\*\*PCF: Posterior cervical foraminotomy

**Table 2: Minimally invasive laminoforaminotomy techniques**

Author (reference) year	Number of patients	Operations MIS-CLF ^ MIS-CLF ^ MELF ^ ^ ^ ^	Outcomes	Complications
Figueiredo <i>et al.</i> <sup>[8]</sup> 2006	39	MIS-CLF ^ Modified keyhole FOR	24 procedures From C3-C6 Levels 12 at C6-C7 3 at C7-T1	None
Adamson <sup>[1]</sup> 2001	100	MIS-MELF ^ ^ ^ ^	Returned to work 97% No mortality	Complications 2 paresthesias 2 dural tears 1 infection
Fessler and Khoo <sup>[7]</sup> 2002	25 MIS-MELF ^ ^ ^ ^ versus 26 open CLF****	MIS-MELF ^ ^ ^ ^ Comparable outcomes at 16 months	MIS-MELF ^ ^ ^ ^ EBL***** 128 cc LOS*** 20 h Durotomy 2 Neck pain Resolved 40% Improved 47% Radiculopathy Resolved 54% Improved 38%	Open CLF**** EBL***** 246 cc LOS*** 68 h Durotomy 0 Neck pain Resolved 33% Improved 56% Radiculopathy Resolved 48% Improved 40%
Clark <i>et al.</i> <sup>[5]</sup> 2011	19 studies	MIS-CLF ^ versus open CLF****	MIS-CLF ^ EBL 52.8 ml Time 58.3 Narcotics 2.5 Eq. LOS 1.0 day	Open CLF**** EBL 173.5 ml Time 108.3 Narcotics 27.6 Eq. LOS 3.2 days
Lidar and Salame <sup>[13]</sup> 2011	32	MIS-CLF ^	Outcomes Motor 100% resolved Sensory Resolved 21	Complications 1 dural tear 1 persistent pain
Choi <i>et al.</i> <sup>[3]</sup> 2013	1	MIS-CLF ^ 65 year old right C5-C7	Outcome Shoulder/neck pain	Complication Postoperative C5-T1 EDH

Contd...

**Table 2: Contd...**

Author (reference) year	Number of patients	Operations MIS-CLF ^ MIS-CLF ^ MELF ^ ^ ^ ^	Outcomes	Complications
Winder <sup>[17]</sup> 2011	107 two groups	Open-CLF**** 65 versus MIS*-MTPF ^ ^ 42	Comparable outcome Both groups	Complications; 0 benefits MTPF Shorter surgery Less EBL**/pain Shorter LOS***
Yadav <i>et al.</i> <sup>[18]</sup> 2014	50	MIS-CLF ^	Outcomes Excellent/good	Complications 1 dural tear 3 minor bleeding 2 C5 root palsies
Liu <i>et al.</i> <sup>[14]</sup> 2013	97 two groups	CA ^ ^ ^ 45 versus 52 MELF ^ ^ ^ ^ 52 outcomes Comparable both groups	MELF ^ ^ ^ ^ Fluoro ^ ^ 12.1 s Surgery time 24 m LOS*** 0.13 day EBL ***** 31.9 ml	CA ^ ^ ^ Fluoro 60.3 s Surgery time 95.1 m LOS*** 1.1 day EBL ***** 75.8 ml

^MIS-CLF: Minimally invasive cervical laminoforaminotomy, ^^MTPF: Microscopic tubular assisted posterior cervical laminoforaminotomy, \*MIS: Minimally invasive surgery, ^^CA: Cervical arthroplasty, \*\*EBL: Estimated blood loss, \*\*\*LOS: Length of stay, ^^^MELF: Microendoscopic laminoforaminotomy, \*\*\*\*CLF: Cervical laminoforaminotomy, EDH: Epidural hematoma, FOR: Foraminotomy

patients with soft disc herniations versus osteophytes [Table 1].<sup>[4]</sup> The 338 patients included in the final study (interviewed) had a mean follow-up interval of 10 years (interviews). Of these, 90% had experienced improvement in postoperative pain, weakness, or function after FOR, and 93% returned to work. The complication rate was 3.3%, with 6.2% experiencing recurrent radiculopathy requiring additional surgery. Better outcomes correlated with soft foraminal discs versus spurs/osteophytes. The authors concluded: "... FOR is a highly effective surgical treatment for cervical radiculopathy with a low incidence of complications".

Also in 2014, Bydon *et al.* evaluated the frequency/timing of persistent/renewed radiculopathy or reoperations required an average of 4.15 years following 151 "open" unilateral posterior cervical foraminotomy (PCF) [Table 1].<sup>[2]</sup> Of these, 9.9% (15 patients) required additional surgery an average of 2.4 years after the original surgery (with > 10 years of follow-up the reoperation rate was 24.3%). Those exhibiting more preoperative neck pain had higher reoperation rates over shorter durations. Second operations included ACDF (80%), repeat PCF (6.7%), or laminectomy/posterior cervical fusion (13.3%). Surgery was performed at the same level (6.6%, 10 patients) versus, adjacent-segments (1.3%, 2 patients) or distant levels (1.9%, 3 patients) Radiculopathy improved in 85% of patients; 91.4% resolved within 1 postoperative month.

### OUTPATIENT SURGICAL TREATMENT OF CERVICAL RADICULOPATHY WITH OPEN CERVICAL LAMINOFORAMINOTOMY; ITS BETTER TO BE LUCKY THAN GOOD

In 1997, Tomaras *et al.* performed outpatient open cervical LF utilizing "limited posterior dissections"

(not MIS procedures) to complete LF in 200 carefully selected patients (without significant comorbidities and willingness to do this) [Table 1].<sup>[16]</sup> Although none of these patients required emergent readmissions, I would argue that performing cervical outpatient procedures is dangerous, whether anterior or posterior, and the medicolegal literature contains reports of such patients becoming quadriplegic at home the first postoperative night. Nonetheless, in this series, 183 patients were followed from 3 (insufficient period of time) to 43 months, for an average of 19 months. For patients not on workers' compensation, they observed a 92.8% rate of excellent/good outcomes (e.g., returning to work/other activities within an average of 2.9 weeks). In comparison, only 77.8% of workers' compensation patients had excellent/good results and required longer periods (average 7.6 weeks) before becoming fully functional.

### MINIMALLY INVASIVE SURGERY FOR CERVICAL LAMINOFORAMINOTOMY

#### 100 microendoscopic-assisted laminoforaminotomies

In 2001, Adamson reported on the performance of 100 microendoscopic-assisted LFs to treat unilateral cervical radiculopathy attributed to lateral/foraminal disc/spur/stenosis [Table 2].<sup>[1]</sup> He compared these results with classical open LF and ACDF with/without fusion. Utilizing a microendoscopic visualization system, these procedures were performed in the sitting position. Excellent/good results were achieved in 97 patients (e.g., they returned to work or prior level of function). Complications included; 2 patients with occasional paresthesias or numbness, 2 with dural tears, and 1 with a superficial wound infection; notably there were no mortalities.

### Microendoscopic foraminotomy in 25 patients

In 2002, Fessler and Khoo discussed the safety/efficacy of a microendoscopic foraminotomy (MEF) technique successfully utilized in 25 patients with lateral/foraminal disc/spurs [Table 2].<sup>[7]</sup> They prospectively employed the MEF technique in 25 patients and compared results/outcomes with 26 other patients treated utilizing the open LF. MEF patients exhibited: less blood loss (138 ml MEF vs. 246 ml open LF per level), recovered faster, had shorter LOS (20 h MEF vs. 68 h open LF), required lower doses of narcotics (11 Eq. MEF vs. 40 Eq. open LF), but exhibited more durotomies (2 [8%] MEF vs. 0 for open LF). Of critical import was that over a mean postoperative period of 16 months, patients from both groups exhibited comparable postoperative outcomes [Table 2].

### Minimally invasive modified keyhole laminoforaminotomy

In 2006, Figueiredo *et al.* performed 39 minimally invasive modified keyhole LF from the C3-C4 through the C7-T1 levels; anatomic landmarks of the posterior cervical vertebral body facilitated an adequate decompression of the intervertebral foramen with minimal bone removal [Table 2].<sup>[8]</sup> Resections included; 24 LF from C3-C4, C4-C5, and C5-C6; an additional 12 were performed at C6-C7 and 3 at C7-T1. The mean length of the nerve root was 4.6 mm, and the mean percentage of bony resection was 21.8%, 7.5%, 11.3%, and 11.5%, respectively, for the superior and inferior laminae and facets. The authors concluded; opening the intervertebral foramen posteriorly consistently exposed sufficient nerve root length and allowed for sufficient access to the intervertebral disc.

### Minimally invasive surgery consisting of cervical laminoforaminotomy in 19 studies

In 2011, Clark *et al.* noted the potential benefits of MIS surgery in general; these included smaller incisions, the potential for reduced pain, less blood loss, and shortened LOS [Table 2].<sup>[5]</sup> The authors included 19 of 162 originally identified studies that cited at least 1 case of LF performed open or with an MIS technique. They found that percutaneous MIS CLF led to; reduced blood loss (estimated blood loss [EBL]) (173.5 ml open CLF vs. 52.8 ml for MIS CLF,  $n = 670$  patients), shorter surgery (108.3 open CLF vs. 58.3 min MIS CLF,  $n = 882$  patients), less inpatient pain medications/narcotics (27.6 Eq. open CLF vs. 2.5 Eq. MIS CLF,  $n = 356$  patients), and shorter LOS (3.2 days open CLF vs. 1.0 days MIS CLF  $n = 1472$  patients). Nevertheless, they questioned their conclusions based on the inhomogeneity of data available.

### MetRx tubular retractor system with the operating microscope utilized in 32 patients undergoing MIS-CLF

Also in 2011, Lidar and Salame retrospectively evaluated 32 patients undergoing MIS-CLF utilizing a MetRx

tubular retractor system with the operating microscope over a 4 year period (2004–2008) [Table 2].<sup>[13]</sup> This article raised a major confounding factor; many studies included the performance of a cervical LF involving only bony decompression without foraminal disc/spur excision. The authors performed a chart review, analyzing outcomes using the visual analog scale (VAS) for neck and arm pain, and the short form (SF)-36 health survey questionnaire assess 32 patients followed an average of 39 months. Motor deficits improved in all patients. Sensory findings resolved while sensory findings resolved in 21 and improved in 7 patients. All VAS and SF-36 results showed “significant improvement.” However, 1 patient sustained a dural tear (apparently without a cerebrospinal fluid [CSF] leak), and 1 patient had persistent neck pain.

### Microscopic tubular assisted posterior cervical laminoforaminotomy (42 patients) versus open laminoforaminotomy (65 patients)

In 2011, Winder and Thomas performed 107 LF: 42 utilized a microscopic tubular assisted posterior CLF (MTPF) approach (1999–2009) versus 65 patients who were treated with open LF [Table 2].<sup>[17]</sup> Their hypothesis was that the MTPF would; reduce tissue damage, operative time, blood loss, narcotic use, and LOS, and would be comparable to endoscopic posterior foraminotomy (EPF). Although the duration of surgery and complication rates were comparable for groups, MTPF significantly reduced EBL, postoperative narcotic requirements, and LOS. Results were also comparable to EPF.

### Posterior endoscopic minimally invasive surgery for decompression of cervical spondylotic myelopathy

In 2014, Yadav *et al.* evaluated the safety/efficacy of utilizing an MIS LF either unilaterally or bilaterally for the treatment of cervical spondylotic myelopathy (CSM) over single or multiple levels [Table 2].<sup>[15]</sup> Advantages of this technique, they argued, included preservation of stability and avoiding a fusion. Their series included 50 patients with myelopathy (average Nurick Grade 2.6, followed an average of 19 months), with predominantly posterior compressive lesions or multilevel anterior disease with an adequate lordotic curvature. Patients had varying levels of pathology that included: in 5 patients (2 levels), in 23 patients (3 levels), in 12 patients (4 levels), and in 10 patients (5 levels). Notably, better outcomes correlated with lesser preoperative deficits and fewer levels of cord compression. Of interest, complications included; one dural tear, minor bleeding (3 patients), and temporary C5 root injuries (2 patients). The authors concluded endoscopic decompression of multilevel CSM was safe/effective and could be accomplished with limited morbidity.

## COMPLICATIONS OF MINIMALLY INVASIVE SURGERY LAMINOFORAMINOTOMY

### Postoperative cervical spinal epidural hematoma after laminoforaminotomy

In 2013, Choi *et al.* presented the case of a 65-year-old male who had an MIS CLF performed on the right side at the C5–C6 and C6–C7 levels [Table 2].<sup>[5]</sup> Intraoperatively, no significant bleeding was noted. However, postoperatively, when the patient complained of unremitting right shoulder/neck pain, a follow-up magnetic resonance (MR) revealed a diffuse cervical epidural hematoma from C5 to T1 level on the right side with resultant cord and root compression from C5 to C7. When the wound was reopened, a source of bleeding was found within the muscle, and the clot was removed; symptoms were significantly improved following the second procedure.

### Complications of instrumentation with minimally invasive cervical laminoforaminotomy and lateral mass screw placement

In 2012, Mikhael *et al.* under fluoroscopic guidance utilized an MIS tubular system (paramedian muscle splitting approach) to perform multilevel posterior cervical LF with lateral mass screw placement.<sup>[15]</sup> Theoretical advantages of this MIS approach were presumed to include; reduced EBL, pain, and LOS versus open LF procedures. Complications, however, included; incomplete decompression, poor screw placement, and neurologic injury (e.g., variously attributed to “poor access and visualization”). Ultimately, they recommended that the: “surgeon must ensure that goals of the surgery, both technical and clinical outcomes, are comparable to those of a conventional open procedure.”

## ONE LEVEL MICROENDOSCOPIC LAMINOFORAMINOTOMY VERSUS CERVICAL ARTHROPLASTY FOR CERVICAL SPONDYLOTIC RADICULOPATHY

In 2013, Liu *et al.* compared the results for treating one-level cervical spondylotic radiculopathy utilizing either a microendoscopic LF (MELF: 52 patients) versus cervical arthroplasty (CA) techniques (45 patients) [Table 2].<sup>[14]</sup> Outcomes were assessed using the neck disability index, SF-36, and VAS up to 24 months postoperatively. For CA versus MELF, fluoroscopy (CA, 60.3 s vs. MELF, 12.1 s) and surgical times (CA, 95.1 min; MELF, 24.0 min;  $P < 0.01$ ) were significantly longer for CA, along with LOS (CA, 1.1 days; MELF, 0.13 days;  $P < 0.01$ ) and EBL (EBL; CA, 75.8 ml; MELF, 31.9 ml;  $P < 0.01$ ). Outcomes, however, for both groups were comparable. The authors concluded that MELF versus CA produced comparable outcomes, while demonstrating

benefits regarding less blood loss, surgical time, fluoroscopy time, and shortened LOS.

## MINIMALLY INVASIVE ENDOSCOPIC CERVICAL LAMINOFORAMINOTOMY VERSUS “OPEN” CERVICAL LAMINOFORAMINOTOMY: DO THE RISKS OUTWEIGH THE BENEFITS?

In 2009, Epstein discussed the learning curve associated with utilizing MIS CLF endoscopic approaches to the cervical spine versus “open” CLF and asked “was it worth it?”.<sup>[6]</sup> She noted that performing open keyhole foraminotomies with the operating microscope are already very demanding procedures, and that adequate exposure is critical for avoiding neural/dural injury. Furthermore, utilizing open techniques, there is much greater maneuverability for utilizing the nerve hook and down-biting curette to free the affected nerve root from underlying scar, and resect underlying soft disc herniations, and ossified spurs. When performing “open” CLF, it was also critical to perform not only the dorsal decompression but also to resect the disc/spurs; failure to do so resulted typically in persistent symptoms, and more reoperations. Additionally, many of the complications attributed to MIS CLF were unacceptable: For example the high 2–8%, rate of cerebrospinal fluid fistulas/dura tears, and a higher rate of neurological injury and infection [compare Tables 1 and 2]. Furthermore, the actual number of complications occurring in MIS CLF is likely underreported, as few surgeons and even fewer journals publish these complications (e.g., few such case reports are published); rather they are found in the medicolegal literature. One example, found in Verdict Search (a medicolegal search engine), involved a physician undergoing a bilateral C4–C5 MIS CLF; he sustained permanent postoperative bilateral C5 palsies. So why risk your patient being a victim of the “learning curve,” particularly since classic open CLF are successful in up to 92.8% of cases, and outcomes for MIS CLF and “open” CLF appear comparable over the longer term [Table 2].

## A SHORT TUTORIAL ON THE SELECTION AND PERFORMANCE OF OPEN CERVICAL LAMINOFORAMINOTOMY [FIGURES 1-6]

### Magnetic resonance, computed tomography, and Myelo-CT findings for patients who are candidates for open cervical laminoforaminotomy

For patients to be candidates for open CLF, the magnetic resonance (MR), computed tomography (CT), and/or Myelo-CT findings should demonstrate a lateral/foraminal soft disc herniation or mild-moderate spur (major spurs should be resected anteriorly). In order to

differentiate soft disc from calcified spur, both MR- and CT-based studies should be performed; the MR scans best demonstrate the soft-tissues, while the CT scans readily identify the calcification/ossification (e.g., also determine whether ossification of the posterior longitudinal ligament [OPLL] is present). Note that large spurs or OPLL at single or multiple levels may warrant a ventral approach, or if the lordosis is preserved, a multilevel bilateral decompressive procedure (e.g., laminectomy with/without fusion). If there is focal hypertrophy of multiple facet joints unilaterally, that contribute to significant cord as well as root compression, then a laminectomy rather than multiple keyhole foraminotomies/hemilaminectomies should be performed [Figures 1-6]. Alternatively, where there is focal lateral/foraminal root compromise, the open CLF exposure may be optimal [Figure 6]. Critical to this exposure is the careful identification of the foraminal exiting nerve root; typically this has a higher takeoff than one would anticipate which is why an adequate laminotomy of the cephalad unilateral lamina is essential, along with often an extended medial facetectomy/FOR. Additionally, the inferior unilateral laminotomy must allow for sufficient exposure of the pedicle (often requiring shaving down the medial pedicle) and axillary portion of the nerve root, as this is your access point. Once the root is clearly identified, a micro nerve hook is carefully introduced under the microscope to differentiate nerve root from underlying disc. As the motor root occasionally does not have a dural investment, it may appear very white, and can be readily mistaken for disc. Once freed from the epidural veins (often engorged), the nerve root can be mobilized with the micro nerve hook, and underlying disc fragments may be teased away or resected with down-biting Epstein curettes. Notably, these disc fragments are typically small; it is important, therefore, to recognize when you are “done” (e.g., avoid CSF fistulas by overly aggressive manipulation to remove the anterior disc confined by the annulus).

## SUMMARY

Spine surgeons, particularly in major teaching hospitals, now often adopt minimally invasive approaches to address complex cervical pathology or choose maximally invasive complex fusions where smaller open procedures may suffice. Specifically, as time goes on, fewer professors themselves know how to perform open CLF to address unilateral radiculopathy attributed to lateral/foraminal disc/spurs. Therefore, they will choose either variants of MIS CLF to address these lesions (e.g., with typically inadequate/limited exposure and greater morbidity), or even more frequently, opt for overly extensive ACDF. With the oversight of such “mentors,” one should carefully look at the learning curves for both professors and spine residents alike. Again, these data will not

likely be found in the spine literature, but rather, among medicolegal suits.

## Financial support and sponsorship

Nil.

## Conflicts of interest

There are no conflicts of interest.

## REFERENCES

1. Adamson TE. Microendoscopic posterior cervical laminoforaminotomy for unilateral radiculopathy: Results of a new technique in 100 cases. *J Neurosurg* 2001;95 1 Suppl: 51-7.
2. Bydon M, Mathios D, Macki M, de la Garza-Ramos R, Sciubba DM, Witham TF, et al. Long-term patient outcomes after posterior cervical foraminotomy: An analysis of 151 cases. *J Neurosurg Spine* 2014;21:727-31.
3. Choi JH, Kim JS, Lee SH. Cervical spinal epidural hematoma following cervical posterior laminoforaminotomy. *J Korean Neurosurg Soc* 2013;53: 125-8.
4. Church EW, Halpern CH, Faight RW, Balmuri U, Attiah MA, Hayden S, et al. Cervical laminoforaminotomy for radiculopathy: Symptomatic and functional outcomes in a large cohort with long-term follow-up. *Surg Neurol Int* 2014;5 Suppl 15:S536-43.
5. Clark JG, Abdullah KG, Steinmetz MP, Benzel EC, Mroz TE. Minimally invasive versus open cervical foraminotomy: A systematic review. *Global Spine J* 2011;1:9-14.
6. Epstein NE. Minimally invasive/endoscopic vs “open” posterior cervical laminoforaminotomy: Do the risks outweigh the benefits? *Surg Neurol* 2009;71:330-1.
7. Fessler RG, Khoo LT. Minimally invasive cervical microendoscopic foraminotomy: An initial clinical experience. *Neurosurgery* 2002;51 5 Suppl: S37-45.
8. Figueiredo EG, Castillo De la Cruz M, Theodore N, Deshmukh P, Preul MC. Modified cervical laminoforaminotomy based on anatomic landmarks reduces need for bony removal. *Minim Invasive Neurosurg* 2006;49:37-42.
9. Fineberg SJ, Oglesby M, Patel AA, Pelton MA, Singh K. Outcomes of cervical spine surgery in teaching and non-teaching hospitals. *Spine (Phila Pa 1976)* 2013;38:1089-96.
10. Ghobrial GM, Balsara K, Maulucci CM, Resnick DK, Selden NR, Sharan AD, et al. Simulation training curricula for neurosurgical residents: Cervical foraminotomy and durotomy repair modules. *World Neurosurg* 2015;84:751-755.e7.
11. Harrop JS, Silva MT, Sharan AD, Dante SJ, Simeone FA. Cervicothoracic radiculopathy treated using posterior cervical foraminotomy/discectomy. *J Neurosurg* 2003;98 2 Suppl: 131-6.
12. Heary RF, Ryken TC, Matz PG, Anderson PA, Groff MW, Holly LT, et al. Cervical laminoforaminotomy for the treatment of cervical degenerative radiculopathy. *J Neurosurg Spine* 2009;11:198-202.
13. Lidar Z, Salame K. Minimally invasive posterior cervical discectomy for cervical radiculopathy: Technique and clinical results. *J Spinal Disord Tech* 2011;24:521-4.
14. Liu GM, Wang YJ, Wang DS, Liu QY. Comparison of one-level microendoscopy laminoforaminotomy and cervical arthroplasty in cervical spondylotic radiculopathy: A minimum 2-year follow-up study. *J Orthop Surg Res* 2013;8:48.
15. Mikhael MM, Celestre PC, Wolf CF, Mroz TE, Wang JC. Minimally invasive cervical spine foraminotomy and lateral mass screw placement. *Spine (Phila Pa 1976)* 2012;37:E318-22.
16. Tomaras CR, Blacklock JB, Parker WD, Harper RL. Outpatient surgical treatment of cervical radiculopathy. *J Neurosurg* 1997;87:41-3.
17. Winder MJ, Thomas KC. Minimally invasive versus open approach for cervical laminoforaminotomy. *Can J Neurol Sci* 2011;38:262-7.
18. Yadav YR, Parihar V, Ratre S, Kher Y, Bhatele PR. Endoscopic decompression of cervical spondylotic myelopathy using posterior approach. *Neurol India* 2014;62:640-5.
19. Zeidman SM, Ducker TB. Posterior cervical laminoforaminotomy for radiculopathy: Review of 172 cases. *Neurosurgery* 1993;33:356-62.