

Feasibility and Perception of Cross-sex Face Transplantation to Expand the Donor Pool

Michael Sosin, MD
 Isabel S. Robinson, MD
 Gustave K. Diep, MD
 Allyson R. Alfonso, BS, BA
 Samantha G. Maliha, MD
 Daniel J. Ceradini, MD
 Jamie P. Levine, MD
 David A. Staffenberg, MD
 Pierre B. Saadeh, MD
 Eduardo D. Rodriguez, MD, DDS

Background: A major challenge in face transplantation (FT) is the limited donor allograft pool. This study aimed to investigate the feasibility of cross-sex FT (CSFT) for donor pool expansion by: (1) comparing craniomaxillofacial metrics following CSFT versus same-sex FT (SSFT); and (2) evaluating the public and medical professionals' perception of CSFT.

Methods: Seven cadaveric FTs were performed, resulting in both CSFT and SSFT. Precision of bony and soft tissue inset was evaluated by comparing pre- versus post-operative cephalometric and anthropometric measurements. Fidelity of the FT compared to the virtual plan was assessed by imaging overlay techniques. Surveys were administered to medical professionals, medical students, and general population to evaluate opinions regarding CSFT.

Results: Five CSFTs and 2 SSFTs were performed. Comparison of recipients versus post-transplant outcomes showed that only the bigonial and medial intercanthal distances were statistically different between CSFT and SSFT ($P = 0.012$ and $P = 0.010$, respectively). Of the 213 survey participants, more were willing to donate for and undergo SSFT, compared with CSFT (donate: 59.6% versus 53.0%, $P = 0.001$; receive: 79.5% versus 52.3%, $P < 0.001$). If supported by research, willingness to receive a CSFT significantly increased to 65.6% ($P < 0.001$). On non-blinded and blinded assessments, 62.9% and 79% of responses rated the CSFT superior or equal to SSFT, respectively.

Conclusions: Our study demonstrates similar anthropometric and cephalometric outcomes for CSFT and SSFT. Participants were more reticent to undergo CSFT, with increased willingness if supported by research. CSFT may represent a viable option for expansion of the donor pool in future patients prepared to undergo transplantation. (*Plast Reconstr Surg Glob Open* 2020;8:e3100; doi: 10.1097/GOX.0000000000003100; Published online 24 September 2020.)

INTRODUCTION

Facial transplantation (FT) has undergone significant changes over the past 15 years, as it transitioned from its experimental stage to its establishment as a reconstructive option for devastating facial deformities. The indications for FT candidacy continue to evolve, and so too does the selection criteria for donor allografts.¹⁻⁵ The shortage of donor facial allografts has led to prolonged transplant wait times.⁶ This is due to the need for rigorous immunologic, anatomic, and color-specific donor-recipient matching, as well as cultural and societal beliefs, and

educational gaps leading to reluctance to donate facial tissue. The focus in FT research is shifting in addressing the composition of the donor pool and emphasizing selection criteria as a priority. To date, 46 FTs have been reported, all of which were same-sex FT (SSFT).^{4,5,7-11} Our group postulates that cross-sex FT (CSFT) can increase the availability of donors. Although a clinical CSFT has never been attempted, sex-mismatched solid organ transplantation (SOT) is common, and cross-sex upper and lower extremity vascularized composite allotransplantation (VCA) have been performed.¹²⁻¹⁷ However, currently there is a lack of evidence supporting or refuting CSFT, and concerns related to skeletal and soft tissue discrepancies due to

From the Hansjörg Wyss Department of Plastic Surgery, NYU Langone Health, New York, N.Y.

Received for publication June 30, 2020; accepted July 20, 2020.

Copyright © 2020 The Authors. Published by Wolters Kluwer Health, Inc. on behalf of The American Society of Plastic Surgeons. This is an open-access article distributed under the terms of the [Creative Commons Attribution-Non Commercial-No Derivatives License 4.0 \(CCBY-NC-ND\)](#), where it is permissible to download and share the work provided it is properly cited. The work cannot be changed in any way or used commercially without permission from the journal.

DOI: 10.1097/GOX.0000000000003100

Disclosure: Dr. Rodriguez has received speaker honoraria for unrelated activities from DePuy Synthes CMF and KLS Martin. All the other authors have no financial interest to declare. This work was supported by the Office of Naval Research (Grant N00014-10-1-0868), the US Department of Defense—Congressional Directed Medical Research Programs (under Reconstructive Transplant Research Award W81XWH15-2-0036), and New York University Langone Health.

sex-specific characteristics remain.¹⁸ Furthermore, there is limited understanding of how CSFT would be perceived in the community. This two-part study compares the anthropometric and cephalometric outcomes between CSFT and SSFT to determine the anatomic feasibility and precision of sex-mismatched FT. The second part investigates the public opinion of CSFT and assesses the impact of research and education on perceptions regarding CSFT.

METHODS

Following Institutional Review Board approval, a two-part study methodology was designed. First, a cadaveric study was conducted simulating both CSFT and SSFT. A survey was then distributed to participants, assessing their opinions on CSFT.

Cadaveric Study

A total of 7 mock en-bloc total face and scalp transplants were performed using 14 cadaveric human models. Specimens were selected at random and paired before FT to randomize anthropometric characteristics, resulting in both CSFT and SSFT. Before each cadaveric FT, craniofacial computed tomographic (CT) scans of the donor and recipient were obtained. The craniofacial CT scan data were uploaded to the computerized surgical planning (CSP) software (3D Systems; Rock Hill, SC). Computerized modeling with superimposition of the donor and recipient was performed to optimize the location of the nasofrontal, bilateral zygomatic, and genial osteotomies (Fig. 1). Once the surgical plan was validated, custom-fit cutting guides were 3D-printed. Pre-transplant cephalometric data were obtained using the pre-operative CT images and anthropometric measurements were collected by the operating surgeons. Bony and soft tissue parameters included head circumference, right and left palpebral apertures, biparietal distance, fronto-occipital distance, bizygomatic distance, bigonial distance, medial and lateral intercanthal distances, right and left external auditory meatus to ipsilateral lateral canthus distances, upper and lower facial heights, sella-nasion–point A (SNA) angle, sella-nasion–point B (SNB) angle, and mandibular angle (Fig. 2).

Once all the pre-operative data were obtained, two teams composed of four surgeons each worked simultaneously on the donor allograft procurement and the recipient preparation for transplantation. The surgical details and techniques used were previously reported.¹⁹ Following completion of the FTs, post-operative data were obtained on the post-transplant cadavers via soft tissue measurements and CT scans. Finally, the craniofacial CT images were utilized to assess the fidelity of the computerized surgical plans compared with the actual transplantation outcomes, using overlay techniques and heat map analysis (Fig. 3). Precision of bony and soft tissue elements following allograft inset between the CSFT and SSFT groups was evaluated via anthropometric and cephalometric analyses.

Survey Development and Distribution

Surveys were tailored and distributed to three distinct groups of participants, including medical professionals, medical students, and members of the general public in New York City. Medical professionals were composed of plastic surgery attendings and residents, non-plastic surgery attendings, and non-physician medical professionals such as nurses or therapists. All participants were at least 18 years old and could speak and read English. Demographic data such as age, sex, religion, and race were recorded. Participants' willingness to donate and receive CSFT and SSFT was evaluated. Additionally, participants were asked to rate aesthetic outcomes of cadaveric FT images. First, participants were blinded to donor and recipient sexes and asked to rate aesthetic outcomes of one CSFT and one SSFT on a five-point Likert scale. Next, participants were un-blinded and asked to rate a different CSFT and SSFT. Finally, the participants were asked to determine which outcomes were superior between the CSFTs versus SSFTs (Fig. 4).

Data Analysis

Statistical calculations were performed using Statistical Package for the Social Sciences (SPSS) software (version 25.0, IBM Corp., Armonk, NY). Paired *t*-tests and McNemar's tests were used for comparative analysis where appropriate. Statistical significance was set to a value of

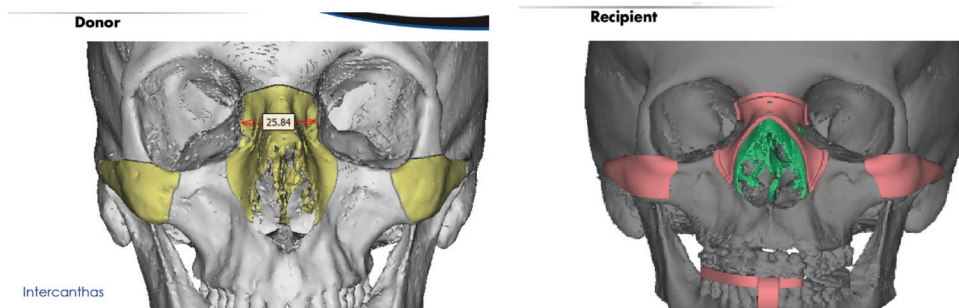


Fig. 1. Computerized modeling using preoperative CT scan images of the donor and recipient. Cephalometric measurements can be obtained, as demonstrated here with the medial intercanthal distance (A). The preoperative CT scans data can be uploaded to the computerized surgical planning (CSP) software to determine the optimal osteotomy locations (B). Reprinted with permission from and copyrights retained by Eduardo D. Rodriguez, MD, DDS.

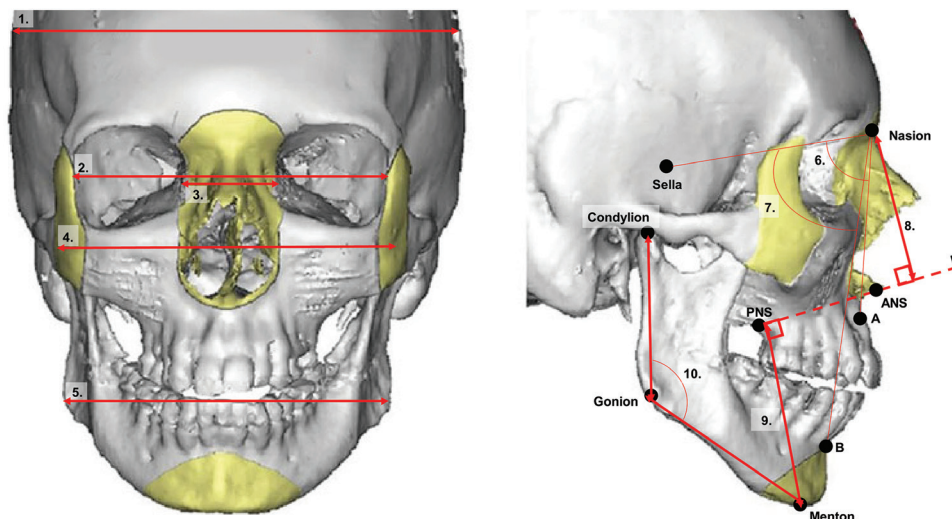


Fig. 2. Bony parameters measured as visualized in frontal (left) and lateral (right) views. ANS, anterior nasal spine; MxPl, maxillary plane; PNS, posterior nasal spine. 1. Biparietal distance; 2. Lateral intercanthal distance; 3. Medial intercanthal distance; 4. Bizygomatic distance; 5. Bigonial distance; 6. Sella-nasion-A angle; 7. Sella-nasion-B angle; 8. Upper facial height; 9. Lower facial height; 10. Mandibular angle. Reprinted with permission from and copyrights retained by Eduardo D. Rodriguez, MD, DDS.

$p < 0.05$. Graphs were generated using Microsoft Excel 16.33 (Microsoft, Redmond, WA).

RESULTS

Anthropometric and Cephalometric Analysis

Of the 14 cadavers, nine were males and five were females. A total of five CSFT (four female-to-male, one male-to-female) and two SSFT (both male-to-male) were performed (donor mean age: 67 (range: 54-80); recipient mean age: 64.8 (range: 38-76)). There was no significant difference in operative time (CSFT: mean 373 minutes; SSFT: mean 337 minutes; $p = 0.730$). Soft and hard tissue measurements are shown in [Table 1](#). When comparing pre-operative donor and recipient anthropometric and cephalometric characteristics, no significant difference was noted for most parameters, with the exception of the difference in lateral intercanthal distance (CSFT: $3.4 \pm 1.8\%$; SSFT: $12.0 \pm 6.3\%$; $p = 0.025$) and SNB angles (CSFT: $1.8 \pm 2.0\%$; SSFT: $22.8 \pm 19.8\%$; $p = 0.039$). When comparing recipients and post-transplant outcomes, the only significant differences observed were with the bigonial (CSFT: $18.1 \pm 4.4\%$; SSFT: $5.5 \pm 0.4\%$; $p = 0.012$) and medial intercanthal distances (CSFT: $12.3 \pm 4.7\%$; SSFT: $26.6 \pm 1.3\%$; $p = 0.010$). On craniofacial CT overlay and heat map analysis, there was no significant difference between CSFT and SSFT in final positioning of the allograft skeletal segments in the recipient, all of them being within 2mm of the computerized plan ([Fig. 5](#)).

Survey Study Analysis

A total of 213 participants were surveyed, including 100 drawn from the general population (46.9%), 51 medical students (23.9%), and 62 medical professionals (29.2%). One hundred and eighteen respondents identified as males (55.4%) and 95 identified as females (44.6%).

There was a significant difference in age, religion, and race between the general public versus the medical group (medical students and professionals). Demographic characteristics are detailed in [Table 2](#).

Participants were more willing to donate their face for SSFT than for CSFT (SSFT: 59.6%; CSFT: 53.0%; $p = 0.001$). This trend was similar when evaluating willingness to donate on behalf of a loved one (SSFT: 37.1%; CSFT: 31.8%; $p = 0.008$). Overall, for both CSFT and SSFT, participants were more likely to donate a facial allograft on behalf of themselves versus on behalf of a loved one (SSFT: 59.6% (self); 37.1% (loved one); $p < 0.001$; CSFT: 53.0% (self); 31.8% (loved one); $p < 0.001$). Assessment of participants' willingness to receive a FT revealed that 79.5% were willing to receive a SSFT, but only 52.3% would undergo a CSFT ($p < 0.001$). When asked whether this would be different if further research demonstrated feasibility of CSFT and equivalent outcomes to SSFT, participants' willingness significantly increased to 65.6% ($p < 0.001$) ([Fig. 6](#)). There was no significant difference in responsiveness towards acceptance of CSFT between the plastic surgery and non-plastic surgery groups ($p = 0.414$).

Non-blinded assessment of the FT aesthetic outcomes showed that 62.9% of the participants rated the CSFT superior or equal to SSFT, with a mean score of 3.2 (Likert scale 1-5) for both ($p > 0.05$). When blinded, the ratings for CSFT were significantly higher than for SSFT, with 79% of the participants rating the CSFT superior or equal to SSFT (SSFT: 3.1; CSFT: 3.7; $p < 0.001$) ([Fig. 7](#)). Participants' satisfaction with the aesthetic outcomes of CSFT were significantly higher when blinded, compared to non-blinded (3.7 vs. 3.2, $p < 0.001$).

DISCUSSION

To our knowledge, this is the first study evaluating the feasibility of CSFT combining both objective data

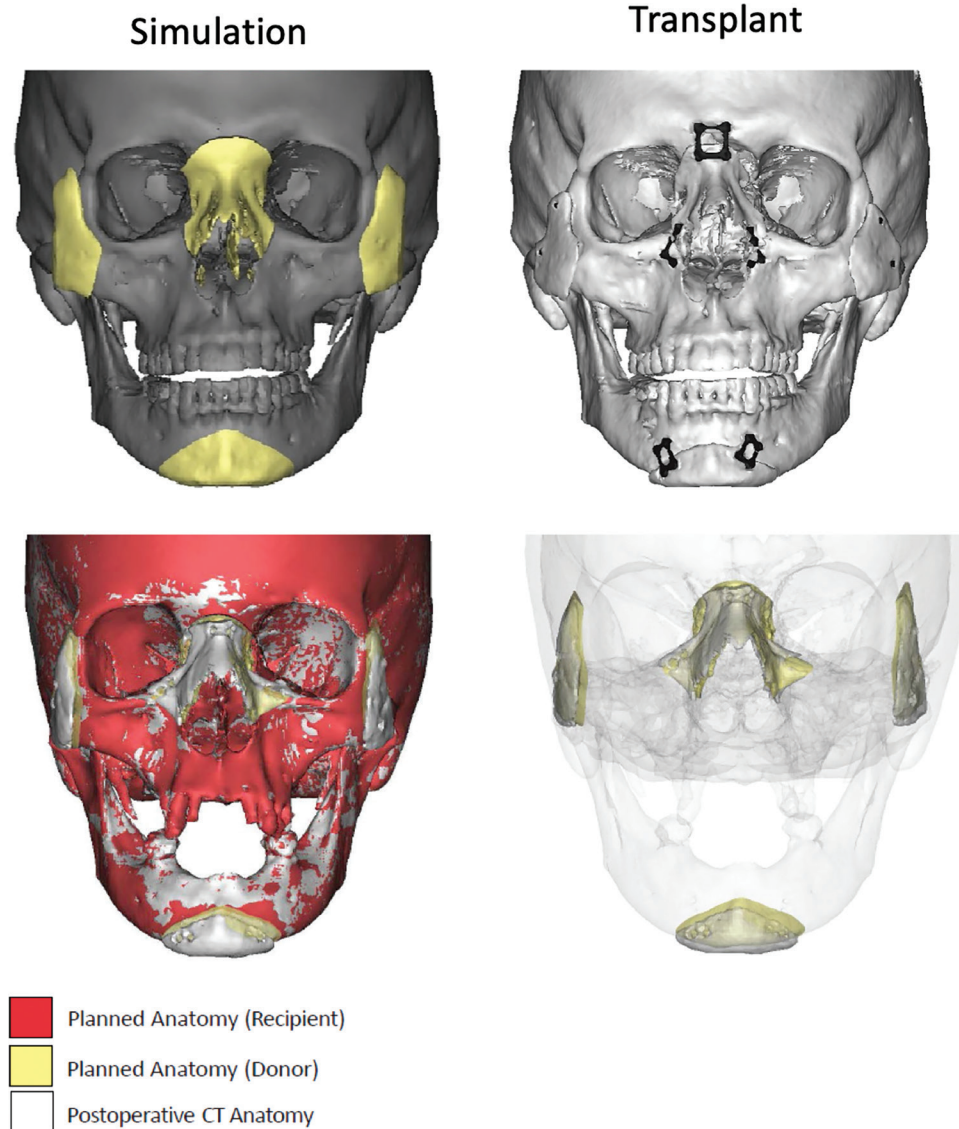


Fig. 3. A comparison of the computerized surgical plan (CSP) and actual transplant outcomes. CSP demonstrating the planned skeletal subunit fixation at the nasofrontal, bilateral zygomatic, and genial segments (A) versus the actual outcomes (B). CT overlay techniques allow outcomes comparison by superimposition of the planned and actual craniofacial anatomy (C and D). Reprinted with permission from and copyrights retained by Eduardo D. Rodriguez, MD, DDS.

with cadaveric measurements and subjective analysis by assessing the public and medical professionals' attitude towards CSFT. Our findings indicate that CSFT and SSFT offer similar anthropometric and cephalometric outcomes, thereby demonstrating its anatomic feasibility. Nonetheless, participants were more reticent to undergo CSFT, albeit with increased willingness if further research were to support it. Overall, our study suggests that CSFT may be a viable solution to the existing donor shortage.

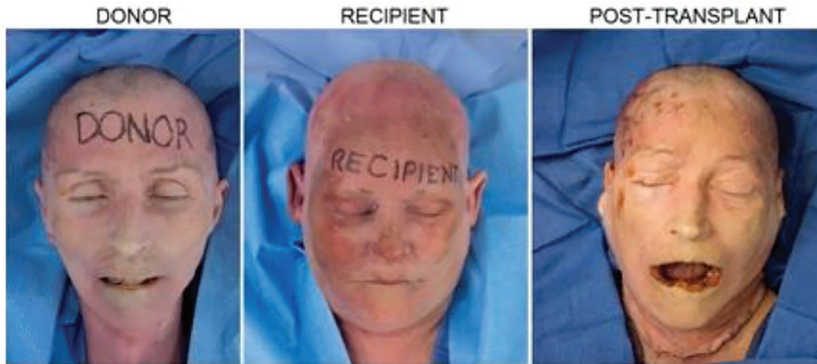Sex-specific Facial Characteristics: A Challenge for CSFT

One of the major concerns with CSFT stems from the inherent differences between the male and female facial characteristics, potentially leading to a physical mismatch. Several studies have delineated the distinct facial

features in females and males.²⁰⁻²⁶ For example, compared with females, males have a larger craniofacial skeleton overall, more square-shaped face, longer jaw with more anterior projection and delineation via sharper gonial angle, broader chin, more significant frontal bossing, wider forehead, larger nose, straighter eyebrows and less prominent cheeks. Due to sex-specific anthropometrics, concerns exist that CSFT would yield a hybrid and disproportionate craniofacial skeleton. However, using an animal and cadaveric models, Gordon et al. found on cephalometric analysis that CSP and CAD/CAM technology allowed for preservation of skeletal harmony, with proportions comparable to those previously reported with SSFT.¹⁸ This observation is in line with our cadaveric study findings.

The following photos will show the pre- and post-operative results of cadaveric face transplants. Please indicate how satisfactory you find the results, with 1 being not at all satisfactory and 5 being very satisfactory.

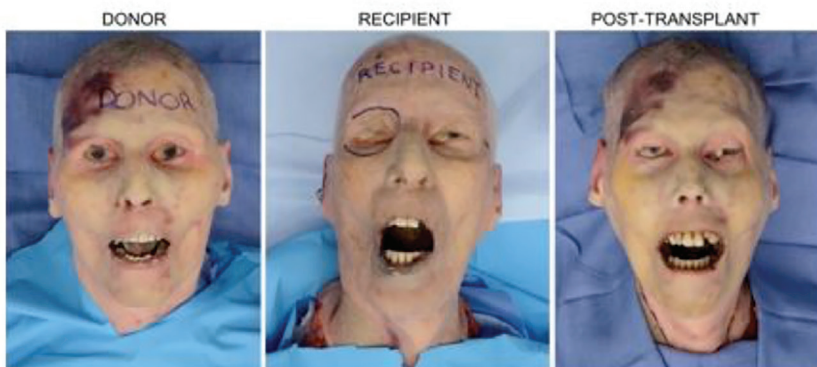Case 1.



How satisfactory do you find these results?

- 1 (Not at all satisfactory)
- 2
- 3
- 4
- 5 (Very satisfactory)

Case 2.



How satisfactory do you find these results?

- 1 (Not at all satisfactory)
- 2
- 3
- 4
- 5 (Very satisfactory)

Do you find the results for Case 2 (bottom row) better, worse, or the same than the results for Case 1 (top row)?

- Case 2 is better than Case 1
- Case 2 is worse than Case 1
- Case 2 is the same as Case 1

Fig. 4. Image showing the survey excerpt. Participants were asked to rate the outcomes of various CSFTs and SSFTs. Only the blinded portion of the assessment is shown here. Reprinted with permission from and copyrights retained by Eduardo D. Rodriguez, MD, DDS.

Soft- and Hard-tissue Discrepancies: Role of Secondary Revisions after CSFT

The cephalometric and anthropometric measurements indicate similar outcomes with CSFT and SSFT, supporting the technical feasibility and anatomic compatibility of CSFT. The only significant differences were noted with the bigonial and medial intercanthal distances on soft and hard tissue analyses respectively. Surgical precision was greater in CSFT for medial intercanthal distance but worse with regard to bigonial distance. A combination of factors likely contributed to these discrepancies.

First, the bigonial distance may have had the largest discrepancy in CSFT due to inherent differences of the facial allograft, in that bony components of the mandibular symphysis were included within the allograft, but not that of the mandibular body or angle. This resulted in disruption of the suspensory ligaments along the mandible subjecting the bigonial distance to minor soft tissue differences. Any suboptimal soft tissue dissection, soft tissue shifting of the allograft and swelling of tissues associated with the cadaver thawing process may have influenced the bigonial distance. However, it remains unclear why

Table 1. Soft- and Hard-tissue Measurements in Donor, Recipient, and Posttransplant Cadavers

	Donor-to-recipient Differences					Recipient-to-posttransplant Differences				
	Cross-sex		Same-sex			Cross-sex		Same-sex		
	Mean Distance/ Angle, mm/ degree	Mean Relative Difference, %	Mean Distance/ Angle, mm/ degree	Mean Relative Difference, %	P	Mean Distance/ Angle, mm/ degree	Mean Relative Difference, %	Mean Distance/ Angle, mm/ degree	Mean Relative Difference, %	P
Soft tissue										
Head circumference	56.6 ± 40.9	8.9 ± 5.9	26.0 ± 9.8	4.4 ± 2.0	0.368	20.3 ± 30.7	3.0 ± 4.4	28.9 ± 1.3	4.9 ± 0.6	0.599
R palpebral aperture	5.6 ± 4.0	13.5 ± 10.7	1.5 ± 1.5	3.6 ± 3.7	0.277	3.4 ± 3.3	7.5 ± 7.0	1.2 ± 1.6	3.0 ± 4.1	0.442
L palpebral aperture	5.0 ± 6.6	12.3 ± 17.5	5.1 ± 6.7	12.6 ± 16.7	0.984	5.5 ± 2.9	12.2 ± 6.5	5.2 ± 4.0	12.9 ± 9.9	0.908
Biparietal	4.7 ± 4.1	3.0 ± 2.6	4.8 ± 2.8	3.0 ± 1.8	0.981	3.1 ± 3.5	2.0 ± 2.2	3.5 ± 1.3	2.2 ± 0.9	0.874
Fronto-occipital	9.4 ± 6.2	4.7 ± 2.9	10.2 ± 5.1	5.3 ± 2.9	0.809	4.5 ± 6.5	2.4 ± 3.6	4.7 ± 0.9	2.4 ± 0.3	0.996
Bizygomatic	10.8 ± 5.8	10.2 ± 5.5	7.3 ± 5.6	5.8 ± 4.4	0.371	8.3 ± 4.7	7.9 ± 4.7	3.3 ± 2.7	2.7 ± 2.3	0.216
Bigonial	7.2 ± 7.2	6.3 ± 6.5	2.2 ± 1.9	1.7 ± 1.5	0.392	21.1 ± 5.2	18.1 ± 4.4	7.0 ± 0.7	5.5 ± 0.4	0.012*
Medial intercanthal	1.5 ± 1.0	8.1 ± 4.9	2.3 ± 0.4	11.5 ± 4.7	0.443	1.8 ± 2.6	9.9 ± 14.7	2.5 ± 3.4	14.1 ± 19.4	0.761
Lateral intercanthal	6.2 ± 4.8	2.3 ± 2.0	6.5 ± 5.3	2.1 ± 1.8	0.317	5.8 ± 4.9	5.9 ± 4.6	20.7 ± 1.7	18.7 ± 0.8	0.014
R ext. auditory meatus to lateral canthus	8.0 ± 5.0	9.7 ± 5.6	8.7 ± 0.4	11.7 ± 1.5	0.652	12.4 ± 8.8	16.3 ± 12.4	15.1 ± 15.8	19.5 ± 19.5	0.798
L ext. auditory meatus to lateral canthus	6.6 ± 10.3	7.3 ± 11.0	4.1 ± 1.5	5.0 ± 1.9	0.795	17.9 ± 7.6	23.1 ± 11.6	16.2 ± 13.4	20.0 ± 16.5	0.782
Hard tissue										
Biparietal	5.5 ± 4.0	3.8 ± 2.6	4.5 ± 5.7	17.2 ± 15.5	0.081	1.7 ± 1.0	1.2 ± 0.7	1.1 ± 0.5	0.8 ± 0.4	0.477
Fronto-occipital	9.8 ± 4.9	5.2 ± 2.4	11.3 ± 10.3	28.0 ± 24.6	0.059	0.8 ± 0.5	0.4 ± 0.3	0.3 ± 0.4	0.2 ± 0.2	0.280
Bizygomatic	5.5 ± 3.3	5.4 ± 3.0	1.5 ± 1.8	2.6 ± 0.1	0.267	7.4 ± 3.7	7.4 ± 4.0	12.7 ± 6.2	12.8 ± 7.4	0.241
Bigonial	5.1 ± 5.4	5.8 ± 6.6	4.9 ± 6.3	11.7 ± 2.7	0.303	1.7 ± 1.0	1.9 ± 1.1	1.3 ± 1.5	1.3 ± 1.6	0.617
Medial intercanthal	2.6 ± 2.2	14.1 ± 11.1	15.0 ± 17.4	216.6 ± 284.6	0.117	2.3 ± 0.7	12.3 ± 4.7	4.8 ± 0.1	26.6 ± 1.3	0.010*
Lateral intercanthal	3.0 ± 1.5	3.4 ± 1.8	3.7 ± 4.1	12.0 ± 6.3	0.025*	2.0 ± 1.1	2.2 ± 1.2	1.3 ± 1.3	1.4 ± 1.4	0.472
Upper facial height	3.5 ± 2.0	7.1 ± 4.1	7.2 ± 3.1	56.7 ± 53.9	0.059	0.4 ± 0.4	0.8 ± 0.7	1.6 ± 1.7	3.2 ± 3.3	0.136
Lower facial height	4.5 ± 2.5	6.5 ± 3.8	5.2 ± 3.9	27.7 ± 23.4	0.068	2.5 ± 1.8	3.5 ± 2.6	2.0 ± 1.0	2.8 ± 1.4	0.709
SNA, degree	2.6 ± 2.1	3.1 ± 2.4	1.5 ± 2.2	13.2 ± 13.7	0.122	2.9 ± 1.4	3.6 ± 1.8	1.0 ± 0.9	1.2 ± 1.2	0.152
SNB, degree	1.4 ± 1.6	1.8 ± 2.0	3.7 ± 4.8	22.8 ± 19.8	0.039*	2.1 ± 1.6	2.8 ± 2.2	1.2 ± 1.6	1.5 ± 2.0	0.491
Mandibular angle, degree	6.9 ± 4.9	27.1 ± 23.8	11.3 ± 0.0	99.1 ± 80.9	0.096	3.4 ± 3.7	14.5 ± 19.3	3.5 ± 3.7	17.6 ± 20.6	0.854

*Statistical significance.

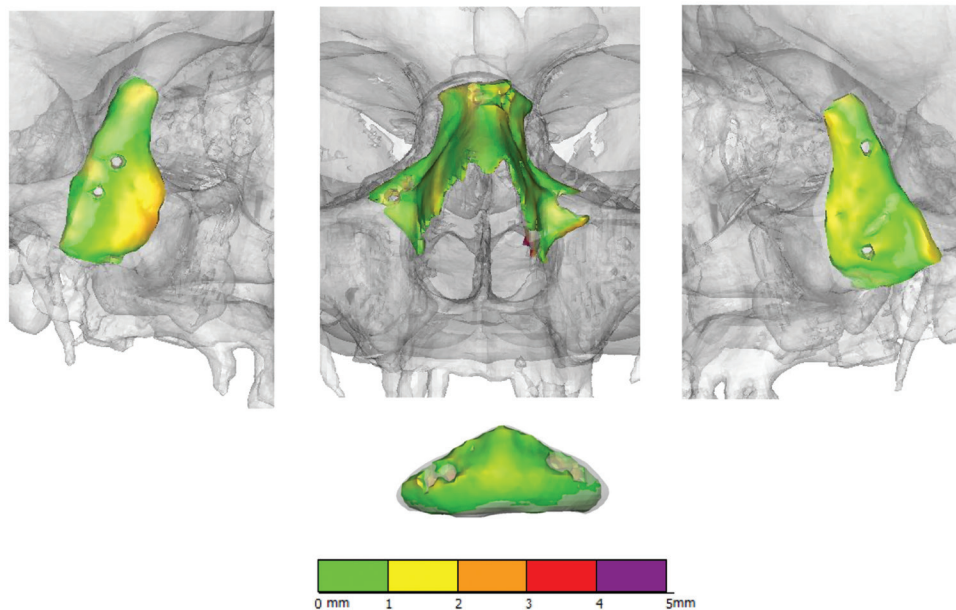


Fig. 5. A comparison of the computerized surgical plan with the actual positions of allograft skeletal segments after CSFT and SSFT. The predominance of green and yellow colors on craniofacial CT overlay and heat map analysis demonstrate high fidelity with the virtual plan, with discrepancies not exceeding 2 mm (*bottom panel*). Frontal view (B); ¾ views (A and C). Reprinted with permission from and copyrights retained by Eduardo D. Rodriguez, MD, DDS.

Table 2. Demographic Distribution of Study Participants

Demographic Characteristic	N (%)
Participants	
General population	100 (46.9%)
Medical students	51 (23.9%)
Medical professionals	62 (29.2%)
Age, y	
18–30	70 (32.9%)
31–40	44 (20.7%)
41–50	25 (11.7%)
51–60	27 (12.7%)
61–70	36 (16.9%)
71–80	7 (3.3%)
81–90	4 (1.9%)
Sex	
Male	118 (55.4%)
Female	95 (44.6%)
Religion	
Catholic	65 (30.5%)
Protestant	32 (15.0%)
Jewish	23 (10.8%)
Muslim	6 (2.8%)
Buddhist	5 (2.3%)
Hindu	11 (5.2%)
Other	20 (9.4%)
Agnostic	19 (8.9%)
Atheist	23 (10.8%)
Prefers not to answer	9 (4.2%)
Race/Ethnicity	
White	103 (48.4%)
Hispanic	33 (15.5%)
Asian	34 (16.0%)
African American	32 (15.0%)
Other	9 (4.2%)
Prefers not to answer	2 (0.9%)
Registered Organ Donor (general population and medical students)	
Yes	65 (43%)
No	86 (57%)
Occupation (medical professionals)	
Attending: plastic surgery	20 (32.3%)
Attending: nonplastic surgery	17 (27.4%)
Resident: plastic surgery	11 (17.7%)
Nonphysician medical professional	7 (11.3%)
Did not answer	7 (11.3%)
Years of experience with craniofacial injuries (medical professionals)	
<1	7 (11.5%)
1–5	29 (47.5%)
6–10	10 (16.4%)
11–20	7 (11.5%)
>20	8 (13.1%)

this difference was pronounced in the CSFT. The medial intercanthal distance precision in CSFT may be due to the result of including the medial canthal tendons intact in continuity with the osseous portion of the allograft. Again, it appears to be unclear why CSFT would have a more precise result than SSFT. Although our study reveals discrepancies, they remain minor in the context of the global precision of the bony and soft tissue elements of FT. In the clinical setting, CSFT recipients may undergo secondary revision procedures to address aesthetic and functional concerns such as blepharoptosis and malocclusion, and the aforementioned theoretical discrepancies can subsequently be addressed. Though revising a facial allograft poses a unique set of challenges, including potential vascular compromise, poor wound healing in the setting of immunosuppression and the potential to trigger an episode of acute rejection,^{27,28} this would not be any different from the widely documented and commonplace management of secondary revisions already

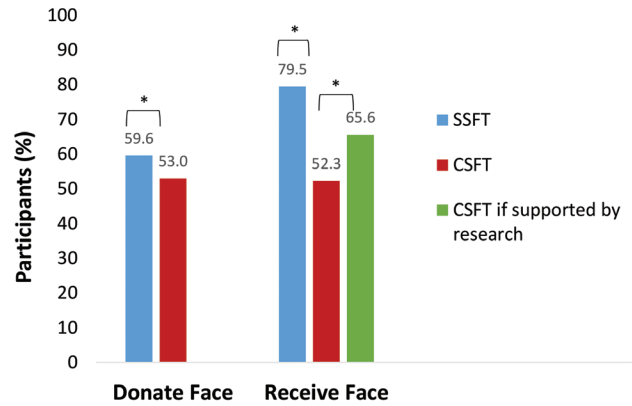


Fig. 6. Participants’ willingness to donate and receive facial allografts. Participants expressed significantly increased willingness to receive a CSFT if further research supports it. Asterisk (*) denotes statistical significance. Reprinted with permission from and copyrights retained by Eduardo D. Rodriguez, MD, DDS.

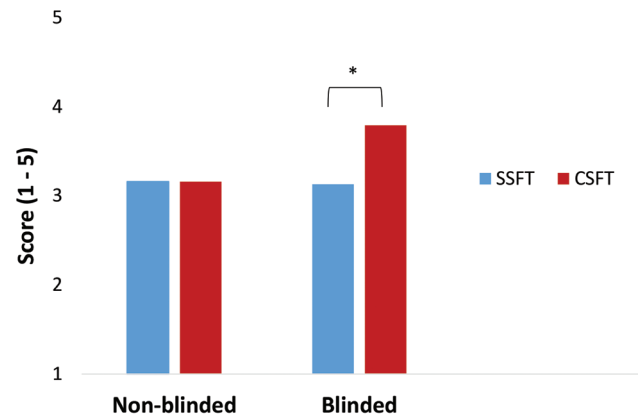


Fig. 7. Participants’ ratings of cadaveric face transplants on a 5-point Likert scale. Asterisk (*) denotes statistical significance. Reprinted with permission from and copyrights retained by Eduardo D. Rodriguez, MD, DDS.

performed on FT recipients.^{29–33} Ultimately, discrepancies of bigonial distance would be addressed with autologous fat grafting or conversely with suction lipectomy for reduction, which have been described in the literature. Although possible, alloplastic implantation for gonial augmentation or serial injection of chemodenevating agent may be less optimal and pose an unnecessarily high risk to the facial allograft.^{30–32,34} Similarly, the medial intercanthal distance can be adjusted post-transplant with medial canthoplasties, and the need for ocular revisions has been well described.⁸

Female-to-male versus Male-to-female Transplants: Are They Equivalent?

Although CSFT has never been attempted in the clinical setting, five sex-mismatched VCAs have been reported, all being female donors to male recipients.^{12–17} Due to the paucity of data in the VCA literature, knowledge on cross-sex transplantation (CST) outcomes is currently best derived from the SOT literature. Several small series and

single-center studies have demonstrated inferior short- and long-term graft outcomes with female donors to male recipient kidney transplants.^{35–39} A large study including over 100,000 kidney transplants corroborated this finding, with worse graft outcomes and patient survival for male recipients of female donors, compared with female recipients of male donors or male recipients of male donors.⁴⁰ Although the precise mechanism accounting for this difference is unknown and likely multifactorial, multiple explanations have been proposed. Nephron underdosing is often cited as a major contributor, with the female kidney being smaller in size with less nephrons than the male kidney, creating a functional mismatch of transplantation.^{41,42} Similar outcome differences were observed with heart and liver allografts, which has led to other explanatory hypotheses.^{43–47} Differences in immunologic response to transplants between males and females could be explained by the higher antigenicity observed in female kidneys secondary to higher antigen expression, ultimately leading to higher rates of rejection episodes in female donor to male recipient transplants.^{37,40} Additionally, these immunologic differences could be due to the distinct effect of sex hormones on the vascular endothelium, with greater mononuclear cell adhesion in an androgen-rich environment, though the model used did not incorporate immunosuppression to study these effects.^{48,49} It should be noted that contradictory results have also been documented, with studies reporting worse outcomes and greater risk of early graft loss in female recipients of male kidneys, emphasizing the lack of consensus regarding sex-mismatched SOT.^{50–53} Ultimately, further immunologic studies and subsequent outcome reporting may be needed to corroborate any differences in female to male versus male to female cross-sex VCA. Particular to FT, female-to-male VCA may be a more viable option considering patients are more likely to be male, female allografts may conform to size mismatch, and hormonal influence of circulating testosterone levels may allow for a more natural transition to the phenotype of the recipient.^{54,55}

Enhancing CSFT Outcomes: Masculinization and Feminization Procedures

Minor discrepancies between the donor and recipient skin texture and facial hair distribution can be addressed with make-up, laser hair removal, or hair transplantation. However, the effect of circulating sex hormones in the recipient should be accounted for, as it may affect skin properties and hair growth, as demonstrated in the transgender population undergoing hormonal treatment.^{54–56} In fact, in the VCA literature, a transplanted lower extremity from a female donor reportedly grew hair similar to that of the male recipient in the presence of circulating testosterone.^{12,18} Because of the potential for virilization of the female facial allograft in a testosterone-rich environment and preservation of the underlying male craniofacial skeleton, performing a female donor to male recipient CSFT may be preferable, with appropriate retention of masculinity.

While other nonsurgical facial masculinization and feminization techniques have been described, fundamental

concepts of gender-affirming surgery could be integrated into the allograft construct or applied as part of revision procedures.^{30,57–60} For example, osteotomies can be tailored during allograft design to implement glabellar or gonial reduction. The role of canthoplasty in FT has been previously discussed in detail, with temporary blink impairment noted with periorbital and eyelid revisions.⁶¹ However, a formal facial feminization or masculinization surgery during transplantation may lead to sub-optimal aesthetic precision given the extensive facial edema present at the time of transplantation, the unpredictable soft tissue suspension and lie over the first 3–6 months of recovery, and importantly the need to minimize ischemia time during the transplantation. Performing a septo-rhinoplasty before allograft harvest would increase operative time and bleeding, and any delicate cartilaginous work may be disrupted during allograft harvest, transfer, and inset. If deemed necessary, this procedure should be performed in a delayed fashion given the extent of mucosal, cartilaginous and bony work required. While it is possible to implement gender-affirming surgical principles at the time of transplantation, delivering precise outcomes may be more effective in a delayed fashion. Ultimately, the timing of execution of these procedures should be at the surgeon's discretion.

CSFT versus SSFT: Public Opinion

The importance of social acceptance is critical, and we sought to evaluate the public's perception on FT. Participants were more willing to donate and receive a facial allograft for SSFT than CSFT, reflecting the skepticism around CSFT. Despite media coverage, a significant portion of the general population remains unaware of its existence, with persistent misconceptions surrounding FT.^{62–64} Concerns regarding facial appearance, hormonal effects on the allograft and preservation of one's masculinity or femininity may contribute to the reluctance towards CSFT, as compared to SSFT. Participants were also asked to rate their satisfaction with the outcomes of SSFT and CSFT and to compare one versus the other. Both blinded and non-blinded assessments showed that CSFT were perceived at least equal to or superior to SSFT for a majority of the participants. In fact, when the participants were blinded, scores were significantly higher for CSFT, and were equal to those of SSFT when non-blinded. This indicates that CSFT can lead to satisfactory outcomes comparable to, and potentially even superior to those with SSFT, though continued efforts should address the implicit bias discovered in this blinding protocol.

Educational interventions may address some of these challenges. An educational video has previously been shown to affect willingness to donate for FT, with an 18% increase among participants in one study.⁶² Likewise in this study, participants expressed a significant increase in willingness to donate for CSFT if further research could also demonstrate similar outcomes to SSFT. With significant efforts being made to increase VCA donation and expand the donor pool, this again highlights the importance of public education and awareness, as well as the need to pursue CSFT research endeavors to support further

evidence-based discussion. Although public interpretation of CSFT is encouraging, extrapolating aesthetic outcomes from cadaveric simulation should be interpreted as only preliminary data and interpreted with a high level of scrutiny.

Limitations

Using a cadaveric model does not account for the dynamic nature of a facial allograft and the variations in post-transplant period. Additionally, this is a small cadaveric study with seven FTs performed at a single institution. Survey participants were drawn from an urban population in New York City, which limits generalization, as the state of New York consistently has one of the lowest organ donor registration rates.^{65,66} Finally, there was a significant difference in age, religion, and race between the medical and non-medical groups. This reflects the population of medical providers and students at our institution, which may differ from that of the general public. Nonetheless, this study lays the foundation for potential success in expanding the donor pool through CSFT.

CONCLUSIONS

Cross-sex face transplantation when compared with SSFT shows comparable anthropometric and cephalometric outcomes, along with equal or superior publicly interpreted subjective outcomes. Cross-sex face transplantation may represent a viable option for expansion of the donor pool. Future investigations should evaluate the immunological outcomes of CSFT with animal studies involving both sexes. Additionally, the psychological impact of CSFT and allograft adaptation to a new hormonal milieu should be assessed. Continuing research efforts, community outreach and education will be necessary to further validate its feasibility, clarify misconceptions, and increase public acceptance.

Eduardo D. Rodriguez, MD, DDS

Hansjörg Wyss Department of Plastic Surgery
Helen L. Kimmel Professor of Reconstructive Plastic Surgery
NYU Langone Health
222 E 41st Street, 6th Floor
New York, NY 10017
E-mail: eduardo.rodriguez@nyulangone.org

ACKNOWLEDGMENT

Statement of Conformity: This article was conducted in accordance with the Declaration of Helsinki.

REFERENCES

- Maciejewski A, Krakowczyk L, Szymczyk C, et al. The first immediate face transplant in the world. *Ann Surg*. 2016;263:e36–e39.
- Barret JP, Gavalda J, Bueno J, et al. Full face transplant: the first case report. *Ann Surg*. 2011;254:252–256.
- Guo S, Han Y, Zhang X, et al. Human facial allotransplantation: a 2-year follow-up study. *Lancet*. 2008;372:631–638.
- CNN. Man's second face transplant is a world first. 2018. Available at <https://www.cnn.com/2018/04/17/health/second-face-transplant-bn/index.html>. Accessed March 1, 2020.
- TIME. He's the First African American to Receive a Face Transplant. His Story Could Change Health Care. 2019. Available at <https://time.com/5709294/first-african-american-face-transplant/>. Accessed March 1, 2020.
- Wainright JL, Wholley CL, Cherikh WS, et al. OPTN vascularized composite allograft waiting list: current status and trends in the United States. *Transplantation*. 2018;102:1885–1890.
- Rifkin WJ, David JA, Plana NM, et al. Achievements and challenges in facial transplantation. *Ann Surg*. 2018;268:260–270.
- Kantar RS, Plana NM, Diaz-Siso JR, et al. Reply: simulation-based cleft surgery education: from theory to real-time application. *Plast Reconstr Surg*. 2019;144:717e–718e.
- Lindford AJ, Mäkisalo H, Jalanko H, et al. The Helsinki approach to face transplantation. *J Plast Reconstr Aesthet Surg*. 2019;72:173–180.
- Post TW. His face was severely damaged on a hunt. Now he's the world's oldest face transplant recipient. 2018. Available at <https://www.washingtonpost.com/news/to-your-health/wp/2018/09/14/his-face-was-severely-damaged-on-a-hunt-now-hes-the-worlds-oldest-face-transplant-recipient/>. Accessed March 1, 2020.
- Sera CD. Transplanted face rejected: "Now we need a new donor". 2018. Available at https://www.corriere.it/english/18-settembre_25/transplanted-face-rejected-now-we-need-new-donor-0916a0ea-c0d2-11e8-8c2f-234b69fe8a3d.shtml. Accessed March 1, 2020.
- Cavadas PC, Thione A, Carballeira A, et al. Bilateral transfemoral lower extremity transplantation: result at 1 year. *Am J Transplant*. 2013;13:1343–1349.
- Jablecki J, Kaczmarzyk L, Domanasiewicz A, et al. Unilateral hand transplant—results after 41 months. *Transplant Proc*. 2013;45:440–443.
- Jablecki J, Kaczmarzyk L, Domanasiewicz A, et al. Hand transplant—outcome after 6 months, preliminary report. *Ortop Traumatol Rehabil*. 2010;12:90–99.
- Jablecki J. World experience after more than a decade of clinical hand transplantation: update on the Polish program. *Hand Clin*. 2011;27:433–442, viii.
- Jablecki J, Kaczmarzyk L, Domanasiewicz A, et al. Unsuccessful attempt of forearm transplantation—case report. *Ann Transplant*. 2010;15:53–56.
- Jablecki J, Syrko M, Arendarska-Maj A. Patient rehabilitation following hand transplantation at forearm distal third level. *Ortop Traumatol Rehabil*. 2010;12:570–580.
- Gordon CR, Swanson EW, Susarla SM, et al. Overcoming cross-gender differences and challenges in Le Fort-based, cranio-maxillofacial transplantation with enhanced computer-assisted technology. *Ann Plast Surg*. 2013;71:421–428.
- Sosin M, Ceradini DJ, Hazen A, et al. Total face, eyelids, ears, scalp, and skeletal subunit transplant cadaver simulation: the culmination of aesthetic, craniofacial, and microsurgery principles. *Plast Reconstr Surg*. 2016;137:1569–1581.
- Bruce V, Burton AM, Hanna E, et al. Sex discrimination: how do we tell the difference between male and female faces? *Perception*. 1993;22:131–152.
- Farkas L. *Anthropometry of the Head and Face*. New York, N.Y.: Raven Press; 1994.
- Ousterhout DK. Feminization of the forehead: contour changing to improve female aesthetics. *Plast Reconstr Surg*. 1987;79:701–713.
- Ousterhout DK. Feminization of the Chin: a review of 485 consecutive cases. In: 10th International Congress, International Society of Craniofacial Surgery; 2003; Monterey, Calif.
- Brown E, Perrett DI. What gives a face its gender? *Perception*. 1993;22:829–840.
- Spiegel JH. Facial determinants of female gender and feminizing forehead cranioplasty. *Laryngoscope*. 2011;121:250–261.
- Roberts T, Bruce V. Feature saliency in judging the sex and familiarity of faces. *Perception*. 1988;17:475–481.

27. Humar A, Ramcharan T, Denny R, et al. Are wound complications after a kidney transplant more common with modern immunosuppression? *Transplantation*. 2001;72:1920–1923.
28. Ka SI, Kim SE. Postoperative complications of plastic and reconstructive surgery in solid organ transplant recipients. *J Craniofac Surg*. 2019;30:1012–1015.
29. Ramly EP, Kantar RS, Diaz-Siso JR, et al. Outcomes after tooth-bearing maxillo-mandibular facial transplantation: insights and lessons learned. *J Oral Maxillofac Surg*. 2019;77:2085–2103.
30. Mohan R, Fisher M, Dorafshar A, et al. Principles of face transplant revision: beyond primary repair. *Plast Reconstr Surg*. 2014;134:1295–1304.
31. Aycart MA, Pomahac B. Discussion: vascular perfusion of the facial skin: implications in allotransplantation of facial aesthetic subunits. *Plast Reconstr Surg*. 2016;138:1080–1081.
32. Lantieri L, Grimbert P, Ortonne N, et al. Face transplant: long-term follow-up and results of a prospective open study. *Lancet*. 2016;388:1398–1407.
33. Frautschi R, Rampazzo A, Bernard S, et al. Management of the salivary glands and facial nerve in face transplantation. *Plast Reconstr Surg*. 2016;137:1887–1897.
34. Sosin M, Ceradini DJ, Levine JP, et al. Total face, eyelids, ears, scalp, and skeletal subunit transplant: a reconstructive solution for the full face and total scalp burn. *Plast Reconstr Surg*. 2016;138:205–219.
35. Neugarten J, Srinivas T, Tellis V, et al. The effect of donor gender on renal allograft survival. *J Am Soc Nephrol*. 1996;7:318–324.
36. Vereerstraeten P, Wissing M, De Pauw L, et al. Male recipients of kidneys from female donors are at increased risk of graft loss from both rejection and technical failure. *Clin Transplant*. 1999;13:181–186.
37. Shibue T, Kondo K, Iwaki Y, et al. Effect of sex on kidney transplants. *Clin Transpl*. 1987:351–360.
38. Koka P, Cecka JM. Sex and age effects in renal transplantation. *Clin Transpl*. 1990:437–446.
39. Sanfey H. Gender-specific issues in liver and kidney failure and transplantation: a review. *J Womens Health (Larchmt)*. 2005;14:617–626.
40. Zeier M, Döhler B, Opelz G, et al. The effect of donor gender on graft survival. *J Am Soc Nephrol*. 2002;13:2570–2576.
41. Brenner BM, Milford EL. Nephron underdosing: a programmed cause of chronic renal allograft failure. *Am J Kidney Dis*. 1993;21(5 suppl 2):66–72.
42. Mackenzie HS, Azuma H, Rennke HG, et al. Renal mass as a determinant of late allograft outcome: insights from experimental studies in rats. *Kidney Int Suppl*. 1995;52:S38–S42.
43. Prendergast TW, Furukawa S, Beyer AJ III, et al. The role of gender in heart transplantation. *Ann Thorac Surg*. 1998;65:88–94.
44. Mehra MR, Stapleton DD, Ventura HO, et al. Influence of donor and recipient gender on cardiac allograft vasculopathy. An intravascular ultrasound study. *Circulation*. 1994;90(5 pt 2):II78–II82.
45. Kahn D, Gavalier JS, Makowka L, et al. Gender of donor influences outcome after orthotopic liver transplantation in adults. *Dig Dis Sci*. 1993;38:1485–1488.
46. Marino IR, Doyle HR, Aldrighetti L, et al. Effect of donor age and sex on the outcome of liver transplantation. *Hepatology*. 1995;22:1754–1762.
47. Brooks BK, Levy MF, Jennings LW, et al. Influence of donor and recipient gender on the outcome of liver transplantation. *Transplantation*. 1996;62:1784–1787.
48. McCrohon JA, Jessup W, Handelsman DJ, et al. Androgen exposure increases human monocyte adhesion to vascular endothelium and endothelial cell expression of vascular cell adhesion molecule-1. *Circulation*. 1999;99:2317–2322.
49. Somjen D, Kohen F, Jaffe A, et al. Effects of gonadal steroids and their antagonists on DNA synthesis in human vascular cells. *Hypertension*. 1998;32:39–45.
50. Zukowski M, Kotfis K, Biernawska J, et al. Donor-recipient gender mismatch affects early graft loss after kidney transplantation. *Transplant Proc*. 2011;43:2914–2916.
51. Valdes F, Pita S, Alonso A, et al. The effect of donor gender on renal allograft survival and influence of donor age on post-transplant graft outcome and patient survival. *Transplant Proc*. 1997;29:3371–3372.
52. Gratwohl A, Döhler B, Stern M, et al. H-Y as a minor histocompatibility antigen in kidney transplantation: a retrospective cohort study. *Lancet*. 2008;372:49–53.
53. Kim SJ, Gill JS. H-Y incompatibility predicts short-term outcomes for kidney transplant recipients. *J Am Soc Nephrol*. 2009;20:2025–2033.
54. Gao Y, Maurer T, Mirmirani P. Understanding and addressing hair disorders in transgender individuals. *Am J Clin Dermatol*. 2018;19:517–527.
55. Wierckx K, Van de Peer F, Verhaeghe E, et al. Short- and long-term clinical skin effects of testosterone treatment in trans men. *J Sex Med*. 2014;11:222–229.
56. Motosko CC, Zakhem GA, Pomeranz MK, et al. Acne: a side-effect of masculinizing hormonal therapy in transgender patients. *Br J Dermatol*. 2019;180:26–30.
57. Altman K. Facial feminization surgery: current state of the art. *Int J Oral Maxillofac Surg*. 2012;41:885–894.
58. Deschamps-Braly JC. Approach to feminization surgery and facial masculinization surgery: aesthetic goals and principles of management. *J Craniofac Surg*. 2019;30:1352–1358.
59. Ascha M, Massie JP, Ginsberg B, et al. Clarification regarding nonsurgical management of facial masculinization and feminization. *Aesthet Surg J*. 2019;39:NP95–NP96.
60. Sayegh F, Ludwig DC, Ascha M, et al. Facial masculinization surgery and its role in the treatment of gender dysphoria. *J Craniofac Surg*. 2019;30:1339–1346.
61. Sosin M, Schultz BD, De La Cruz C, et al. Microsurgical scalp reconstruction in the elderly: a systematic review and pooled analysis of the current data. *Plast Reconstr Surg*. 2015;135:856–866.
62. Plana NM, Kimberly LL, Parent B, et al. The public face of transplantation: the potential of education to expand the face donor pool. *Plast Reconstr Surg*. 2018;141:176–185.
63. Rodrigue JR, Tomich D, Fleishman A, et al. Vascularized composite allograft donation and transplantation: a survey of public attitudes in the United States. *Am J Transplant*. 2017;17:2687–2695.
64. Gwanmesia I, Clarke A, Butler PE. Facial transplantation revisited: findings from the very first public engagement exercise. *Int J Surg*. 2011;9:433–436.
65. LiveOnNY. Organ, eye, and tissue donation & transplantation. 2018. Available at https://www.liveonny.org/documents/3/LiveOnNY_Fact_Sheet_March_2018.pdf. Accessed March 1, 2020.
66. America DL. Annual Update. 2019. Available at https://www.donatelife.net/wp-content/uploads/2016/06/2019_AnnualUpdate.pdf. Accessed March 1, 2020.