

CASE REPORT

Radioactive seed localization of renal cell carcinoma in a patient with Von Hippel-Lindau disease

Christina Marie Schiøttz Hassing¹, Tove Filtenborg Tvedskov¹, Niels Kroman¹, Thomas Levin Klausen², Sissal Djurhuus³ & Linnea Langhans¹

¹Department of Plastic Surgery, Breast surgery and Burns, Rigshospitalet, University of Copenhagen, Denmark

²Department of Clinical Physiology, Nuclear Medicine and PET, Rigshospitalet, University of Copenhagen, Denmark

³Department of Urology, Rigshospitalet, University of Copenhagen, Denmark

Correspondence

Christina Marie Schiøttz Hassing, Department of Plastic Surgery, Breast surgery and Burns, Rigshospitalet, University of Copenhagen, Blegdamsvej 9, DK-2100 Copenhagen Ø, Denmark.

Tel: +45 3545 0516;

Fax: 004535452102;

E-mail: christina.marie.schioettz.

hassing@regionh.dk

Funding Information

Kræftens Bekæmpelse, (Grant/Award

Number: 'R100-A6761').

Received: 12 May 2016; Revised: 29 June

2016; Accepted: 12 August 2016

Clinical Case Reports 2017; 5(1): 26–28

doi: 10.1002/ccr3.685

Introduction

Radioactive seed localization (RSL) is a new method of preoperative localization involving a small titanium seed containing radioactive iodine (I-125). RSL is increasingly applied for localizing nonpalpable lesions in breast cancer treatment [1], but we believe that RSL has the potential to be used in various surgical specialties. Few studies have described the use of RSL outside breast surgery such as localization of axillary lymph nodes [2, 3] and parenchymal lung lesions [4]. The comprehensive use of imaging modalities has led to an increased number of detected suspicious nonpalpable lesions. Identifying these lesions during surgery and differentiating them from normal tissue is often difficult, and preoperative localization can therefore be necessary.

The radioactive iodine seed is preoperatively placed in the center of the suspicious lesion guided by ultrasound. During surgery, the nonpalpable lesion is located with a handheld

Key Clinical Message

This report describes the case of a patient, who had successful radioactive seed localization (RSL) performed to improve the identification and excision of a renal cell carcinoma. RSL is a new method of preoperative localization, which can ease the surgical procedure, minimize tissue trauma, and ultimately benefit the patient.

Keywords

Preoperative marking, radioactive seed localization, renal cell carcinoma, von Hippel-Lindau disease.

gamma-probe. The incision is made just above the lesion according to the auditory signal, and the probe allows for a constant reorientation during the procedure. Correct removal of the iodine seed is confirmed by measuring activity in the specimen and no remaining activity in the resection bed. In contrast to wire-guided localization (WGL), where the wire needs to be placed on the day of surgery, the iodine seed can be placed several days before surgery, which eases the logistic part of the procedure. Additionally, low rates of complications have been reported [1].

Von Hippel-Lindau (VHL) disease is a genetic neoplasia syndrome resulting from a mutation in the VHL gene. The mutation increases the risk of developing malignant tumors, benign tumors, and cysts in various organs. Examples of clinical manifestations are hemangioblastomas in the central nervous system and retina, renal cysts and carcinomas, pheochromocytomas and pancreatic cysts [5].

To our knowledge, this case report describes the first experience of RSL in a patient with VHL disease. In VHL

patients resection is performed with the objective to spare as much renal parenchyma as possible and prevent metastasis of the lesions already present [6].

Case Report

A 34-year-old male was diagnosed with VHL disease in 2008. The patient was found to suffer from polycystic kidneys, a retinal, and cerebellar hemangioblastoma.

In April 2009, he was diagnosed with clear cell-lined renal cell carcinoma and two tumors in the left kidney were surgically removed. Following the partial resection of his left kidney, the patient had annual magnetic resonance imaging (MRI) follow-up. In June 2013, two suspicious lesions were detected in the right kidney and their size had increased on the following MRI 9 months later. The lesions were surgically removed in April 2014. Postoperatively, the patient's estimated glomerular filtration rate (eGFR) decreased from 46 to 36 mL/min.

In November 2014, MRI (Fig. 1) showed progression of a tumor in the right kidney. It was unclear whether it was a new tumor or recurrence of the primary tumor. The tumor was located in the central part of the kidney, which was infiltrated by multiple cysts and considered very difficult to localize and remove without guidance. An ultrasound examination performed January 2015 confirmed the complicated structure (Fig. 2). Due to reduced renal function, it was essential to preserve as much functional kidney tissue as possible. Accordingly, ultrasound-

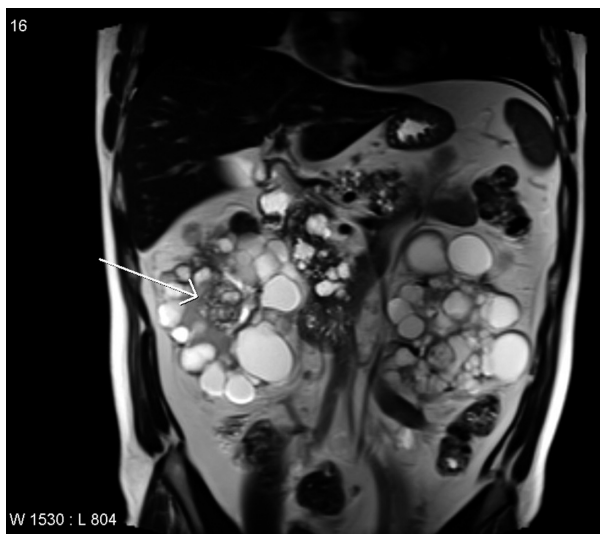


Figure 1. A coronal T2-weighted MRI from November 2014 illustrating multiple cysts in the pancreas and in both kidneys. The arrow marks the tumor in the central part of the right kidney.

guided RSL was performed. Patient consent was given before the procedure.

In our institution, we use iodine seeds with an average activity of 1–3 MBq. Administration and use of the seeds was performed as described previously [7]. During surgery, the tumor was located with the gamma-probe and ultrasound guidance. Tumor resection was performed, and the surgical specimen was sent for pathological examination, where the iodine seed was identified and removed. No complications occurred postoperatively and two weeks following surgery the patient's renal function had stabilized with an eGFR of 41 mL/min.

The pathological examination revealed regular kidney tissue, cysts, and clear cell tumor tissue. Three tumors were identified within the specimen with diameters of 11, 13, and 16 mm. The tumor tissue was not seen in the cutting plane, but it was difficult to estimate the margin status.

Discussion

This case report is the first to our knowledge that describes the use of RSL in a VHL patient with renal cell carcinoma. RSL made tumor resection possible, despite the numerous cysts surrounding the tumor and resulted in preservation of as much functional kidney tissue as possible, which may have postponed the patient's dialysis treatment.

Partial nephrectomy was chosen in this case due to the complicated localization of the tumor on ultrasound and to preserve as much kidney function as possible. In the surgical treatment of renal cell carcinoma, minimally invasive techniques have been developed within the last

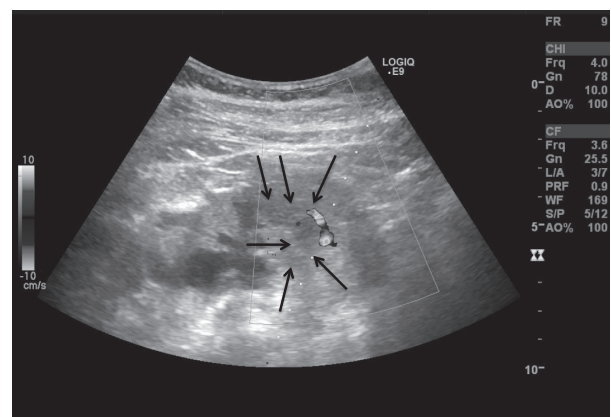


Figure 2. A longitudinal section of the right kidney illustrating the multiple cysts, echogenic adipose tissue, and the surrounding renal cortex. The arrows mark the central serrated tumor.

10 years. These include radiofrequency ablation (RFA) and cryoablation. RFA uses alternating current to cause cell death, and cryoablation causes intracellular ice formation thereby causing cell death [8]. The techniques can be performed either laparoscopically or by percutaneous image guidance [6]. A study comparing RFA with partial nephrectomy concluded that RFA has an advantage in the treatment of patients with an age above 60 years or more than three comorbidities. Partial nephrectomy is preferred in patients with centrally localized tumors larger than 5 cm or tumors adjacent to the ureter [9].

The iodine seed used had an activity between 1 and 3 MBq, which leads to an absorbed maximum dose of 100 mGy to the surrounding tissue, believed to be acceptable for the patient. As the iodine seeds are regarded as sealed radioactive sources, all seeds must be traceable throughout the entire procedure, which requires extensive interdisciplinary collaboration.

The experience regarding the use of RSL in other specialties than breast surgery is sparse. Two studies localizing axillary lymph nodes with iodine seeds for axillary staging in breast cancer patients have been published. It was demonstrated that RSL is a feasible technique and has a high identification rate of localizing lymph nodes [2, 3]. Another study has tested the use of RSL of nonvisible or nonpalpable lung lesions prior to video assisted thoracic surgery with wedge resection. This study concluded that RSL of parenchymal lung lesions is a feasible technique with complication rates comparable to standard wire-guided localization [4]. In January 2016, we initiated a feasibility study where RSL is tested in patients with suspect nonpalpable lymph nodes in Plastic, Breast and Head and Neck Surgery.

We believe RSL can improve the localization of suspicious lesions in various surgical specialties, which due to increasing use of new imaging modalities are detected earlier, making identification at surgery difficult. RSL may become an alternative method of localization in a wide range of surgical specialties and has the potential to improve treatment by easing the surgical approach. This may lead to reduced operating time, minimize trauma to the surrounding tissue, and ultimately benefit the patient.

In conclusion, this case report presents a successful placement of an iodine seed improving the identification and excision of a renal cell carcinoma in a complicated case. Future prospective studies regarding the use of RSL within urology are necessary to investigate the potential of the method.

Acknowledgments

The authors thank Flemming Jensen, Department of Radiology, Copenhagen University Hospital for performing the ultrasound examination, placement of the iodine seed, and subsequently describing the examination.

Conflict of Interest

The authors declare that there are no financial relationships to private foundations or private companies with interest in our study.

References

1. Pouw, B., L. J. de Wit-van der Veen, M. P. Stokkel, C. E. Loo, M. J. Vrancken Peeters, and R. A. Valdes Olmos. 2015. Heading toward radioactive seed localization in non-palpable breast cancer surgery? A meta-analysis *J. Surg. Oncol.* 111:185–191.
2. Straver, M. E., C. E. Loo, T. Alderliesten, E. J. Rutgers, and M. T. Vrancken Peeters. 2010. Marking the axilla with radioactive iodine seeds (MARI procedure) may reduce the need for axillary dissection after neoadjuvant chemotherapy for breast cancer. *Br. J. Surg.* 97:1226–1231.
3. Donker, M., M. E. Straver, J. Wesseling, C. E. Loo, M. Schot, C. A. Drukker, et al. 2015. Marking axillary lymph nodes with radioactive iodine seeds for axillary staging after neoadjuvant systemic treatment in breast cancer patients: the MARI procedure. *Ann. Surg.* 261:378–382.
4. Gobardhan, P. D., R. S. Djamin, P. J. Romme, P. E. de Wit, H. G. de Groot, T. Adriaensen, et al. 2013. The use of iodine seed (I-125) as a marker for the localisation of lung nodules in minimal invasive pulmonary surgery. *Eur. J. Surg. Oncol.* 39:945–950.
5. Lonser, R. R., G. M. Glenn, M. Walther, E. Y. Chew, S. K. Libutti, W. M. Linehan, et al. 2003. von Hippel-Lindau disease. *Lancet* 361:2059–2067.
6. Reed, A. B., and D. J. Parekh. 2009. Surgical management of von Hippel-Lindau disease: urologic considerations. *Surg. Oncol. Clin. N. Am.* 18:157–174, x.
7. Langhans, L., T. L. Klausen, T. F. Tvedskov, M. L. Talman, P. S. Oturai, I. Vejborg, et al. 2015. Preparation and administration of I-125 labeled seeds for localization of nonpalpable breast lesions. *Curr. Radiopharm.* [Epub ahead of print].
8. Lane, B. R., and A. C. Novick. 2007. Nephron-sparing surgery. *BJU Int.* 99(5 Pt B):1245–1250.
9. McDougal, W. S. 2007. Radiofrequency ablation of renal cell carcinoma. *BJU Int.* 99(5 Pt B):1271–1272.