

## Brachial plexus tumor simulating an axillary metastasis from breast carcinoma

Anne Lynch, MBChB, and Gudrun Peters, MD

An ipsilateral axillary mass was detected on pre-operative ultrasound in a 79-year-old woman with newly diagnosed breast carcinoma. The mass had sonographic features that were initially thought to represent a lymph node completely replaced by metastatic disease. Though ultrasound-guided axillary fine-needle aspiration was attempted, it could not be performed due to pain. At surgery, the mass was found to be a brachial plexus tumor.

### Case report

A 79-year-old woman presented to our breast clinic with a two-week history of a tender medial right-breast lump. She had used hormone replacement therapy in the form of estrogen patches for 25 years. There was no history of neurological symptoms or deficit in the right upper limb. The breast lump was in the same area as several cysts that had been identified with mammography and ultrasound one year earlier. Current mammography and ultrasound showed an irregular 23mm mass suspicious for carcinoma at 3 o'clock in the right breast, corresponding to the new lump (Fig. 1). Core biopsy of this mass demonstrated invasive ductal carcinoma. Pre-operative axillary ultrasound showed a 20mm, well-defined, hypoechoic, oval mass with an eccentric hyperechoic focus (Figs. 2 and 3) in close proximity to the axillary artery and vein (Fig. 4). No vessels were seen within the mass on Doppler interrogation (Fig. 5), and it was not palpable by the treating breast surgeon. There were no other axillary abnormalities.

Ultrasound-guided, fine-needle aspiration (FNA) was attempted, in keeping with our policy when a possible axil-

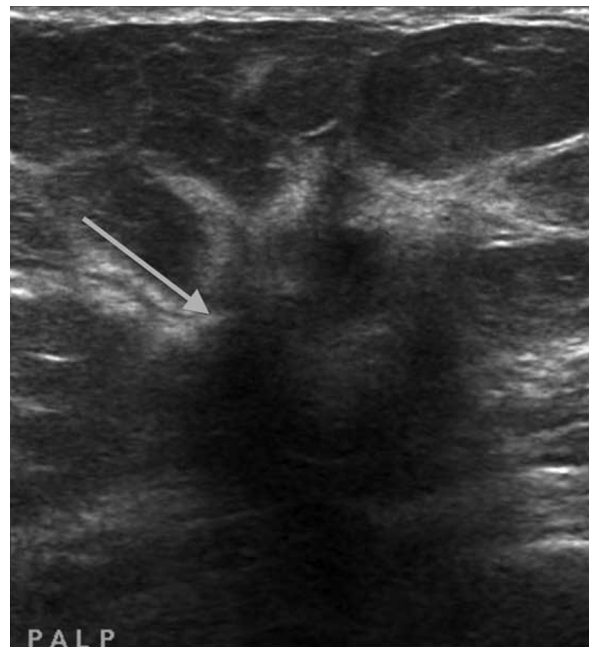


Figure 1. 79-year-old woman with brachial plexus tumor. Right breast carcinoma. Antiradial ultrasound shows a typical irregular hypoechoic mass (arrow) with some angulated margins at 3 o'clock in the right breast.

lary metastasis is present. At the time of FNA, the patient experienced shooting pain in her right axilla and arm with each of three needle approaches, despite infiltration of local anesthetic to the edge of the lesion. The biopsy was not performed, and the patient proceeded to definitive

**Citation:** Lynch A, Peters G. Brachial plexus tumor simulating an axillary metastasis from breast carcinoma. *Radiology Case Reports*. (Online) 2012;7:712.

**Copyright:** © 2012 The Authors. This is an open-access article distributed under the terms of the Creative Commons Attribution-NonCommercial-NoDerivs 2.5 License, which permits reproduction and distribution, provided the original work is properly cited. Commercial use and derivative works are not permitted.

Dr. Lynch is associated with BreastScreen Victoria, Monash Screening and Assessment Service, Victoria, Australia. Dr. Peters is associated with BreastScreen Tasmania, Hobart, Australia. Contact Dr. Lynch at [anne.lynych@breastunit.com.au](mailto:anne.lynych@breastunit.com.au).

**Competing Interests:** The authors have declared that no competing interests exist.

**DOI:** 10.2484/rcr.v7i3.712

## Brachial plexus tumor simulating an axillary metastasis from breast carcinoma

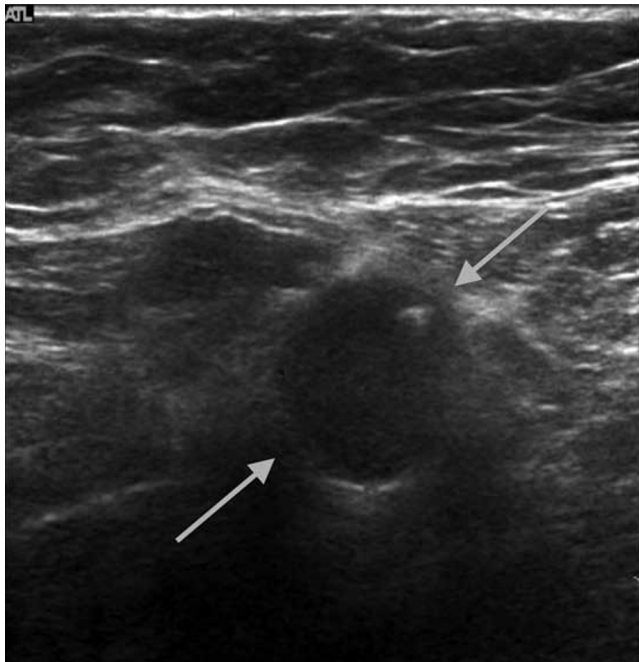


Figure 2. 79-year-old woman with brachial plexus tumor. Right axillary nerve-sheath tumor. Transverse ultrasound image shows a hyperechoic focus in the peripheral aspect of the tumor and a partially visualized capsule (arrows).

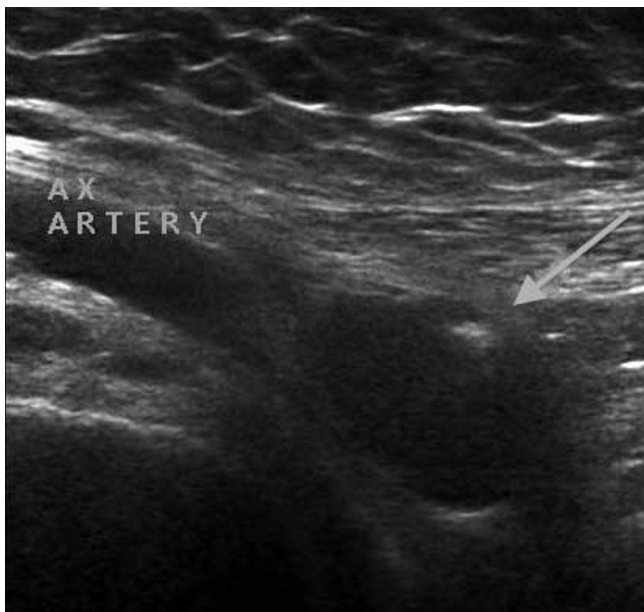

Figure 3. 79-year-old woman with brachial plexus tumor. Longitudinal ultrasound shows the right axillary artery with the adjacent nerve-sheath tumor. Note the eccentric hyperechoic focus (arrow).

wide-excision surgery in the breast and axillary sentinel-node biopsy, with the knowledge that axillary dissection might also be required. Surgical exploration of the axilla

revealed that the sonographic mass was a fusiform tumor arising from the medial cord of the brachial plexus, rather than a metastasis. A frozen section of the sentinel node did,

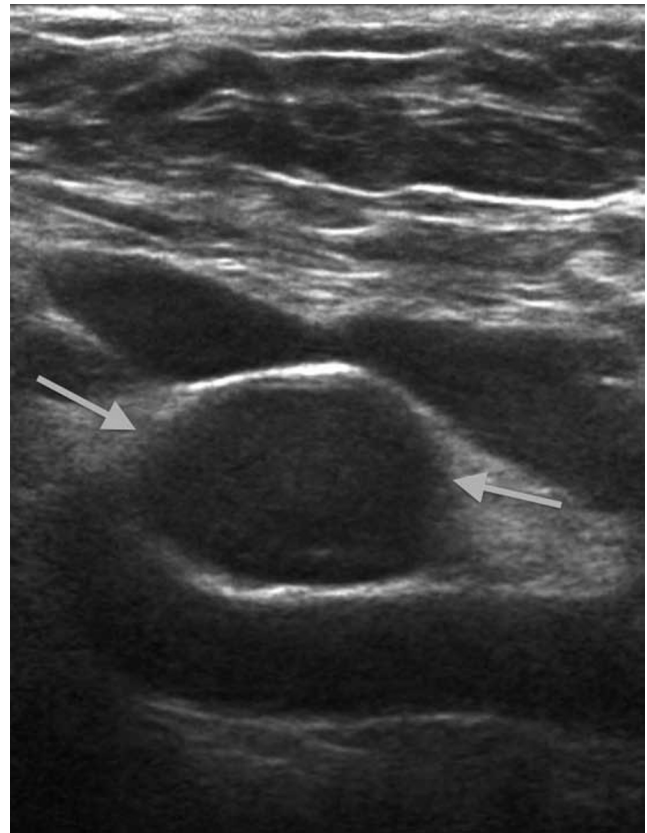


Figure 4. 79-year-old woman with brachial plexus tumor. Right axillary nerve-sheath tumor. Longitudinal ultrasound image shows an oval circumscribed mass (arrows) with thin hyperechoic capsule between the axillary vein and artery.

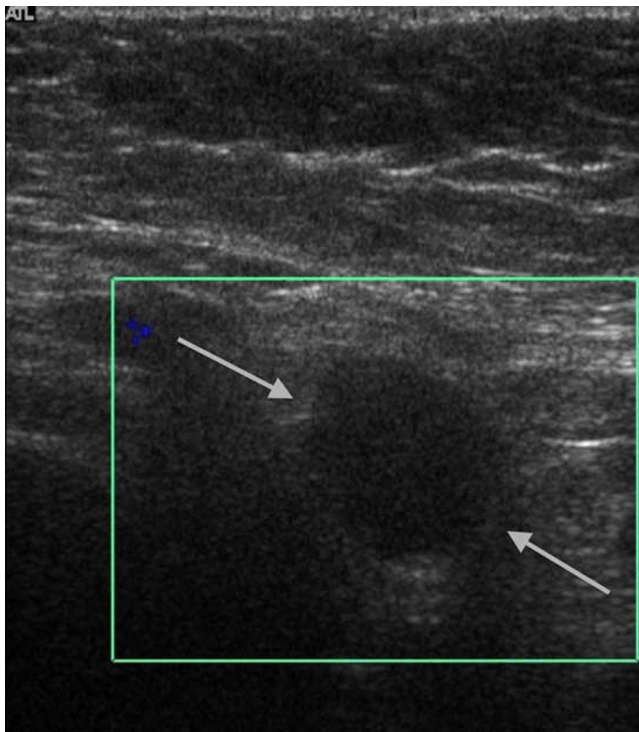
however, show metastatic tumor, and two additional positive nodes were found on subsequent axillary dissection. After intra-operative discussion with a neurosurgeon, no attempt was made to sample or dissect the brachial plexus tumor. The breast malignancy was a grade 2 invasive ductal carcinoma of no special type, with associated low-grade solid-type ductal carcinoma in situ.

### Discussion

Assessment of the ipsilateral axilla with ultrasound is now a routine part of the pre-operative workup of breast cancer patients, with the aim of identifying possible metastatic disease within lymph nodes. If nodal metastases are confirmed by either ultrasound-guided core biopsy or FNA, this allows for appropriate surgical planning and patient preparation for axillary dissection. Initial signs of metastatic disease in lymph nodes include eccentric cortical thickening and nodularity. As disease progresses, the nor-

## Brachial plexus tumor simulating an axillary metastasis from breast carcinoma

mal hyperechoic fatty hilum of the node becomes less visible, and it may eventually be completely obliterated, and the node then enlarges. In our experience, even metastatic



**Figure 5.** 79-year-old woman with brachial plexus tumor. Right axillary nerve-sheath tumor. Transverse ultrasound image shows a well-defined mass (arrows) with no detectable vascularity.

lymph nodes that are completely replaced by tumor often still retain their oval shape and can be well defined.

The differential diagnosis of a solid axillary mass should include benign masses and primary carcinomas arising within accessory axillary breast tissue, metastases of non-breast origin, extra-abdominal desmoid tumors, benign and malignant nerve sheath tumors, malignant fibrous histiocytomas, hemangiomas, lipomas, and old hematomas (1, 2). In view of the concurrent breast carcinoma in this case, the axillary mass was thought to be suspicious for metastatic disease, and other causes were not considered.

Neural-sheath tumors of the brachial plexus are relatively rare, with several series of up to 115 tumors reported (3). In the benign subgroup, neurofibromas and schwannomas have a similar incidence, each composing about 5% of all benign soft-tissue tumors. The position of the parent nerve relative to the mass is of some value in differentiating these entities in the axilla. The nerve is usually centrally located in a neurofibroma, and is eccentric but inseparable in a schwannoma (4, 5). Tsai et al reported a series of 76 extremity and superficial nerve-sheath tumors and found that an eccentric position of the mass to the nerve was suggestive of a schwannoma, whereas if the nerve position was

central, one could not distinguish between the two tumors (6). A capsule composed of epineurium may be present, which encapsulates the mass with progressive growth; however, neither the capsule nor the presence of intratumoral cysts or the degree of vascularity allows differentiation between neuromas and schwannomas (6). Both entities occasionally contain discrete hyperechoic foci, which may be due to focal collagen deposits. A complete or incomplete hyperechoic "ring sign" has also been described, and is said to be a rare but virtually pathognomonic feature of nerve sheath tumors (4, 7).

In retrospect, several sonographic features suggested that the axillary mass was not a metastatic lymph node in the present case. The axillary mass displayed a hyperechoic focus consistent with a collagen deposit (Figs. 4 and 5), and a capsule was also seen (Figs. 2 and 4). The mass was positioned close to the axillary vein (Fig. 2), in the region of the lateral node group, without other enlarged lymph nodes in the expected position of the pectoral and the central axillary groups. A solitary metastatic lateral lymph node from breast carcinoma would be unusual, as involved nodes are usually first visualized in the more inferior groups, toward the axillary tail of the breast. In addition, radiating and shooting pain at the time of attempted FNA should have alerted us to a possible brachial plexus lesion, as schwannomas, in particular, tend to be painful when undergoing percutaneous biopsy.

Four other case reports of benign brachial plexus tumors have been reported in breast cancer patients. All of these tumors were schwannomas. Two reports differ from the current case in that the schwannoma was diagnosed on followup imaging (MRI in one case, PET-CT in the other) between 2 and 5 years following initial breast cancer surgery (8, 9). One case was thought to be in association with neurofibromatosis type 1, and the schwannoma was surgically treated 2 years before the diagnosis of breast cancer (10). In only one other case report was the diagnosis of breast malignancy and brachial plexus tumor made at the same time (11).

Pre-operative diagnosis of a nerve sheath tumor may not be possible but is ideal to allow precise surgical planning and patient counseling. Even if ultrasound can show the relationship of a suspected brachial plexus mass to nerve bundles, MRI should be used to provide additional anatomical detail (3, 5, 12). Pre-operative open-incision biopsy and core biopsy should be avoided if possible, as these may result in peritumoral scar formation, making subsequent definitive resection more difficult. Surgical resection of a nerve-sheath tumor is best achieved with wide exposure of the lesion, microsurgical technique, and intraoperative electrophysiological monitoring. This allows complete excision without subsequent neurologic deficits for most benign tumors (3, 11).

In summary, brachial plexus tumors can mimic metastatic axillary lymph nodes on ultrasound, and they should be considered even when concurrent breast malignancy is present. Several sonographic features may aid in distinguishing between these two lesions and, in conjunction

## Brachial plexus tumor simulating an axillary metastasis from breast carcinoma

with MRI, allow correct pre-operative planning and better surgical outcome.

### References

1. Sohn YM, Kim SY, Kim EK. Sonographic appearance of a schwannoma mimicking an axillary lymphadenopathy. *J Clin Ultrasound*. 2011; 39: 477-479. [\[PubMed\]](#)
2. Kim EY, Ko EY, Han BK et al. Sonography of axillary masses: what should be considered other than the lymph nodes? *J Ultrasound Med*. 2009; 28: 923-939. [\[PubMed\]](#)
3. Desai KI. Primary Benign Brachial Plexus Tumors: An experience of 115 operated cases. *Neurosurgery*. 2012; 70(1): 220-233. [\[PubMed\]](#)
4. Beggs I. Sonographic appearances of nerve tumors. *J Clin Ultrasound*. 1999; 27: 363-368. [\[PubMed\]](#)
5. Beaman FD, Kransdorf MJ, Menke DM. Schwannoma: radiologic-pathologic correlation. *Radiographics*. 2004; 24: 1477-81. [\[PubMed\]](#)
6. Tsai WC, Chiou HJ, Chou YH, Wang HK, Chiou SY, Chang CH. Differentiation between schwannomas and neurofibromas in the extremities and superficial body: the role of high-resolution and color Doppler ultrasonography. *J Ultrasound Med*. 2008; 27(2): 161-166. [\[PubMed\]](#)
7. Beggs I. The ring sign: a new ultrasound sign of peripheral nerve tumors. *Clin Radiol*. 1998; 53: 849-850. [\[PubMed\]](#)
8. Fujiuchi N, Saeki T, Takeuchi H et al. A false positive for metastatic lymph nodes in the axillary region of a breast cancer patient following mastectomy. *Breast Cancer*. 2011; 18: 141-144. [\[PubMed\]](#)
9. Rodríguez BG, Moreno-Gutiérrez A, Gutiérrez-González R, Villar-Martin A, Arraez-Aybar LA, Serrano Hernando J. Schwannoma of the brachial plexus resembling a breast adenocarcinoma metastasis. *Medicina (B Aires)*. 2011; 71(5): 459-461. [\[PubMed\]](#)
10. Godwin JT. Encapsulated neurilemmoma (schwannoma) of the brachial plexus; report of 11 cases. *Cancer*. 1952; 5: 708-720. [\[PubMed\]](#)
11. Nakamura M, Akao S. Neurilemmoma arising in the brachial plexus in association with breast cancer: report of case. *Surg Today*. 2000; 30: 1012-05. [\[PubMed\]](#)
12. Kim WK, Ahn SK, Song JH. A case of brachial plexus schwannoma. *J Korean Neurosurg Soc*. 2006; 39(5): 396-399. <http://jkns.or.kr/htm/abstract.asp?no=0042006077&m=006/06/2012>