

---

## New technique for challenging cases of percutaneous balloon mitral valvuloplasty: The venoarterial looping

**İsmail Ateş, Şeref Ulucan<sup>1</sup>, Zeynettin Kaya<sup>1</sup>, Mehmet Doğru<sup>2</sup>, Hüseyin Katlandur<sup>1</sup>, Ahmet Keser<sup>1</sup>**

**Clinic of Cardiology, Sema Hospital; Almaty-Kazakhstan**

**<sup>1</sup>Department of Cardiology, Faculty of Medicine, Mevlana University; Konya-Turkey**

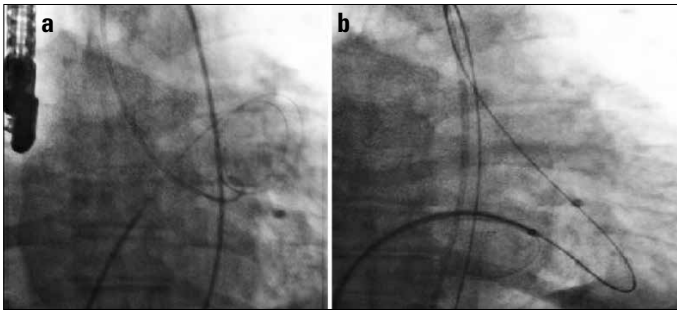
**<sup>2</sup>Clinic of Cardiology, Medline Hospital; Antalya-Turkey**

### Introduction

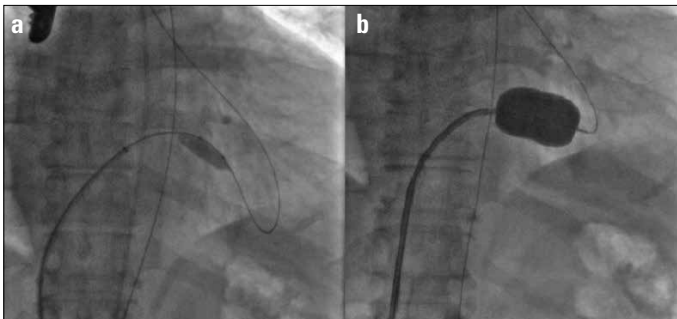
Mitral stenosis (MS) is generally the sequel of rheumatic carditis occurring in childhood (1). MS is particularly observed in developing countries (1, 2). Untreated patients can develop irreversible right ventricular failure (1, 2). Since its introduction by Inoue, percutaneous mitral balloon valvuloplasty (PMBV) is considered the leading and effective treatment option for symptomatic moderate to severe MS with favorable valve morphology (3, 4). PMBV provides immediate and sustained hemodynamic improvement, comparable with the results of surgery (3). However, there are challenges in some cases of PMBV, where surgery is also not feasible. Various techniques have been described for directing the mitral balloon catheter to left ventricle during PMBV (5-9). Here we aim to define a new technique for challenging cases of PMBV in patients with a large left atrium and a severe MS called the venoarterial looping.

### Case Report

A 67-year-old man was transferred to an intensive care unit from emergency service after intubation due to acute respiratory failure. The patient showed significant rheumatic MS (mitral valve area 0.6 cm<sup>2</sup>) and systolic heart failure (the left ventricular ejection fraction was 30%) associated with wide QRS complex (left bundle branch block; QRS duration >150 ms), and atrial fibrillation with rapid ventricular response



**Figure 1. a, b. Fluoroscopic images demonstrating the challenging septostomy procedure (a) and venoarterial looping (b)**



**Figure 2. a, b. Fluoroscopic records show the predilatation of the mitral valve with a 10/40-mm peripheral balloon catheter (a) and final dilatation of the mitral valve with a Toray mitral balloon catheter (b)**

on electrocardiography. After the recovery period, we decided to perform PMBV and cardiac resynchronization therapy-defibrillator (CRT-D) implantation combined with atrioventricular (AV) node ablation at the same session. Septostomy was performed despite the difficulties (e.g., shifting of interatrial septum) by assistance of transesophageal echocardiography (Fig. 1a). However, we could not direct the mitral balloon catheter to the mitral valve, even after attempting several maneuvers because of left atrium being very large and huge along with severe MS. We decided to attempt a new technique. A 0.35-in Terumo guidewire was directed to the aorta crossing mitral valve and left ventricle using a multipurpose catheter. Next, the guidewire was forwarded into the descending aorta, snared in left common iliac artery, and pulled out from the sheath. The venoarterial loop was formed for good support (Fig. 1b). A peripheral balloon catheter was advanced via right femoral vein over the guidewire. Predilatation of the mitral valve was performed by 10/40- and 12/40-mm peripheral balloon catheters (Fig. 2a). Finally, the Toray mitral balloon was advanced over the guidewire. The mitral valve was passed very easily and a 28-mm Toray mitral balloon was inflated (Fig. 2b). The mitral valve area was estimated to be 2.2 cm<sup>2</sup> at the end of the procedure. Mitral gradient decreased from 16 mm Hg to 5.5 mm Hg. Mild mitral but acceptable regurgitation was observed. Finally, CRT-D was implanted and AV node ablation was performed. The patient was discharged without complications.

## Discussion

PMBV is recommended as a first-line therapy with high success and low complication rate in clinical and anatomical appropriate cases (3).

Although PMBV previously preferred only in young patients with mild to moderate stenosis, recently, PMBV are widely performed in older patients with severe MS. Therefore, various difficulties have emerged during the procedure of PMBV. Various loop and over-the-wire techniques have been defined to overcome these challenges (5-9).

Here we introduce a new modified over-the-wire technique. Unlike the other methods, a complete venoarterial loop was formed to provide better support. Then, we used the peripheral balloon catheter for predilatation of the stenotic valve. Finally, the Toray mitral balloon was advanced over a 0.35-inch guidewire and mitral valve was passed very easily.

## Conclusion

The venoarterial looping is a unique technique and it may be useful in difficult PMBV cases.

## References

1. Lung B, Vahanian A. Epidemiology of acquired valvular heart disease. *Can J Cardiol* 2014; 30: 962-70. [\[CrossRef\]](#)
2. Kumar RK, Tandon R. Rheumatic fever & rheumatic heart disease: the last 50 years. *Indian J Med Res* 2013; 137: 643-58.
3. Nishimura RA, Otto CM, Bonow RO, Carabello BA, Erwin JP 3rd, Guyton RA, et al. 2014 AHA/ACC guideline for the management of patients with valvular heart disease: a report of the American College of Cardiology/American Heart Association Task Force on Practice Guidelines. *J Thorac Cardiovasc Surg* 2014; 148: e1-132. [\[CrossRef\]](#)
4. Kaya Z, Karapınar H, Kaya H, Batukan Esen O, Akçakoyun M, Acar G, et al. Evaluation of the long-term effect of percutaneous balloon valvuloplasty on right ventricular function using tissue Doppler imaging in patients with mitral stenosis. *Türk Kardiyol Derneği Arş* 2014; 42: 35-43. [\[CrossRef\]](#)
5. Safi AM, Kwan T, Clark LT. Successful percutaneous balloon mitral valvuloplasty using left ventricular pressure as a guide to cross the mitral valve-A case report. *Angiology* 2000; 51: 83-6. [\[CrossRef\]](#)
6. Ramamurthy S, Bahl VK, Manchanda SC. Successful Inoue balloon valvotomy in a difficult case of mitral stenosis using multiple modifications of technique: alternative method for loop formation of the Inoue balloon catheter. *J Invasive Cardiol* 2001; 13: 755-7.
7. Deora S, Vyas C, Shah S. Percutaneous transvenous mitral commissurotomy: a modified over-the-wire technique for difficult left ventricle entry. *J Invasive Cardiol* 2013; 25: 471-3.
8. Trehan V, Mehta V, Mukhopadhyay S, Yusuf J, Kaul UA. Difficult percutaneous transvenous mitral commissurotomy: a new technique for left atrium to left ventricular entry. *Indian Heart J* 2004; 56: 158-62.
9. Mehan VK, Meier B. Impossibility to cross a stenotic mitral valve with the Inoue balloon: success with a modified technique. *Indian Heart J* 1994; 46: 51-2.

**Address for Correspondence:** Dr. Zeynettin Kaya,  
Mevlana Üniversitesi Tıp Fakültesi,  
Kardiyoloji Anabilim Dalı,  
Yeni İstanbul Cad. No: 235  
42003 Selçuklu/Konya-Türkiye  
Phone: +90 505 253 70 49  
E-mail: zeynettinkeya@yahoo.com



©Copyright 2015 by Turkish Society of Cardiology - Available online at [www.anatoljcardiol.com](http://www.anatoljcardiol.com)  
DOI:10.5152/akd.2015.6127