



Arthroscopic Arthrodesis of the Lesser Ray Tarsometatarsal Joints: 2-Portal Technique

Tun Hing Lui, M.B.B.S.(H.K.), F.R.C.S.(Edin.), F.H.K.A.M., F.H.K.C.O.S.

Abstract: Tarsometatarsal (Lisfranc) destruction of the tarsometatarsal articulation of the lesser rays is most commonly due to midfoot Charcot neuroarthropathy. Tarsometatarsal arthrodesis is indicated when conservative management cannot relieve the symptoms. The purpose of this Technical Note is to describe a minimally invasive approach of arthroscopic arthrodesis of the destroyed lesser ray tarsometatarsal joints. The arthroscopic procedure is performed through the lateral and P1-2 Lisfranc portals. It has the advantages of better cosmesis, less wound complication, less bone resection, and more thorough joint debridement. However, it is contraindicated if there is associated significant foot deformity or shortening of the lesser foot rays.

Tarsometatarsal (Lisfranc) destruction of the tarsometatarsal articulation of the lesser rays can be a disabling condition. It is most commonly due to midfoot Charcot neuroarthropathy.¹ Conservative treatments include rocker bottom shoes, orthoses, and analgesics.² Tarsometatarsal arthrodesis is indicated when conservative management cannot relieve the symptoms.³ Classically, this is performed as an open procedure with extensive incisions and soft tissue dissection.^{2,4-7} Arthroscopic Lisfranc arthrodesis has been reported and involves 6 portals: medial and lateral portals together with 4 junctional portals.⁸⁻¹² The purpose of this Technical Note is to describe a minimally invasive approach of arthroscopic arthrodesis of the tarsometatarsal joints of the lesser rays through 2 portals. It is indicated if there is symptomatic tarsometatarsal destruction of the lesser rays. It is contraindicated if there is significant bone loss requiring strut graft reconstruction. It is also

contraindicated if the bone is soft and cannot be stably fixed with screws or open reduction is required for deformity correction (Table 1).

Technique

Preoperative Planning and Patient Positioning

Standard dorsoplantar, oblique, and lateral radiographs of the foot are important to confirm the surgical indication (Fig 1).

The patient is in the supine position with the legs spread. A thigh tourniquet (Zimmer, Warsaw, IN) is applied to provide a bloodless operative field. A 2.7-mm 30° arthroscope (Henke Sass Wolf, Tuttlingen, Germany) is used for this procedure. Fluid inflow is by gravity and no arthropump is used.

Portal Placement

This procedure is performed through the L1-2 and lateral tarsometatarsal (Lisfranc) portals. The L1-2 portal is located at the medial side of the second tarsometatarsal articulation and the lateral portal is located at the lateral side of the fifth metatarsocuboid articulation (Fig 2). Three- to four-millimeter skin incisions are made at the portal sites and the subcutaneous tissue is bluntly dissected to the joint by a hemostat. The joint capsule is perforated by the tip of the hemostat. Sometimes, the capsule is fibrotic and thick and should be incised open.

Debridement of the Lateral Half of the Tarsometatarsal Joint of the Lesser Rays

The P1-2 portal is the viewing portal and the lateral portal is the working portal. Usually, the destroyed joint allows direct insertion of the arthroscope and

From the Department of Orthopaedics and Traumatology, North District Hospital, Sheung Shui, NT, Hong Kong SAR, China.

The author reports that he has no conflicts of interest in the authorship and publication of this article. Full ICMJE author disclosure forms are available for this article online, as [supplementary material](#).

Received March 28, 2017; accepted June 2, 2017.

Address correspondence to Tun Hing Lui, M.B.B.S.(H.K.), F.R.C.S.(Edin.), F.H.K.A.M., F.H.K.C.O.S., Department of Orthopaedics and Traumatology, North District Hospital, 9 Po Kin Road, Sheung Shui, NT, Hong Kong SAR, China. E-mail: luithderek@yahoo.co.uk

© 2017 by the Arthroscopy Association of North America. Published by Elsevier. This is an open access article under the CC BY-NC-ND license (<http://creativecommons.org/licenses/by-nc-nd/4.0/>).

2212-6287/17402

<http://dx.doi.org/10.1016/j.eats.2017.06.003>

Table 1. Indications and Contraindications of Arthroscopic Tarsometatarsal Arthrodesis: 2-Portal Technique

Indications	Contraindications
1. It is indicated if there is symptomatic tarsometatarsal destruction of the lesser rays	1. It is contraindicated if there is significant bone loss requiring strut graft reconstruction
	2. It is contraindicated if the bone is soft and cannot be stably fixed with screws
	3. It is contraindicated if open reduction is required for deformity correction

arthroscopic shaver (Dyonics, Smith & Nephew, Andover, MA) into the gap between the articular surfaces. If not, the arthroscope and arthroscopic instrument can be inserted into the dorsal gutter first and the dorsal soft tissue is stripped from the bone to increase the space between the articular surfaces for subsequent joint debridement. The lateral half of the joint is debrided down to the plantar capsule until the bone surfaces of the joint can be seen (Fig 3). The position of the arthroscopic instrument is regularly checked under fluoroscopy because there is no clear arthroscopic landmark in the destroyed joint.

Debridement of the Medial Half of the Tarsometatarsal Joint of the Lesser Rays

The lateral portal is the viewing portal and the P1-2 portal is the working portal. The medial half of the joint is debrided down to the plantar capsule by means

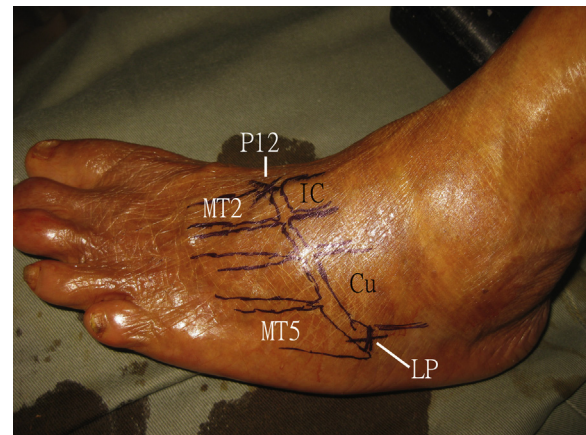


Fig 2. Arthroscopic arthrodesis of the lesser ray tarsometatarsal joints of the left foot. The patient is in the supine position. This procedure is performed through the L1-2 and lateral tarsometatarsal (Lisfranc) portals. The L1-2 portal is located at the medial side of the second tarsometatarsal articulation and the lateral portal is located at the lateral side of the fifth metatarsocuboid articulation. (Cu, cuboid bone; IC, intermediate cuneiform bone; LP, lateral portal; MT2, second metatarsal; MT5, fifth metatarsal; P12, P1-2 portal.)

of the arthroscopic shaver until the bone surfaces of the joint can be seen (Fig 4).

Preparation of the Fusion Surfaces

Microfracture of bone surfaces of both tarsal and metatarsal bones is performed with an arthroscopic awl (Acufex, Smith & Nephew) via the lateral and

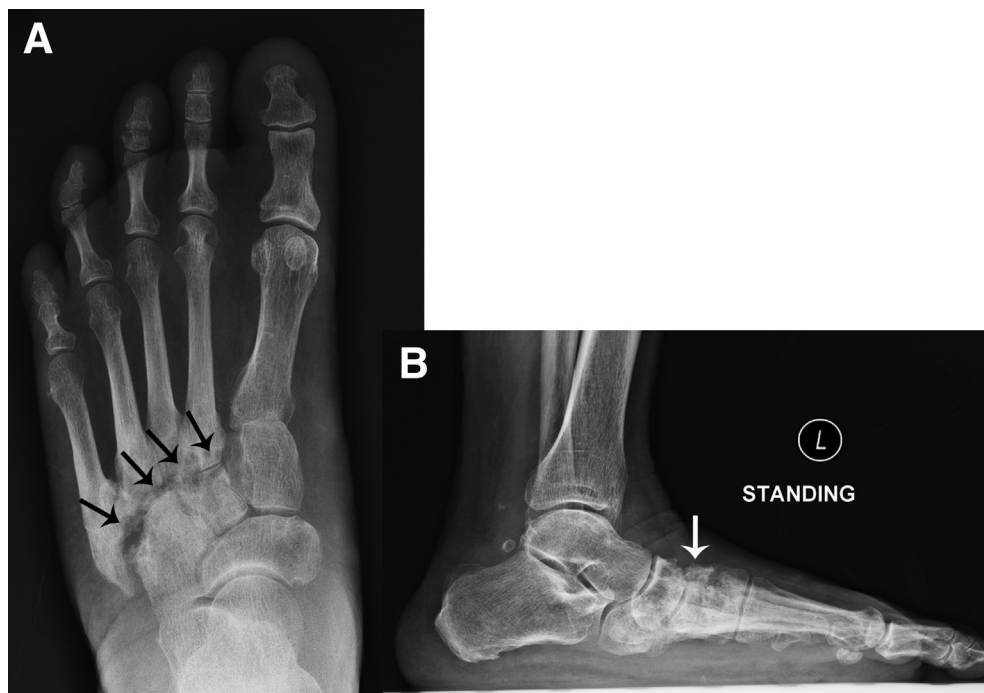


Fig 1. Arthroscopic arthrodesis of the lesser ray tarsometatarsal joints of the left foot. The patient is in the supine position. Standing dorsoplantar (A) and lateral (B) radiographs of the left foot of the illustrated case show destruction of the second to fourth tarsometatarsal joints (arrows).

Fig 3. Arthroscopic arthrodesis of the lesser ray tarsometatarsal joints of the left foot. The patient is in the supine position. (A) The P1-2 portal is the viewing portal and the lateral portal is the working portal. (B) The lateral half of the joint is debrided. (AS, arthroscopic shaver; LP, lateral portal; MT, metatarsal bone; P12, P1-2 portal; T, tarsal bone.)

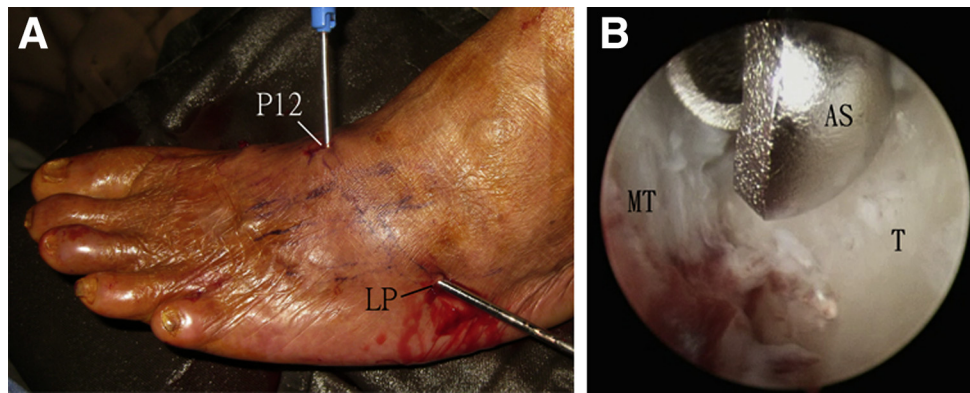
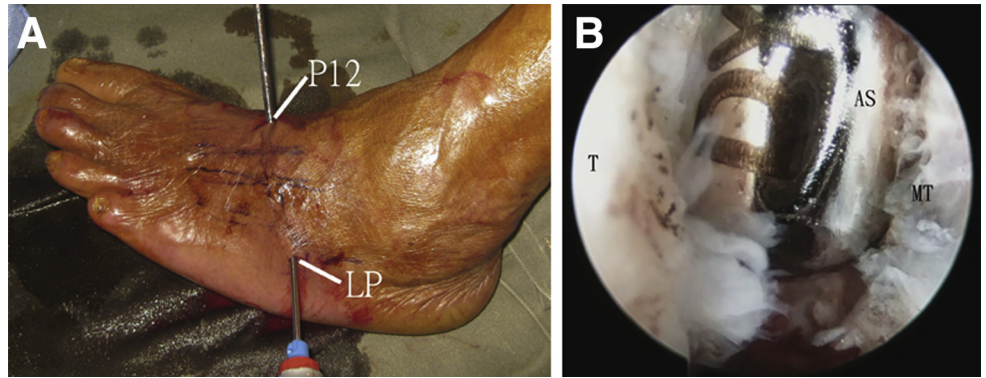
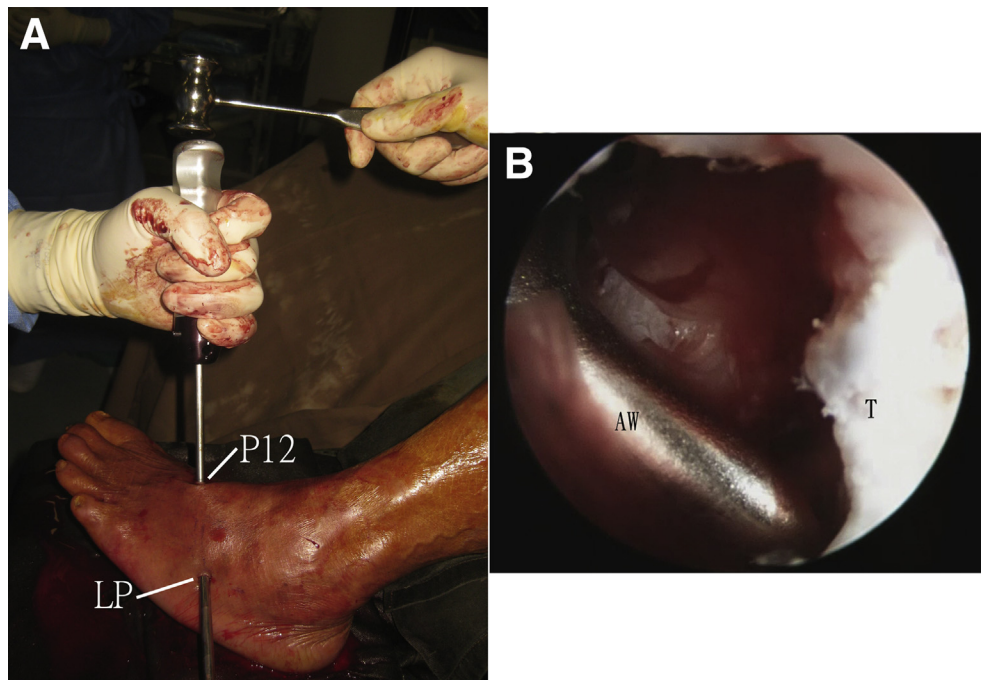


Fig 4. Arthroscopic arthrodesis of the lesser ray tarsometatarsal joints of the left foot. The patient is in the supine position. (A) The lateral portal is the viewing portal and the P1-2 portal is the working portal. (B) The medial half of the joint is debrided. (AS, arthroscopic shaver; LP, lateral portal; MT, metatarsal bone; P12, P1-2 portal; T, tarsal bone.)

Fig 5. Arthroscopic arthrodesis of the lesser ray tarsometatarsal joints of the left foot. The patient is in the supine position. (A) The lateral portal is the viewing portal and the P1-2 portal is the working portal. (B) Microfracture of tarsal bone surface is performed with an arthroscopic awl. (AW, arthroscopic awl; LP, lateral portal; P12, P1-2 portal; T, tarsal bone.)



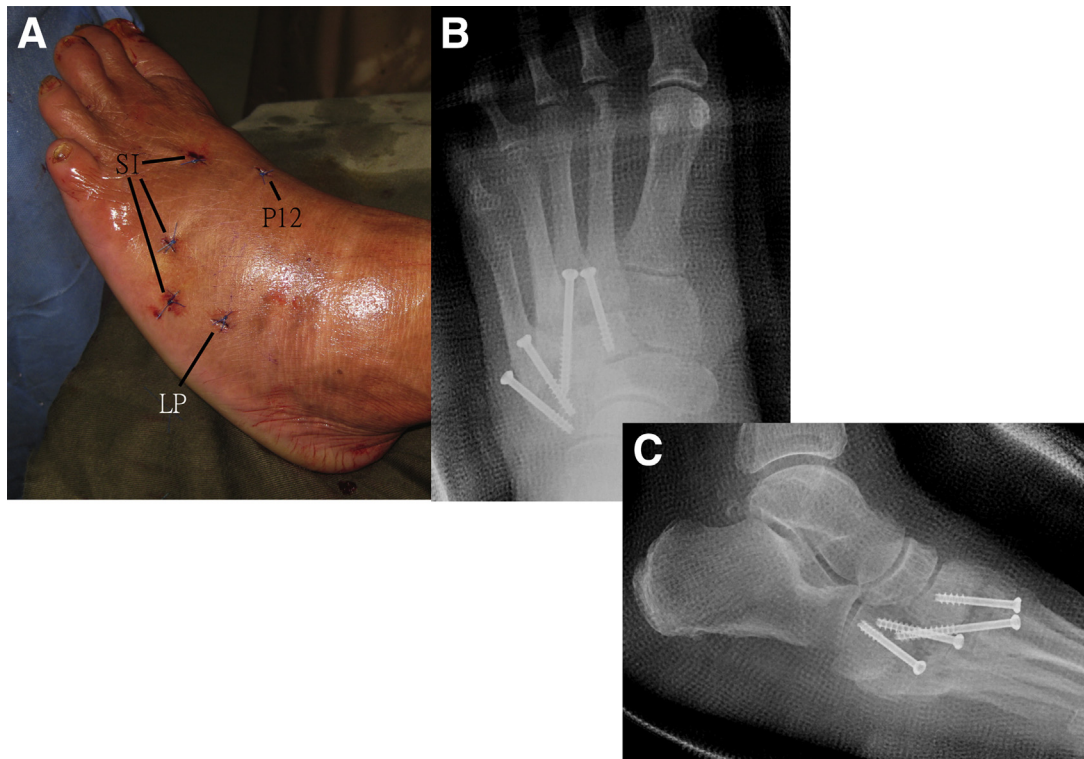


Fig 6. Arthroscopic arthrodesis of the lesser ray tarsometatarsal joints of the left foot. The patient is in the supine position. (A) The portals and screw insertion wounds are closed with simple sutures. (B) Dorsoplantar radiograph shows the second to fifth tarsometatarsal joints transfixed with screws. (C) Lateral radiograph shows the correction of the midfoot deformity. (LP, lateral portal; P12, P1-2 portal; SI, screw insertion wounds.)

P1-2 portals with the arthroscope in the opposite portal (Fig 5).

Positioning of the Lesser Ray Tarsometatarsal Joints and Screw Fixation of the Fusion Sites

The joint is put into a desirable position especially to avoid excessive pressure over the lateral column and compressed manually. It is transfixed with 4.0-mm cannulated screws (Synthes, West Chester, PA) across each articulation of the lesser rays (Fig 6, Video 1, Table 2). The foot is immobilized in a short leg cast for 12 to 16 weeks depending on the underlying pathology. Non-weight-bearing is advised during this period.

Discussion

Maintaining the mobility of the fourth and fifth tarsometatarsal joints has been reported to be important in arthrodesis of the tarsometatarsal joint. However, fusion of the lateral column can be necessary for correction of painful or unstable midfoot destruction.^{3,5,13}

This reported 2-portal technique is feasible because the following prerequisites are fulfilled:

- (1) The second to fifth tarsometatarsal joints share a common capsular compartment.
- (2) The erosive arthropathy eliminates the stepping at the second tarsometatarsal joint making the lesser ray tarsometatarsal joints at the same level.

Table 2. Pearls and Pitfalls of Arthroscopic Tarsometatarsal Arthrodesis: 2-Portal Technique

Pearls	Pitfalls
1. The position of the arthroscopic instrument is regularly checked under fluoroscopy because there is no clear arthroscopic landmark in the destructed joint	1. The patient should be compliant to the prolonged cast immobilization and strict non-weight-bearing
2. Joint debridement should be completed down to the plantar capsule	2. If there is difficulty in accessing some part of the joint, an additional Lisfranc portal should be established
3. The midfoot should be fixed in a slightly supinated position to avoid excessive pressure over the lateral column	

Table 3. Advantages and Risks of Arthroscopic Tarsometatarsal Arthrodesis: 2-Portal Technique

Advantages	Risks
1. Less wound complication	1. Injury to the superficial peroneal nerve
2. Less soft tissue trauma	2. Injury to the deep peroneal nerve
3. Better cosmesis	3. Injury to the dorsalis pedis artery
4. Less bone resection and less shortening of the foot rays	4. Malunion and metatarsalgia
5. More thorough debridement of the deep part of the joints under arthroscopic visualization	5. Nonunion
	6. Implant failure

- (3) The destructed joint is spacious enough to allow insertion of the arthroscopic instruments into the joint space throughout its span.

The advantages of this minimally invasive approach include better cosmesis, less soft tissue dissection, low risk of wound complication, minimal bone resection, minimal shortening of the involved foot rays, and more thorough debridement of deep part of the joints under arthroscopic visualization. The structures at risk include the superficial and deep peroneal nerves, dorsalis pedis artery. Other complications of this procedure include infection, nonunion, malunion, and implant failure. Metatarsalgia may be encountered if positioning of the metatarsal heads at the time of fusion is not properly assessed (Table 3).

References

- Lamm BM, Siddiqui NA, Nair AK, LaPorta G. Intra-medullary foot fixation for midfoot Charcot neuro-arthropathy. *J Foot Ankle Surg* 2012;51:531-536.
- Withey CJ, Murphy AL, Horner R. Tarsometatarsal joint arthrodesis with trephine joint resection and dowel calcaneal bone graft. *J Foot Ankle Surg* 2014;53:243-247.
- Russell DF, Ferdinand RD. Review of the evidence: Surgical management of 4th and 5th tarsometatarsal joint osteoarthritis. *Foot Ankle Surg* 2013;19:207-211.
- Komenda GA, Myerson MS, Biddinger KR. Results of arthrodesis of the tarsometatarsal joints after traumatic injury. *J Bone Joint Surg Am* 1996;78:1665-1676.
- Treadwell JR, Kahn MD. Lisfranc arthrodesis for chronic pain: A cannulated screw technique. *J Foot Ankle Surg* 1998;37:28-36.
- Rammelt S, Schneiders W, Zwipp H. Corrective tarsometatarsal arthrodesis for malunion after fracture-dislocation. *Orthopade* 2006;35:435-442.
- Myerson MS. The diagnosis and treatment of injury to the tarsometatarsal joint complex. *J Bone Joint Surg Br* 1999;81:756-763.
- Lui TH. Arthroscopic tarsometatarsal (Lisfranc) arthrodesis. *Knee Surg Sports Traumatol Arthrosc* 2007;15:671-675.
- Lui TH. Arthroscopic lysis of arthrofibrosis of the fifth tarsometatarsal joint. *Arthrosc Tech* 2015;4:e707-e710.
- Lui TH. Lateral foot pain following open reduction and internal fixation of the fracture of the fifth metatarsal tubercle: Treated by arthroscopic arthrolysis and endoscopic tenolysis [published online April 17, 2014]. *BMJ Case Rep*. doi:10.1136/bcr-2014-204116.
- Lui TH. Arthroscopy and endoscopy of the foot and ankle: Indications for new techniques. *Arthroscopy* 2007;23:889-902.
- Lui TH. Arthroscopic tarsometatarsal arthrodesis. *Arthrosc Tech* 2016;5:e1311-e1316.
- Raikin SM, Schon LC. Arthrodesis of the fourth and fifth tarsometatarsal joints of the midfoot. *Foot Ankle Int* 2003;24:584-590.