

# Femoro-Supragenicular Popliteal Bypass with a Bridging Stent Graft in a Diffusely Diseased Distal Target Popliteal Artery: Alternative to Below-Knee Popliteal Polytetrafluoroethylene Bypass

Joung Hun Byun, M.D.<sup>1</sup>, Tae Gyu Kim, M.D.<sup>2</sup>, Yun Gyu Song, M.D., Ph.D.<sup>3</sup>

<sup>1</sup>Department of Thoracic and Cardiovascular Surgery, Gyeongsang National University Changwon Hospital, Departments of <sup>2</sup>Radiation Oncology and <sup>3</sup>Radiology, Samsung Changwon Hospital, Sungkyunkwan University School of Medicine

**Background:** Lesions in distal target arteries hinder surgical bypass procedures in patients with peripheral arterial occlusive disease. **Methods:** Between April 2012 and October 2015, 16 patients (18 limbs) with life-style-limiting claudication (n=12) or chronic critical limb ischemia (n=6) underwent femoral-above-knee (AK) polytetrafluoroethylene (PTFE) bypass grafts with a bridging stent graft placement between the distal target popliteal artery and the PTFE graft. Ring-supported PTFE grafts were used in all patients with no available vein for graft material. Follow-up evaluations assessed clinical symptoms, the ankle-brachial index, ultrasonographic imaging and/or computed tomography angiography, the primary patency rate, and complications. **Results:** All procedures were successful. The mean follow-up was 12.6 months (range, 11 to 14 months), and there were no major complications. The median baseline ankle-brachial index of 0.4 (range, 0.2 to 0.55) significantly increased to 0.8 (range, 0.5 to 1.0) at 12 months ( $p < 0.01$ ). The primary patency rate at 12 months was 83.3%. The presenting symptoms resolved within 2 weeks. **Conclusion:** In AK bypasses with a diffusely diseased distal target popliteal artery or when below-knee (BK) bypass surgery is impossible, this procedure could be clinically effective and safe when used as an alternative to femoral-BK bypass surgery.

*Key words:* 1. Arteries  
2. Bypass  
3. Graft  
4. Stents

## Introduction

Femoral-above-knee (AK) popliteal bypass surgery is a long-standing, well-recognized revascularization procedure used in the lower extremities of patients with atherosclerotic occlusive disease. Lesions in distal target arteries hinder surgical bypass procedures in patients with peripheral arterial occlusive disease

(PAOD). Experienced surgeons have raised concerns about whether the optimal location of distal anastomosis is AK or below-knee (BK) [1]. Previous studies have reported that synthetic grafts are considered acceptable alternatives for femoral-AK popliteal bypass procedures, unlike femoral-BK popliteal bypass procedures [2-4].

Endovascular alternatives have been introduced for

Received: January 2, 2017, Revised: April 30, 2017, Accepted: May 9, 2017, Published online: October 5, 2017

Corresponding author: Yun Gyu Song, Department of Radiology, Samsung Changwon Hospital, Sungkyunkwan University School of Medicine, 158 Paryong-ro, Masanhoewon-gu, Changwon 51353, Korea  
(Tel) 82-55-290-6092 (Fax) 82-55-290-6087 (E-mail) yawoo114@naver.com

© The Korean Society for Thoracic and Cardiovascular Surgery. 2017. All right reserved.

© This is an open access article distributed under the terms of the Creative Commons Attribution Non-Commercial License (<http://creativecommons.org/licenses/by-nc/4.0>) which permits unrestricted non-commercial use, distribution, and reproduction in any medium, provided the original work is properly cited.

advanced PAOD, but do not lead to better results or may not be feasible [5]. Recently, the Viabahn Open Revascularization Technique (VORTEC) and Viabahn Padova Sutureless (ViPS) techniques for the anastomosis of synthetic grafts to diseased and calcified AK popliteal arteries have been applied in femoropopliteal occlusive disease [6-8].

Generally, the patency of BK polytetrafluoroethylene (PTFE) bypass grafts is inferior to that of AK PTFE bypass grafts [1,9,10]. Moreover, long superficial femoral artery (SFA) occlusion may sometimes occur with a diffusely diseased distal target popliteal artery or if BK bypass surgery is impossible due to conditions such as a skin wound at the incision site. Therefore, there is a need for an alternative to BK PTFE bypass grafts.

To our knowledge, few studies have reported alternatives to BK popliteal PTFE bypass surgery in patients with lifestyle-limiting claudication (LLC) or chronic critical limb ischemia (CLI).

Therefore, we aimed to report the results of femoral-AK popliteal PTFE bypass grafts with a bridging stent graft placement between the distal target popliteal artery and PTFE graft in patients with long SFA occlusion with diffusely diseased or calcified distal target popliteal arteries as an alternative to BK popliteal PTFE bypass surgery.

## Methods

This was a case-series study that was retrospectively reviewed and approved by the institutional review board of Samsung Changwon Hospital (No. SCMC-031-000) and performed in accordance with the principles of the Declaration of Helsinki. Written informed consents were obtained.

Computed tomography angiography (CTA) was initially performed in consecutive patients with LLC or chronic CLI. Femoral-AK popliteal bypass procedures with placement of a bridging stent graft between the distal target popliteal artery and a PTFE graft (Rutherford classification 3 to 5) were performed in our hospital between April 2012 and October 2015. All patients were counseled on smoking cessation and walking exercise. All patients received aspirin (81 mg or 325 mg), a vasodilator (calcium channel blocker), and statins. All patients underwent intramuscular injection of 5,000 units of low-molec-

ular-weight heparin for 1 day and oral administration of warfarin and aspirin from day 2 postoperatively to maintain the prothrombin time between an international normalized ratio of 1.5 and 2.0. The use of postoperative anticoagulation medication was planned for the lifetime of the patients.

Patients were included based on the following criteria: long chronic SFA occlusion, a circumferentially calcified or diseased AK and BK popliteal artery that was not a candidate for traditional bypass surgery, prominent collateral vessels arising from the deep femoral artery around the knee, and no available saphenous or brachial vein for an autogenous conduit. No vein was considered to be available if the vein was very small (<3 mm) or showed fibrotic changes of the vessel wall.

Femoral-AK popliteal bypass procedures for contralateral lesions were performed in 2 patients. Preoperative distal runoff was scored by the number of patent tibial vessels. Lesions of the femoropopliteal artery were categorized as C and D according to the second TransAtlantic Inter-Society Consensus. Age, gender, procedure-related adverse events, the ankle-brachial index (ABI), and patency rate were evaluated. The preoperative characteristics of patients and lesions are presented in Table 1.

### 1) Procedures

The original report by Greenberg et al. [7] outlines the basic technique of VORTEC [6]. Under general anesthesia, all procedures were performed using fluoroscopy in an operating room. Standard surgical exposure of the common femoral artery and AK popliteal artery was performed. After administration of heparin to maintain the activated clotting time in the range of 180 to 200 seconds, the proximal part of the common femoral artery was clamped. The proximal end of the ring-supported PTFE graft was sutured to the common femoral artery in an end-to-side fashion. The distal end of the PTFE graft was tunneled to the distal thigh.

A 1-cm longitudinal incision of the anterior wall of the AK popliteal artery was made. The distal end of the PTFE graft was sutured to the AK popliteal artery in an end-to-side fashion. After releasing the clamp applied to the proximal artery, the distal PTFE graft was punctured with an 18-gauge access needle, and a 0.889-mm guidewire (Terumo, Tokyo, Japan)

Table 1. Preoperative characteristics

Patient no.	Sex/age (yr)	Symptoms	Ankle-brachial index	Target vessel size (mm)	No. of tibial vessels	TransAtlantic Inter-Society Consensus II category	Saphenous vein status
1	M/72	Claudication	0.55	5.2	3	C	Small size
2	M/78	Claudication	0.5	4.5	2	C	Small size
3	M/80	Pain at rest <sup>a)</sup>	0.2	4	1	D	Fibrotic changes
4	F/77	Pain at rest	0.25	4.2	1	D	Small size
5	M/76	Claudication	0.44	5	2	C	Fibrotic changes
6	M/78	Claudication	0.3	4	1	D	Small size
		Claudication	0.4	4.2	1	D	Small size
7	F/77	Pain at rest	0.3	5	1	D	Fibrotic changes
8	F/75	Claudication	0.4	5.4	2	C	Small size
9	M/74	Pain at rest	0.38	4	1	D	Fibrotic changes
10	M/83	Pain at rest <sup>a)</sup>	0.35	4	1	D	Small size
11	M/77	Claudication	0.5	5	2	C	Small size
		Claudication	0.3	3.8	1	D	Small size
12	F/74	Pain at rest	0.35	5	1	D	Fibrotic changes
13	M/75	Claudication	0.5	5	2	C	Small size
14	M/76	Claudication	0.55	4	2	D	Fibrotic changes
15	F/73	Claudication	0.55	5.3	3	C	Small size
16	M/74	Claudication	0.36	4	1	D	Small size

M, male; F, female.

<sup>a)</sup>Indicates tissue loss.

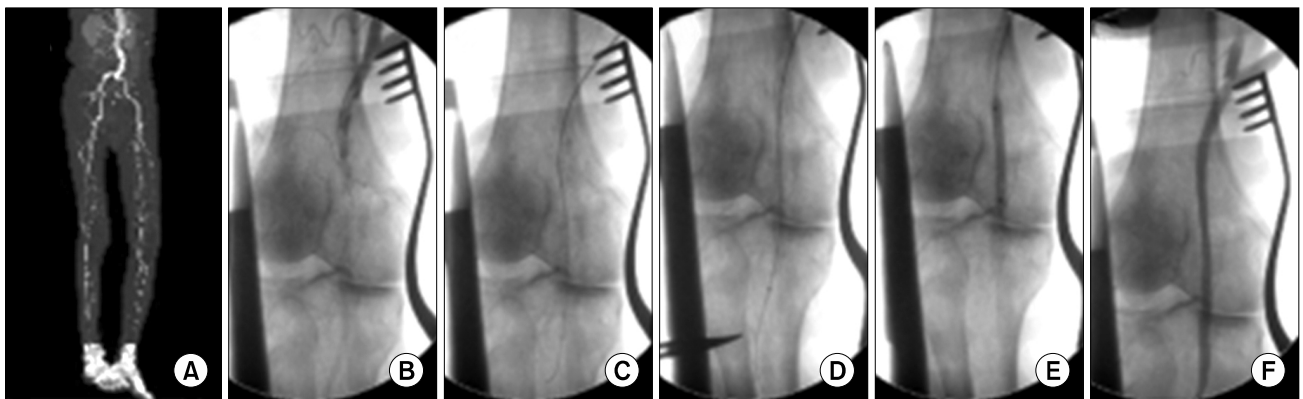
was inserted through this needle into the PTFE graft under fluoroscopic guidance. Then, a 7-Fr sheath was introduced into the PTFE graft. The diseased and calcified AK and BK popliteal arteries were cannulated with a 0.889-mm guidewire under fluoroscopic guidance through a 5-Fr diagnostic catheter (Kumpe; Cook Medical, Bloomington, IN, USA). If the diseased distal target popliteal artery was completely occluded, recanalization of the total occlusion was performed. Angioplasty was then carried out to pre-dilate before placement of the bridging stent graft. Balloon size selection was based on a visual estimate of the vessel or lesion size. A Viabahn stent graft 5 or 6 mm in diameter (5, 10, or 15 cm in length; W. L. Gore & Associates, Flagstaff, AZ, USA) was introduced over a guidewire into the distal target artery with proper landing under fluoroscopic and angiographic guidance. The bridging stent graft diameter was determined by preoperative CTA, with a mean diameter between the diameters of the distal target popliteal artery and the PTFE graft. The bridging stent graft was 10% to 15% oversized based on the luminal diameter. The Viabahn stent graft was partly deployed within the diseased popliteal artery and partly within the PTFE graft. A

balloon was used to mold the stent graft to achieve good apposition to the healthy popliteal artery wall and to the PTFE graft under fluoroscopic guidance. A completion angiogram was performed at the end of the procedure to ensure patency of the graft and the Viabahn stent with preserved distal runoff (Figs. 1, 2). The punctured distal PTFE graft was sutured by one or two 6/0 Prolene stitches. Wounds were then closed and dressed.

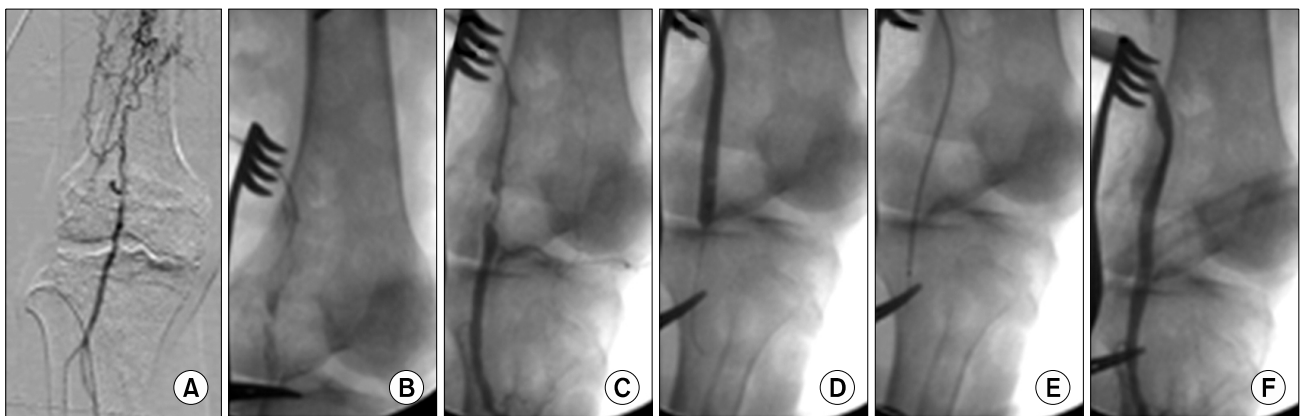
## 2) Follow-up protocol

Postoperative follow-up visits occurred at approximately 1 month, 3 months, 6 months, and 1 year after surgery. At each visit, a clinical examination was performed with color-flow duplex ultrasonography. Follow-up CTA was only carried out if noninvasive studies suggested restenosis or occlusion (positive duplex scan with a difference in ABI >0.15), or if the patient had recurrent symptoms. Patency was defined as stenosis <50% on color-flow duplex ultrasonography. The definition of 50% restenosis was based on a peak systolic velocity ratio >2.4 [11].

A symptom severity questionnaire was completed to assess the severity of patient symptoms during



**Fig. 1.** Femoral-above-knee bypass with placement of a bridging stent graft. Images from a 73-year-old man suffering from chronic critical limb ischemia. (A) Preoperative angiographic details of the above-knee popliteal artery. (B) Angiography performed by guiding the catheter through the PTFE graft shows a diffuse diseased popliteal artery after femoral-above knee bypass. (C) Recanalization of the focal occlusion and diseased popliteal artery was performed. (D) A Viabahn stent graft 5 mm in diameter was introduced over a guidewire into the distal target artery with proper landing under fluoroscopic and angiographic guidance after pre-dilatation angioplasty. (E) A balloon was used to mold the stent graft to achieve good apposition to the healthy popliteal artery wall and to the PTFE graft. (F) Final angiographic imaging after the femoral above-knee bypass with the hybrid procedure shows good patency of the graft and the Viabahn stent with preserved distal runoff. PTFE, polytetrafluoroethylene.



**Fig. 2.** A 77-year-old man with a skin wound at the below-knee bypass incision site who was treated with a femoral-above-knee bypass with placement of a bridging stent graft. (A) Computed tomography angiography shows occlusion of the right femoropopliteal artery and posterior tibial artery. (B) Angiography performed by guiding the catheter through the polytetrafluoroethylene graft shows the diffusely diseased popliteal artery after the femoral-above-knee bypass. (C) Recanalization of the diseased popliteal artery was performed. (D) Angioplasty was performed for pre-dilatation before placement of the bridging stent graft. (E) A Viabahn stent graft 5 mm in diameter was introduced over a guidewire into the distal target artery with proper landing under fluoroscopic and angiographic guidance. (F) The final angiographic imaging after the femoral-above-knee bypass with the hybrid procedure shows good patency of the graft and Viabahn stent with preserved distal runoff.

follow-up, using a scale from  $-3$  (markedly worse) to  $+3$  (resolved). The scores were divided into 4 categories: resolved (score of  $+3$ ), improved (scores of  $+1$  to  $+2$ ), no change (score of  $0$ ), and deteriorated (scores of  $-1$  to  $-3$ ) [12].

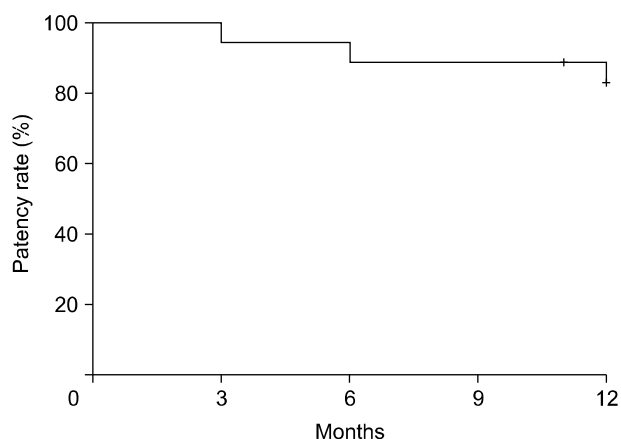
### 3) Data analysis

Measured values are reported as mean or median

with range. The patency rate was calculated using Kaplan-Meier analysis. All statistical analyses were performed using PASW SPSS ver. 18.0 (SPSS Inc., Chicago, IL, USA).

## Results

The technical failure rate was 0% for the surgical



**Fig. 3.** Kaplan-Meier estimates of primary patency after femoral-above-knee bypass procedures with placement of a bridging stent graft.

bypass grafts using this hybrid procedure. During the first year after surgery, 2 of the 18 implanted grafts became occluded within 3 months and 6 months, respectively. One occlusion was treated with thrombolysis and percutaneous transluminal angioplasty. The other failed to improve with treatment. The overall 1-year primary patency rate with bridging Viabahn grafts was 83.3% (Fig. 3). The operative mortality rate was 0%. No major perioperative ( $\leq 30$  days) complications occurred. One minor complication, perigraft seroma formation, was observed. Despite a patent graft, 1 toe amputation had to be performed. This patient had tissue loss with chronic CLI and 1 patent tibial artery. The patients' symptoms improved within 2 weeks. The mean follow-up period was  $12.6 \pm 2.8$  months. Patient outcomes are reported in Table 2.

## Discussion

Femoropopliteal bypass surgery has been used for decades as a first-line revascularization option for patients with PAOD in order to relieve their symptoms, restore their ability to walk, and avoid foot amputation. Autologous saphenous veins are generally the preferred conduit. Femoral-AK popliteal PTFE vascular grafts might yield patency results comparable to those achieved with veins; even if the outcomes are somewhat inferior afterwards, the discrepancy is not significant [13,14].

Surgical skills and endovascular alternatives are

**Table 2.** Hemodynamic and symptom changes at one year

Variable	Value
Hemodynamic changes	
Ankle-brachial index	0.8 (0.5-1.0)
Immediate symptom relief	
Resolved	7
Improved	11
Deterioration	-
Amputation	1

Values are presented as median (range) or number.

being continuously developed. Recently, VORTEC has been introduced as a hybrid technique for femoral-AK popliteal bypass procedures. With VORTEC, the Viabahn stent is inserted via direct puncture into the target artery. The stent graft is then sutured to the artery and graft [6,7]. With the ViPS technique [8], after the unsheathed distal portion of the Viabahn stent is sutured to the PTFE graft in an end-to-end fashion, the undeployed proximal portion of the Viabahn is inserted into the target artery.

Both VORTEC and ViPS techniques pose risks of distal target vascular injury, such as perforation by the guidewire, inaccurate landing of the Viabahn graft, rupture, or dissection of a distal target vessel during stent graft deployment under direct vision. Furthermore, ViPS has the potential risk of bleeding at anastomotic sites between the PTFE graft and the Viabahn stent. Unlike the VORTEC and ViPS techniques, our hybrid procedure minimizes vascular injury to the distal target and enables a more accurate landing of the Viabahn stents, because the stent is introduced over a guidewire into the distal target artery under fluoroscopic and angiographic guidance. Another advantage of our procedure is that it does not require circumferential dissection of the distal AK popliteal artery or result in distal back bleeding during anastomosis to the distal AK popliteal artery. Additionally, the distal end of the PTFE graft can be controlled using soft snares around the target artery without cross-clamping.

There was a discrepancy in diameters between the distal target popliteal artery and the PTFE graft in our procedure. To overcome this discrepancy, a bridging Viabahn stent was used. The femoropopliteal junction and popliteal artery are exposed to repetitive flexion and extension of the knee joint. Therefore, stent placement in this area can be accompanied by

limited clinical success in interventions [15,16]. A Viabahn stent graft with a mean diameter between that of the distal target popliteal artery and the PTFE graft was used, followed by ballooning of the deployed Viabahn stent.

The Viabahn graft is a stent graft originally designed for treating femoropopliteal arterial occlusive disease and arterial aneurysm. The Viabahn stent graft is a composite based on the combination of a thin expanded PTFE (ePTFE) lining and a surrounding self-expanding nitinol stent. ePTFE is a well-known synthetic material (GORE-TEX, W. L. Gore & Associates) with a long and successful record in traditional and endovascular surgery [7,8].

We were concerned about collateral circulation of the distal target popliteal artery. However, in patients with chronic long SFA occlusion and diffusely diseased distal popliteal arteries, the major collateral vessels around the diseased popliteal artery mostly arise from the deep femoral artery. Before the procedure, the major collateral vessels were evaluated on CTA. Attempts were made to preserve collateral circulation by choosing the most proximal possible landing zone under fluoroscopic and angiographic guidance.

To reduce unnecessary proximal graft puncture sites and to minimize the procedure time, angiography was performed through a distal graft with CTA evaluation for lesions and major collateral vessels. During follow-up, no complications related to excluded collateral vessels were observed.

In many patients, an autologous vein cannot be used for graft materials because there is no suitable available vein or because they are at an increased risk of wound complications or difficult vein harvesting. The 12-month follow-up period in many femoral-AK popliteal bypass studies with PTFE grafts revealed mean primary patency rates of 76.3% to 85.3% [10,13,17,18]. Other studies reported that the primary patency rate was as low as 59% to 81% in femoral-BK popliteal bypasses with PTFE grafts [9,17]. In our study, the primary patency rate at 1 year was relatively high, at 83.3%. The primary patency rate of our study was comparable to those that have been reported in studies of AK bypass procedures with PTFE grafts. This may have been due to the transluminal treatment of diffusely diseased AK and BK popliteal arteries and the use of bridging stent grafts.

Safety was assessed with respect to complications during and after the procedures. There were no major complications after femoral-AK bypass with the hybrid technique. There was one case of toe amputation at 6 months after bypass surgery with the hybrid technique. The patient had tissue loss with 1 tibial runoff vessel before the hybrid procedure and showed a patent graft after the hybrid procedure. We presumed that the cause of amputation was distal runoff, which negatively affects graft patency, and poor tibial runoff is a predictor of poor anatomic and functional outcomes [16,19,20].

Future research plans include clinical examinations, color-flow duplex ultrasonography, and calculation of the ABI every 6 months. If a noninvasive study suggests restenosis or occlusion, or if the patient has recurrent symptoms, follow-up CTA will be performed.

Two drawbacks of our procedure are the extra cost of bridging stent grafts and the long amount of time required to perform the procedures. However, the extra cost is justified by the relatively long patency of the diseased popliteal arteries compared to the patency of femoral-BK bypass with PTFE grafts. The time required for bridging stent graft placement is not excessive when the procedure is performed by experienced surgeons and interventional radiologists. The limitations of this study include a small number of patients and a short follow-up period. Therefore, an additional study with longer-term follow-up is needed.

In conclusion, despite its limitations, this study presented a safe procedure for patients with no available vein for graft material, with an acceptable patency rate, to treat long SFA occlusion with a diffusely diseased or calcified distal target popliteal artery or patients in which a BK bypass graft would be impossible. This procedure may be a clinically effective and safe alternative to femoral-BK PTFE bypass surgery.

### Conflict of interest

No potential conflicts of interest relevant to this article are reported.

### Acknowledgments

This work was supported by a Samsung Biomedical

Research Institute grant. This study was supported by a Grant of the Samsung Vein Clinic Network (Daejeon, Anyang, Cheongju, Cheonan; Fund no. KTCS04-086).

## References

1. Brewster DC, LaSalle AJ, Darling RC. *Comparison of above-knee and below-knee anastomosis in femoropopliteal bypass grafts*. Arch Surg 1981;116:1013-8.
2. Klinkert P, Post PN, Breslau PJ, van Bockel JH. *Saphenous vein versus PTFE for above-knee femoropopliteal bypass: a review of the literature*. Eur J Vasc Endovasc Surg 2004;27:357-62.
3. Kim HY, Kim JS, Kim MY, Hwang SW, Yoo BH. *Comparison of saphenous vein and PTFE grafts for above the knee femoropopliteal bypass grafting*. Korean J Thorac Cardiovasc Surg 2010;43:127-32.
4. Quinones-Baldrich WJ, Prego AA, Ucelay-Gomez R, et al. *Long-term results of infrainguinal revascularization with polytetrafluoroethylene: a ten-year experience*. J Vasc Surg 1992;16:209-17.
5. Baumann F, Do DD, Willenberg T, Baumgartner I, Diehm N. *Treatment for long-segment femoro-popliteal obstructions: initial experience with a 4-F compatible self-expanding nitinol stent and review of the literature*. J Cardiovasc Surg (Torino) 2012;53:475-80.
6. Szendro G, Greenberg G, Leytzin A, Mayzler O, Ginzburg V. *A new minimally invasive hybrid technique for femoro-above knee popliteal bypass*. Int Angiol 2011;30:522-6.
7. Greenberg G, Szendro G, Mayzler O, Ginzburg V, Leytzin A. *Use of ViaBahn open revascularisation technique for above-knee femoro-popliteal anastomosis: a technical note*. Eur J Vasc Endovasc Surg 2011;42:202-5.
8. Ferretto L, Piazza M, Bonvini S, Battocchio P, Grego F, Ricotta JJ. *ViPS (Viabahn Padova Sutureless) technique: preliminary results in the treatment of peripheral arterial disease*. Ann Vasc Surg 2012;26:34-9.
9. Albers M, Battistella VM, Romiti M, Rodrigues AA, Pereira CA. *Meta-analysis of polytetrafluoroethylene bypass grafts to infrapopliteal arteries*. J Vasc Surg 2003;37:1263-9.
10. Pereira CE, Albers M, Romiti M, Brochado-Neto FC, Pereira CA. *Meta-analysis of femoropopliteal bypass grafts for lower extremity arterial insufficiency*. J Vasc Surg 2006;44:510-7.
11. Ranke C, Rieder M, Creutzig A, Alexander K. *A nomogram of duplex ultrasound quantification of peripheral arterial stenoses: studies of the cardiovascular model and in angiography patients*. Med Klin (Munich) 1995;90:72-7.
12. Rutherford RB, Baker JD, Ernst C, et al. *Recommended standards for reports dealing with lower extremity ischemia: revised version*. J Vasc Surg 1997;26:517-38.
13. Bosiers M, Deloose K, Verbist J, et al. *Heparin-bonded expanded polytetrafluoroethylene vascular graft for femoropopliteal and femorocrural bypass grafting: 1-year results*. J Vasc Surg 2006;43:313-8.
14. Veith FJ, Gupta SK, Ascer E, et al. *Six-year prospective multicenter randomized comparison of autologous saphenous vein and expanded polytetrafluoroethylene grafts in infrainguinal arterial reconstructions*. J Vasc Surg 1986;3:104-14.
15. Goltz JP, Ritter CO, Kellersmann R, Klein D, Hahn D, Kickuth R. *Endovascular treatment of popliteal artery segments P1 and P2 in patients with critical limb ischemia: initial experience using a helical nitinol stent with increased radial force*. J Endovasc Ther 2012;19:450-6.
16. Kröger K, Santosa F, Goyen M. *Biomechanical incompatibility of popliteal stent placement*. J Endovasc Ther 2004;11:686-94.
17. Ruckert RI, Tsilimparis N, Lobenstein B, Witte J, Seip G, Storck M. *Midterm results of a precuffed expanded polytetrafluoroethylene graft for above knee femoropopliteal bypass in a multicenter study*. J Vasc Surg 2009;49:1203-9.
18. Solakovic E, Totic D, Solakovic S. *Femoro-popliteal bypass above knee with saphenous vein vs synthetic graft*. Bosn J Basic Med Sci 2008;8:367-72.
19. Davies MG, Saad WE, Peden EK, Mohiuddin IT, Naoum JJ, Lumsden AB. *Impact of runoff on superficial femoral artery endoluminal interventions for rest pain and tissue loss*. J Vasc Surg 2008;48:619-25.
20. Toursarkissian B, D'Ayala M, Stefanidis D, et al. *Angiographic scoring of vascular occlusive disease in the diabetic foot: relevance to bypass graft patency and limb salvage*. J Vasc Surg 2002;35:494-500.