

# The Effect of Alendronate on Various Graft Materials Used in Maxillary Sinus Augmentation: A Rabbit Study

Ferhat Ayranci,<sup>1\*</sup> Metin Gungormus,<sup>2</sup> Mehmet Melih Omezli,<sup>1</sup> and Betul Gundogdu<sup>3</sup>

<sup>1</sup>Department of Oral Maxillofacial Surgery, Faculty of Dentistry, Ordu University, Ordu, Turkey

<sup>2</sup>Department of Oral and Maxillofacial Surgery, Faculty of Dentistry, Gaziantep University, Gaziantep, Turkey

<sup>3</sup>Department of Pathology, Faculty of Medicine, Ataturk University, Erzurum, Turkey

\*Corresponding Author: Ferhat Ayranci, Department of Oral Maxillofacial Surgery, Faculty of Dentistry, Ordu University, 52200, Ordu, Turkey. Tel: +90-4522125005, Fax: +90-4522121289, E-mail: dfayranci@hotmail.com

Received 2015 October 3; Revised 2015 October 21; Accepted 2015 November 11.

## Abstract

**Background:** Increasing sinus pneumatization and the accompanying alveolar bone resorption complicate dental implant placement. This problem can be overcome today by raising the maxillary sinus floor with graft materials. Bisphosphonates are commonly used to accelerate the recovery of the graft materials and to prevent resorption.

**Objectives:** The purpose of this study is to investigate whether systemic administration of a bisphosphonate (alendronate) would improve new bone formation and reduce fibrous tissue formation over a 6-week follow-up in rabbits treated with two different grafting materials for maxillary sinus floor augmentation.

**Materials and Methods:** This experimental animal study was conducted at the Experimental Medical Application and Research Center at Erzurum/Turkey. Twelve New Zealand rabbits, each weighing between 2.7 and 3.3 kg, were used. Twenty-four maxillary sinus floor elevation operations were performed, two on each animal (n = 24). Each elevation was repaired with either deproteinized bovine bone (xenograft) or autogenous bone graft obtained from the iliac crest. Both groups were divided into 2 subgroups: saline-treated and alendronate-treated. All groups underwent the same surgical procedures and evaluation, and were sacrificed at the 6th postoperative week. Sinuses augmented with deproteinized bovine bone (xenograft) and autogenous bone graft were examined histopathologically and histomorphometrically.

**Results:** At 6 weeks, the bone area was significantly larger in the Xenograft-Alendronate group (33.0% ± 5.0%) than in the Xenograft-Saline group (20.8% ± 4.9%) and the bone area was significantly larger in the Autogenous-Alendronate group (43.3% ± 3.8%) than in the Autogenous-Saline group (37.5% ± 6.6%) (P = 0.001). The histomorphometric and histopathological results consistently showed that alendronate stimulated bone formation and reduced fibrous tissue formation in maxillary sinus augmentation grafts, especially in the deproteinized bovine bone group (xenograft).

**Conclusions:** Alendronate may be considered a therapeutic option for improving the bone formation process and reducing resorption in different bone grafting procedures. Further detailed studies should focus on dosage and time-dependent effects of alendronate on bone remodeling.

**Keywords:** Bisphosphonate, Alendronate, Sinus, Maxillary

## 1. Background

Osteointegrated implants are regarded as an ideal alternative for replacing missing teeth. However, the bone height from the alveolar crest to the sinus floor at the posterior maxillary region is usually insufficient due to sinus pneumatization, as well as to the lack of stability caused by maxillary bone loss at the edentulous sites required for osteointegrated implantation (1). Among the various techniques used to restore the height of the resorbed maxilla, maxillary sinus elevation is regarded as an effective method for restoring the upper jaw (2). Since the technique was first described by Tatum (3), the use of autogenous bone grafts in sinus augmentation has come the 'gold standard' because of the excellent survival of these grafts with loaded implants and the degree of functionality these grafts afford (4-6). However, donor site morbidity, infection, pain, blood loss, and increased

hospital costs have led to a search for alternative graft materials for augmentation of the maxillary sinus floor. These materials have included allografts, alloplasts, and xenografts, which all provide adequate viable bone to stabilize dental implants and promote osteointegration (7).

The recovery of the graft materials is accelerated and resorption is prevented by mixing together graft materials with different features, as well as by employing other materials that can hasten bone processing in some applications (8-11). Bisphosphonates are commonly used for these purposes (12-15), with alendronate now recognized as one of the most potent bisphosphonates in terms of inhibiting bone resorption both in vitro and in vivo. Alendronate has been used as a bone resorption inhibitor for preventing systemic bone resorption in a number of bone disorders, including osteoporosis, Paget's disease, and neoplastic bone diseases (16, 17).

## 2. Objectives

The aim of this study was to evaluate whether systemic administration of alendronate would improve new bone formation and reduce fibrous tissue formation during the 6-week follow-up after maxillary sinus floor augmentation (MSFA) in rabbits treated with two different grafting materials.

## 3. Materials and Methods

### 3.1. Experimental Model

A power analysis (PASS 2008 software, NCSS, Kaysville, UT) was performed to estimate the sample size, based on a significance level of 0.05 and power of 80 %. This study was designed as a prospective, randomized, controlled experiment. Twelve mature New Zealand white rabbits (aged 3 months, and weighing 2.7 to 3.3 kg) were obtained from the experimental research center (Erzurum, Turkey). The animals were housed individually at a temperature of  $20 \pm 1^\circ\text{C}$  under a 12-hour light-dark cycle and a constant humidity of  $50 \pm 5\%$ . The animals were given a soft diet and water ad libitum.

Twenty-four maxillary sinus floor elevation operations were performed, two on each animal. These were then repaired using two grafting materials: deproteinized bovine bone (Dexabone Otrokovice, Czech Republic) or an autogenous bone graft obtained from the animal's iliac crest. Both the deproteinized bovine bone and autogenous graft-treated groups were divided into two subgroups: a saline-treated group and an alendronate-treated group. All groups were selected by a randomized schedule using a simple random allocation strategy. The groups underwent the same surgical procedures and evaluations, and the animals were sacrificed at the 6th postoperative week. The study was approved by the institutional ethics review committee for animal research at Ataturk University (10.10.2011; AU-2011.4.1/12) and was supported by the Scientific Research Projects of Ataturk University. The "guide for the care and use of laboratory animals," as prepared by the Ethics Committee for Animal Research at Ataturk University, was followed carefully.

General anesthesia was induced in each animal using a combination of intramuscular ketamine (50 mg/kg) (Ketalar; Eczacıbaşı, Istanbul, Turkey) and xylazine hydrochloride (Rompun 2%; Bayer, Istanbul, Turkey). Next, a 5 mg/kg intramuscular induction and 0.5 ml of 1% lidocaine with epinephrine (1:100,000) were injected subcutaneously at the midline of the nasal dorsum. A midline incision, extending approximately 50 mm, was then made, and the skin and periosteum were elevated sufficiently to expose the nasal bone and the nasoincisor suture line. Two windows were outlined in the nasal bone using a round bur, and a fenestra was made with an osteotome under continuous cooling with sterile saline solution. Upon completion of the outline, a freer elevator was used to gently push the antral mucosa inward. The mucosa was elevated from the floor, lateral walls, and medial wall of the antrum, to provide a large compartment for graft placement. One sinus was filled with deproteinized bovine bone (xenograft) and the other sinus filled with autogenous

bone particles (Figure 1A). The autogenous bone graft was harvested from the iliac crest, following local anesthesia, by making a 15-mm incision over the iliac crest to expose the ilium. The corticocancellous bone graft harvested from the iliac crest was cut into small parts before these were grafted to the maxillary sinus. Sutures were then placed to close the periosteum and skin. Following surgery, the grafted maxillary sinus areas were evaluated by cone beam tomography (NewTom FP, Quantitative Radiology, Verona, Italy) (Figure 1B). All animals were administered intramuscular ceftriaxone (25 mg/kg) (Rocephin; Pfizer, New York, IL, USA) and intracutaneous carprofen (4 mg/kg) (Rimadyl; Pfizer, New York, IL, USA) postoperatively, twice a day for 3 days. Healing progressed uneventfully in all animals, and no postoperative complications were observed during the 6-week observation period. The alendronate-treated groups received 0.15 mg/kg alendronate (Sigma-Aldrich Co. LLC St. Louis, MO, USA), administered subcutaneously daily for 6 weeks. The saline-treated groups were given a daily saline solution injection for 6 weeks.

### 3.2. Preparation of Tissue

Rabbits were anesthetized intravenously with a high dose of ketamine and sacrificed 6 weeks after the operation. The maxilla was dissected and cut into smaller blocks, which included the nasal and maxillary sinus, and then fixed 4% formaldehyde solution for 48 hours at  $4^\circ\text{C}$ , and decalcified with nitric acid. The specimens were then embedded in paraffin, sliced into sections 5  $\mu\text{m}$  thick, and stained with hematoxylin-eosin.

### 3.3. Histomorphometric Analysis

Measurements were performed on decalcified specimens using a personal computer-based image analysis system (Stereo-Investigator 7.0, Microbrightfield, Colchester, VT). The system was calibrated using a slide calibrated in micrometers, and the setting remained unchanged during the analysis of all samples. Four randomly selected sections were analyzed manually from the serial sections collected from each sample. The margins of the sinus augmentation area were drawn to remain beneath the sinus membrane and to exclude the basal bone structure of the maxilla. The area within this line was recorded as the total area calculated by the software (Stereo-Investigator 7.0, Microbrightfield, Colchester, VT). Lines were subsequently drawn around the dark red areas on sections stained with hematoxylin-eosin dye and assessed as areas of new bone formation. Areas stained a paler pink than the new bone formation area were evaluated as fibrous tissue, and the entire area was determined by drawing around the entire augmentation field. All analysis was performed by the same examiner, who was blinded to the treatment rendered. The newly formed bone areas (the proportion of the area of newly formed bone to the total measured area), fibrous connective tissue area (the proportion of the area of fibrous connective tissue to the total measured area) were recorded and compared.

### 3.4. Statistical Analysis

All the data analyses were performed using the Statistical Package for Social Sciences (SPSS) Version 15.0. The Shapiro-Wilk test was used to evaluate whether data variables were normally distributed ( $P > 0.05$ ) and then normally distributed continuous data were expressed as sample size, means with standard deviation, and analyzed by two-way ANOVA. Values of  $P < 0.05$  were considered statistically significant.

## 4. Results

### 4.1. Histopathological Evaluation

Examination of histological sections from the control group of rabbits with maxillary sinuses augmented using deproteinized bovine bone (xenograft) in this 6-week study revealed comparatively less bone formation and closure of the augmentation area with a layer of fibrous tissue mimicking bone. The presence of bone was observed in very narrow areas in the region. Dense fibroblastic cells were observed in fibrous tissue (Figure 2A and B). In the alendronate-treated group, a woven bone formation that exhibited a skeletally mature structure covered a large area in the augmentation field, and low amounts of fibrous tissue formation were observed between new bone formation areas. Vessels and osteocytes with dense nuclei were noted in the regions of new bone formation (Figure 2C and D).

Histological examination of sections from subjects with maxillary sinuses augmented using autogenous bone grafts revealed intensive new bone formation in the control group, with small amounts of fibrous tissue formation observed between the new bone formation areas (Figure 3A and B). In the autogenous bone groups receiving alendronate, the formed bone had a more mature structure, bone marrow began developing, and the bone haversian system had begun to form. The osteocyte cell activity was quite low in the autogenous graft group administered alendronate (Figure 3C and D).

### 4.2. Histomorphometric Analysis

#### 4.2.1. Bone Area

At 6 weeks postoperatively, the bone area was significantly larger in the Xenograft-Alendronate group ( $33.0\% \pm 5.0\%$ ) than in the Xenograft-Saline group ( $20.8\% \pm 4.9\%$ ) and the bone area was significantly larger in the Autogenous-Alendronate group ( $43.3\% \pm 3.8\%$ ) than in the Autogenous-Saline group ( $37.5\% \pm 6.6\%$ ) ( $P = 0.001$ ) (Table 1).

#### 4.2.2. Fibrous Tissue Area

Fibrous tissue area in the Autogenous-Alendronate group ( $7.2\% \pm 1.7\%$ ) was not significantly different from that in the Autogenous-Saline group ( $7.7\% \pm 8.3\%$ ), but the fibrous tissue area in the Xenograft-Saline group ( $20.0\% \pm$

$4.7\%$ ) was significantly larger than that in the Xenograft-Alendronate group ( $8.5\% \pm 3.4\%$ ) ( $P < 0.05$ ) (Table 2).

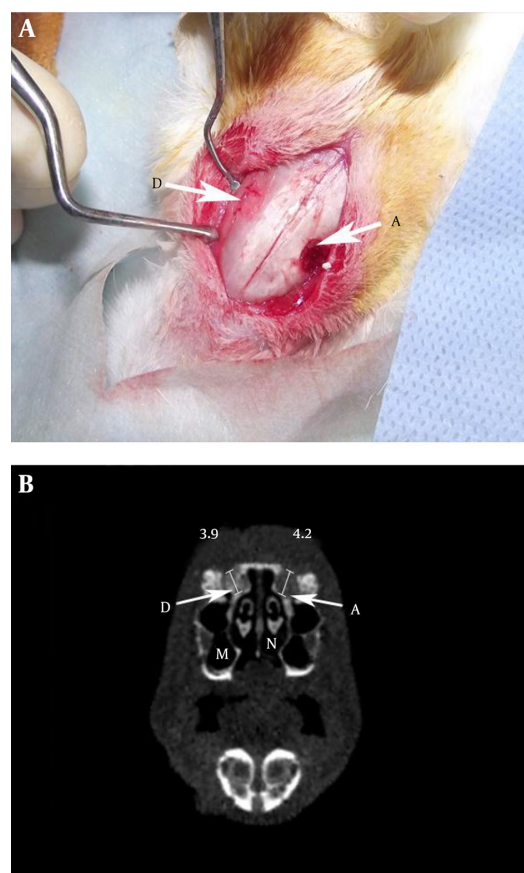
Newly formed bone in the augmented spaces was significantly greater in both alendronate-treated groups when compared to the saline-treated groups. Additionally, fibrous tissue formation was significantly less in the Xenograft-Alendronate group than in the Xenograft-Saline group. This indicated that bisphosphonates may act as bone formation stimulators and may have a potentially beneficial effect on the bone formation process.

Analysis revealed a comparatively greater new bone formation in maxillary sinus augmentations performed using autogenous bone grafts than in those using xenografts (Table 1), and this difference was statistically significant ( $P = 0.001$ ) (Table 1).

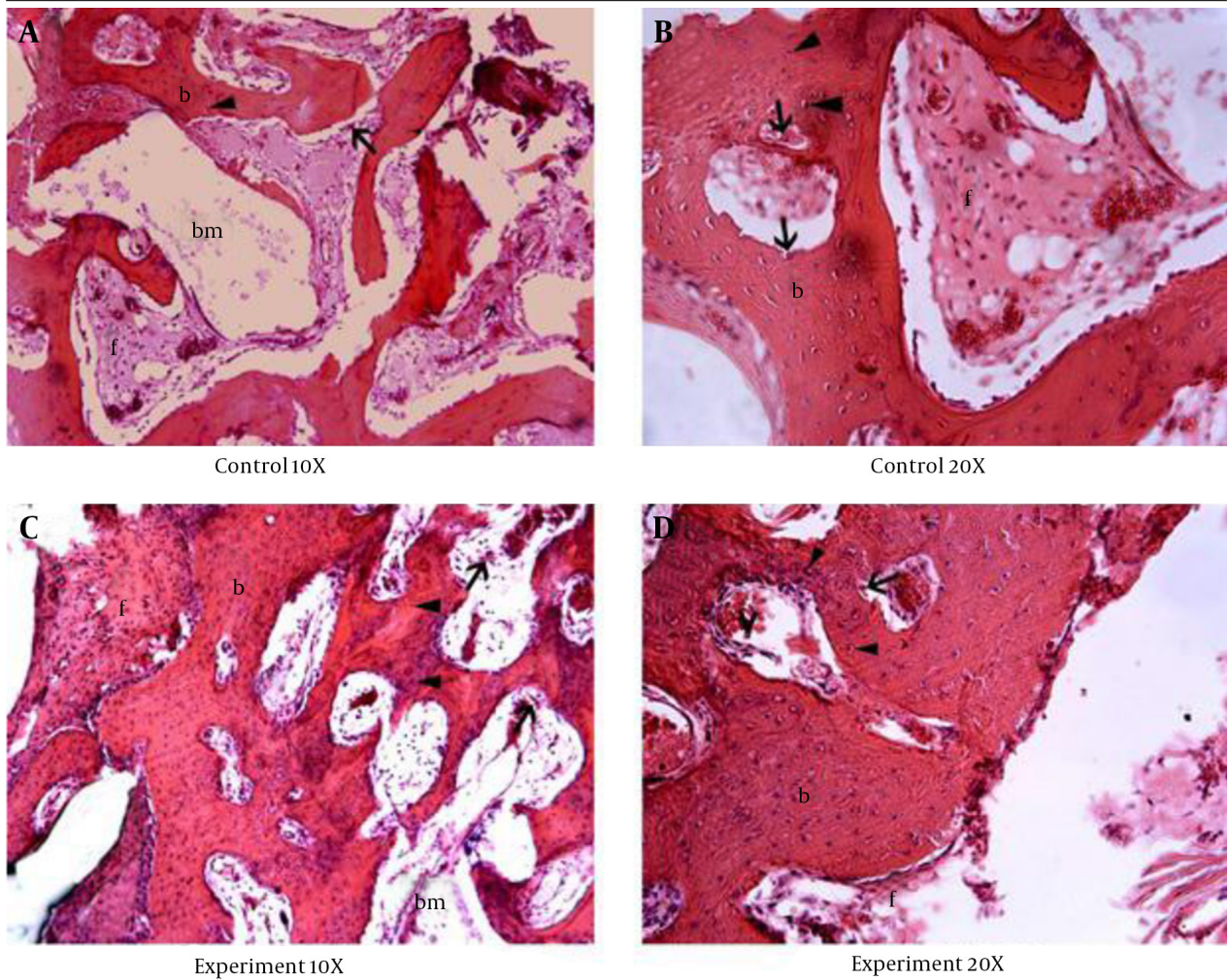
Comparatively more new bone formation was also observed in groups administered alendronate than in those without alendronate and this difference was statistically significant ( $P = 0.001$ ) (Table 1).

No statistically significant difference was determined between the Xenograft-Alendronate and Autogenous-Alendronate groups ( $P = 0.203$ ) (Table 1).

**Figure 1.** The Defect Sites Were Filled With Grafting Materials



A, Autogenous bone graft; B, Cone-beam tomographic image immediately after surgery; D, Deproteinized bovine bone (xenograft); M, Maxillary Sinus; N, Nose.



**Figure 2.** A, Control 10x; B, Control 20x; C, Alendronate 10x; D, Alendronate 20x; A - B, Illustration of new bone ossification areas for xenograft material in the control group; C - D, New bone ossification areas for xenograft material in the alendronate-treated group; (b, bone trabecular; f, fibrous tissue; bm, bone marrow cavity; d, vessel; open arrow, osteoclast cell; arrow head, osteocyte).

**Table 1.** The Results of New Bone Formation (%) for the Xenografts and Autogenous Grafts With Alendronate Application or Without (Saline Only)<sup>a,b</sup>

Alendronate (A)	Grafts (G)		P Value
	Xenograft	Autogenous	
With Saline (n = 6)	20.8 ± 4.9	37.5 ± 6.6	< 0.001
With Alendronate (n = 6)	33.0 ± 5.0	43.3 ± 3.8	< 0.001

<sup>a</sup>The interaction effect of GA was not statistically significant (P = 0.203).

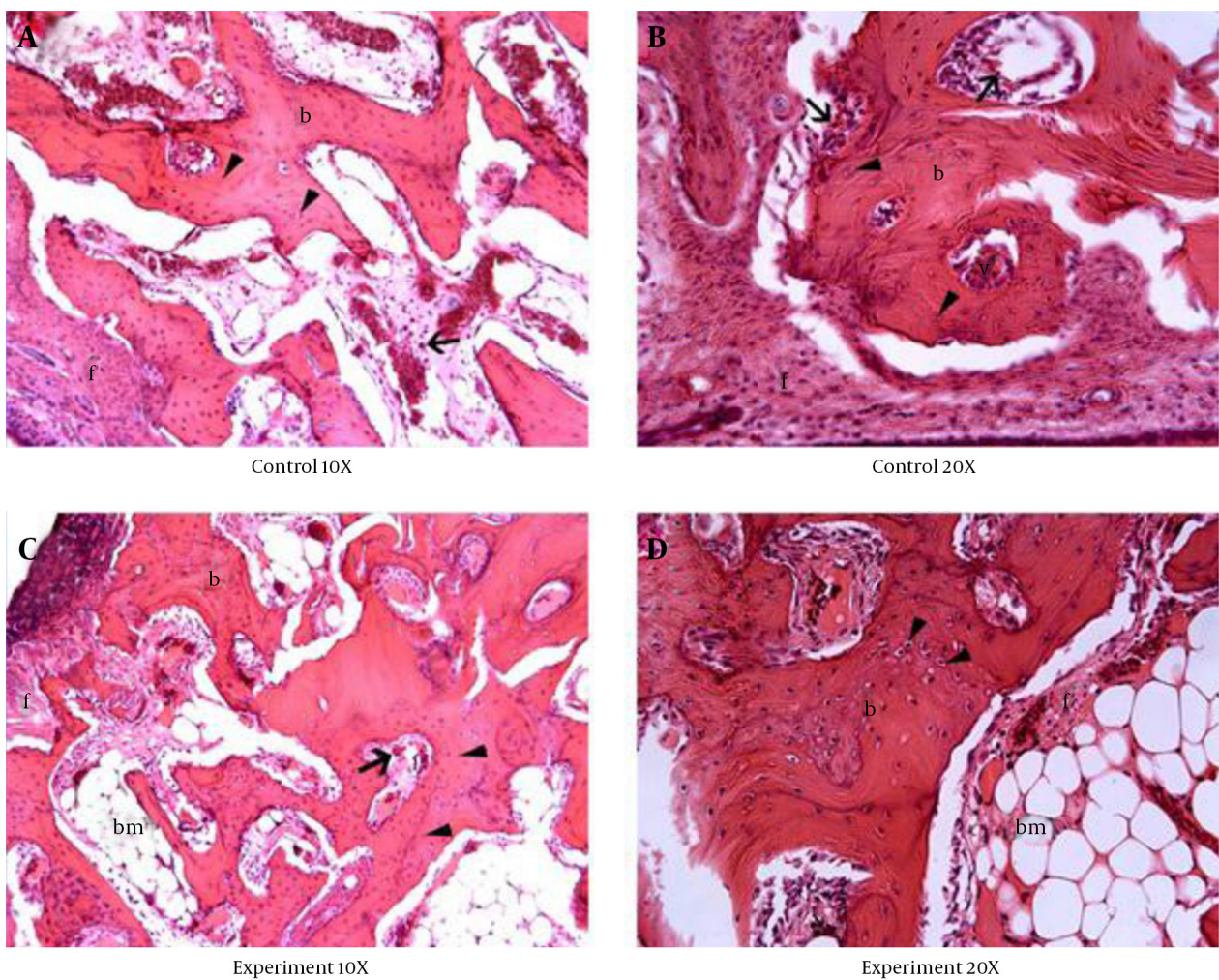
<sup>b</sup>Data are presented as (Mean ± SD).

**Table 2.** The Results of Fibrous Tissue Formation (%) for the Xenografts and Autogenous Grafts With Alendronate Application or Without (Saline Only)<sup>a,b</sup>

Alendronate (A)	Grafts (G)		P Value
	Xenograft	Autogenous	
With Saline (n = 6)	20.0 ± 4.7	7.7 ± 8.3	0.004
With Alendronate (n = 6)	8.5 ± 3.4	7.2 ± 1.7	0.010

<sup>a</sup>The interaction effect of GA was not statistically significant (P = 0.171).

<sup>b</sup>Data are presented as (Mean ± SD).



**Figure 3.** A, Control 10x; B, Control 20x; C, Alendronate 10x; D, Alendronate 20x; A - B, Illustration of new bone ossification areas for autogenous bone grafts in the control group; C - D, New bone ossification areas for autogenous bone grafts in the alendronate-treated group; (b, bone trabecular; f, fibrous tissue; bm, bone marrow cavity; open arrow, osteoclast cell; d, vessel; arrow head, osteocyte).

## 5. Discussion

Dental implant placement in patients who are edentulous in the posterior part of the upper jaw can be problematic for various reasons. Increasing sinus pneumatization and the accompanying alveolar bone resorption complicate dental implant placement. Today, this problem can be overcome by raising the maxillary sinus floor with graft materials.

Tatum (3), in the early 1970s, first described the raising of the maxillary sinus floor using graft materials and this procedure came into wide use following a clinical study in 1980 by Boyne and James (18), who showed that the maxillary sinus is a suitable area for bone formation. Various single or double-stage techniques have been described to date for dental implant placement with the MSFA procedure (19, 20). The success of MSFA with graft materials for implant placement has increased in the last

10 years, so that this procedure now occupies an important place in the prosthetic treatment of individuals with atrophic maxillas.

The literature shows a variety of graft materials now being used for MSFA, including autogenous bone, allografts, xenografts, alloplastic grafts, and combinations of various materials (21-23). Autogenous bone is regarded as the gold standard graft material because of its osteoinductive, osteoconductive, and osteogenic effects (24). However, the sole use of autogenous bone as a graft material in sinus augmentation results in intense remodeling properties that lead to greater resorption (25). Additional disadvantages include discomfort in the graft donor region, bone resorption, increased costs due to the second donor region surgical procedure, and the limited amounts of autogenous material available. These limita-

tions have encouraged a search for alternative graft materials (26).

Xenografts can be safely used as a graft material because of their osteoconductive properties and biocompatibilities (24, 26). This graft material is also used in maxillary sinus augmentation because it has its own morphological structure and has lost its antigenic properties due to complete extraction of proteins deriving from its inorganic structure (27). However, no consensus has been reached regarding the ideal graft material for use in MSFA.

The present study investigated the efficacy of different graft types in cases of insufficient bone elevation between the maxillary sinus floor and alveolar bone and explored the histomorphometric effect of alendronate sodium trihydrate on grafts after MSFA. Various studies have reported that the rabbit sinus is a suitable model for maxillary sinus augmentation, since both the ostia opening onto the nasal cavity and the air changes inside the nasal cavity are similar to those in humans (28, 29).

Asai et al. (28) reported that air pressure inside the maxillary sinus applied constant pressure on the sinus membrane and the graft material inside the sinus, and that the effect of this pressure was to induce changes in the healing and structure of the augmented bone. Karabuda et al. (30) used several different graft materials and performed a histological assessment of graft healing after 6 months. They reported high levels of resorption, which left only 5% - 10% of the graft materials, and an ossification level of 70% - 75% in the remaining part. Jensen et al. (31) reported that corticocancellous autogenous bone grafts failed to withstand the air pressure inside the sinuses and lost their density and elevation in the first few weeks after augmentation. In a similar study, Johansson et al. (32) reported a graft resorption level as high as 47% after 6 - 7 months in sinus augmentation procedures using autogenous grafts. Serra et al. (26) reported a 14% volume loss after 6 months in xenografts, while 49.5% of the autogenous bone graft was resorbed. They described this as an obstacle to the long-term success of maxillary sinus augmentation.

The combined use of graft materials with different properties and the addition of materials that accelerate bone formation have been explored as methods to hasten healing and prevent graft resorption in bone grafting procedures in the face and jaw regions (29, 33). Bisphosphonates are widely used in this context (34-38). The mechanism involved with bisphosphonates is unclear, but they are used in the treatment of various bone and calcium metabolism disorders that result in bone destruction, particularly osteoporosis (39). The effects of bisphosphonates on bone healing have been investigated previously, and one reported effect is that bisphosphonates increase callus resistance (15, 40, 41). A study of distraction osteogenesis (DO) in a rabbit model by Little et al. (42), who investigated the effect of 3 ml/kg pamidronate on bone formation, documented a significant in-

crease in bone production in both histological and radiological terms. Kucuk et al. (43) investigated the effects of bisphosphonates in DO and reported significantly better bone formation in experimental subjects administered bisphosphonates. Tekin et al. (44) reported a significant acceleration of bone healing during DO in rabbits administered systematic alendronate for 3 days postoperatively.

Yaffe et al. (13) investigated the effect of alendronate on bone formation in rats following bone marrow placement into the ectopic region, and reported that daily injection of alendronate at 500 µg/kg increased bone mass by 70%. Aspenberg and Astrand (35), who investigated the effect of alendronate on the resorption of allogenic graft material, reported that the graft remained healthy in a high-dose alendronate group (205 µg/kg per day) and that greater bone formation was detected around the graft trabeculae.

Altundal and Gursoy (34) harvested autogenous grafts 3 mm in diameter and 2 mm high from rat femurs and placed these into defects of the same dimensions established 5 mm away from the recipient area. The formation of new lamellae and woven bone was significantly higher in the group injected with 250 µg/kg alendronate than in the other groups.

In agreement with the findings from these previous studies, we concluded that alendronate administered subcutaneously at a daily dose of 150 µg/kg significantly increased new bone formation in our subjects with bone autogenous grafts and xenografts when compared to the control groups treated with saline only. This effect of alendronate may be associated with inhibition of osteoclastic activity during the healing of the graft material. The data from the present study indicated a greater level of bone healing and lower fibrous tissue formation in both the autogenous graft and xenograft groups when alendronate was administered, compared to the control groups ( $P < 0.05$ ).

No consensus has been reached in the literature concerning the mode of use, dosage, and duration of application of alendronate. The alendronate dose used in this study was therefore determined as a mean value, and one close to that used in the treatment of osteoporosis in humans (39, 45).

Some other studies have reported findings that are incompatible with the positive effects observed in alendronate on bone formation. In one in vitro study, Garcia-Moreno et al. (46) reported that alendronate had no effect on the lifespan, growth, or mineral deposition capacities of osteoblasts. Kaynak et al. (47) found no difference in terms of osteoblastic activity between alendronate and control groups following mucoperiosteal flap surgery. They suggested that the increase in osteoblastic activity was an indirect result of an inhibition of the bone resorption mechanism. Altundal and Guvener (12) investigated the effect of alendronate on osteoblastic activity and bone resorption following tooth extraction and reported that alendronate reduced osteoblastic activity but did not sig-

nificantly prevent alveolar bone loss.

The present study was limited by its small sample size and by the relatively short postoperative time before animal sacrifice, which was established based upon consideration of the risks related to systemic alendronate treatment. However, the results provide evidence that alendronate therapy, given systemically, increased new bone formation in both xenograft and autogenous graft groups in a maxillary sinus augmentation model. We suggest that further studies focusing on local applications of alendronate at different dosages might be more successful in improving bone graft healing.

### 5.1. Conclusion

The histomorphometric and histopathological results of this study consistently showed that alendronate stimulated bone formation and reduced fibrous tissue formation, especially in the xenograft group, following maxillary sinus augmentation grafts. Alendronate may therefore be considered as a potential therapeutic option for improving bone formation processes and for reducing resorption following different bone grafting procedures. Further detailed studies should now focus on the dosage- and time-dependent effects of alendronate on bone remodeling.

### Acknowledgments

The authors thank Dr. Serkan Ozkan for preparing the figures.

### Footnotes

**Authors' Contribution:** Study concept and design: Metin Gungormus, Ferhat Ayranci; analysis and interpretation of data: Ferhat Ayranci, Betul Gundogdu and Metin Gungormus; drafting of the manuscript: Mehmet Melih Omezli, Ferhat Ayranci; critical revision of the manuscript for important intellectual content: Mehmet Melih Omezli, Ferhat Ayranci; statistical analysis: Ferhat Ayranci.

**Funding/Support:** This research was supported by a grant from the scientific research council of Ataturk University (BAP 2007/133).

### References

1. Wada K, Niimi A, Watanabe K, Sawai T, Ueda M. Maxillary sinus floor augmentation in rabbits: a comparative histologic-histomorphometric study between rhBMP-2 and autogenous bone. *Int J Periodontics Restorative Dent*. 2001;**21**(3):252-63. [PubMed: 11490402]
2. Wanschitz F, Figl M, Wagner A, Rolf E. Measurement of volume changes after sinus floor augmentation with a phycogenic hydroxyapatite. *Int J Oral Maxillofac Implants*. 2006;**21**(3):433-8. [PubMed: 16796287]
3. Tatum Jr H. Maxillary and sinus implant reconstructions. *Dent Clin North Am*. 1986;**30**(2):207-29. [PubMed: 3516738]
4. Joshi A. An investigation of post-operative morbidity following chin graft surgery. *Br Dent J*. 2004;**196**(4):215-8. doi: 10.1038/sj.bdj.4810987. [PubMed: 15039731]
5. Nkenke E, Radespiel-Troger M, Wiltfang J, Schultze-Mosgau S, Winkler G, Neukam FW. Morbidity of harvesting of retro-

- molar bone grafts: a prospective study. *Clin Oral Implants Res*. 2002;**13**(5):514-21. [PubMed: 12453129]
6. Raghoobar GM, Louwerse C, Kalk WW, Vissink A. Morbidity of chin bone harvesting. *Clin Oral Implants Res*. 2001;**12**(5):503-7. [PubMed: 11564111]
7. Browaeys H, Bouvry P, De Bruyn H. A literature review on bio-materials in sinus augmentation procedures. *Clin Implant Dent Relat Res*. 2007;**9**(3):166-77. doi: 10.1111/j.1708-8208.2007.00050.x. [PubMed: 17716261]
8. Boyne PJ, Lilly LC, Marx RE, Moy PK, Nevins M, Spagnoli DB, et al. De novo bone induction by recombinant human bone morphogenetic protein-2 (rhBMP-2) in maxillary sinus floor augmentation. *J Oral Maxillofac Surg*. 2005;**63**(12):1693-707. doi: 10.1016/j.joms.2005.08.018. [PubMed: 16297689]
9. Gruber RM, Ludwig A, Merten HA, Achilles M, Poehling S, Schliephake H. Sinus floor augmentation with recombinant human growth and differentiation factor-5 (rhGDF-5): a histological and histomorphometric study in the Goettingen miniature pig. *Clin Oral Implants Res*. 2008;**19**(5):522-9. doi: 10.1111/j.1600-0501.2007.01494.x. [PubMed: 18371105]
10. Gruber RM, Ludwig A, Merten HA, Pippig S, Kramer FJ, Schliephake H. Sinus floor augmentation with recombinant human growth and differentiation factor-5 (rhGDF-5): a pilot study in the Goettingen miniature pig comparing autogenous bone and rhGDF-5. *Clin Oral Implants Res*. 2009;**20**(2):175-82. doi: 10.1111/j.1600-0501.2008.01628.x. [PubMed: 19077151]
11. Roldan JC, Jepsen S, Schmidt C, Knuppel H, Rueger DC, Acil Y, et al. Sinus floor augmentation with simultaneous placement of dental implants in the presence of platelet-rich plasma or recombinant human bone morphogenetic protein-7. *Clin Oral Implants Res*. 2004;**15**(6):716-23. doi: 10.1111/j.1600-0501.2004.01070.x. [PubMed: 15533133]
12. Altundal H, Guvener O. The effect of alendronate on resorption of the alveolar bone following tooth extraction. *Int J Oral Maxillofac Surg*. 2004;**33**(3):286-93. doi: 10.1006/ijom.2002.0472. [PubMed: 15287313]
13. Yaffe A, Kollerman R, Bahar H, Binderman I. The influence of alendronate on bone formation and resorption in a rat ectopic bone development model. *J Periodontol*. 2003;**74**(1):44-50. doi: 10.1902/jop.2003.74.1.44. [PubMed: 12593595]
14. Lui PP, Lee YW, Mok TY, Cheuk YC. Local administration of alendronate reduced peri-tunnel bone loss and promoted graft-bone tunnel healing with minimal systemic effect on bone in contralateral knee. *J Orthop Res*. 2013;**31**(12):1897-906. doi: 10.1002/jor.22442. [PubMed: 23877997]
15. Moller B, Wiltfang J, Acil Y, Gierloff M, Lippross S, Terheyden H. Prevention of the surface resorption of bone grafts by topical application of bisphosphonate on different carrier materials. *Clin Oral Investig*. 2014;**18**(9):2203-11. doi: 10.1007/s00784-014-1202-9. [PubMed: 24562699]
16. Aspenberg P, Astrand J. Bone allografts pretreated with a bisphosphonate are not resorbed. *Acta Orthop Scand*. 2002;**73**(1):20-3. doi: 10.1080/000164702317281350. [PubMed: 11928906]
17. Coxon FP, Thompson K, Rogers MJ. Recent advances in understanding the mechanism of action of bisphosphonates. *Curr Opin Pharmacol*. 2006;**6**(3):307-12. doi: 10.1016/j.coph.2006.03.005. [PubMed: 16650801]
18. Boyne PJ, James RA. Grafting of the maxillary sinus floor with autogenous marrow and bone. *J Oral Surg*. 1980;**38**(8):613-6. [PubMed: 6993637]
19. Nystrom E, Kahnberg KE, Gunne J. Bone grafts and Branemark implants in the treatment of the severely resorbed maxilla: a 2-year longitudinal study. *Int J Oral Maxillofac Implants*. 1993;**8**(1):45-53. [PubMed: 8468086]
20. Raghoobar GM, Brouwer TJ, Reintsema H, Van Oort RP. Augmentation of the maxillary sinus floor with autogenous bone for the placement of endosseous implants: a preliminary report. *J Oral Maxillofac Surg*. 1993;**51**(11):1198-203. [PubMed: 8229391]
21. Del Fabbro M, Testori T, Francetti L, Weinstein R. Systematic review of survival rates for implants placed in the grafted maxillary sinus. *Int J Periodontics Restorative Dent*. 2004;**24**(6):565-77. [PubMed: 15626319]

22. Wallace SS, Froum SJ. Effect of maxillary sinus augmentation on the survival of endosseous dental implants. A systematic review. *Ann Periodontol*. 2003;**8**(1):328-43. doi: 10.1902/annals.2003.8.1.328. [PubMed: 14971260]
23. Wheeler SL. Sinus augmentation for dental implants: the use of alloplastic materials. *J Oral Maxillofac Surg*. 1997;**55**(11):1287-93. [PubMed: 9371121]
24. Galindo-Moreno P, Moreno-Riestra I, Avila G, Padiar-Molina M, Paya JA, Wang HL, et al. Effect of anorganic bovine bone to autogenous cortical bone ratio upon bone remodeling patterns following maxillary sinus augmentation. *Clin Oral Implants Res*. 2011;**22**(8):857-64. doi: 10.1111/j.1600-0501.2010.02073.x. [PubMed: 21244500]
25. Schlegel KA, Fichtner G, Schultze-Mosgau S, Wiltfang J. Histologic findings in sinus augmentation with autogenous bone chips versus a bovine bone substitute. *Int J Oral Maxillofac Implants*. 2003;**18**(1):53-8. [PubMed: 12608669]
26. Serra e Silva FM, de Albergaria-Barbosa R, Mazzonetto R. Clinical evaluation of association of bovine organic osseous matrix and bovine bone morphogenetic protein versus autogenous bone graft in sinus floor augmentation. *J Oral Maxillofac Surg*. 2006;**64**(6):931-5. doi: 10.1016/j.joms.2006.02.026. [PubMed: 16713808]
27. Wetzel AC, Stich H, Caffesse RG. Bone apposition onto oral implants in the sinus area filled with different grafting materials. A histological study in beagle dogs. *Clin Oral Implants Res*. 1995;**6**(3):155-63. [PubMed: 7578791]
28. Asai S, Shimizu Y, Ooya K. Maxillary sinus augmentation model in rabbits: effect of occluded nasal ostium on new bone formation. *Clin Oral Implants Res*. 2002;**13**(4):405-9. [PubMed: 12175378]
29. Butterfield KJ, Bennett J, Gronowicz G, Adams D. Effect of platelet-rich plasma with autogenous bone graft for maxillary sinus augmentation in a rabbit model. *J Oral Maxillofac Surg*. 2005;**63**(3):370-6. doi: 10.1016/j.joms.2004.07.017. [PubMed: 15742289]
30. Karabuda C, Ozdemir O, Tosun T, Anil A, Olgac V. Histological and clinical evaluation of 3 different grafting materials for sinus lifting procedure based on 8 cases. *J Periodontol*. 2001;**72**(10):1436-42. doi: 10.1902/jop.2001.72.10.1436. [PubMed: 11699487]
31. Jensen OT, Shulman LB, Block MS, Iacono VJ. Report of the Sinus Consensus Conference of 1996. *Int J Oral Maxillofac Implants*. 1998;**13** Suppl:11-45. [PubMed: 9715571]
32. Johansson B, Grepe A, Wannfors K, Hirsch JM. A clinical study of changes in the volume of bone grafts in the atrophic maxilla. *Dentomaxillofac Radiol*. 2001;**30**(3):157-61. doi: 10.1038/sj/dmfr/4600601. [PubMed: 11420628]
33. Galindo-Moreno P, Avila G, Fernandez-Barbero JE, Aguilar M, Sanchez-Fernandez E, Cutando A, et al. Evaluation of sinus floor elevation using a composite bone graft mixture. *Clin Oral Implants Res*. 2007;**18**(3):376-82. doi: 10.1111/j.1600-0501.2007.01337.x. [PubMed: 17355356]
34. Altundal H, Gursoy B. The influence of alendronate on bone formation after autogenous free bone grafting in rats. *Oral Surg Oral Med Oral Pathol Oral Radiol Endod*. 2005;**99**(3):285-91. doi: 10.1016/j.tripleo.2004.05.022. [PubMed: 15716833]
35. Astrand J, Aspenberg P. Systemic alendronate prevents resorption of necrotic bone during revascularization. A bone chamber study in rats. *BMC Musculoskelet Disord*. 2002;**3**:19. [PubMed: 12165099]
36. Astrand J, Harding AK, Aspenberg P, Tagil M. Systemic zoledronate treatment both prevents resorption of allograft bone and increases the retention of new formed bone during revascularization and remodelling. A bone chamber study in rats. *BMC Musculoskelet Disord*. 2006;**7**:63. doi: 10.1186/1471-2474-7-63. [PubMed: 16889666]
37. De Sarkar A, Singhvi N, Shetty JN, Ramakrishna T, Shetye O, Islam M, et al. The Local Effect of Alendronate with Intra-alveolar Collagen Sponges on Post Extraction Alveolar Ridge Resorption: A Clinical Trial. *J Maxillofac Oral Surg*. 2015;**14**(2):344-56. doi: 10.1007/s12663-014-0633-9. [PubMed: 26028857]
38. Toker H, Ozdemir H, Ozer H, Eren K. Alendronate enhances osseous healing in a rat calvarial defect model. *Arch Oral Biol*. 2012;**57**(11):1545-50. doi: 10.1016/j.archoralbio.2012.06.013. [PubMed: 22795567]
39. Rodan GA, Reszka AA. Osteoporosis and bisphosphonates. *J Bone Joint Surg Am*. 2003;**85-A** Suppl 3:8-12. [PubMed: 12925603]
40. Seebach C, Kurth A, Marzi I. [The influence of bisphosphonates on fracture healing]. *Orthopade*. 2007;**36**(2):136-40. doi: 10.1007/s00132-006-1036-5. [PubMed: 17242960]
41. Mathijssen NM, Hannink G, Pilot P, Schreurs BW, Bloem RM, Buma P. Impregnation of bone chips with alendronate and cefazolin, combined with demineralized bone matrix: a bone chamber study in goats. *BMC Musculoskelet Disord*. 2012;**13**:44. doi: 10.1186/1471-2474-13-44. [PubMed: 22443362]
42. Little DG, Cornell MS, Briody J, Cowell CT, Arbuckle S, Cooke-Yarborough CM. Intravenous pamidronate reduces osteoporosis and improves formation of the regenerate during distraction osteogenesis. A study in immature rabbits. *J Bone Joint Surg Br*. 2001;**83**(7):1069-74. [PubMed: 11603525]
43. Kucuk D, Ay S, Kara MI, Avunduk MC, Gumus C. Comparison of local and systemic alendronate on distraction osteogenesis. *Int J Oral Maxillofac Surg*. 2011;**40**(12):1395-400. doi: 10.1016/j.ijom.2011.08.004. [PubMed: 21945486]
44. Tekin U, Tuz HH, Onder E, Ozkaynak O, Korkusuz P. Effects of alendronate on rate of distraction in rabbit mandibles. *J Oral Maxillofac Surg*. 2008;**66**(10):2042-9. doi: 10.1016/j.joms.2008.06.023. [PubMed: 18848100]
45. Jamal SA, Bauer DC, Ensrud KE, Cauley JA, Hochberg M, Ishani A, et al. Alendronate treatment in women with normal to severely impaired renal function: an analysis of the fracture intervention trial. *J Bone Miner Res*. 2007;**22**(4):503-8. doi: 10.1359/jbmr.070112. [PubMed: 17243862]
46. Garcia-Moreno C, Serrano S, Nacher M, Farre M, Diez A, Marinoso ML, et al. Effect of alendronate on cultured normal human osteoblasts. *Bone*. 1998;**22**(3):233-9. [PubMed: 9580147]
47. Kaynak D, Meffert R, Gunhan M, Gunhan O, Ozkaya O. A histopathological investigation on the effects of the bisphosphonate alendronate on resorptive phase following mucoperiosteal flap surgery in the mandible of rats. *J Periodontol*. 2000;**71**(5):790-6. doi: 10.1902/jop.2000.71.5.790. [PubMed: 10872961]