

[ CASE REPORT ]

## Gemcitabine, Dexamethasone, and Cisplatin Regimen as an Effective Salvage Therapy for High-grade B-cell Lymphoma with *MYC* and *BCL2* and/or *BCL6* Rearrangements

Masaki Mitobe<sup>1</sup>, Keisuke Kawamoto<sup>1</sup>, Takaharu Suzuki<sup>1</sup>, Maiko Kiryu<sup>1</sup>, Suguru Tamura<sup>1</sup>, Ayako Nanba<sup>1</sup>, Tatsuya Suwabe<sup>1</sup>, Tomoyuki Tanaka<sup>1</sup>, Kyoko Fuse<sup>1</sup>, Yasuhiko Shibasaki<sup>1</sup>, Masayoshi Masuko<sup>1</sup>, Hiroaki Miyoshi<sup>2</sup>, Koichi Ohshima<sup>2</sup>, Hirohito Sone<sup>1</sup> and Jun Takizawa<sup>1</sup>

### Abstract:

A 61-year-old woman exhibited right inguinal lymphadenopathy and right lower limb edema approximately 1 month prior to hospitalization. She was diagnosed with high grade B-cell lymphoma, and a lymph node biopsy and fluorescence *in situ* hybridization indicated *MYC*, *BCL2*, and *BCL6* rearrangements (triple-hit lymphoma). She had progressive disease that was CD20-negative after two courses of rituximab, cyclophosphamide, doxorubicin, vincristine, methotrexate/ifosfamide, etoposide, high-dose cytarabine (R-CODOX-M/IVAC) therapy. Subsequent etoposide, prednisolone, vincristine, cyclophosphamide, doxorubicin (EPOCH) therapy was not effective. However, after two cycles of gemcitabine, dexamethasone, and cisplatin (GDP) therapy, she achieved a complete response and was able to undergo autologous peripheral blood stem cell transplantation. GDP therapy may be effective as salvage therapy for chemotherapy-resistant triple-hit lymphoma.

**Key words:** GDP, high-grade B-cell lymphoma (HGBL) with *MYC* and *BCL2* and/or *BCL6* rearrangements, triple-hit lymphoma

(Intern Med 58: 575-580, 2019)

(DOI: 10.2169/internalmedicine.1686-18)

### Introduction

High-grade B-cell lymphoma (HGBL) with *MYC* and *BCL2* and/or *BCL6* rearrangements (double-hit/triple-hit lymphoma) was established as an independent entity in the group of aggressive B-cell lymphomas in the recent World Health Organization classification (4th revised edition) (1). Although intensive chemotherapies, such as dose-adjusted (DA) etoposide, prednisolone, vincristine, cyclophosphamide, doxorubicin, and rituximab (EPOCH-R), have been reported as effective treatments for double-hit/triple-hit lymphoma, no standard of treatment has been established (2).

Rituximab, cyclophosphamide, doxorubicin, vincristine, and prednisolone (R-CHOP therapy) is administered as a standard chemotherapy for newly diagnosed diffuse large B-cell lymphoma (DLBCL); however, many studies have reported that DLBCL patients with genetic abnormalities, such as *MYC* and/or *BCL2* rearrangements, show R-CHOP resistance and a poor prognosis (3-6). Furthermore, even in patients in whom autologous peripheral blood transplantation or allogeneic transplantation have been performed after salvage chemotherapy, double-hit/triple-hit lymphomas have an extremely poor prognosis, with no established salvage chemotherapy (1, 2, 7).

High-dose chemotherapy with autologous hematopoietic stem cell transplantation (HDC/AHSCT) is recommended

<sup>1</sup>Department of Hematology, Endocrinology and Metabolism, Faculty of Medicine, Niigata University, Japan and <sup>2</sup>Department of Pathology, School of Medicine, Kurume University, Japan

Received: June 13, 2018; Accepted: July 22, 2018; Advance Publication by J-STAGE: September 12, 2018

Correspondence to Dr. Keisuke Kawamoto, kawakeis@med.niigata-u.ac.jp

for patients under 65 years of age with relapsed/refractory DLBCL if salvage chemotherapies are effective [complete response (CR) or partial response] (8, 9). However, there has been no evidence supporting treatments other than HDC/AHSCT for refractory or relapsed DLBCL (10). Recently, several chemotherapy regimens, including dexamethasone, cisplatin, and cytarabine (9, 11); methylprednisolone, etoposide, cytarabine, and cisplatin (12); ifosfamide, carboplatin, and etoposide (ICE) (13); cyclophosphamide, cytarabine, dexamethasone, and etoposide (14); DA-EPOCH (15); ifosfamide, mitoxantrone, and etoposide (16); and gemcitabine, dexamethasone, and cisplatin (GDP) (17), with or without rituxamib, have been reported as effective salvage therapies. However, it is unclear which salvage chemotherapy is superior in which patients. Few chemotherapy regimens can achieve a CR prior to HSCT and obtain sufficient numbers of CD34-positive cells in peripheral blood stem cell harvest (PBSCH). GDP; carmustine, etoposide, cytarabine, and melphalan; and ICE regimens have been reported as appropriate regimens for PBSCH (18).

We herein report a case of relapsed/refractory triple-hit lymphoma in which GDP therapy was effective salvage chemotherapy as a bridge to autologous peripheral blood stem cell transplantation (PBSCT).

## Case Report

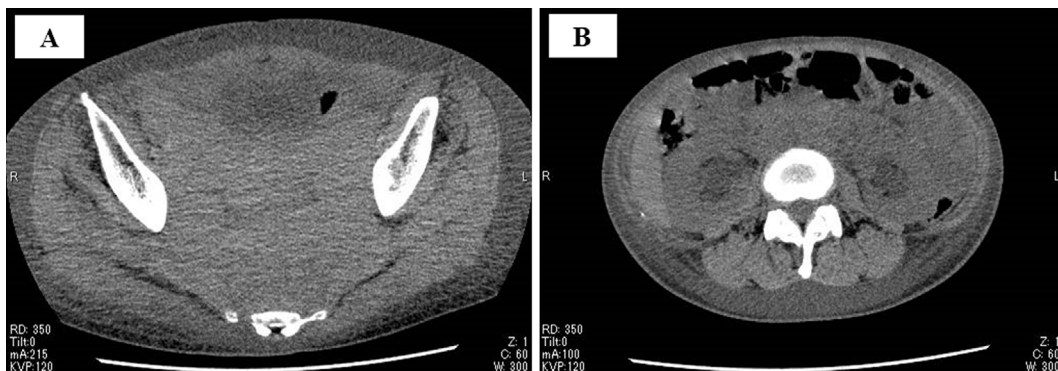
A 61-year-old Japanese woman visited her doctor because of right inguinal lymphadenopathy and right lower limb edema that appeared approximately 1 month prior to hospitalization. The edema worsened, and multiple skin masses appeared. Laboratory data showed the elevation of lactate dehydrogenase (1,030 IU/L). Computed tomography (CT) revealed a bulky mass in the retroperitoneum in addition to the skin masses. Malignant lymphoma was suspected, and she was referred to our department. Due to the rapid growth of the tumor, she was hospitalized immediately.

She was diagnosed with DLBCL by a skin biopsy on the first hospital day. The results of immunohistochemistry are shown in Table 1. CT showed the presence of a bulky mass in the pelvic cavity (maximum diameter 16 cm) and bilateral hydronephrosis (Fig. 1). Immediately, ureteral stenting was performed, and R-CHOP was subsequently performed on the third hospital day. A bone marrow examination showed infiltration of lymphoma cells, and a fluorescence *in situ* hybridization analysis (5'/'3' *MYC* probe split signal, 5'/'3' *BCL2* probe split signal, and 5'/'3' *BCL6* probe split signal) proved *MYC*, *BCL2*, and *BCL6* rearrangements (Fig. 2). Based on these results, the diagnosis was HGBL with *MYC* and *BCL2* and/or *BCL6* rearrangements (clinical stage: IVAX, International prognostic index: high risk).

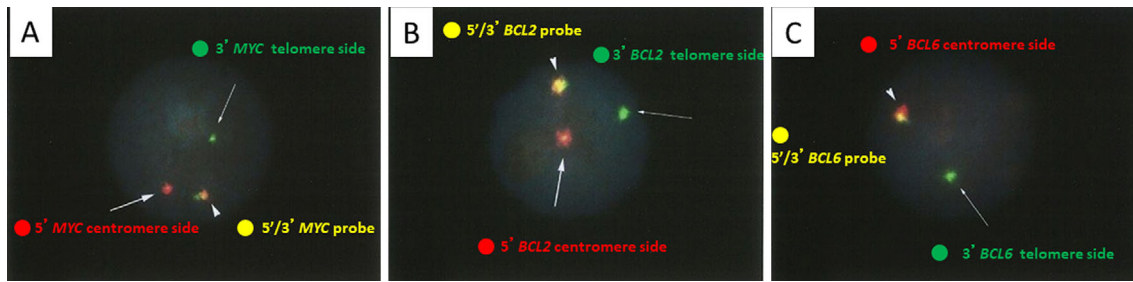
Because HGBL with *MYC* and *BCL2* and/or *BCL6* rearrangements has been reported to show significantly more central nervous system infiltration than DLBCL without *MYC* rearrangement (19), we started rituximab, cyclophosphamide, doxorubicin, vincristine, and methotrexate/ifosfamide, etoposide, and high-dose cytarabine (R-CODOX-M/IVAC) as the first-line therapy on the 12th hospital day. CR was confirmed by CT and a bone marrow biopsy at the end of one cycle of R-CODOX-M/IVAC. In order to perform PBSCT after 2 cycles of R-IVAC, we started granulocyte-colony-stimulating factor (G-CSF; 600 µg/day) for 4 days starting on the 116th hospital day (at the end of the second cycle of R-IVAC) and performed PBSCH. We collected a to-

**Table 1.** Immunophenotype at the First Diagnosis and at Relapse.

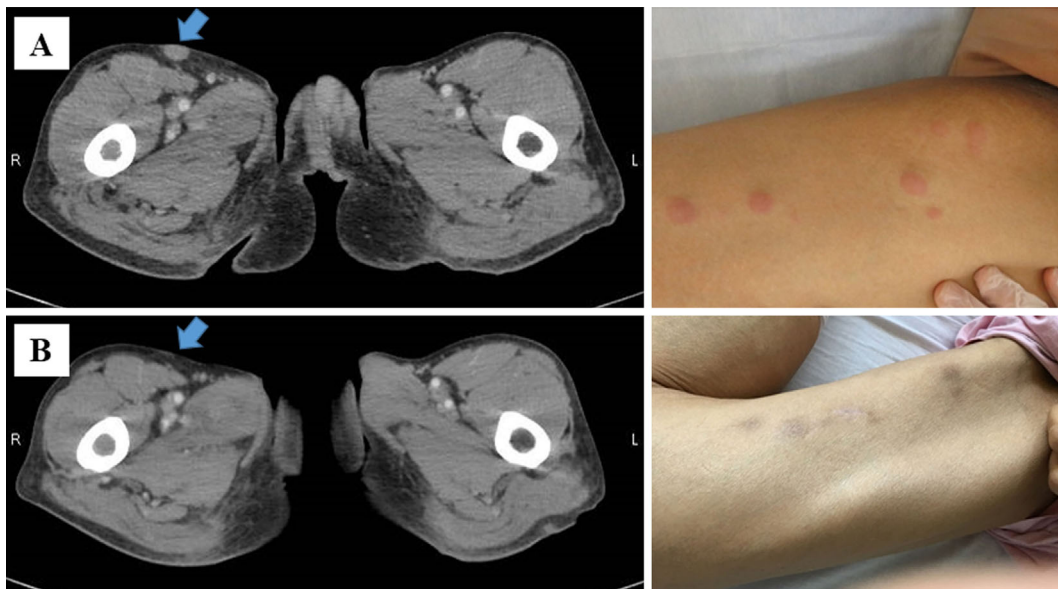
| phenotype       | at first diagnosis | at relapse     |
|-----------------|--------------------|----------------|
| CD20            | positive           | negative       |
| CD79a           | positive           | positive       |
| CD10            | positive           | positive       |
| BCL2            | positive           | positive       |
| BCL6            | positive (40-45%)  | negative (5%)  |
| MUM1            | negative           | negative       |
| MYC             | positive (90%)     | positive (90%) |
| Ki67 positivity | >90%               | >90%           |



**Figure 1.** Systemic computed tomography (CT) images at the first day of hospitalization. Systemic CT showed (A) the presence of a bulky mass in the pelvic cavity (maximum diameter 16 cm) and (B) bilateral hydronephrosis due to tumor growth.



**Figure 2.** The results of a fluorescence *in situ* hybridization analysis. A bone marrow examination showed infiltration of lymphoma cells. A fluorescence *in situ* hybridization (FISH) analysis [(A) 5'/3' *MYC* probe split signal, (B) 5'/3' *BCL2* probe split signal, and (C) 5'/3' *BCL6* probe split signal] revealed *MYC*, *BCL2*, and *BCL6* rearrangements.



**Figure 3.** Computed tomography (CT) images and skin images at recurrence after rituximab, cyclophosphamide, doxorubicin, vincristine, and methotrexate/ifosfamide, etoposide, and high-dose cytarabine (R-CODOX-M/IVAC) therapy and at remission after gemcitabine, dexamethasone, and cisplatin (GDP) therapy. (A) Multiple skin lesions appeared after R-CODOX-M/IVAC therapy. (B) A complete response was confirmed by CT after two cycles of GDP therapy.

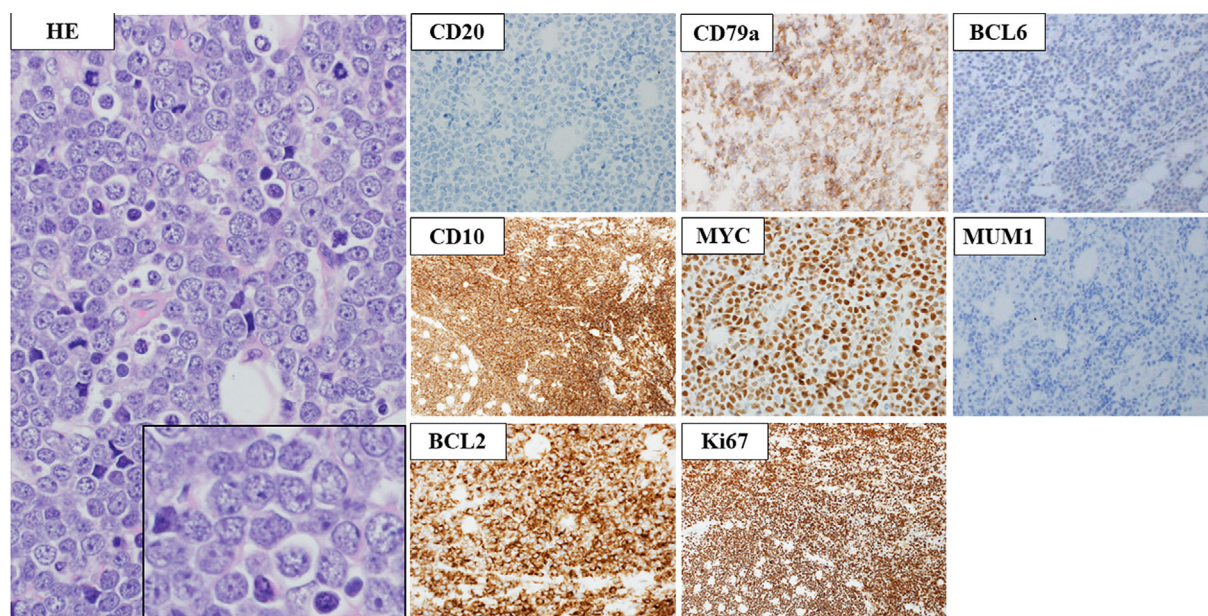
tal of  $0.59 \times 10^6$  CD34-positive cells/kg (Table 2).

On the 124th hospital day, left femoral skin lesions appeared (Fig. 3A). A skin biopsy confirmed relapse of HGBL with *MYC* and *BCL2* and/or *BCL6* rearrangements (Fig. 4). The lesions were negative for CD20 and BCL6 (Table 1). On the 128th hospital day, EPOCH therapy was started as a salvage chemotherapy. At the end of one cycle of EPOCH (starting dose level), the diameter of the skin lesions had increased. The treatment effect was judged to be progressive disease. EPOCH therapy was discontinued because of grade 3 peripheral neuropathy due to vincristine.

From the 147th hospital day, we started GDP therapy as a second salvage regimen. CR was confirmed by CT and a bone marrow biopsy at the end of two cycles of GDP (Fig. 3B). From the 208th hospital day (3 cycles of GDP at day 20), we started G-CSF (600  $\mu\text{g}/\text{day}$ ) for 5 days and performed PBSCH on the 4th and 5th days. A total of  $0.65 \times 10^6$

CD34-positive cells/kg were obtained (Table 2). We also confirmed CR by CT and a bone marrow biopsy immediately prior to PBSCH. Because the patient was a poor mobilizer, we started G-CSF (600  $\mu\text{g}/\text{day}$ ) for 7 days and performed PBSCH on the 5th, 6th, and 7th days, in combination with plerixafor. A total of  $3.23 \times 10^6$  CD34-positive cells/kg were obtained (Table 2). Subsequently, we performed autologous PBSCT with carboplatin, etoposide, and cyclophosphamide. For autologous PBSCT, we used only the third harvest. Although we investigated the presence of immunoglobulin heavy chain rearrangement by polymerase chain reaction in the graft cells, we could not prove monoclonality. On the 282nd hospitalization day, we performed autologous PBSCT with ranimustine, carboplatin, etoposide, and cyclophosphamide therapy and confirmed engraftment on the 296th day. However, CT on the 320th day revealed recurrence of a mass in the right femoral region.





**Figure 4.** Pathological image of a skin biopsy at the recurrence after R-CODOX-M/IVAC therapy. The proliferation of lymphoma cells was diffusely observed in the skin tissue. According to the immunohistochemistry, lymphoma cells were negative for CD3, CD20, BCL6, and MUM-1 and positive for CD79a, CD10, BCL2, and MYC. The Ki67-positive rate was approximately 99%.

**Table 2.** CD34-positive Cells in Peripheral Blood Stem Cell Harvests.

| Harvest number | Harvest regimen      | Total mononuclear cells (/kg) | Total CD34-positive cells (/kg) |
|----------------|----------------------|-------------------------------|---------------------------------|
| 1              | R-CODOX-M/IVAC+G-CSF | 12.0×10 <sup>8</sup>          | 0.59×10 <sup>6</sup>            |
| 2              | GDP+G-CSF            | 6.9×10 <sup>8</sup>           | 0.65×10 <sup>6</sup>            |
| 3              | G-CSF+Plerixafor     | 26.3×10 <sup>8</sup>          | 3.23×10 <sup>6</sup>            |

R-CODOX-M/IVAC: rituximab, cyclophosphamide, doxorubicin, vincristine, methotrexate/ifosfamide, etoposide, high-dose cytarabine, G-CSF: granulocyte-colony-stimulating factor, GDP: gemcitabine, dexamethasone, cisplatin

Although radiation therapy and dexamethasone, etoposide, ifosfamide, and carboplatin were administered, she ultimately died from progressive disease on the 366th day.

## Discussion

In the present case, we achieved CR by GDP as a salvage chemotherapy for HGBL with *MYC* and *BCL2* and/or *BCL6* rearrangements (triple-hit lymphoma) and performed autologous PBSCT.

Autologous PBSCT followed by intensive chemotherapy is often needed to cure HGBL with *MYC* and *BCL2* and/or *BCL6* rearrangements, as these tumors are frequently chemotherapy-resistant (20). Although there is no salvage regimen established for relapsed/refractory HGBL with *MYC* and *BCL2* and/or *BCL6* rearrangements, (R)-CODOX-M/IVAC; DA-EPOCH-(R); and cyclophosphamide, doxorubicin, vincristine, dexamethasone, methotrexate, and cytarabine have been reported as effective salvage regimens (21, 22). However, there is no prospective cohort study examining these treatments in a large number of patients. In the future, an effective salvage regimen that serves as a bridge to autologous PBSCT and can be safely admin-

istered is needed to improve the overall survival.

We selected GDP for our patient for several reasons. First, GDP has been reported to be an effective salvage regimen for relapsed/refractory DLBCL (23). GDP was found to be effective even in cases showing resistance to various salvage treatments. Second, GDP has been reported to have relatively few side effects and be well tolerated (23-25). In the present case, three courses of GDP therapy were performed. Although the patient suffered side effects, including grade 3 neutropenia, grade 3 anemia, and grade 3 thrombocytopenia, no nonhematologic toxicity was observed. Third, the GDP regimen has been reported to obtain more CD34-positive cells for autologous PBSCT than other regimens (18). For these reasons, GDP therapy is considered to be effective for double/triple-hit lymphoma; therefore, we chose the GDP regimen because neither gemcitabine nor platinum-based therapies had been previously administered in our patient. Although we were unable to collect enough cells for PBSCT with G-CSF alone after GDP therapy, a sufficient amount of CD34-positive cells were able to be collected by combination of plerixafor and G-CSF. In this case, EPOCH therapy was started after R-CODOX-M/IVAC; however, autologous PBSCT following several cycles of GDP therapy might be

effective as the treatment of choice for salvage therapy.

In our case, the expression of BCL6 and CD20 were decreased in the tumor at the time of recurrence, as shown in Table 1. The decrease in the BCL6 expression at the time of recurrence might suggest the presence of genetic abnormalities in the promoter region. However, there are no reports on the BCL6 expression at the time of recurrence of triple-hit lymphoma. The reduction in the CD20 expression in relapsed DLBCL has been reported to be caused by rituximab (26). Since a decrease in the CD20 expression suggests that rituximab is ineffective, such cases are expected to show a poor prognosis. However, the genetic background of the CD20 expression reduction is also unknown. Differences in the protein expression in lesions at the first diagnosis and recurrence have not been well studied in a large cohort. Investigating such differences in the future may be very important for treating relapsed and/or refractory cases.

There are no previous reports showing that GDP therapy is an effective salvage chemotherapy for HGBL with *MYC* and *BCL2* and/or *BCL6* rearrangements. However, the present case demonstrated the effectiveness of this therapy for achieving CR. Further studies and more cases will be needed to verify the efficacy and safety of GDP for HGBL with *MYC* and *BCL2* and/or *BCL6* rearrangements.

**The authors state that they have no Conflict of Interest (COI).**

#### Acknowledgement

The authors thank Etsuko Tamaki and Hiromi Ito for the measurement of CD34 positive cell count.

#### References

- Swerdlow SH, Campo E, Pileri SA, et al. The 2016 revision of the World Health Organization classification of lymphoid neoplasms. *Blood* **127**: 2375-2390, 2016.
- Staton AD, Cohen JB. A clinician's approach to double-hit lymphoma: identification, evaluation, and management. *J Oncol Pract* **12**: 232-238, 2016.
- Johnson NA, Savage KJ, Ludkovski O, et al. Lymphomas with concurrent BCL2 and MYC translocations: the critical factors associated with survival. *Blood* **114**: 2273-2279, 2009.
- Savage KJ, Johnson NA, Ben-Neriah S, et al. MYC gene rearrangements are associated with a poor prognosis in diffuse large B-cell lymphoma patients treated with R-CHOP chemotherapy. *Blood* **114**: 3533-3537, 2009.
- Kawamoto K, Miyoshi H, Yoshida N, et al. MYC translocation and/or BCL 2 protein expression are associated with poor prognosis in diffuse large B-cell lymphoma. *Cancer Sci* **107**: 853-861, 2016.
- Tomita N, Tokunaka M, Nakamura N, et al. Clinicopathological features of lymphoma/leukemia patients carrying both BCL2 and MYC translocations. *Haematologica* **94**: 935-943, 2009.
- Chen AI, Leonard JT, Okada CY, et al. Outcomes of DA-EPOCH-R induction plus autologous transplant consolidation for double hit lymphoma. *Leuk Lymphoma* 1-6, 2017.
- Philip T, Guglielmi C, Hagenbeek A, et al. Autologous bone marrow transplantation as compared with salvage chemotherapy in relapses of chemotherapy-sensitive non-Hodgkin's lymphoma. *N Engl J Med* **333**: 1540-1545, 1995.
- Gisselbrecht C, Glass B, Mounier N, et al. Salvage regimens with autologous transplantation for relapsed large B-cell lymphoma in the rituximab era. *J Clin Oncol* **28**: 4184-4190, 2010.
- Friedberg JW. Relapsed/refractory diffuse large B-cell lymphoma. *Hematology / the Education Program of the American Society of Hematology American Society of Hematology Education Program* **2011**: 498-505, 2011.
- Mey UJ, Orloff KS, Flieger D, et al. Dexamethasone, high-dose cytarabine, and cisplatin in combination with rituximab as salvage treatment for patients with relapsed or refractory aggressive non-Hodgkin's lymphoma. *Cancer Invest* **24**: 593-600, 2006.
- Martin A, Caballero MD; Grupo Espanol de Linfomas/Trasplante Autologo de Medula O. R-ESHAP as salvage therapy for patients with relapsed or refractory diffuse large B-cell lymphoma: influence of prior autologous stem-cell transplantation on outcome. *Haematologica* **94**: 744, 2009.
- Kewalramani T, Zelenetz AD, Nimer SD, et al. Rituximab and ICE as second-line therapy before autologous stem cell transplantation for relapsed or primary refractory diffuse large B-cell lymphoma. *Blood* **103**: 3684-3688, 2004.
- Oki Y, Ogura M, Kato H, et al. Phase II study of a salvage regimen using cyclophosphamide, high-dose cytarabine, dexamethasone, etoposide, and rituximab in patients with relapsed or refractory B-cell non-Hodgkin's lymphoma. *Cancer Sci* **99**: 179-184, 2008.
- Jermann M, Jost LM, Taverna C, et al. Rituximab-EPOCH, an effective salvage therapy for relapsed, refractory or transformed B-cell lymphomas: results of a phase II study. *Ann Oncol* **15**: 511-516, 2004.
- Rodriguez MA, Cabanillas FC, Hagemeister FB, et al. A phase II trial of mesna/ifosfamide, mitoxantrone and etoposide for refractory lymphomas. *Ann Oncol* **6**: 609-611, 1995.
- Crump M, Baetz T, Couban S, et al. Gemcitabine, dexamethasone, and cisplatin in patients with recurrent or refractory aggressive histology B-cell non-Hodgkin lymphoma: a Phase II study by the National Cancer Institute of Canada Clinical Trials Group (NCIC-CTG). *Cancer* **101**: 1835-1842, 2004.
- Kuruvilla J, Keating A, Crump M. How I treat relapsed and refractory Hodgkin lymphoma. *Blood* **117**: 4208-4217, 2011.
- Rosenthal A, Younes A. High grade B-cell lymphoma with rearrangements of MYC and BCL2 and/or BCL6: Double hit and triple hit lymphomas and double expressing lymphoma. *Blood Rev* **31**: 37-42, 2017.
- Petrich AM, Gandhi M, Jovanovic B, et al. Impact of induction regimen and stem cell transplantation on outcomes in double-hit lymphoma: a multicenter retrospective analysis. *Blood* **124**: 2354-2361, 2014.
- Oki Y, Noorani M, Lin P, et al. Double hit lymphoma: the MD Anderson Cancer Center clinical experience. *Br J Haematol* **166**: 891-901, 2014.
- Sun H, Savage KJ, Karsan A, et al. Outcome of patients with non-Hodgkin lymphomas with concurrent MYC and BCL2 rearrangements treated with CODOX-M/IVAC with rituximab followed by hematopoietic stem cell transplantation. *Clin Lymphoma Myeloma Leuk* **15**: 341-348, 2015.
- Moccia AA, Hitz F, Hoskins P, et al. Gemcitabine, dexamethasone, and cisplatin (GDP) is an effective and well-tolerated salvage therapy for relapsed/refractory diffuse large B-cell lymphoma and Hodgkin lymphoma. *Leuk Lymphoma* **58**: 324-332, 2017.
- Wang JJ, Dong M, He XH, et al. GDP (gemcitabine, dexamethasone, and cisplatin) is highly effective and well-tolerated for newly diagnosed stage IV and relapsed/refractory extranodal natural killer/T-cell lymphoma, Nasal Type. *Medicine* **95**: e2787, 2016.
- Ramzi M, Rezvani A, Dehghani M. GDP versus ESHAP regimen in relapsed and/or refractory Hodgkin lymphoma: a comparison study. *Int J Hematol Oncol Stem Cell Res* **9**: 10-14, 2015.
- Miyoshi H, Arakawa F, Sato K, et al. Comparison of CD20 ex-

pression in B-cell lymphoma between newly diagnosed, untreated cases and those after rituximab treatment. *Cancer Sci* **103**: 1567-1573, 2012.

The Internal Medicine is an Open Access journal distributed under the Creative Commons Attribution-NonCommercial-NoDerivatives 4.0 International License. To view the details of this license, please visit (<https://creativecommons.org/licenses/by-nc-nd/4.0/>).

---

© 2019 The Japanese Society of Internal Medicine  
*Intern Med* 58: 575-580, 2019