



## Research Brief

# Single center experience of transcatheter closure of mitral and aortic Paravalvular leaks using the new rechristened rectangular Amplatzer PVL plug



Pramod Sagar, Sreeja Pavithran, Monica Rajendran, Kothandam Sivakumar\*

Department of Pediatric Cardiology, Institute of Cardio Vascular Diseases, Madras Medical Mission, 4A Dr. J.J. Nagar, Mogappair, Chennai, 600037, India

## ARTICLE INFO

## Article history:

Received 16 November 2021

Received in revised form

13 March 2022

Accepted 9 April 2022

Available online 12 April 2022

## Keywords:

Crescentic shape

Oblong plug

Periprosthetic leak

## ABSTRACT

Amplatzer Paravalvular leak (PVL) plug is rectangular in shape, that might suit closure of crescentic PVL. Among 79 transcatheter PVL closures from a single center, a subgroup of 16 patients who received Amplatzer PVL plugs were analyzed. All procedures were successful, as the plug auto-oriented to the leak, without mechanical leaflet interference, though needing additional 31 devices. Two patients needed an elective re-intervention. NYHA class improved from III-IV before procedure to less than II after procedure. Complications were not directly related to the Amplatzer PVL plug. The rectangular shape for crescentic leaks, auto-orientation and non-interference with mechanical leaflets were good attributes.

© 2022 Cardiological Society of India. Published by Elsevier, a division of RELX India, Pvt. Ltd. This is an open access article under the CC BY-NC-ND license (<http://creativecommons.org/licenses/by-nc-nd/4.0/>).

## 1. Introduction

When significant Paravalvular leaks (PVL) complicate 3–5% of valve replacement, transcatheter closure is emerging as a treatment.<sup>1,2</sup> Without a dedicated occluder, different ‘off-label’ plugs are tried.<sup>3</sup> AVPIII (Amplatzer vascular plug III, Abbott Medical, Plymouth, MN) designed for vascular closure is peculiarly suited for crescentic PVL and rechristened as Amplatzer PVL plug.<sup>4–7</sup> We present our experience with this plug in this retrospective analysis.

## 2. Methods

Among 79 transcatheter PVL closures in 8 years, 16 patients received Amplatzer PVL plug. Crescentic shape on three-dimensional echocardiogram was the inclusion criterion. Exclusion criteria was (i) long-axis dimension of PVL exceeding 12 mm; (ii) non-availability of appropriate sized plug in shelf. Institutional review board and ethical committee approved this retrospective review. Multidisciplinary Heart Team approved transcatheter closure after informed consent from patient.

Coumadin switch to heparin preceded the intervention. In crescentic leaks, Amplatzer PVL plug varying from 8–4 mm to 14–

5 mm was preferred.<sup>8,9</sup> The plug was chosen 1.2–2 times larger than the PVL and the device auto-oriented to the leak (Fig. 1). The small 2 mm rim avoided mechanical interference (Fig. 2). AVP II or AVP IV plugs were used for residual leaks.

Data collection included symptom class, cardiac rhythm, surgical details, type of prosthesis, ventricular ejection fraction, grade of pulmonary hypertension, blood tests for hemolysis and renal function. Location, number, shape, size and severity of PVL were assessed on three-dimensional echocardiography. Compliant balloon sizing was sometimes used.<sup>10</sup> Residual PVL and valve function were evaluated on echocardiography on 1,6 and 12-month follow-up.

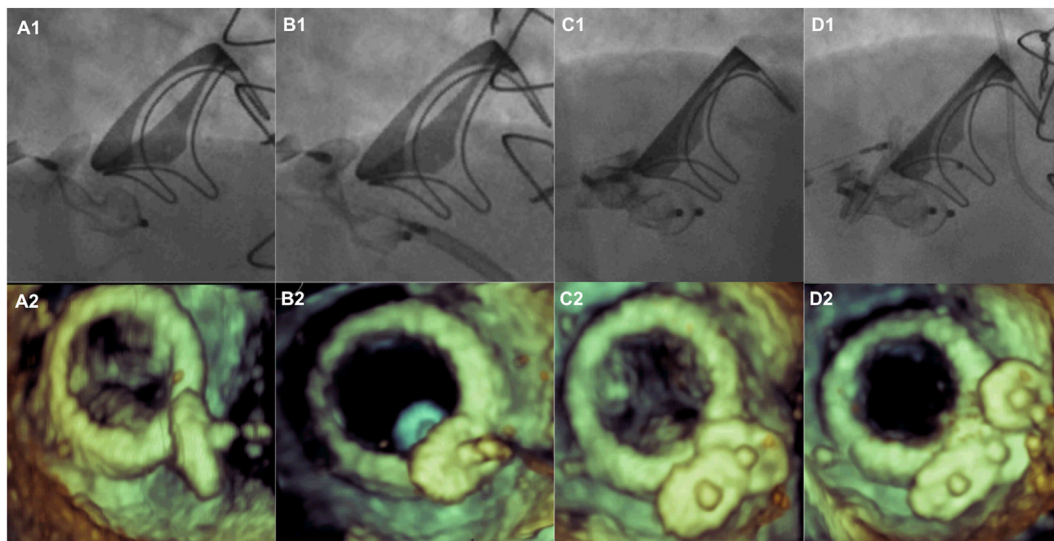
## 3. Results

Sixteen patients aged 18–78 years, who received a total of 18 AVP III devices formed the study cohort (Supplemental Table) 8 plugs were implanted in aortic and 10 plugs in mitral position. Two patients received two adjacent Amplatzer PVL plugs in mitral position. 31 additional plugs were used.

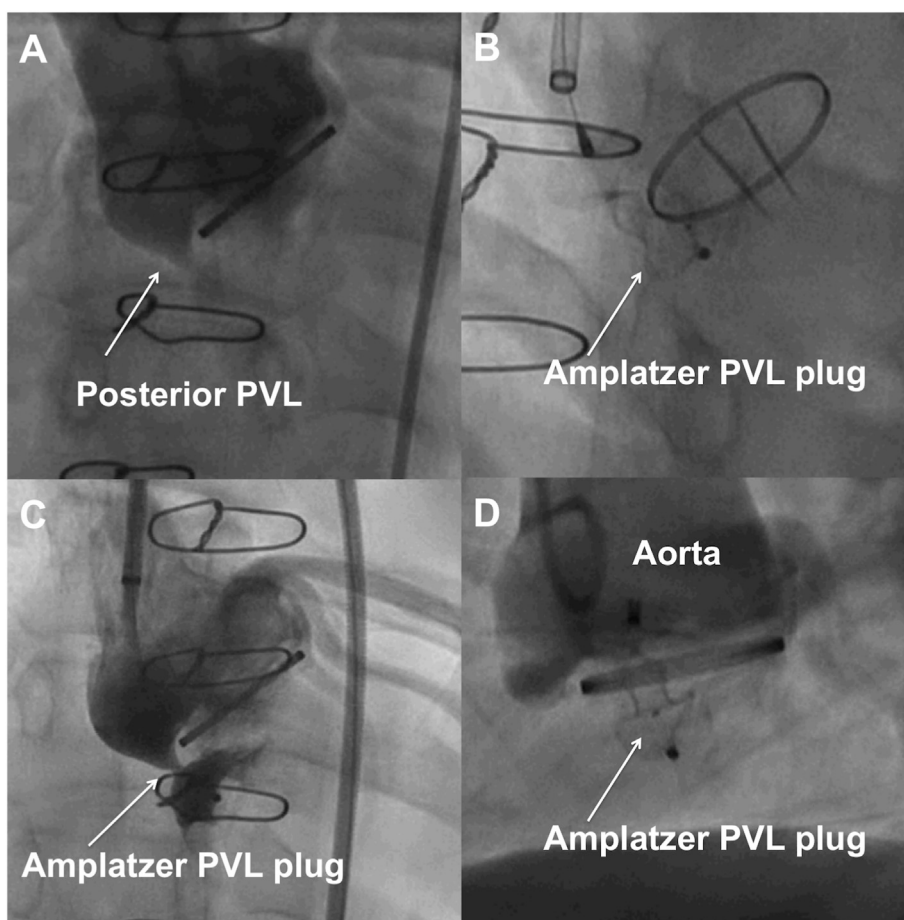
Among the 8 aortic PVL that included four mechanical valves, comorbidities included atrial fibrillation in one, pulmonary hypertension in two, ventricular dysfunction in 7 and chronic renal failure in one patient. Two patients had more than one preceding surgery. NYHA functional class was IV in three patients, III in two patients and II in the rest. The regurgitation reduced from grade IV

\* Corresponding author.

E-mail address: [drkumarsiva@hotmail.com](mailto:drkumarsiva@hotmail.com) (K. Sivakumar).



**Fig. 1. Auto-orientation of Amplatzer PVL plug.** Mitral paravalvular leak closed with a first Amplatzer PVL plug under combined fluoroscopic (A1) and three-dimensional echocardiographic (A2) guidance. The plug auto-orientes to the long axis (B1,B2) of the circumferential crescentic leak. A second rectangular Amplatzer PVL plug (C1,C2) and a circular plug (D1,D2) added later complete the transcatheter closure.



**Fig. 2. Single Paravalvular leak closed by a single PVL plug.** A single posterior Paravalvular leak around a mechanical aortic prosthesis(A) closed with an Amplatzer PVL plug(B) after a check angiogram through the delivery sheath(C) and finally released(D). The platinum marker indicating the short-axis of the plug shows its auto-orientation.

in five and grade III in three patients to grade I in two and none in rest. At a median follow up of 24 months ranging 12–72 months, all

survivors were in NYHA class I or II. There was one late death from cerebrovascular accident. Additional intervention included closure

of residual sinus of valsalva aneurysm in one patient.<sup>11</sup>(-Supplemental Fig. 1).

Among 8 mitral PVL that included six mechanical valves, 10 Amplatzer PVL plugs were used. Comorbidities included atrial fibrillation in 5, pulmonary hypertension in 7, kidney disease, subdural hemorrhage, complete heart block and hypoalbuminemia in one each. Six patients had more than one previous surgeries. Six patients had active hemolysis though none had a past history of endocarditis. All patients had transseptal access; four patients additionally had percutaneous apical access. All patients needed more than one plug. Seven patients had NYHA class III or more, improved to class II after the closure. There was mild residual leak in five patients. At a median follow up of 30 months ranging 3–54 months, two patients required a planned reintervention for the residual PVL.

Seventeen of the 18 plugs used were larger than 10 mm. Fourteen patients needed additional plugs. Even though there was no direct mechanical interference from PVL plug, an additional vascular plug deployed in one patient tilted the PVL plug into the valve orifice and was corrected by an undersized vascular plug (Supplemental Fig. 2). Procedural complications included hemothorax from apical puncture in two, embolization of a duct occluder in one, catheter fragmentation in one and were not directly related to the Amplatzer PVL plug.

#### 4. Discussion

Treatment options were limited for PVL after valve replacements.<sup>3</sup> Circular devices and plugs were often used in the past for transcatheter closure. Oblong Amplatzer PVL plug might be more appropriate for crescentic leaks from circumferential suture lines.<sup>5,6</sup> We analyzed a subgroup where the PVL plug was used among heterogenous leaks with varying numbers, shapes, sizes and locations and presentations. Apart from PVL plug, these patients received 31 more circular plugs, indicating the need for additional occluders. This heterogeneity precluded comparison of these PVL plugs against other circular plugs. 259 patients in a 12-year multicenter UK registry received 344 devices, with some patients receiving upto four devices.<sup>5</sup> Sequential staggered 'nesting' of PVL with multiple devices was the preferred strategy.<sup>12</sup> PVL plug was not approved in United States outside PARADIGM trial.<sup>7</sup> We used them in only 16 out of the 79 procedures due to familiarity with circular plugs. International PVL closure experience had been dominated by circular plugs and devices for similar reasons, despite the recent availability of oblong plugs. Annular abnormalities posed significant problems for sheath placement through the fibrosed and calcified tracks.<sup>13</sup>

Procedural success defined as significant reduction of PVL was achieved in all, though after elective reintervention in three patients. A quarter of patients in a single-center Polish mitral PVL registry, a single center United States report and 12-year United Kingdom multicenter study required an elective second procedure.<sup>2,5,6</sup> Emphasis for defining success is given to improvement of the leak rather than the number of sittings required.<sup>5,6,14</sup> While procedural success was 78% in Polish registry, it was 89% in US study.<sup>5,6</sup>

Procedural outcomes might differ from clinical outcomes in prosthetic valve disease as these patients might continue to have adverse cardiovascular events.<sup>2</sup> Old age, renal failure, persistent PVL and post procedure NYHA class were correlated to late events.<sup>2</sup> Though NYHA class uniformly improved in all, two patients had late cerebrovascular fatal events. Lack of interference with metallic valves was a key advantage.<sup>5,6</sup> The peculiar shape auto-oriented to crescentic leaks facilitating the procedure.<sup>15</sup>

#### 5. Conclusions

The oblong shaped Amplatzer PVL plug provided successful closure in crescentic mitral and aortic PVL, though some needed an elective second reintervention. The auto-orientation of the long axis of the plug and lack of interference of metal valves were useful attributes.

#### 6. What is already known?

Paravalvular defects after valve replacements offer unique challenges due to heterogeneity of their shape, size, location and tortuosity of their track. Transcatheter closure utilizes multiple off-label devices that are not specifically meant for the purpose.

#### 7. What this study adds?

A rectangular recently rechristened Amplatzer PVL plug adds to the armamentarium for crescentic leaks along the circumference. Auto-orientation of the plug and minimal protrusion are favorable attributes.

#### Declaration of competing interest

None of the authors have any conflicts to declare.

#### Appendix A. Supplementary data

Supplementary data to this article can be found online at <https://doi.org/10.1016/j.ihj.2022.04.004>.

#### References

1. Beurtheret S, Gariboldi V, Feier H, et al. Short-term results of repeat valve replacement: a predictive factor analysis. *J Heart Valve Dis.* 2010;19:326–332.
2. Ruiz CE, Jelin V, Kronzon I, et al. Clinical outcomes in patients undergoing percutaneous closure of periprosthetic paravalvular leaks. *J Am Coll Cardiol.* 2011;58:2210–2217.
3. Hijazi ZM. Transcatheter management of paravalvular mitral leaks: far from ideal. *Cathet Cardiovasc Interv.* 2004;61:552–553.
4. Lopera JE. The amplatzer vascular plug: review of evolution and current applications. *Semin Intervent Radiol.* 2015;32:356–369.
5. Calvert PA, Northridge DB, Malik IS, et al. Percutaneous device closure of paravalvular leak: combined experience from the United Kingdom and Ireland. *Circulation.* 2016;134:934–944.
6. Smolka G, Pysz P, Jasinski M, et al. Multipleg paravalvular leak closure using Amplatzer Vascular Plugs III: a prospective registry. *Cathet Cardiovasc Interv.* 2016;87:478–487.
7. Ruiz CE. PARADIGM Amplatzer Valvular Plug for PVL Closure. <https://clinicaltrials.gov/show/NCT04489823>.
8. Nietlispach F, Johnson M, Moss RR, et al. Transcatheter closure of Paravalvular defects using a purpose-specific occluder. *J Am Coll Cardiol Intv.* 2010;3:759–765.
9. Cruz-Gonzalez I, Rama-Merchan JC, Arribas-Jimenez A, et al. Paravalvular leak closure with the Amplatzer vascular plug III device: immediate and short-term results. *Rev Española Cardiol.* 2014;67:608–614.
10. Sivakumar K. Transcatheter closure of paravalvular leaks - how do I do it? *Indian Heart J.* 2013;65:289–294.
11. Sivakumar K, Doraiswamy V, Sheriff EA. Multimodal imaging of dissecting sinus of valsalva aneurysms from right and left aortic sinuses and its management. *J Indian Acad Echocardiogr Cardiovasc Imaging.* 2017;1:167–168.
12. Rihal CS, Sorajja P, Booker JD, Hagler DJ, Cabalka AK. Principles of percutaneous Paravalvular leak closure. *J Am Coll Cardiol Intv.* 2012;5:121–130.
13. Raghuram P, Sivakumar K. Acquired submitral aneurysms may be associated with mitral Paravalvular leaks. *Asian Cardiovasc Thorac Ann.* 2021;29:822–825.
14. Sivakumar K, Shahani J. Trans catheter closure of paravalvular mitral prosthetic leak with resultant hemolysis. *Int J Cardiol.* 2006;115:e39–e40.
15. Onarato EM, Muratori M, Smolka G, et al. Midterm procedural and clinical outcomes of percutaneous Paravalvular leak closure with the Occlutech Paravalvular leak device. *Eurointervention.* 2020;15:1–9.