

# Chemotherapy-induced nephrotoxicity was improved by crocin in mouse model

Qichao Yin, Hua Xiong

Department of Hematology, the Affiliated Hospital of Qinghai University, Xining, China

## ABSTRACT

Cisplatin (CDDP) has been widely used in cancer therapy, but it has been linked to side effects such as nephrotoxicity. Crocin is a carotenoid found in crocus and gardenia flowers that has been shown to have anti-oxidant properties, inhibit tumor growth, and provide neuroprotection. The purpose of this study was to investigate the protective effect of crocin against CDDP-induced nephrotoxicity in a mouse model. Kunming mice were administered orally with crocin for 7 days at the dose of 6.25 mg/kg and 12.5 mg/kg per body weight daily and were injected with CDDP *via* intraperitoneal route at the dose of 10 mg/kg per body weight. Using commercial kits, the oxidative stress markers glutathione, malondialdehyde, catalase, glutathione peroxidase, and superoxide dismutase were measured in the kidneys of mice. Immunohistochemistry was used to assess the levels of p53, cleaved caspase-3, and phospho-p38 mitogen-activated protein kinase in the kidneys. Crocin significantly reduced CDDP-induced changes in serum creatinine and blood urea nitrogen levels, according to the findings. Crocin reduced malondialdehyde levels and increased glutathione, glutathione peroxidase, catalase, and superoxide dismutase levels in CDDP-induced lipid peroxidation. Crocin also significantly inhibited p38 mitogen-activated protein kinase activation, p53 expression, and caspase-3 cleavage. In conclusion, crocin protects against CDDP-induced oxidative stress and nephrotoxicity by attenuating the activation of p38 mitogen-activated protein kinase and caspase-3 cleavage.

**Key words:** Crocin; cisplatin; nephrotoxicity; p38 MAPK; caspase-3.

**Correspondence:** Hua Xiong, Department of Hematology, the Affiliated Hospital of Qinghai University, No. 29 Tongren Road, Chengxi District, Qinghai 810001, China. Tel. +86.13897267647.  
E-mail: 330963014@qq.com

**Contributions:** HX, study design; QY, HX, experiments performing. All the authors have read and approved the final version of the manuscript and agreed to be accountable for all aspects of the work.

**Ethics Approval:** All animal experiment protocols listed below have been reviewed and approved by the by Animal Use and Care Committee of Affiliated Hospital of Qinghai University, Xining, China (No. 20200318).

**Availability of data and material:** All data generated or analyzed during this study are included in this published article.

**Conflict of interest:** The authors declare that they have no competing interests, and all authors confirm accuracy.

**Funding:** This study received no funding.

## Introduction

Cisplatin (CDDP) has been widely applied in cancer treatment as one effective chemotherapy agent. Nevertheless, nephrotoxicity is the dose limiting factor for clinical use of CDDP.<sup>1</sup> The nephrotoxicity induced by CDDP may be due to oxidative stress, DNA damage, apoptosis and inflammation.<sup>2,3</sup> Previous study indicated the role of reactive oxygen metabolites in the nephrotoxicity.<sup>4</sup> CDDP induced nephrotoxicity is associated with reduced levels of superoxide dismutase (SOD) and catalase (CAT), and the changed levels of glutathione (GSH) and malondialdehyde (MDA) in the kidneys.<sup>5,6</sup> The mechanism of p53 activation by CDDP may involve cell apoptosis and oxidative stress.<sup>7</sup> Reactive oxygen molecules, for example, can activate p53 and caspases.<sup>8</sup>

To maximize the efficacy of CDDP in cancer chemotherapy, it is critical to identify compounds that reduce CDDP-induced nephrotoxicity. Crocin is a carotenoid chemical compound found in crocus and gardenia flowers. Crocin has been shown in recent studies to inhibit tumor growth, provide neuroprotection, and have anti-oxidant properties.<sup>9-11</sup> As a result, we hypothesized that crocin could prevent CDDP-induced nephrotoxicity by inhibiting oxidative stress and apoptosis. Using the Kunming mouse as the experimental model, this study sought to investigate the activity of crocin in attenuating CDDP-induced nephrotoxicity.

## Material and Methods

### Animals

Kunming mice (weight 18-22 g) were provided by the Qinghai University Experiment Animal Center. Animals were maintained in the laboratory under standardized, sterilized conditions (25±2°C, 50-60% relative humidity, 12 h dark/light cycle), and fed with standard diet and water *ad libitum*. All animal experiment protocols were approved by Animal Use and Care Committee of Affiliated Hospital of Qinghai University.

Thirty mice were randomly divided into five groups (n=6). CDDP, crocin, and the antioxidant agent, silymarin were obtained from Sigma-Aldrich (St. Louis, MO, USA). Group I received 0.9% saline intraperitoneally for 7 days. Group II received CDDP (10 mg/kg) intraperitoneally on day one. Group III and IV received crocin at 6.25 and 12.5 mg/kg intraperitoneally per day, respectively, for 7 days following CDDP (10 mg/kg) injection on day one. Group V (positive control) received silymarin (100 mg/kg) orally per day for 7 days following CDDP (10 mg/kg) injection on day one. Seven days after CDDP treatment, all mice were sacrificed.

### Measurement of blood urea nitrogen and serum creatinine

Blood samples were collected and centrifuged at 2,500 rpm for 10 min at 4°C. Blood urea nitrogen (BUN) and serum creatinine (Cr) kits were obtained from Jiancheng Bioengineering Institute (Nanjing, China). BUN and creatinine levels were measured using commercial kits according to the manufacturers' instructions.

### Biochemical analysis

Kidney tissues were homogenized in phosphate buffer (pH 7.4) and the supernatants were collected after centrifugation at 12,000 g at 4°C for 20 min. Glutathione (GSH), malondialdehyde (MDA), catalase (CAT), glutathione peroxidase (GPx), and superoxide dismutase (SOD) kits were obtained from Jiancheng Bioengineering Institute (Nanjing, China). The activities of SOD, CAT, and GPx and MDA and GSH levels in the supernatants were determined by the

assay kits and normalized to protein concentrations.

### Histological analysis

The kidneys were dissected, washed in 0.9% saline and fixed in 10% formalin overnight. The samples were embedded in paraffin and cut into 5 µm sections. After staining by hematoxylin and eosin (H&E) the sections were observed under a light microscope (Olympus, Japan) with 50x objective.

### Immunohistochemical staining

The kidney sections were boiled in citric acid buffer for 10 min for antigen retrieval and then incubated in 0.3% H<sub>2</sub>O<sub>2</sub> for 30 min to block endogenous peroxidase. Next, the sections were incubated with 10% normal horse serum for 30 min and then incubated overnight at 4°C with primary antibodies for p53, cleaved caspase-3 and phospho-p38 MAPK (all from Santa Cruz Biotechnology, Inc., Dallas, TX, USA, 1:100 dilution in phosphate buffered saline containing 2% normal horse serum). The sections were washed with phosphate buffered saline and then incubated with biotinylated secondary antibody (1:1,000 dilution in phosphate buffered saline containing 2% normal horse serum) at 37°C for 30 min, followed by the incubation with streptavidin/biotin complex peroxidase kit (Boster, Wuhan, China) at 37°C for 30 min. The sections incubated with phosphate buffered saline instead of primary antibodies were used as negative controls. Finally, all sections were counterstained with hematoxylin. The immunostaining signal was observed under Olympus microscope with 50x objective, and the staining intensity from five randomly selected microscope fields (the size of the selected area was around 250 µm<sup>2</sup>) per sample was analyzed using Media Cybernetics Image-Pro Plus system, with staining intensity in sample from control group set as 1.

### Statistical analysis

Data were presented as the mean ± standard deviation (SD), and analyzed by using one-way analysis of variance (ANOVA) followed by LSD test using SPSS 23.0 software. A p-value <0.05 indicated significant difference.

## Results

### Crocin attenuated renal injury in CDDP treated mice

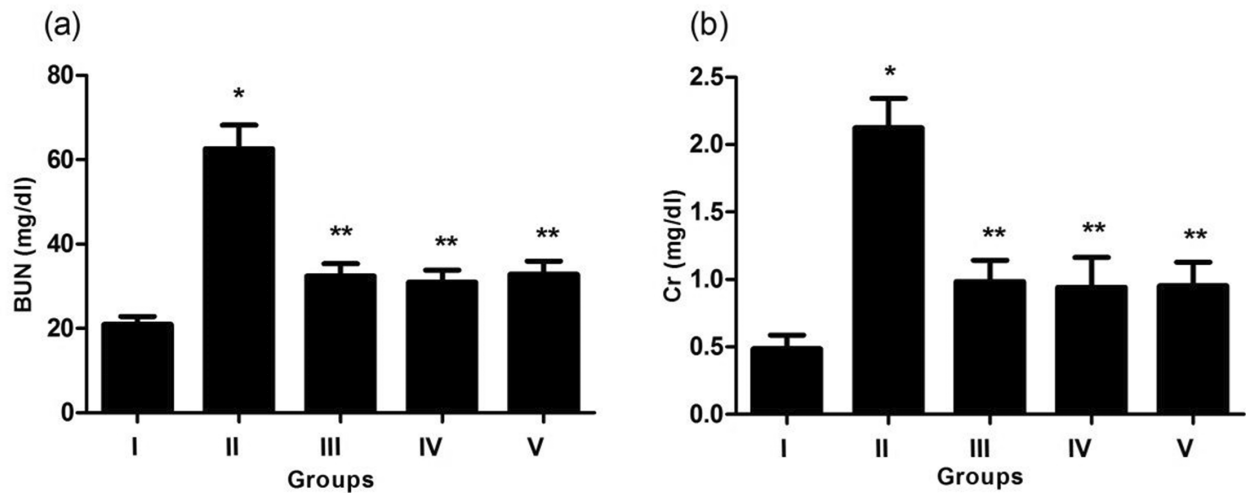
First, we detected the levels of serum BUN and creatinine as the biomarkers of renal injury. Serum BUN and creatinine levels were significantly higher in CDDP treated group compared to control group, but serum BUN and creatinine levels were significantly reduced in crocin treated group compared to CDDP treated group (Figure 1).

### Crocin improved kidney histology in CDDP treated mice

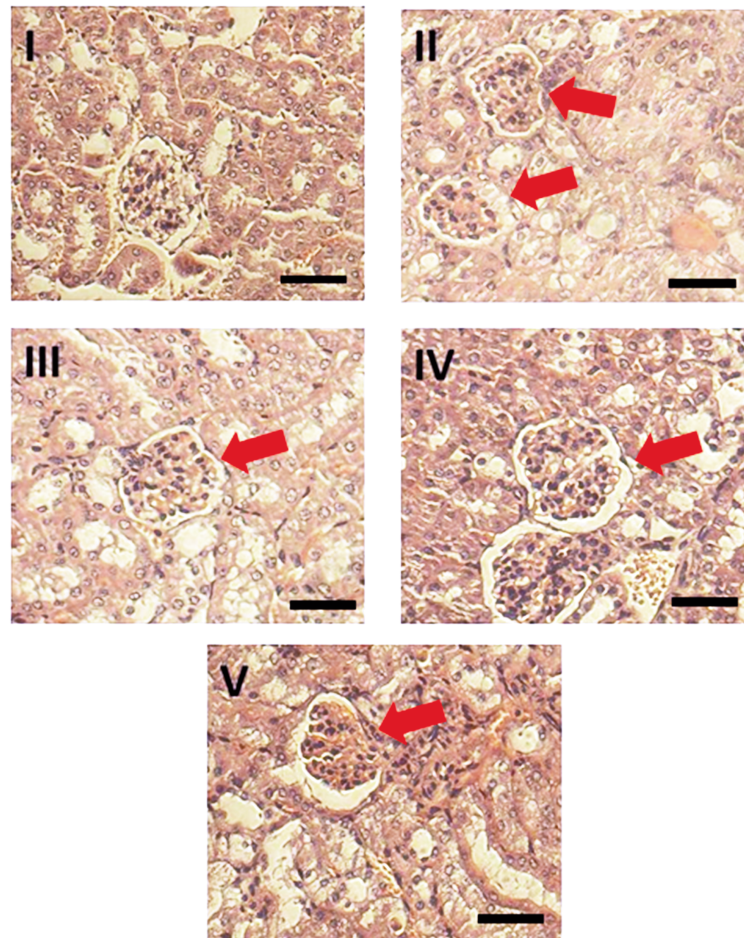
Histological analysis showed regular appearance of glomeruli and tubuli in the kidney sections of control mice. In contrast, in CDDP group we found severe degeneration in glomeruli and tubuli, especially proximal tubular necrosis, the degeneration in epithelial cells of the proximal tubules, and renal tubular cast. However, kidney lesions were ameliorated in crocin treated group (Figure 2).

### Crocin relieved CDDP induced oxidative stress in the kidneys

To examine the role of oxidative stress in CDDP induced nephrotoxicity, we measured MDA and GSH levels in the kidneys. As shown in Figure 3a, CDDP administration caused significant increase in MDA level (6.87±0.37 nmol/mg protein) in the kidneys compared to control (2.92±0.23 nmol/mg protein; p<0.05), and



**Figure 1.** Crocin reduced the levels of serum BUN (a) and Cr (b) in mice. I, control group; II, CDDP treatment group (10 mg/kg); III, crocin (6.25 mg/kg body weight) +CDDP treatment group; IV, crocin (12.5 mg/kg body weight) +CDDP treatment group; V, silymarin (100 mg/kg) + CDDP treatment group. Silymarin as antioxidant agent was used as positive control. Data were expressed as mean  $\pm$  SD (n=6). \* $p < 0.05$  versus group I; \*\* $p < 0.05$  versus group II.



**Figure 2.** Crocin reduced renal lesions in mice. HE staining of kidney tissue sections. In control group (I), we observed normal appearance of glomeruli and tubuli in the kidney sections. In CDDP treatment group (10 mg/kg) (II), we observed severe degeneration in glomeruli and tubuli as indicated by red arrows. In crocin (6.25 mg/kg body weight) +CDDP treatment group (III), we observed much less degeneration in glomeruli and tubuli as indicated by red arrow. In crocin (12.5 mg/kg body weight) +CDDP treatment group (IV), we observed almost normal appearance of glomeruli and tubuli as indicated by red arrow. In silymarin (100 mg/kg) + CDDP treatment group (V), we observed almost normal appearance of glomeruli and tubuli as indicated by red arrow. Silymarin as antioxidant agent was used as positive control. Scale bar: 50  $\mu$ m.

crocin treatment reduced kidney MDA level in CDDP treated mice ( $p < 0.05$ ). In addition, GSH content decreased in the kidney tissues of CDDP treated mice, but was recovered after crocin treatment (Figure 3b,  $p < 0.05$ ). Moreover, significantly reduced SOD, CAT, and GPx activities were found in the kidneys of CDDP treated animals compared to control group. However, treatment with crocin and silymarin increased CAT, SOD and GPx activities in the kidneys of CDDP treated mice (Figure 3 c-e). These results showed that crocin may attenuate oxidative stress in the kidneys induced by CDDP.

### Crocin reduced p53, cleaved caspase-3 and phospho-p38 levels in the kidneys of CDDP treated mice

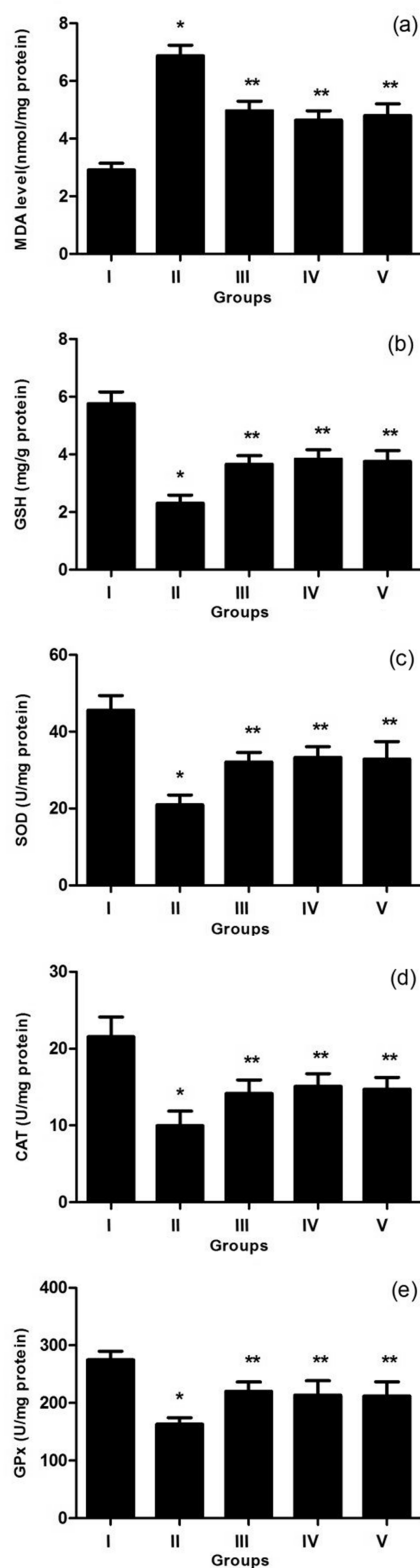
Immunohistochemical staining of p53, phospho-p38, and cleaved caspase-3 in the kidneys showed stronger signal in CDDP treated group than in control group, but it showed weaker signal after the treatment with crocin and silymarin (Figure 4). Quantitative analysis showed that significantly increased staining intensity of p53, phospho-p38, and cleaved caspase-3 were found in the kidneys of CDDP treated animals compared to control group. However, treatment with crocin and silymarin significantly decreased staining intensity of p53, phospho-p38, and cleaved caspase-3 in the kidneys of CDDP treated mice (Figure 5). These results showed that crocin decreased the levels of p53, cleaved caspase-3 and phospho-p38 in the kidneys of CDDP treated mice.

## Discussion

CDDP is a platinum-based antineoplastic agent, but it causes side effects such as nephrotoxicity.<sup>12</sup> Here we reported that crocin could attenuate CDDP induced nephrotoxicity using mouse model, and the activity of crocin was related to reduced oxidative stress, reduced activation of p38 MAPK and reduced cleavage of caspase-3 in the kidneys of CDDP treated mice.

We found that CDDP caused kidney injury as shown by significantly increased serum creatinine and BUN levels compared to control group. These results are consistent with previous report that CDDP significantly increased serum creatinine and BUN levels.<sup>13</sup> However, compared to CDDP group, serum creatinine and BUN levels significantly decreased in crocin treatment (6.25 and 12.5 mg/kg) groups. Serum creatinine and BUN levels in crocin treatment group were similar to those in silymarin treatment group. Histopathological analysis showed that after the injection of CDDP the kidneys were characterized by proximal tubular injury such as moderate necrosis, and the injury improved after crocin treatment. However, the mechanism of CDDP induced renal injury remains unclear. The cytotoxic effects of CDDP may involve several mechanisms, including oxidative stress, DNA damage, inflammatory response, mitochondrial injury, and apoptosis of renal tubular cells.<sup>14,15</sup>

Lipid peroxidation is a marker of oxidative stress and the level of MDA, a lipid peroxidation product, increases after CDDP treatment. In addition, GSH depletion contributed to CDDP induced oxidative stress.<sup>16</sup> Similarly, we observed CDDP induced oxidation damage in the kidneys. The increased level of MDA and the depletion of GSH demonstrated that CDDP induced oxidative damage. These changes of the antioxidant system may be secondary to oxidative stress induced by CDDP. In addition, crocin significantly reduced MDA level and increased GSH level. In fact, it has been reported that the activities of antioxidant enzymes decreased in animals treated with CDDP.<sup>17</sup> In this study, the decrease in CAT, SOD, and GPx activities after CDDP treatment was consistent with previous reports.<sup>18,19</sup> However, crocin increased the activities of antioxidant enzymes to lessen CDDP toxicity.



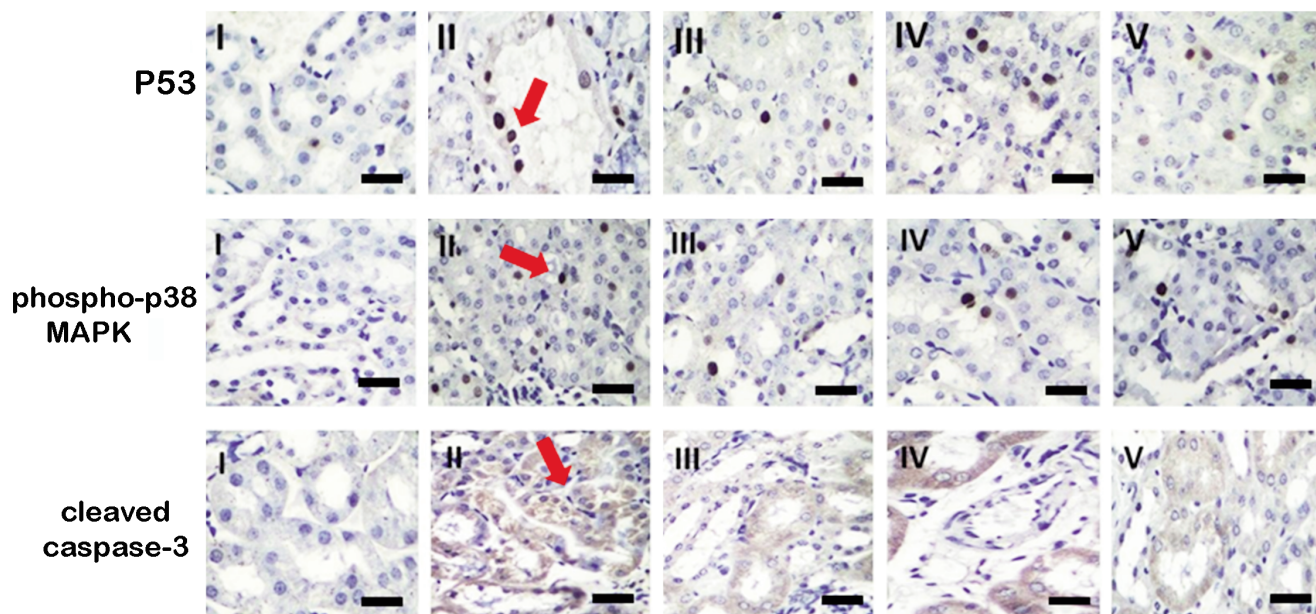
**Figure 3.** Crocin attenuated oxidant stress in the kidneys. Levels of (a) MDA, (b) GSH, (c) SOD, (d) CAT, and (e) GPx were measured. I, control group; II, CDDP treatment group (10 mg/kg); III, crocin (6.25 mg/kg body weight) +CDDP treatment group; IV, crocin (12.5 mg/kg body weight) +CDDP treatment group; V, silymarin (100 mg/kg) + CDDP treatment group. Silymarin as antioxidant agent was used as positive control. Data were expressed as mean  $\pm$  SD (n=6). \* $p < 0.05$  versus group I; \*\* $p < 0.05$  versus group II.

Reactive oxygen species (ROS) may contribute to CDDP induced toxicity.<sup>20</sup> CDDP generates ROS, which then induces DNA damage and the activation of p38 MAPK.<sup>21</sup> In our study, we found that p38 MAPK activity increased after CDDP treatment, but crocin inhibited CDDP induced activation of p38 MAPK. These data confirmed the role of oxidative stress in CDDP induced toxicity.

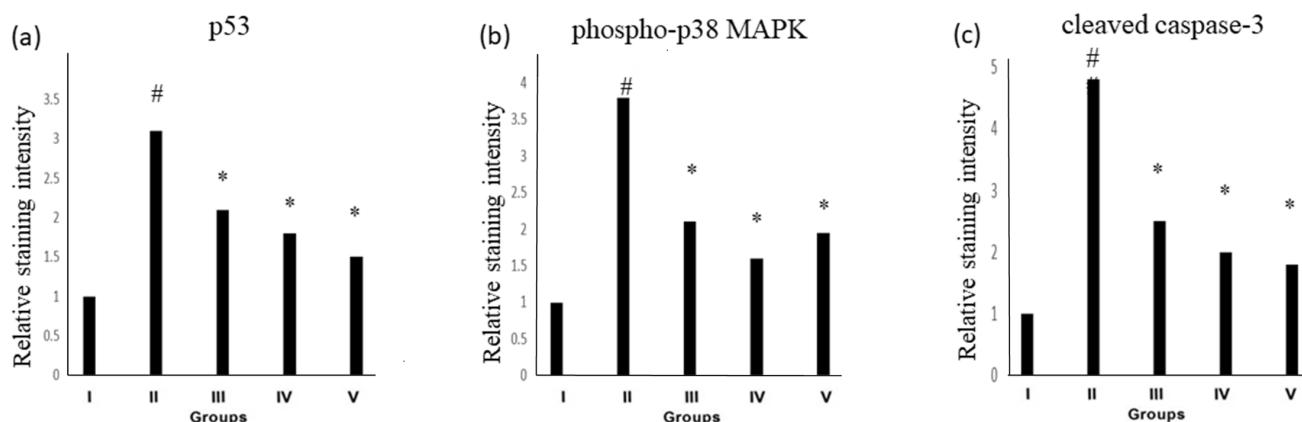
DNA damage could activate p38MAPK, leading to the activation of p53.<sup>22</sup> Apoptosis is induced after the activation of caspases-8 and caspase-9, which then trigger effector caspase-3.<sup>23</sup> In this study, the levels of p53 and cleaved caspase-3 increased in the kidneys of mice treated with CDDP, consistent with previous study.<sup>24</sup> However,

crocin significantly attenuated p53 and cleaved caspase-3 levels in CDDP group. Our results indicate that crocin may inhibit apoptosis of kidney cells. In future studies, we will employ p38 MAPK signaling inhibitors to confirm that crocin reduces cisplatin induced apoptosis of kidney cells by regulating p38 MAPK signaling.

While detailed mechanism of crocin on CDDP induced nephrotoxicity remains incompletely understood, our results indicate that crocin may provide protection on CDDP induced nephrotoxicity by inhibiting oxidative stress and apoptotic damage. Crocin could be used to attenuate CDDP induced nephrotoxicity in cancer patients.



**Figure 4.** Immunohistochemical staining of p53, phospho-p38 MAPK and cleaved caspase-3 in the kidneys. I, control group; II, CDDP treatment group (10 mg/kg); III, crocin (6.25 mg/kg body weight) +CDDP treatment group; IV, crocin (12.5 mg/kg body weight) +CDDP treatment group; V, silymarin (100 mg/kg) + CDDP treatment group. Silymarin as antioxidant agent was used as positive control. The strong staining signal was marked by red arrows. Scale bar: 50  $\mu$ m.



**Figure 5.** Quantitative analysis of p53, phospho-p38 MAPK and cleaved caspase-3 staining in the kidneys. I, control group; II, CDDP treatment group (10 mg/kg); III, crocin (6.25 mg/kg body weight) +CDDP treatment group; IV, crocin (12.5 mg/kg body weight) +CDDP treatment group; V, silymarin (100 mg/kg) + CDDP treatment group. Silymarin as antioxidant agent was used as positive control. # $p < 0.05$  versus group I; \* $p < 0.05$  versus group II.

## References

- Manohar S, Leung N. Cisplatin nephrotoxicity: a review of the literature. *J Nephrol* 2018;31:15-25.
- Wang Z, Wu R, Nie Q, Bouchonville KJ, Diasio RB, Offer SM. Chromatin assembly factor 1 suppresses epigenetic reprogramming toward adaptive drug resistance. *J Natl Cancer Cent* 2021;1:15-22.
- Yoon S P, Kim J. Exogenous spermidine ameliorates tubular necrosis during cisplatin nephrotoxicity. *Anat Cell Biol* 2018;51:189-99.
- Ahmed OM, Hassan MA, Saleh AS. Combinatory effect of hesperetin and mesenchymal stem cells on the deteriorated lipid profile, heart and kidney functions and antioxidant activity in STZ-induced diabetic rats. *Biocell* 2020;44:27-9.
- Neamatallah T, El-Shitany N, Abbas A, Eid BG, Harakeh S, Ali S, et al. Nano ellagic acid counteracts cisplatin-induced upregulation in OAT1 and OAT3: a possible nephroprotection mechanism. *Molecules* 2020;25:3031.
- Huang H, Miao H, Wang J, Wu D, Lei Q, Wang S, et al. Advances on anticancer new drugs in China and the USA in 2020: from ongoing trial to drug approval. *J Natl Cancer Cent* 2021;1:147-52.
- Kim JY, Jo J, Leem J, Park KK. Inhibition of p300 by garcinol protects against cisplatin-induced acute kidney injury through suppression of oxidative stress, inflammation, and tubular cell death in mice. *Antioxidants* 2020;9:1271.
- Owumi SE, Dim UJ. Manganese suppresses oxidative stress, inflammation and caspase-3 activation in rats exposed to chlorpyrifos. *Toxicol Rep* 2019;6:202-9.
- Heitmar R, Brown J, Kyrou I. Saffron (*Crocus sativus* L.) in ocular diseases: a narrative review of the existing evidence from clinical studies. *Nutrients* 2019;11:649.
- Lambrianidou A, Koutsougianni F, Papapostolou I, Dimas K. Recent advances on the anticancer properties of Saffron (*Crocus sativus* L.) and its major constituents. *Molecules* 2020;26:86.
- Sheng K, Wei S, Mei J, Xie J. Chilling injury, physicochemical properties, and antioxidant enzyme activities of red pitahaya (*Hylocereus polyrhizus*) fruits under cold storage stress. *Phyton-Int J Exp Botany* 2021;90:291-305.
- Perše M, Večerić-Haler Ž. Cisplatin-induced rodent model of kidney injury: characteristics and challenges. *Biomed Res Int* 2018;2018:1462802.
- Sohail N, Hira K, Tariq A, Sultana V, Ehteshamul-Haque S. Marine macro-algae attenuates nephrotoxicity and hepatotoxicity induced by cisplatin and acetaminophen in rats. *Environ Sci Pollut Res Int* 2019;26:25301-11.
- Volarevic V, Djokovic B, Jankovic MG, Harrell CR, Fellabaum C, Djonov V, et al. Molecular mechanisms of cisplatin-induced nephrotoxicity: a balance on the knife edge between renoprotection and tumor toxicity. *J Biomed Sci* 2019;26:25.
- Li W, Yang Y, Li Y, Zhao Y, Jiang H. Sirt5 attenuates cisplatin-induced acute kidney injury through regulation of Nrf2/HO-1 and Bcl-2. *Biomed Res Int* 2019;2019:4745132.
- Santos NA, Catão CS, Martins NM, Curti C, Bianchi ML, Santos AC. Cisplatin-induced nephrotoxicity is associated with oxidative stress, redox state unbalance, impairment of energetic metabolism and apoptosis in rat kidney mitochondria. *Arch Toxicol* 2007;81:495-504.
- Qi Z, Li Z, Li W, Liu Y, Wang C, Lin H, et al. Pseudoginsengin DQ exhibits therapeutic effects in cisplatin-induced acute kidney injury via Sirt1/NF-κB and caspase signaling pathway without compromising its antitumor activity in mice. *Molecules* 2018;23:3038.
- Un H, Ugan RA, Gurbuz MA, Bayir Y, Kahramanlar A, Kaya G, et al. Phloretin and phloridzin guard against cisplatin-induced nephrotoxicity in mice through inhibiting oxidative stress and inflammation. *Life Sci* 2021;266:118869.
- Ahmed OM, Galaly SR, Raslan M, Mostafa MMA. Thyme oil and thymol abrogate doxorubicin-induced nephrotoxicity and cardiotoxicity in Wistar rats via repression of oxidative stress and enhancement of antioxidant defense mechanisms. *Biocell* 2020;44:41-53.
- Sheth S, Mukherjee D, Rybak LP, Ramkumar V. Mechanisms of cisplatin-induced ototoxicity and otoprotection. *Front Cell Neurosci* 2017;11:338.
- Zhou J, Fan Y, Zhong J, Huang Z, Huang T, Lin S, et al. TAK1 mediates excessive autophagy via p38 and ERK in cisplatin-induced acute kidney injury. *J Cell Mol Med* 2018;22:2908-21.
- Khan R, Khan AQ, Qamar W, Lateef A, Tahir M, Rehman MU, et al. Chrysin protects against cisplatin-induced colon toxicity via amelioration of oxidative stress and apoptosis: Probable role of p38MAPK and p53. *Toxicol Appl Pharmacol* 2012;258:315-29.
- Heilig R, Dilucca M, Boucher D, Chen KW, Hancz D, Demarco B, et al. Caspase-1 cleaves Bid to release mitochondrial SMAC and drive secondary necrosis in the absence of GSDMD. *Life Sci Alliance* 2020;3:e202000735.
- Huang D, Wang C, Duan Y, Meng Q, Liu Z, Huo X, et al. Targeting Oct2 and P53: Formononetin prevents cisplatin-induced acute kidney injury. *Toxicol Appl Pharmacol* 2017;326:15-24.

Received for publication: 30 August 2022. Accepted for publication: 26 September 2022.

This work is licensed under a Creative Commons Attribution-NonCommercial 4.0 International License (CC BY-NC 4.0).

©Copyright: the Author(s), 2022

Licensee PAGEPress, Italy

*European Journal of Histochemistry* 2022; 66:3541

doi:10.4081/ejh.2022.3541

*Publisher's note: All claims expressed in this article are solely those of the authors and do not necessarily represent those of their affiliated organizations, or those of the publisher, the editors and the reviewers. Any product that may be evaluated in this article or claim that may be made by its manufacturer is not guaranteed or endorsed by the publisher.*