

The Evaluation of Ophthalmic Findings in Women Patients With Iron and Vitamin B12 Deficiency Anemia

Mehmet Coskun¹ and Nurhayat O. Sevencan²

¹ Medicine Faculty, Department of Ophthalmology, The University of Karabuk, Karabuk, Turkey

² Medicine Faculty, Department of Internal Medicine, The University of Karabuk, Karabuk, Turkey

Correspondence: Nurhayat O. Sevencan, The University of Karabuk, Medicine Faculty, Karabuk, Turkey. e-mail: dr_nurhayat@hotmail.com

Received: 14 March 2018

Accepted: 14 June 2018

Published: 24 August 2018

Keywords: iron deficiency anemia; vitamin B12 deficiency anemia; central corneal thickness; retinal nerve fiber layer; ganglion cell-inner plexiform layer

Citation: Coskun M, Sevencan NO. The evaluation of ophthalmic findings in women patients with iron and vitamin B12 deficiency anemia. *Trans Vis Sci Tech.* 2018;7(4):16, <https://doi.org/10.1167/tvst.7.4.16> Copyright 2018 The Authors

Purpose: To determine whether there are differences in the central corneal thickness (CCT), retinal nerve fiber layer (RNFL), and ganglion cell-inner plexiform layer (GC-IPL) in women with iron deficiency anemia (IDA) and vitamin B12 deficiency anemia (B12DA).

Methods: The patients were divided and evaluated in three groups as IDA (group 1), combined IDA-B12DA (group 2), and healthy females (group 3). Each group constituted 35 subjects. CCT, endothelial cell density (CD), the coefficient of variation (CV), and hexagonality (HEX) values were evaluated. Superior, nasal, inferior, and temporal retinal nerve fiber analysis were done, and mean thickness of GC-IPL complex was also evaluated.

Results: CCT was found to be less (thin CCT) in group 2 as compared to group 1 and group 3 ($P = 0.016$ and $P = 0.013$, respectively). While CD measurements did not vary significantly between the groups, CV value was found to be lower in the control group as compared to that in the other groups ($P = 0.001$ and $P = 0.002$, respectively). HEX and the thicknesses of all RNFL and GC-IPL were lower in both the anemic groups as compared to the control group ($P = 0.012$ and $P = 0.013$, respectively); however, no significant difference was determined between the anemia groups.

Conclusions: It should be noted that anemia is a common clinical picture particularly seen in women, and there may be a tendency toward corneal and retinal disorders in these patients. The present study found that presence in the patients with IDA and with combined IDA-B12DA may have influenced endothelial functions; also the patients with anemia had significantly thinner CCT than healthy controls.

Translational Relevance: Optical coherence tomography and specular microscopy measurements may provide important data for early diagnosis and treatment of both corneal and retinal diseases according to the type of anemia in anemic women.

Introduction

Anemia affects roughly one third of the world's population and it is a major and global public health problem. Children aged 0 to 5 years, women of childbearing age, and pregnant women are particularly at risk.^{1,2} Iron deficiency is responsible for most of the cases; and also iron deficiency, nutritional megaloblastic anemia occurs commonly among undernourished societies of tropical and subtropical countries and incidence has dramatically increased over past decades.³

Anemia is clinically defined as blood hemoglobin (Hb) or hematocrit concentration below the lower limit of the reference range applicable to a patient. Hb concentration < 12 g/dL in females and < 13 g/dL in males defines anemia.⁴ The primary function of Hb is to transport oxygen from the lungs to the tissues. In anemic patients, hypoxia is generally seen, as the oxygen transport capacity of blood decreases. As a consequence of hypoxia, tissue functions are impaired; and hence, symptoms of anemia become visible in various systems of the body. Muscular, cardiovascular, and central nervous system symptoms are particularly significant.⁵

Vitamin B12 deficiency is a common cause of megaloblastic anemia, various neuropsychiatric symptoms, and other clinical manifestations. Patients may have severe neurological disorders without significant hematological impairment. The basic neuropathic change in cobalamin deficiency is the demyelination seen in the cerebral cortex and in dorsal and lateral columns of the spinal cord. Since both, the sensorial and the motor systems are affected, the clinical presentation is also referred to as Subacute Combined Degeneration and Combined System Disease.⁶

Iron plays an important role in myelin production, and optic nerve function is unfavorably affected by hypomyelination in the case of inadequate intake of iron.^{7,8} The synthesis of neurotransmitter in the central nervous system is impaired in the presence of iron deficiency and results in cognitive dysfunctions.⁹ Oligodendrocytes play an essential role in myelination and their functions are impaired in states of deficiency of iron. Iron influences myelin synthesis both ways, directly as a co-factor in cholesterol and fatty acid synthesis and indirectly as a component of oxidative metabolism of oligodendrocytes.¹⁰

In recent studies, central corneal thickness (CCT) and choroidal thickness were found to be decreased in children with sickle cell anemia and iron deficiency anemia (IDA).^{11,12} In the present study, the CCT, specular microscopic measurements, the thickness of retinal nerve fiber layer (RNFL), and the thickness of ganglion cell-inner plexiform layer (GC-IPL) were compared between the females with IDA, combined IDA and vitamin B12 anemia (B12DA), and healthy females.

Materials and Methods

This prospective study included 105 patients. Patients presenting to the internal medicine and ophthalmology clinics were evaluated after obtaining approval from the Local Ethical Committee. The corneal examination was performed using a specular microscope (Topcon SP-1P, Japan), CCT was measured using ultrasound pachymeter (Quantel Medical Clermont-Fernand, France), and retinal examination was performed using Cirrus HD spectral-domain OCT (Carl Zeiss Meditec, Dublin, CA). Coefficient of variation (CV) is an objective measure of polymorphism that shows variability between cell areas. CV is the ratio of the standard deviation of cell areas in an endothelial region to the average cell area.

Normal value should be < 0.30 (30%) [CV: (SD/AVE $\times 100$)].

Hb < 12 g/dL and ferritin < 15 ng/mL were considered IDA, whereas vitamin B12 < 200 pg/mL was considered B12DA.⁵ The right eye of 35 females with IDA was assigned to group 1, and the right eye of 35 females with combined IDA-B12DA was assigned to group 2. The right eye of 35 healthy females was assigned to group 3 (control group). Patients with any systemic disease other than iron deficiency or vitamin B12 deficiency, or patients receiving any ocular and systemic drug, and having a history of ocular disease (such as glaucoma, retinal pigment epithelium diseases, and neuro-ophthalmological pathology) or surgical ocular intervention were excluded from the study. In addition, specific and frequent causes for corneal thinning, increased mean keratometry values, and corneal dystrophy among others were also excluded from the study.

Sample Size Calculations

We planned our study of a continuous response variable from independent control and experimental subjects with one control(s) per experimental subject. In a previous study¹² the response within each subject group was normally distributed with standard deviation 39.77. If the true difference in the experimental and control means was 30.54, we needed to study at least 28 experimental subjects and 28 control subjects to be able to reject the null hypothesis that the population means of the experimental and control groups are equal with probability (power) 0.8. The type I error probability associated with this test of this null hypothesis was 0.05. Power and Sample Size Program Version 3.0 (13) was used to estimate sample size.

Statistical Analysis

The results were presented as mean \pm standard deviation for parametric tests and as median, minimum, and maximum for nonparametric tests, where appropriate. The variables were investigated using analytical methods (Kolmogorov-Smirnov goodness of fit test) to determine whether or not they are normally distributed. When investigating the associations between nonnormally distributed continuous variables of three groups, Kruskal-Wallis test was used for the comparisons. Following a significant Kruskal-Wallis test, Dunn-Bonferroni post hoc meth-

Table. The Median, Minimum and Maximum Values of the Comparative Parameters in the Groups and the Statistical Significance Ratings (Statistically Significant Values and Significance Levels Are Indicated in Bold)

Parameters	Group 1	Group 2	Group 3	<i>P</i>
Age (y)	37.85 ± 11.06	34.54 ± 7.44	33.48 ± 9.03	0.126*
CCT (μ)	534^a (477–599)	514^a (473–610)	532 (489–598)	0.018**
CD (cells/mm ²)	2939 (1836–3421)	2669 (2236–3406)	2998 (2040–3100)	0.53**
CV (%)	32^b (23–42)	31^b (26–34)	28^b (24–39)	0.0001**
HEX (%)	50^c (20–75)	54 (20–63)	59^c (41–66)	0.014**
SRNFL (μ)	113^d (84–153)	124^d (44–149)	151^d (77–162)	0.0001**
NRNFL (μ)	73^e (50–99)	69^e (40–95)	96^e (55–104)	0.0001**
IRNFL (μ)	133^f (66–161)	133^f (86–167)	144^f (118–180)	0.003**
TRNFL (μ)	65^g (48–81)	70^g (50–88)	98^g (55–118)	0.0001**
GC-IPL (μ)	86^h (54–97)	82^h (72–101)	92^h (81–98)	0.0001**

* One way ANOVA test (Tukey corrected).

** Kruskal-Wallis test (Dunn-Bonferroni post hoc method adjusted).

^a *P* = 0.028 for groups 1–2.

^b *P* < 0.001 for groups 1–3, *P* = 0.002 for groups 2–3.

^c *P* = 0.022 for groups 1–3.

^d *P* < 0.001 for groups 1–3, *P* < 0.001 for groups 2–3.

^e *P* < 0.001 for groups 1–3, *P* < 0.001 for groups 2–3.

^f *P* = 0.007 for groups 1–3, *P* = 0.014 for groups 2–3.

^g *P* < 0.001 for groups 1–3, *P* < 0.001 for groups 2–3.

^h *P* < 0.001 for groups 1–3, *P* < 0.001 for groups 2–3.

od was performed. For associations between normally distributed continuous variables of three groups, one-way ANOVA test was used. When necessary, Tukey test was used for post hoc. A 5% type I error level was used to infer statistical significance. Statistical analysis was performed using the IBM SPSS software version 24.0 (IBM Corporation, Armonk, NY).

Results

Both the study groups and the control group consisted of female subjects. The mean age was 37.85 ± 11.06 years in group 1, 34.54 ± 7.44 years in group 2, and 33.48 ± 9.03 years in group 3 (*P* = 0.127). CCT was observed as median value of 534 μ (minimum, 477; maximum, 599) in group 1, 514 μ (minimum, 473; maximum, 610) in group 2, and 532 μ (minimum, 489; maximum, 598) in group 3 (*P* = 0.018) (Table; Fig. 1).

The corneal endothelial cell density (CD) was found to be higher in control group (2998 [2040–3100] cell/mm²) compared to the study groups (2939 [1836–3421] cell/mm² in group 1 and 2669 [2236–3406] in group 2). There was no statistically significant difference between the groups (*P* = 0.53) (Table; Fig. 2).

The CV was observed 32% (23–42) in group 1, 31% (minimum, 26; maximum, 34) in group 2, and 28% (minimum, 24; maximum, 39) in group 3 (*P* = 0.0001; Fig. 3). Hexagonality (HEX) was observed 50% (20–75) in group 1, 54% (20–63) in group 2, and 59% (41–66) in group 3 (*P* = 0.014) (Table; Fig. 3).

Superior RNFL (SRNFL) was found to be higher in control group (151 μ [77–162]) compared to the study groups (113 μ [84–153] in group 1 and 124 μ [44–149] in group 2) (*P* = 0.0001) (Table; Fig. 4).

Inferior RNFL (IRNFL) was also higher in control group 144 μ (118–180) (133 μ [66–161] in group 1 and 133 μ [86–167] in group 2; *P* = 0.003) (Table; Fig. 4). Nasal RNFL (NRNFL) was lower in the study groups (73 μ [50–99] in group 1 and 69 μ [40–95] in group 2) compared to the control group (96 μ [55–104]; *P* = 0.0001) (Table; Fig. 5).

Temporal RNFL (TRNFL) was also lower in the study groups (65 μ [48–81] in group 1 and 70 μ [50–88] in group 2) compared to the control group (98 μ [55–118]; *P* = 0.0001) (Table; Fig. 5).

GC-IPL thickness was elevated in control group (92 μ [81–98]) compared to the study groups (86 μ [54–97] and 82 μ [72–101], respectively; *P* = 0.0001) (Table; Fig. 5).

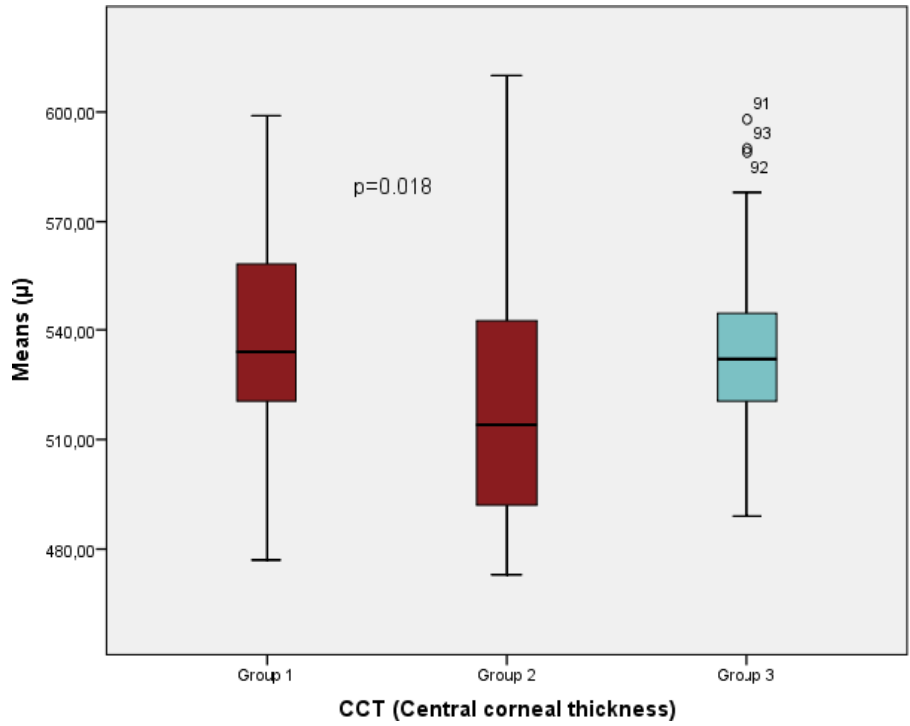


Figure 1. The comparison of CCT levels according to the groups.

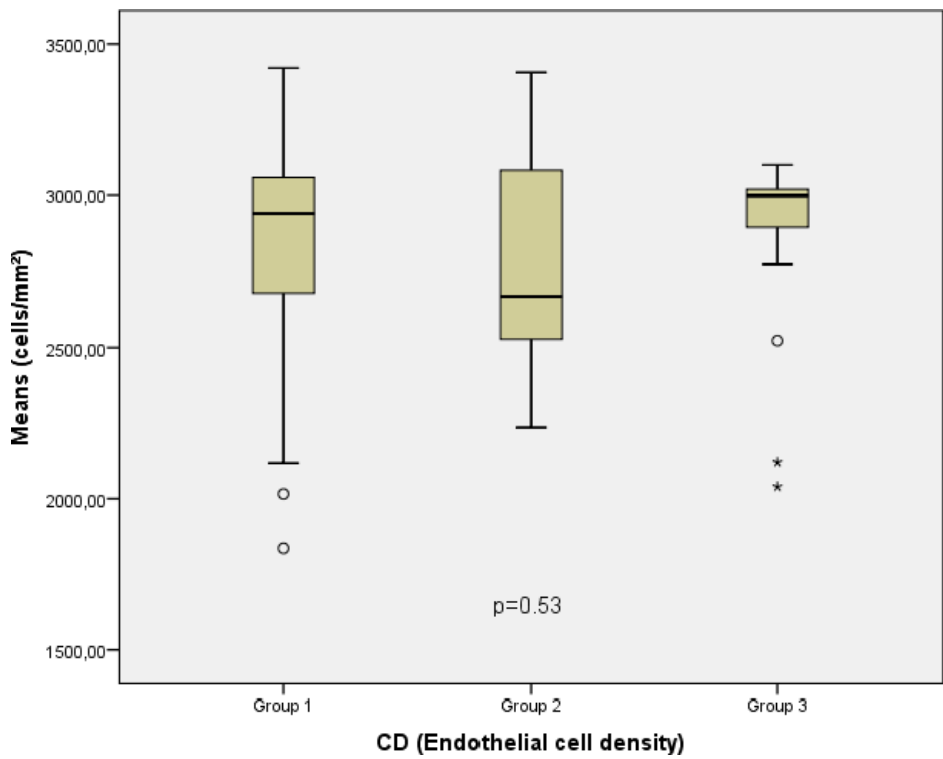


Figure 2. The comparison of CD levels according to the groups.

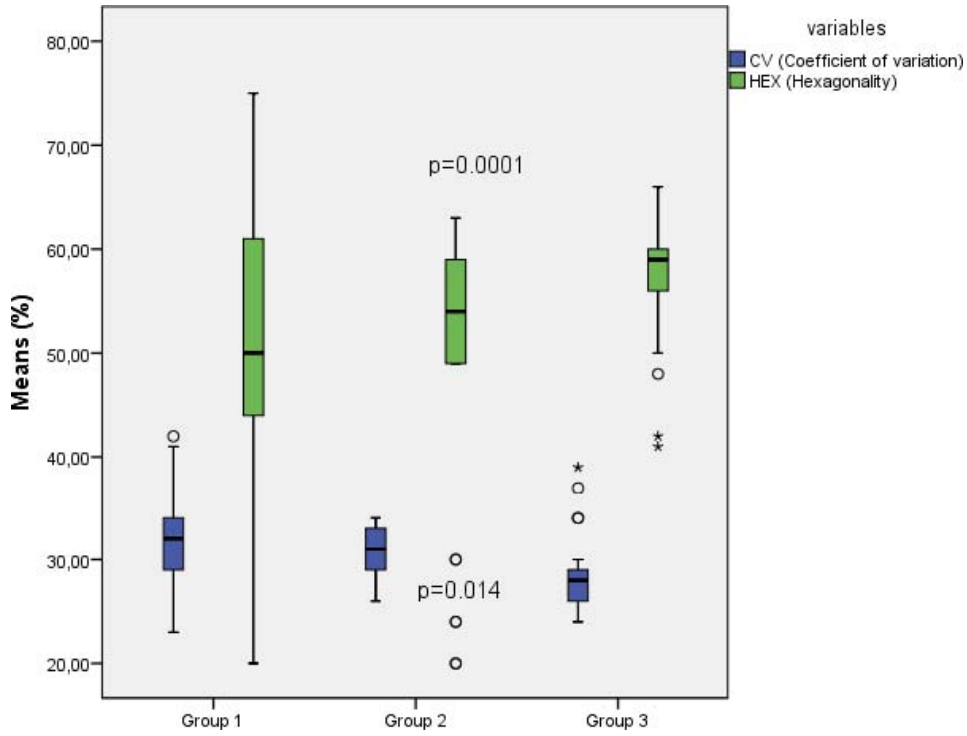


Figure 3. The comparison of IRNFL and SRNFL levels according to the groups.

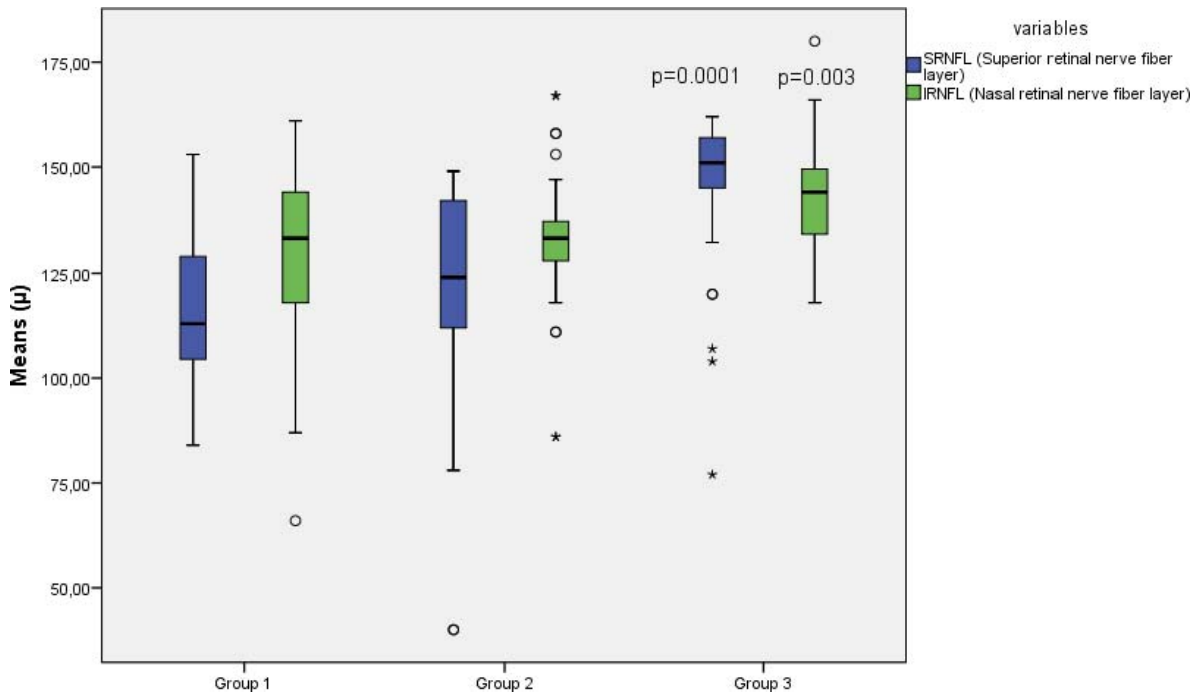


Figure 4. The comparison of IRNFL and SRNFL levels according to the groups.

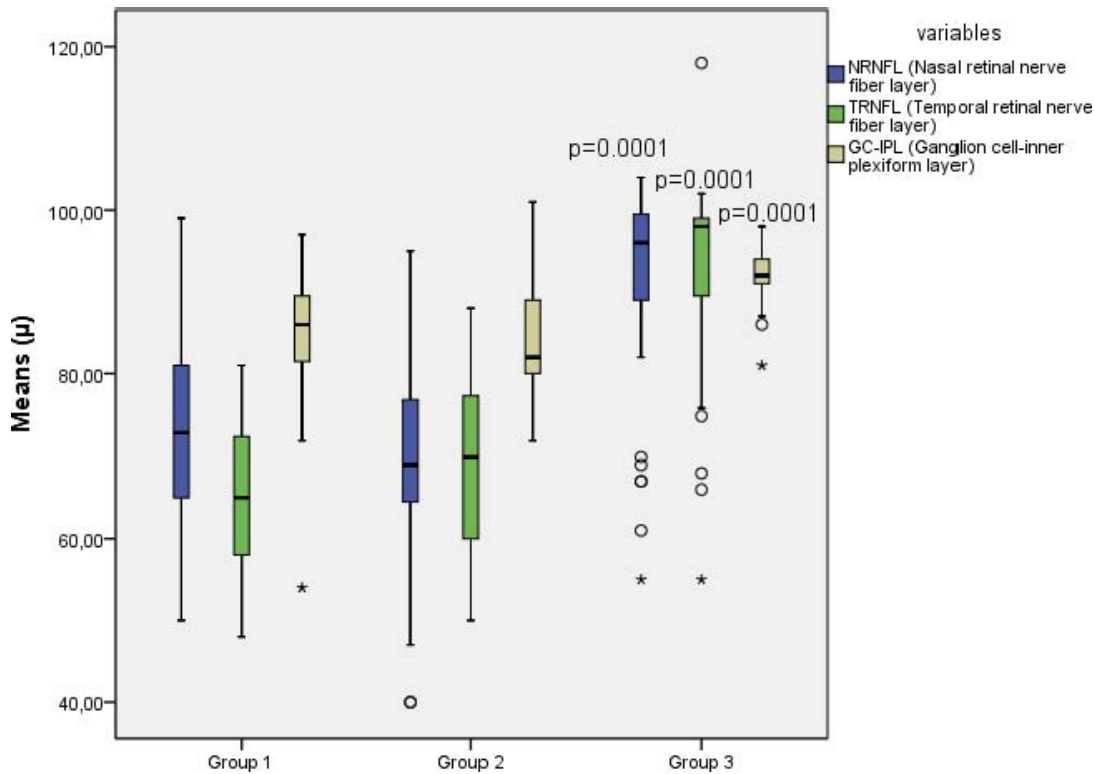


Figure 5. The comparison of NRNFL and TRNFL and GC-IPL levels according to the groups.

Discussion

In the present study, we have been found that RNFL and GC-IPL thicknesses decreased in females of both the groups, IDA group, and combined IDA-B12DA group as compared to those in the control group; however, there was no significant difference between IDA group and combined IDA-B12DA group in terms of both RNFL and GC-IPL thicknesses. Hence, it must be considered in females with IDA or with combined IDA-B12DA in terms of both glaucoma and other neuro-ophthalmological conditions.

Gonul et al.¹⁴ conducted a study in patients with ischemic optic neuropathy and reported thinning in the superior and inferior regions of peripapillary RNFL. Studies conducted in patients with non-arteritic ischemic optic neuropathy have reported that superior peripapillary RNFL is more susceptible to ischemia and that thinning is more significant in that area.^{15–17} Aksoy et al.¹⁸ demonstrated thinning in the inferior RNFL in children with iron deficiency. In addition, thinning of the inferior nasal RNFL has also been demonstrated in females with iron deficiency.¹⁹

Corneal tissue is avascular. The endothelium of the cornea is composed of a single layer of hexagonal cells located on the Descemet's membrane. Endothelial cells show variations throughout life in terms of topography and density, and honeycomb cell configuration, which is geometrically and thermodynamically most stable and has the lowest surface tension, with time.²⁰ CD shows a significant decrease until early adolescence, particularly in the first few years after birth. Earlier studies have found that in patients above 50 years of age, the mean endothelial cell count decreases while pleomorphism is significantly increased.²¹ CD decreases from a mean value of 3000 to 4000 cell/mm² to a mean value of 2600 cell/mm² between the second and eighth decades of life. The percentage of hexagonal cells as well decreases from 75% to about 60%.²² All the participants in the present study were younger than 50 years in age; hence, the effect of age on endothelial parameters has been minimized.

The ability of endothelial cells to undergo mitosis is either or is very low. When cell count decreases after a small trauma in a part of the endothelium or after natural cell death due to aging, the adjacent endothelial cells that do not have the ability to undergo mitosis, try to fill the space by altering their

size and shape.²³ In greater injuries, other neighboring cells immigrate to this region and fill these cell deprived areas. Meanwhile, the hexagonal shape of the cells disappears and larger cells in different geometrical shapes or in strange shapes are seen. This appearance of cells in different sizes is termed as polymegathism, and the decreased ratio of hexagonal cells with an increased number of cells of various geometrical shapes is called pleomorphism. These two parameters should be evaluated together with CD to predict the healthy cell reserve because the mosaic formed by the uniform and homogeneous hexagonal cells is geometrically and thermodynamically the most stable form. Else, the endurance of endothelium against trauma would be decreased.²⁴

The CV is an objective measure of polymegathism, which indicates variation among cellular areas. Its normal value must be lower than 0.30 (30%). HEX is the ratio of hexagonal cells to the other cells having different geometric shapes. Ideally, the ratio must be 100%. However, for a healthy endothelial layer, the ratio must be within the range 60% to 70%. CD is the cell count per 1 mm². Despite any significant difference between CD values of the groups in the present study, CV was found to be significantly high but HEX value was observed to be significantly low in the IDA and combined IDA-B12DA groups as compared to that in the control group; though, there was no statistically significant difference between the anemia groups.

Endothelial cell loss and injury hinder the functions of endothelial layer and increase corneal thickness. Thus, a measurement of corneal thickness indirectly reflects the corneal endothelial functions. However, edema decreases and corneal thickness returns back to normal within several months in healthy corneas, with the loss of endothelial cell not exceeding the physiological limits. In the corneas with moderate endothelial cell injury where healthy cells continue to provide corneal dehydration, a pachymeter does not reflect the functions of endothelial cell layer accurately.²⁴ In the present study, the corneal thickness was observed to be significantly lower in the combined IDA-B12DA group, but there was no significant difference between IDA group and the control group. Endothelial dysfunction due to a hypoxic condition in anemia cannot be explained by this; it has been deliberated by the authors that vitamin B12 deficiency might be a determinant and needs to be supported by larger studies in the future.

As cornea is a transparent tissue, it plays a critical role in vision. Extensive metabolic activity is required to maintain corneal transparency. Oxygen is an important parameter for this metabolic activity. There is a limited number of studies on this subject. One of the rare studies concluded that use of contact lenses may have an unfavorable influence on corneal physiology by creating a hypoxic environment.²⁵ Similarly, corneal endothelial involvement resulting from the hypoxic environment in the anemic subjects versus healthy subjects can be explained by alterations in CV and HEX values, even though quantitative alteration in CD was not significant.

In another study, the endotheliopathy determined in the subjects with pseudoexfoliation could be explained by certain alterations. Conditions like low-grade chronic inflammation, hypoxia, and oxidative stress, that induce cellular stress, play a role in the pathogenesis of pseudoexfoliation syndrome. Increased oxidative stress, decreased antioxidant production, and impaired oxidant-antioxidant balance have been reported in the aqueous humor.^{26–30} This may explain that hypoxia and oxidative stress occurring in the aqueous humor, that touches corneal endothelium, is similar to that seen in pseudoexfoliation and consequently, causes an additional cellular stress in the patients with IDA or combined IDA-B12DA, leading to endothelial injury.

Conclusions

In the present study, CCT, HEX, and the thicknesses of all RNFL and GC-IPL were significantly lower in both the anemic groups as compared to the control group. This means that hypoxia may influence endothelial functions in the patients with IDA and combined IDA-B12DA. This condition must be considered during diagnosis and monitoring of ocular diseases. However, more detailed and comprehensive studies are required on this topic.

Acknowledgments

Thanks to Mustafa Alparslan Babayigit, MD, for valuable contribution. This work was developed in Karabuk University, Training and Education Hospital, Karabuk, Turkey.

Disclosure: **M. Coskun**, None; **N.O. Sevencan**, None

References

- Lopez A, Cacoub P, Macdougall IC, Peyrin-Biroulet L. Iron deficiency anaemia. *Lancet*. 2016;387:907–916.
- World Health Organization. *Haemoglobin Concentrations for the Diagnosis of Anaemia and Assessment of Severity*. Geneva, Switzerland: World Health Organization; 2011.
- Cardoso MA, Augusto RA, Bortolini GA, et al. Effect of providing multiple micronutrients in powder through primary healthcare on anemia in young Brazilian children: a multicentre pragmatic controlled trial. *PLoS One*. 2016;11:e0151097.
- Toki Y, Ikuta K, Kawahara Y, et al. Reticulocyte hemoglobin equivalent as a potential marker for diagnosis of iron deficiency. *Int J Hematol*. 2017; 106:116–125.
- Charlot K, Antoine-Jonville S, Moeckesch B, et al. Cerebral and muscle microvascular oxygenation in children with sickle cell disease: influence of hematology, hemorheology and vasomotion. *Blood Cells Mol Dis*. 2017;65:23–28.
- Langan RC, Goodbred AJ. Vitamin B 12 deficiency: recognition and management. *Am Fam Physician*. 2017;96:384–389.
- Musso CG, Vilas M. Nefroprevención en el paciente muy anciano. *Revista Colombiana de Nefrología*. 2016;2:131–136.
- DeMaman AS, Homem JM, Lachat J-J. Early iron deficiency produces persistent damage to visual tracts in Wistar rats. *Nutritional Neurosci*. 2008;11:283–289.
- Youdim MB. Brain iron deficiency and excess; cognitive impairment and neurodegeneration with involvement of striatum and hippocampus. *Neurotoxicity Res*. 2008;14:45–56.
- Todorich B, Pasquini JM, Garcia CI, Paez PM, Connor JR. Oligodendrocytes and myelination: the role of iron. *Glia*. 2009;57:467–478.
- Coşkun M, İlhan Ö, İlhan N, et al. Changes in the cornea related to sickle cell disease: a pilot investigation. *Eur J Ophthalmol*. 2015;25:463–467.
- Simsek A, Tekin M, Bilen A, Karadag AS, Bucak IH, Turgut M. Evaluation of Choroidal Thickness in Children With Iron Deficiency Anemia. *Invest Ophthalmol Vis Sci*. 2016;57:5940–5944.
- Dupont WD, Plummer WD. Power and sample size calculations: a review and computer program. *Control Clin Trials*. 1990;11:116–128.
- Gonul S, Koktekir BE, Bakbak B, Gedik S. Comparison of the ganglion cell complex and retinal nerve fibre layer measurements using Fourier domain optical coherence tomography to detect ganglion cell loss in non-arteritic anterior ischaemic optic neuropathy. *Br J Ophthalmol*. 2013;97:1045–1050.
- Contreras I, Noval S, Rebolleda G, Muñoz-Negrete FJ. Follow-up of nonarteritic anterior ischemic optic neuropathy with optical coherence tomography. *Ophthalmology*. 2007;114:2338–2344.
- Contreras I, Rebolleda G, Noval S, Munoz-Negrete FJ. Optic disc evaluation by optical coherence tomography in nonarteritic anterior ischemic optic neuropathy. *Invest Ophthalmol Vis Sci*. 2007;48:4087–4092.
- Hood DC, Anderson S, Rouleau J, et al. Retinal nerve fiber structure versus visual field function in patients with ischemic optic neuropathy: a test of a linear model. *Ophthalmology*. 2008;115:904–910.
- Aksoy A, Aslan L, Aslankurt M, et al., eds. *Retinal Fiber Layer Thickness in Children With Thalassemia Major and Iron Deficiency Anemia. Seminars in Ophthalmology*. Taylor & Francis; 2014.
- Arifoglu HB, Gulhan A, Ozen M, et al. Demir Eksikliği Anemisi Olan Kadınlarda Peripapiller Retina Sinir Lifi Kalınlığı. *Türkiye Klinikleri J Ophthalmol*. 2016;25:153–157.
- American Academy of Ophthalmology. Corneal endothelial photography. *Ophthalmology*. 1991; 98:1464–1468.
- Kaye GI, Pappas GD, Donn A, Mallett N. Studies on the cornea: II. The uptake and transport of colloidal particles by the living rabbit cornea in vitro. *J Cell Biol*. 1962;12:481.
- Tufekci AB, Cevik SG, Parmak N, et al. Analysis of the cornea donor data: an eye bank study. *Eur Res J*. 2016;2:30.
- Pepose J, Ubels J. Cornea and sclera. *Adler's Physiology of the Eye*. 10th ed. St Louis, MO: Mosby; 2003:59–92.
- Ventura AS, Wälti R, Böhnke M. Corneal thickness and endothelial density before and after cataract surgery. *Br J Ophthalmol*. 2001;85:18–20.
- McCanna DJ, Driot J-Y, Hartsook R, Ward KW. Rabbit models of contact lens-associated corneal hypoxia: a review of the literature. *Eye Contact Lens*. 2008;34:160–165.
- Hayashi K, Manabe S-I, Yoshimura K, Kondo H. Corneal endothelial damage after cataract surgery in eyes with pseudoexfoliation syndrome. *J Cataract Refractive Surg*. 2013;39:881–887.

27. Beyazyıldız E, Çankaya AB, Beyazyıldız Ö, et al. Disturbed oxidant/antioxidant balance in aqueous humour of patients with exfoliation syndrome. *Jpn J Ophthalmol.* 2014;58:353–358.
28. Doğu B, Yüksel N, Çekmen MB, Çağlar Y. Aqueous humor and serum erythropoietin levels in patients with pseudoexfoliation syndrome and pseudoexfoliative glaucoma. *Int Ophthalmol.* 2010;30:669–674.
29. Erdurmuş M, Yağcı R, Atış Ö, Karadağ R, Akbaş A, Hepşen İF. Antioxidant status and oxidative stress in primary open angle glaucoma and pseudoexfoliative glaucoma. *Curr Eye Res.* 2011;36:713–718.
30. Anastasopoulos E, Founti P, Topouzis F. Update on pseudoexfoliation syndrome pathogenesis and associations with intraocular pressure, glaucoma and systemic diseases. *Curr Opin Ophthalmol.* 2015;26:82–89.