


Collagenous Gastritis: An Unusual Presentation With Tubular Shaped Stomach

Journal of Investigative Medicine High Impact Case Reports
Volume 8: 1–3
© 2020 American Federation for Medical Research
DOI: 10.1177/2324709620944695
journals.sagepub.com/home/hic


Nathaly Cortez, MD¹ , Manuel Berzosa, MD¹, Adam Jacobs, DO¹ , and Michael Bloom, MD¹

Abstract

Collagenous gastritis is a rare histopathologic entity that causes marked subepithelial collagen deposition in the gastric mucosa. Clinical presentation is diverse, considering only less than 100 cases have been reported. However, we report a unique case of isolated collagenous gastritis in a 71-year-old female who presented with a 6-month history of dyspepsia and 27 kg weight loss. Her endoscopic findings revealed a tubular shaped stomach with diffuse gastric mucosal atrophy, findings that differ with previous case reports of a cobblestone pattern. Treatment remains unclear.

Keywords

collagenous gastritis, stomach, dyspepsia, weight loss

Introduction

Collagenous gastritis (CG) is a rare histopathologic entity that involves marked subepithelial collagen deposition in the gastric mucosa.¹ The first case of CG was found in the gastric corpus and reported in 1989; since then, less than 100 cases have been reported.² Diagnosis requires high clinical suspicion and close communication with the pathologist, as ultimately this is a histopathologic diagnosis. Endoscopic findings of CG can be diverse such as mucosal erythema, nodularity, and ulceration. The clinical presentation varies from abdominal pain, weight loss, gastrointestinal bleeding, and dyspepsia.³

Case Presentation

A 71-year-old female with a long history of gastroesophageal reflux disease (GERD) and dyspepsia presented to the gastroenterology outpatient office with a 6-month history of worsening dyspeptic symptoms along with 27 kg weight loss and epigastric fullness associated with early satiety. Her dyspepsia was described as “intermittent epigastric spasms” predominantly after food ingestion. Her GERD had been controlled with proton pump inhibitors (PPIs) for the last 5 years. There was no history of alcohol, tobacco, or nonsteroidal anti-inflammatory drug use. Outside colonoscopy was unrevealing and esophagogastroduodenoscopy (EGD) showed chronic gastritis. Persistent symptoms led to further workup including upper gastrointestinal series, gastric emptying, and magnetic resonance imaging

enterography, all of which were negative for gastric outlet obstruction and small bowel strictures, but noted a tubular shaped stomach (Figure 1). The patient was referred to our institution for further evaluation. EGD with endoscopic ultrasound was done for further characterization of the stomach layers, revealing a tubular shaped gastric body with diffuse atrophic mucosa. Localized submucosal wall thickening was visualized endosonographically in the entire body of the stomach, measuring up to 5 mm in thickness of the gastric wall. Random gastric biopsies with hematoxylin and eosin staining and trichrome staining did not confirm the diagnosis of CG at that time but did reveal collagen deposition. Endoscopic ultrasound–fine needle biopsy was not performed because it was thought that random biopsies would reveal the final diagnosis in the setting of mucosal atrophy and thickening in the superficial “layer 3.”

After the procedure, the patient was recommended sucralfate and to have small frequent meals which mildly improve her symptoms. Numerous clinical studies were negative including complete blood count, complete metabolic panel, anti-transglutaminase immunoglobulin A, CA 19-9, and vitamin B₁₂. She had multiple admissions to the hospital for the

¹Mount Sinai Medical Center, Miami, FL, USA

Received June 8, 2020. Revised June 21, 2020. Accepted June 28, 2020.

Corresponding Author:

Nathaly Cortez, MD, Internal Medicine, Mount Sinai Medical Center, 4300 Alton Road, Miami Beach, FL 33140, USA.
Email: nathaly.cortez@msmc.com



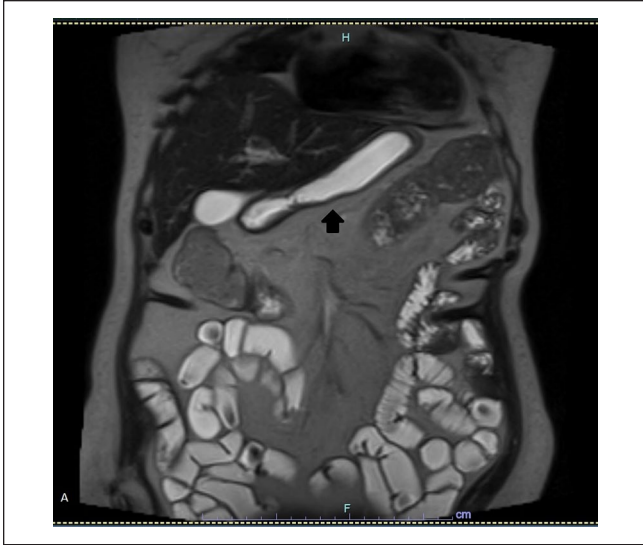


Figure 1. Magnetic resonance enterography showing tubular shaped stomach (arrow).

“intermittent epigastric spasms,” which later made her unable to tolerate food and return to the office with worsening of symptoms 8 months later. Repeat EGD with tunneled biopsies were taken from the gastric body and antrum revealing thickened subepithelial collagen layer on Masson Trichrome stain (Figure 2). Special stains for Crystal Violet and Congo Red were negative and failed to reveal evidence of amyloid deposition. These features were consistent with a diagnosis of CG. There was no evidence of collagen deposition in the small bowel or colon. She was started on budesonide therapy (9 mg/day). Follow-up 6 months later revealed significant clinical improvement.

Discussion

Isolated CG is extremely uncommon. It is defined by subepithelial collagen deposition of greater than 10 μm with associated inflammatory infiltrate and surface epithelial damage.³ There are several hypotheses for the pathogenesis of the disease, and it is thought that CG appears as a reparative response to chronic inflammation where collagen is released from subepithelial fibroblasts.¹⁻³ Multiple case reports and literature review describe some association between autoimmune diseases and CG, the most common being celiac disease.⁴⁻⁸

According to the published literature, the presentation is very diverse including abdominal pain, weight loss, gastrointestinal bleeding, dyspepsia, and gastric perforation as the most severe presentation reported.^{1,3,9,10} Diagnosis is very challenging as endoscopic findings can be very subtle. Our patient’s first EGD only revealed chronic inflammation. CG has been typically described with a cobblestone pattern reflected as patchy nodularity in the gastric mucosa more

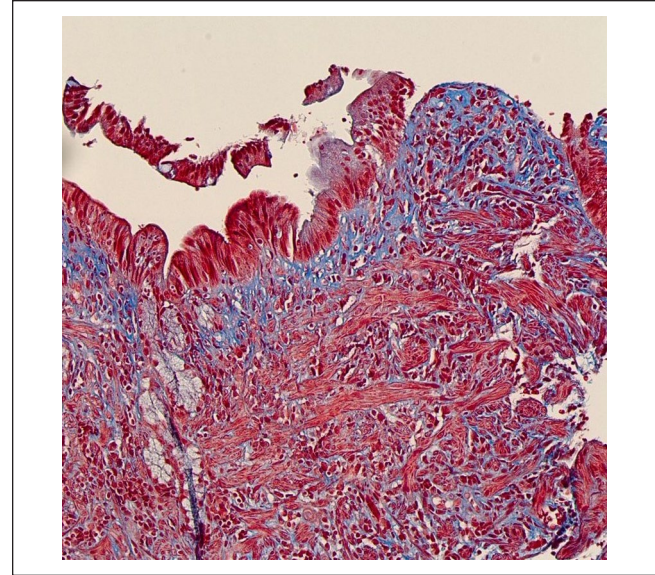


Figure 2. Histological section of gastric mucosa with thickened subepithelial collagen deposition highlighted by Masson trichrome stain (color blue).

predominant in the body and antrum.^{2,7} There are several case reports with normal gastric mucosa findings on EGD. Other classic but nonspecific endoscopic findings include mucosal erythema, erosions, or ulcers.¹¹ In our case, the patient had a “tubular shaped” gastric body resembling a gastric sleeve, which most likely was associated with the collagen deposition. As a result, she presented with early satiety and weight loss. This finding is unique since it has not been reported in the literature yet.

Endoscopic-guided biopsies remain the main diagnostic tool, as CG is a histopathological diagnosis. The literature reports that the collagen deposition is heterogeneous, and it tends to be found in the depressed areas between the nodularity. Like in our case, this can result in sampling error and delay diagnosis. There are also mucosal inflammatory infiltrates with lymphocytes, eosinophils, and plasma cells, mostly in the lamina propria.¹² Based on histopathological literature, CG has been further classified according to 3 different patterns of inflammation: lymphocytic gastritis-like pattern, an eosinophil-rich pattern, and an atrophic pattern.⁷ Our case revealed an atrophic pattern with atrophic antral glands with pyloric-type gland hyperplasia, and dense chronic inflammatory infiltrates within the lamina propria.

To date, no standard treatment has been identified. Multiple therapies have been used including PPIs, corticosteroids, sucralfate, histamine-2 receptor antagonists, and 5-aminosalicylates among others. Some case reports of patients with CG have had clinical improvement with budesonide, which had been used to treat collagenous deposition in the colon.¹²

In our case, we first attempted dietary changes, she was already on PPI, and sucralfate was added. Due to the progression of symptoms, the decision was made to treat with budesonide 9 mg daily with good clinical response, concordant with previous reports. A repeat EGD for biopsy has still not been performed.

Conclusion

Collagenous gastritis is a rare entity and the scarcity of information about this subject makes it difficult to understand its pathophysiological process. Due to the rarity of the disease, etiology and treatment have yet to be firmly established. We need to raise awareness and more documentation of this disease for better understanding in order to establish diagnostic criteria and standard therapy.

Authors' Note

This case was presented as an abstract/poster (P2683) with the title: "A Case of Collagenous Gastritis: A Rare Entity" at the American College of Gastroenterology (ACG) 2019 Annual Scientific Meeting; October 29, 2019; in San Antonio, TX.

Declaration of Conflicting Interests

The author(s) declared no potential conflicts of interest with respect to the research, authorship, and/or publication of this article.

Funding

The author(s) received no financial support for the research, authorship, and/or publication of this article.


Ethics Approval

Our institution does not require ethical approval for reporting individual cases or case series.

Informed Consent

Verbal informed consent was obtained from the patient for their anonymized information to be published in this article.

ORCID iDs

Nathaly Cortez  <https://orcid.org/0000-0001-9536-6061>
Adam Jacobs  <https://orcid.org/0000-0002-9732-9771>

References

1. Sharma P, Barbieri A, Masoud A. Collagenous gastritis: a case report and literature review. *J Nat Sci Biol Med.* 2018;9:285-287.
2. Colletti RB, Trainer TD. Collagenous gastritis. *Gastroenterology.* 1989;97:1552-1555.
3. Kamimura K, Kobayashi M, Sato Y, Aoyagi Y, Terai S. Collagenous gastritis: review. *World J Gastrointest Endosc.* 2015;7:265-273.
4. Ma C, Park JY, Montgomery EA, et al. A comparative clinicopathologic study of collagenous gastritis in children and adults: the same disorder with associated immune-mediated diseases. *Am J Surg Pathol.* 2015;39:802-812.
5. Amason T, Brown IS, Goldsmith JD, et al. Collagenous gastritis: a morphologic and immunohistochemical study of 40 patients. *Mod Pathol.* 2015;28:533-544.
6. Al-Kandari A, Al-Alardati H, Sayadi H, Al-Judaibi B, Mawardi M. An unusual case of collagenous gastritis in a middle-aged woman with systemic lupus erythromatosis: a case report. *J Med Case Reports.* 2014;8:278.
7. Vesoulis Z, Lozanski G, Ravichandran P, Esber E. Collagenous gastritis: a case report, morphologic evaluation, and review. *Mod Pathol.* 2000;13:591-596.
8. Stancu M, De Petris G, Palumbo TP, Lev R. Collagenous gastritis associated with lymphocytic gastritis and celiac disease. *Arch Pathol Lab Med.* 2001;125:1579-1584.
9. Appelman MH, de Meij TGJ, Neeffjes-Borst EA, Kneepkens CMF. Spontaneous gastric perforation in a case of collagenous gastritis. *APSP J Case Rep.* 2016;7:7.
10. Mandaliya R, DiMarino AJ, Abraham S, Burkart A, Cohen S. Collagenous gastritis a rare disorder in search of a disease. *Gastroenterol Res.* 2013;6:139-144.
11. Lagorce-Pages C, Fabiani B, Bouvier R, Scoazec JY, Durand L, Flejou JF. Collagenous gastritis: a report of six cases. *Am J Surg Pathol.* 2001;25:1174-1179.
12. Leung ST, Chandan VS, Murray JA, Wu TT. Collagenous gastritis: histopathologic features and association with other gastrointestinal diseases. *Am J Surg Pathol.* 009;33:788-798.