

Brain perfusion single photon emission computed tomography in major psychiatric disorders: From basics to clinical practice

Amburanjan Santra¹, Rakesh Kumar²

¹Department of Nuclear Medicine, Brain imaging Centre, Dakshi Diagnostics, Lucknow, Uttar Pradesh, ²Department of Nuclear Medicine, All India Institute of Medical Sciences, New Delhi, India

ABSTRACT

Brain single photon emission computed tomography (SPECT) is a well-established and reliable method to assess brain function through measurement of regional cerebral blood flow (rCBF). It can be used to define a patient's pathophysiological status when neurological or psychiatric symptoms cannot be explained by anatomical neuroimaging findings. Though there is ample evidence validating brain SPECT as a technique to track human behavior and correlating psychiatric disorders with dysfunction of specific brain regions, only few psychiatrists have adopted brain SPECT in routine clinical practice. It can be utilized to evaluate the involvement of brain regions in a particular patient, to individualize treatment on basis of SPECT findings, to monitor the treatment response and modify treatment, if necessary. In this article, we have reviewed the available studies in this regard from existing literature and tried to present the evidence for establishing the clinical role of brain SPECT in major psychiatric illnesses.

Keywords: Brain perfusion, psychiatric disorders, regional cerebral blood flow, single photon emission computed tomography

INTRODUCTION

Brain single photon emission computed tomography (SPECT) is a well-established and reliable method for evaluating brain function through measurement of regional cerebral blood flow (rCBF).^[1] It is being utilized for detection of various neurodegenerative diseases and their management for several years. Brain SPECT can be used to define a patient's pathological status when neurological or psychiatric symptoms cannot be explained by structural neuroimaging findings. Though there is ample evidence in the literature validating brain SPECT as a promising technique to track human behavior and correlating psychiatric disorders with dysfunction of specific brain regions, it is rarely utilized technique in routine psychiatric practice. Renowned medical bodies like the American College of

Radiology, the Society of Nuclear Medicine and the European Society of Nuclear Medicine have published evidence-based guidelines for using brain SPECT to improve patient care. Commonly accepted clinical indications for brain SPECT include: Dementia (early diagnosis, differentiation from normal ageing, and differential diagnosis of Alzheimer's disease from other neurodegenerative diseases), epilepsy (localization of epileptic focus by ictal and interictal studies), movement disorders, traumatic brain injury, cerebrovascular diseases, brain tumor and brain infections.^[2-4] Nearly two decades back, Holman and Devous in their study, highlighted brain SPECT as a powerful window into the function of the brain and asserted it as a promising tool which could become an important component of the routine clinical evaluation of patients with neurological and psychiatric diseases.^[5] A consistently growing body of research supports brain SPECT's clinical utility. In 1996, Vasile concluded that, the clinical utility of SPECT in neuropsychiatry is well-established.^[6] Camargo reviewed the utility of brain SPECT in 2001 and demonstrated its role in obsessive-compulsive disorder (OCD), Gilles de la Tourette's syndrome, schizophrenia, depression, panic disorder, and drug abuse, in addition to common neurological indications.^[7] However, despite the evidence relevant to diagnosis and treatment, only few psychiatrists have adopted brain SPECT or other functional neuroimaging techniques in

Access this article online

Quick Response Code:



Website:
www.ijnm.in

DOI:
10.4103/0972-3919.142622

Address for correspondence:

Dr. Amburanjan Santra, D/4E Souraniloy Housing Complex, 1 Kailash Ghosh Road, Kolkata - 700 008, West Bengal, India.
E-mail: dramburanjan@gmail.com

routine clinical practice. Brain SPECT can be utilized to evaluate the involvement of specific brain regions in different patients, to individualize the treatment, for monitoring the treatment response and to modify treatment, when warranted. Though specific perfusion patterns for various psychiatric diseases have not been definitely recognized, perfusion and receptor imaging findings may be used as an additional diagnostic tool to guide clinicians searching for a definitive diagnosis. In this review article we have tried to consolidate the facts from existing literature and our own clinical experience, as to the kind of role brain SPECT can play in different psychiatric diseases.

BRAIN PERFUSION SINGLE PHOTON EMISSION COMPUTED TOMOGRAPHY-TECHNICAL OVERVIEW

Radiopharmaceuticals

The tracers used for brain perfusion SPECT are technetium-99m-hexamethylpropyleneamineoxime (^{99m}Tc -HMPAO) and technetium-99m-ethylcysteinate dimer (^{99m}Tc -ECD). The main differences between ^{99m}Tc -HMPAO and ^{99m}Tc -ECD relate to their *in vitro* stability, uptake mechanism, and dosimetry.^[8-10] ^{99m}Tc -HMPAO is highly unstable *in vitro* and high radiochemical purity must be assured before injection.^[11] Stabilized forms of ^{99m}Tc -HMPAO allow easier labeling and improvement of image quality by reducing background activity.^[12] By contrast, ^{99m}Tc -ECD is stable up to at least 4 h *in vitro*, and freshly eluted ^{99m}Tc is not required. Higher gray-matter-to-white-matter ratio, contributes to the better image quality obtained with ^{99m}Tc -ECD. Although both of tracers are distributed proportionally to rCBF, their retention is not completely linear with rCBF because of an initial back diffusion. High blood flow may be underestimated and low blood flow may be overestimated with both tracers.^[13,14] In normal brain tissue, the kinetic properties are similar for both the perfusion agents. They enter the brain cells because of their lipophilic nature and remain there because of conversion into hydrophilic compounds. However, in patients with brain disease, the distribution of these compounds may differ because of the biochemistry of lipophilic-to-hydrophilic conversion. Although a metabolic process of de-esterification accounts for hydrophilic conversion of ^{99m}Tc -ECD, instability of the lipophilic form have been proposed for ^{99m}Tc -HMPAO. A perfusion-metabolic (de-esterification) coupling is needed in case of ^{99m}Tc -ECD to be trapped within cell, whereas only perfusion matters in ^{99m}Tc -HMPAO. Thus, ^{99m}Tc -ECD would have a predominant cellular-metabolic uptake, and ^{99m}Tc -HMPAO would reflect blood flow arrival to cerebral regions.^[15]

Patient preparation

Before arrival, patients should be instructed to avoid, if possible, caffeine, alcohol, or other drugs known to affect cerebral blood flow (CBF). Brain perfusion is sensitive to neuronal activities, hence, tracer injection to be done in a quiet room and no interaction with patients at this time is desirable, to avoid any sensorial and cognitive stimuli. To avoid head movement during

scanning (20-30 min), the patient should be comfortable and relaxed. The uncooperative patients (those with severe cognitive impairment or with loss of insight) may need sedation. Tracer injection must precede sedation to avoid sedation-induced blood flow changes. Appropriate positioning is needed to keep the collimators as close as possible to the patient's head and to get entire brain within the center of field of view.^[16,17]

Acquisition system and postprocessing software

Because of the small size of important anatomically and functionally independent cerebral structures, spatial resolution is the main concern in brain imaging. A good compromise is to fit a general purpose rotating camera with fan beam collimator. Addition of computed tomography scan improves the quality of images by attenuation correction and structural correlation. Software applications are available for image processing to quantify the results in terms of rCBF for each brain functional area. Many of them have the features to compare with normal population database and provide statistical parametric mapping, so that one can easily recognize the abnormally perfused area.^[16,17]

MAJOR PSYCHIATRIC DISORDERS AND BRAIN PERFUSION SINGLE PHOTON EMISSION COMPUTED TOMOGRAPHY

Attention deficit hyperactivity disorder

Attention deficit hyperactivity disorder (ADHD) is one of the most prevalent disorders in child and adolescent psychiatry. Prevalence of ADHD in the general population is approximately 5% of school-age children.^[18] ADHD is characterized by a developmentally inappropriate poor attention span or age-inappropriate features of hyperactivity and impulsivity or both. To meet the Diagnostic and Statistical Manual of Mental Disorders-IV (DSM-IV) diagnostic criteria, the disorder should be present for at least 6 months, cause impairment in academic or social functioning, and occur before the age of 7 years. ADHD appears to be heterogeneous, with a variety of known etiologies such as head trauma, intrauterine exposure to toxins, and infections, but in the majority of cases no etiology can be determined.^[19] A neurobiological basis of ADHD resulting from the involvement of the fronto-striatal system has been proposed.^[20] Several studies [Table 1] analyzed the patterns of rCBF in ADHD, demonstrating decreases in brain perfusion, especially in the premotor cortex and the prefrontal cortex, and hypoperfusion of striatal and periventricular structures.^[21-24] Daniel *et al.* found that, 65% of children and adolescents with ADHD revealed decreased perfusion in the prefrontal cortex with intellectual stress, though only 25% had decreased prefrontal lobe activity at rest.^[25] There is a pattern of lateralization in prefrontal hypoperfusion from right to left with increase in age of patients as demonstrated by a study.^[26] Many researcher demonstrated temporal lobe dysfunction as significant in patients with ADHD. Kaya *et al.* described temporal hypoperfusion being more frequent than in the frontal cortex.^[27] An association of temporal lobe hypoperfusion with severity of

symptoms and comorbidity have been demonstrated by some studies.^[27,28] Studies were also undertaken to demonstrate the response to methylphenidate treatment. Responders usually normalize the prefrontal hypoperfusion and may have increase or decrease in striatal perfusion.^[29,30] The nonresponders had significantly increased activity in anterior cingulate (AC) cortex at baseline.^[31] We observed both prefrontal and temporal hypoperfusion in all of the seven ADHD patients scanned in our center [Figure 1] and there is evidence of prefrontal activity normalization in available post therapy scans (four out of seven in a time period of 6-9 months) after successful treatment.

Obsessive-compulsive disorder

Obsessive-compulsive disorder is rare (5% of psychiatric patients), with a usually gradual onset in adolescence or early adult life and a slightly greater prevalence in females. Family history shows a high incidence in other members. Obsessions are imperative, distressing thoughts that persist despite the desire to resist them and may take various forms: Intellectual (phrases, rhymes, ideas, images), impulsive (killing, stabbing, performing abject acts), or inhibiting. Compulsions are acts that result from obsessions, such as checking rituals, repeated hand washing, and wiping objects. Brain SPECT findings in patients with OCD have been investigated by several authors [Table 2]. A study suggested involvement of prefrontal-striatal-thalamic and limbic circuitry in the pathophysiology of OCD.^[32] Hyperperfusion of the anterior portion of the cingulate gyrus; bilateral orbito-frontal regions; and in some patients, basal ganglia, before therapy has been described.^[33-35] These changes returned to normal after treatment

with fluoxetine.^[34,35] In contrast, hypoperfusion of the frontal lobes, right caudate nucleus, and right thalamus has also been found.^[36] Patients with poor insight on their condition or with schizo-obsessive behavior probably will display hypoperfusion of the frontal lobes, whereas patients with adequate insight tend to display hyperperfusion of frontal lobes and cingulate gyrus. Impulsive issues are often from low activity in the prefrontal cortex and compulsive tendencies are usually due to high activity in the anterior cingulate gyrus. In our patients, we observed hypoperfusion of prefrontal, temporal and AC cortex in majority, probably due to our study group, which comprises chronic patients under long term treatment [Figure 2]. Anterior cingulate cortex seems to be an important structure in the pathogenesis of OCD symptoms and anterior cingulotomy is an approach for symptomatic improvement.^[37] The patients having increased activity in frontal and AC cortex also respond well to selective serotonin reuptake inhibitors.^[38,39] There is possible role of brain SPECT in tracking hereditary OCD or predicting future development of OCD in offspring.^[40]

Schizophrenia

Schizophrenia comprises a group of closely related disorders characterized by a particular type of disordered affect, behavior, and thinking. Symptoms are usually categorized as positive (auditory, tactile, visual, or olfactory hallucinations; persecutory, grandiose, or religious delusions; aggressiveness; bizarre appearance; abnormal sexual behavior; disordered thoughts) or negative (poor eye contact, speech, or hygiene; inappropriate affect; blocking; apathy; social inattentiveness). Though there

Table 1: Review summary of brain perfusion studies in patients with ADHD

Author	Year	Study group	Brain SPECT tracer	Perfusion pattern (↓hypoperfusion, ↑hyperperfusion)
Our findings	-	ADHD-baseline and posttreatment	^{99m} Tc-HMPAO	↓B/L prefrontal (mainly orbito-frontal) ↓B/L medial temporal
Yeh <i>et al.</i>	2012	ADHD with developmental coordination disorder	^{99m} Tc-ECD	↓B/L frontal lobe, inferior parental lobe ↑Right posterior cingulate gyrus, anterior lobe of cerebellum
Gardner <i>et al.</i>	2009	ADHD with depression	^{99m} Tc-HMPAO	↓B/L cerebellum and ↑B/L frontal in "depression+ADHD" compared to "depression" only
Cho <i>et al.</i>	2007	ADHD-MPH responders versus nonresponders	^{99m} Tc-HMPAO	Nonresponders had ↑left anterior cingulate cortex, ↑left claustrum, ↑right anterior cingulate cortex, ↑right putamen and ↓right superior parietal lobule
Oner <i>et al.</i>	2005	ADHD in relation to age	^{99m} Tc-HMPAO	↑Prefrontal rCBF, lateralization from the right to the left side with age
Lee <i>et al.</i>	2005	ADHD-response to MPH	^{99m} Tc-HMPAO	Baseline-↓orbito-frontal, ↑somatosensory MPH response-normalization of above with ↓striatum activity
Lorberboym <i>et al.</i>	2004	ADHD with comorbid conditions	^{99m} Tc-ECD	↓Temporal lobe in comorbid type of ADHD
Kaya <i>et al.</i>	2002	ADHD	^{99m} Tc-HMPAO	↓Temporal cortex Hypoperfusion is inversely correlated with severity of disease
Kim <i>et al.</i>	2002	ADHD	^{99m} Tc-HMPAO	↓Right lateral prefrontal cortex, right middle temporal cortex, both orbital prefrontal cortex and both cerebellar cortices
Langleben <i>et al.</i>	2001	ADHD rCBF asymmetry	^{99m} Tc-ECD	The severe hyperactivity group exhibited left > right asymmetry in prefrontal and occipito-parietal area
Kim <i>et al.</i>	2001	ADHD-effect of MPH	^{99m} Tc-HMPAO	↑Left and right prefrontal areas, and caudate and thalamic areas after MPH treatment
Gustafsson <i>et al.</i>	2000	ADHD-association of rCBF with symptoms	^{99m} Tc-HMPAO	Disturbance of right frontal lobes related to behavior, integration of temporal, cerebellum and subcortical structures, related to motor planning and cognition
Amen <i>et al.</i>	1997	ADHD on intellectual stress	^{99m} Tc-HMPAO	↓Prefrontal cortex with intellectual stress

**SPECT: Single photon emission computed tomography, ADHD: Attention deficit hyperkinetic disorder, ^{99m}Tc-HMPAO: Technetium-99m-exametazine-hexamethylpropyleneamineoxime, ^{99m}Tc-ECD: Technetium-99m-ethylcysteinate dimer, MPH: Methylphenidate, rCBF: Regional cerebral blood flow, B/L: Bilateral

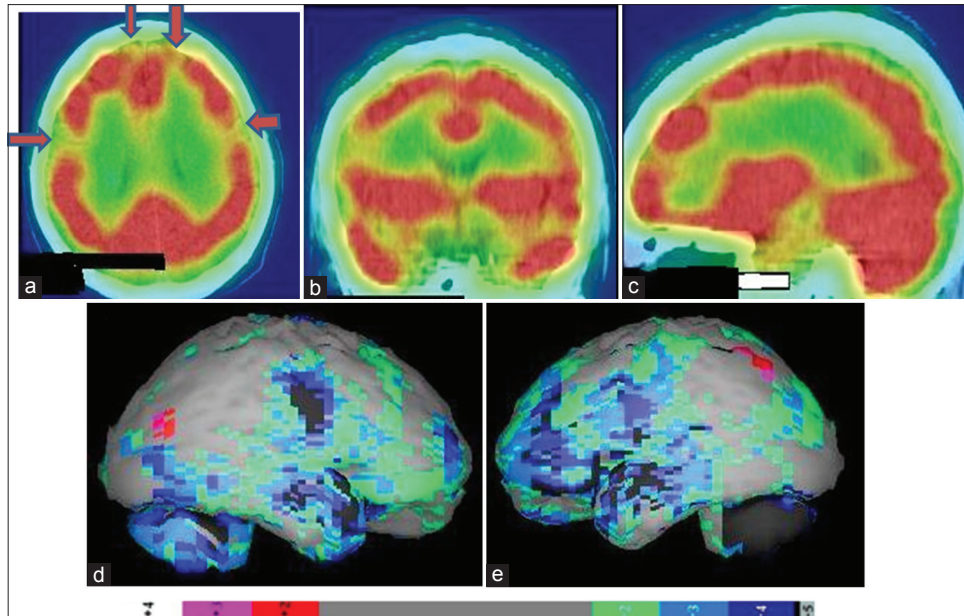


Figure 1: Technetium-99m-hexamethylpropyleneamineoxime brain perfusion single photon emission computed tomography-computed tomography (SPECT-CT) images of a 17 year old attention deficit hyperactivity disorder patient, showing hypoperfusion in bilateral frontal cortices and bilateral medial temporal lobes. (a) Transverse view, (b) sagittal view, (c) coronal view of the SPECT-CT, (d) right lateral, (e) left lateral surface projection views of “Neurogam” processed (compared with normal population adult database) images with color scale below (d and e)

Table 2: Review summary of important brain perfusion study findings in patients with OCD

Author	Year	Study group	Brain imaging	Perfusion pattern (↓hypoperfusion, ↑hyperperfusion)
Our findings	-	OCD on treatment	^{99m} Tc-HMPAO SPECT	↓Prefrontal and temporal bilaterally, ↓anterior cingulate cortex, also involvement of thalamus, basal ganglia and cerebellum noted
Karadağ <i>et al.</i>	2013	OCD response to SSRI	^{99m} Tc-HMPAO SPECT	SSRI normalized rCBF in the frontal region with bilaterally increased rCBF in the thalamus
Wen <i>et al.</i>	2012	OCD	SPECT	↑Basal ganglia and occipital lobe
Huysen <i>et al.</i>	2009	OCD	fMRI, MRS, SPECT	Involvement of prefrontal-striatal-thalamic and limbic circuitry
Oner <i>et al.</i>	2008	OCD versus ADHD	^{99m} Tc-HMPAO SPECT	↑Prefrontal rCBF in OCD subjects, significantly in right; ↓prefrontal in ADHD
Topçuoğlu <i>et al.</i>	2005	OCD	^{99m} Tc-HMPAO SPECT	↓Right basal ganglion
Castillo <i>et al.</i>	2005	OCD-rCBF/age relation	^{99m} Tc-HMPAO SPECT	Age and age of onset of OCD correlated with rCBF in the B/L superior frontal, and B/L parietal cortex
Diler <i>et al.</i>	2004	OCD	^{99m} Tc-HMPAO SPECT	↑B/L cingulate cortex and B/L dorsolateral prefrontal lobe
Chang <i>et al.</i>	2003	OCD and anterior cingulotomy	^{99m} Tc-HMPAO SPECT	Anterior cingulated cortex seems to be an important structure in the pathogenesis of OCD symptoms
Lacerda <i>et al.</i>	2003	OCD	^{99m} Tc-HMPAO SPECT	↑Right superior and inferior frontal cortex and B/L thalamus
Hoehn-Saric <i>et al.</i>	2001	OCD with depression	^{99m} Tc-HMPAO SPECT	Responders have ↑prefrontal regions (mostly left), ↑B/L cingulate and basal ganglia
Alptekin <i>et al.</i>	2001	OCD	^{99m} Tc-HMPAO SPECT	↑Right thalamus, left frontotemporal cortex and B/L Orbito-frontal cortex
Busatto <i>et al.</i>	2001	OCD-early and late onset	^{99m} Tc-ECD	Early-onset: ↓Left anterior cingulate and right orbito-frontal rCBF, and ↑right cerebellum, whereas late-onset: ↓Right orbitofrontal and ↑left precuneus
Busatto <i>et al.</i>	2000	OCD	^{99m} Tc-ECD	↓Right lateral orbito-frontal cortex, ↓left dorsal anterior cingulate cortex
Lucey <i>et al.</i>	1995	OCD	^{99m} Tc-HMPAO SPECT	↓B/L superior frontal cortex, right inferior frontal cortex, left temporal cortex, left parietal cortex, right caudate nucleus and right thalamus
Rubin <i>et al.</i>	1995	OCD	^{99m} Tc-HMPAO SPECT	↑Orbital frontal cortex, postero-frontal cortex, dorsal parietal cortex bilaterally, ↓caudate nucleus bilaterally
Harris <i>et al.</i>	1994	OCD	^{99m} Tc-HMPAO SPECT	↑Medial-frontal, right frontal cortex and cerebellum, ↓right visual association cortex

**SPECT: Single photon emission computed tomography, OCD: Obsessive-compulsive disorder, ^{99m}Tc-HMPAO: Technetium-99m-hexamethylpropyleneamineoxime, ^{99m}Tc-ECD: Technetium-99m-ethylcysteinate dimer, rCBF: Regional cerebral blood flow, SSRI: Selective serotonin reuptake inhibitor, fMRI: Functional magnetic resonance imaging, MRS: Magnetic resonance spectroscopy, ADHD: Attention deficit hyperkinetic disorder, B/L: Bilateral

is conflict among several studies [Table 3], brain SPECT most frequently shows hypofrontality, especially during a specific task; perfusion changes in the basal ganglia, possibly related to the use

of neuroleptic drugs; and temporal lobe hypoperfusion, usually on the left side and frequently associated with ipsilateral frontal lobe hypoperfusion^[41] [Figure 3]. However, patients who are not

receiving medication may show hyperfrontality and depending on positive or negative symptoms may show conflicting findings (hypo and hyperperfusion).^[42] Patients with positive symptoms have demonstrated increased precuneus activity.^[43] Hypofrontality and temporal hypoperfusion related with negative symptoms and aggression in schizophrenia.^[44-48] Studies on treatment response evaluation demonstrated improvement of blood flow in frontal, temporal, basal ganglia region with increased activity in motor cortex.^[49-52] Involvement of inferior parietal cortex, cuneus and posterior temporal lobe are noted in chronic and progressive disease.^[53] Injection of perfusion agents at the time of visual or auditory hallucinations shows hyperperfusion of the primary visual or auditory cortex, respectively.^[54] Cognitive activation also significantly increases frontal activity in schizophrenia cases.^[55] We have studied >50 patients of chronic schizophrenia and found significant hyperperfusion in prefrontal cortex mainly dorsolateral

prefrontal cortex, and orbitofrontal cortex (OFC), temporal lobe, mainly temporopolar and superior temporal cortex, and inferior parietal lobule. There was also involvement of basal ganglia in 50% cases with occasional involvement of cerebellum, and sometimes global hypoperfusion [Figure 4] in severe cases.

Anxiety and depression

Anxiety and depression are extremely common public health problems in today's world. The loss to our society from these illnesses is staggering: Individual pain, family strife, school and relationship failure, lost work productivity, and death. People actively seek out a cure for anxiety and depression, and are put on prescription medications that can harm them in other ways. Loss of interest or pleasure is the key symptom of depression. Other symptoms include feelings of hopelessness, worthlessness, and emotional pain; reduced energy and motivation; trouble sleeping;

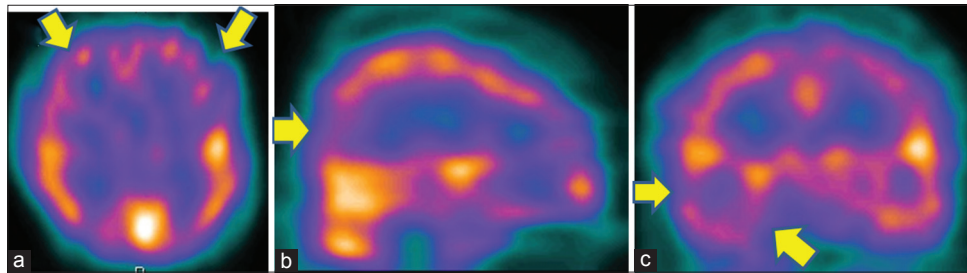


Figure 2: Technetium-99m-hexamethylpropyleneamineoxime brain perfusion single photon emission computed tomography (SPECT) in a 40-year-old male patient with obsessive-compulsive disorder revealed hyperperfusion in bilateral prefrontal cortices, with right temporal and occipital lobe. (a) Transverse view, (b) sagittal view, (c) coronal view of the SPECT images

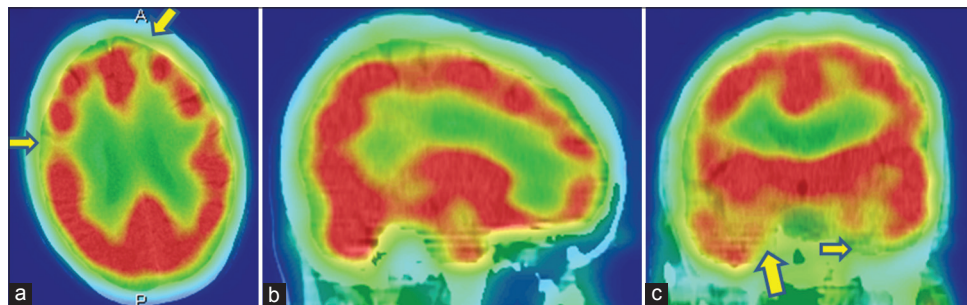


Figure 3: A 45-year-old female with paranoid schizophrenia on antipsychotic treatment have bilateral frontal, and temporal hypoperfusion in technetium-99m-hexamethylpropyleneamineoxime brain perfusion single photon emission computed tomography-computed tomography images. (a) Transverse view, (b) sagittal view, (c) coronal view

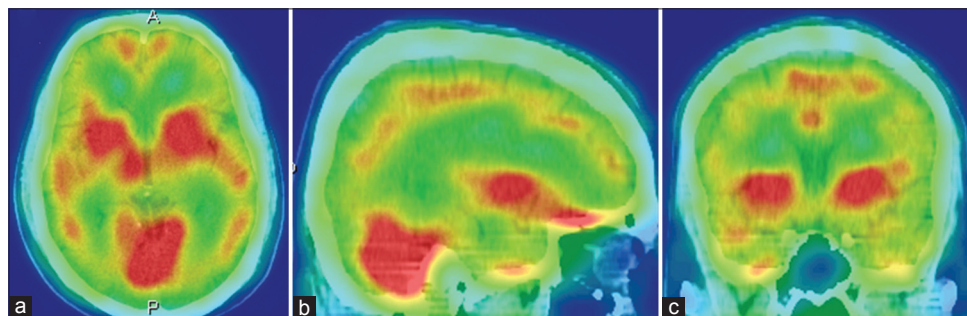


Figure 4: A 26-year-old male with disorganized schizophrenia was under treatment for last 1-year, showing global cortical hypoperfusion with relative increase in basal ganglia and cerebellar activity in technetium-99m-hexamethylpropyleneamineoxime brain perfusion single photon emission computed tomography-computed tomography images. (a) Transverse view, (b) sagittal view, (c) coronal view

Table 3: Review summary of important brain perfusion study findings in patients with schizophrenia

Author	Year	Study group	Imaging	Perfusion pattern (↓hypoperfusion, ↑hyperperfusion)
Our findings		Schizophrenia-chronic medicated	^{99m} Tc-HMPAO SPECT	↓Prefrontal cortex (DLPFC and OFC mainly) ↓Temporallobe (temporopolar and superior temporal mainly); ↓inferior parietal lobule Basal ganglia involvement in 50%, occasional involvement of cerebellum, may be global hypoperfusion in severe cases ↓Prefrontal cortex. OFC might play an important role in the development of severe negative symptoms
Kanahara <i>et al.</i>	2013	Schizophrenia-negative symptoms	SPECT	↓Precuneus activity
Faget-Agius <i>et al.</i>	2012	Schizophrenia with preserved insight	^{99m} Tc-ECD	
Tsujino <i>et al.</i>	2011	Very-late-onset schizophrenia with catatonia	SPECT	Baseline: ↓Striatum and the thalamus, ↑left lateral frontal and the left temporal cortex. After treatment, normalization, with ↑motor cortex
Hoptman <i>et al.</i>	2011	Aggression in schizophrenia	fMRI	Frontal and temporal abnormalities appear to be a consistent feature of aggression in schizophrenia
Wake <i>et al.</i>	2010	First-episode schizophrenia	^{99m} Tc-ECD	↓B/L temporal
Ertugrul <i>et al.</i>	2009	Effect of clozapine	SPECT, MRS	↑B/L frontal (superior and medial)/caudate perfusion ratios in treatment responders
Kanahara <i>et al.</i>	2009	Progression in schizophrenia	SPECT	First-episode-↓prefrontal cortex, anterior cingulate Chronic cases-↓inferior parietal cortex, posterior temporal lobe, and the cuneus
Zhao <i>et al.</i>	2006	Schizophrenia-negative symptom	SPECT	Negative symptom profile schizophrenia has ↓B/L frontal and ↓temporal lobe
Malhotra <i>et al.</i>	2006	Childhood onset schizophrenia	SPECT	↓Left temporal and frontal areas of the brain, no difference with adult onset schizophrenia
Kohno <i>et al.</i>	2006	BPRS and rCBF in schizophrenia	¹²³ I-IMP SPECT	BPRS score was positively correlated with rCBF in the left inferior temporal gyrus
Ortuno <i>et al.</i>	2006	Schizophrenia	^{99m} Tc-HMPAO SPECT	↑B/L prefrontal and right parietal
Novak <i>et al.</i>	2005	Schizophrenia-before and after symptoms	^{99m} Tc-ECD	Baseline: ↓Dorsolateral frontal (left > right). ↑Dorsolateral frontal bilaterally after 10 weeks of antipsychotic medication
Moreno-Iñiguez <i>et al.</i>	2005	Schizophrenia	SPECT	Negative symptoms: ↓Frontal lobe Positive symptoms: ↑Left-frontal blood flow
Suzuki <i>et al.</i>	2005	Simple schizophrenia	SPECT	Prefrontal hypoperfusion
Li <i>et al.</i>	2005	Schizophrenia	SPECT	Negative symptoms negatively correlated left frontal rCBF. Improved memory correlated with ↑rCBF in the left temporal lobe
Sharafi <i>et al.</i>	2005	Schizophrenia, before and after clozapine	^{99m} Tc-ECD	Before treatment, hypofrontality was the most common (85%) finding, whereas after treatment hypofrontality was mostly cleared
Wang <i>et al.</i>	2003	Negative symptoms in schizophrenia	SPECT	Negatively correlated with B/L hypofrontality, mainly left orbital frontal and B/L superior frontal
Gonul <i>et al.</i>	2003	Schizophrenics with deficit and nondeficit syndrome	^{99m} Tc-HMPAO SPECT	The deficit subgroup-↓frontal bilaterally, right parietal and right superior temporal. No significant abnormality in non-deficit schizophrenics
Puri <i>et al.</i>	2001	Schizophrenia with religious delusion	^{99m} Tc-HMPAO SPECT	Left temporal over activation and ↓occipital uptake, particularly on the left
Vaiva <i>et al.</i>	2000	Schizophrenics with deficit and nondeficit syndrome	^{99m} Tc-HMPAO SPECT	Deficit group showed ↓B/L fronto-dorsolateral cortex compared with the nondeficit group
Yildiz <i>et al.</i>	2000	Schizophrenia effects of neuroleptics	SPECT	Baseline: ↓Left temporal lobe No significant difference after medication
Toone <i>et al.</i>	2000	Schizophrenia-cognitive activation	SPECT	Substantial increase in rCBF, particularly in the frontal region

** SPECT: Single photon emission computed tomography, ^{99m}Tc-HMPAO: Technetium-99m-hexamethylpropyleneamineoxime, ^{99m}Tc-ECD: Technetium-99m-ethylcysteinatedimer, rCBF: Regional cerebral blood flow, DLPFC: Dorsolateral prefrontal cortex, OFC: Orbito-frontal cortex, fMRI: Functional magnetic resonance imaging, MRS: Magnetic resonance spectroscopy, IMP: Iodomethyltyrosine, BPRS: Brief psychiatric rating scale, B/L: Bilateral

decreased appetite; and weight loss.^[56] Brain SPECT with perfusion agents in patients free of medication has shown hypoperfusion of the following areas: The prefrontal area and temporal lobes, cingulate gyrus, and left caudate nucleus.^[57-59] There is evidence of prefrontal, limbic, and paralimbic hypoperfusion in both unipolar and bipolar depression,^[60] and the lateral frontal area involvement in acute depression in the elderly.^[61] Hypofrontality was shown to be associated with severe negative symptoms^[62] [Figure 5]. In many occasions, both anxiety and depression coexist. Increased activity in the basal ganglia and frontal lobe may be seen in

patients with anxiety [Figure 6]. Severity of depression is inversely correlated with rCBF in left cingulate cortex, lentiform nucleus, and parahippocampal gyrus, and directly correlated with right posterolateral parietal cortex. Anxiety directly correlated with right anterolateral OFC, while cognitive performance correlated with right posteromedial OFC and left lentiform nucleus.^[63,64] Cognitive decline in postmenopausal women is also associated with hypofrontality.^[65] In major depressive disorders, sadness is related to decrease activity in dorsolateral prefrontal and dorsal cingulate cortex, with increased activity in ventromedial

prefrontal and ventral cingulated cortex; whereas anxiety is associated with left AC cortex.^[66] Whole brain blood flow also correlated positively with anxiety.^[67] When recurrent depressions progressed to melancholies, involvement of left posterior parieto-temporal region is seen in addition to hypofrontality.^[68] Findings of brain SPECT in anxiety depression disorders from different studies are summarized in Table 4.

Substance abuse and addiction

Psychoactive substance abuse and dependence are disorders defined by patterns of maladaptive behavior related to the procurement and ingestion of substances of abuse (marijuana, hallucinogens, inhalants, cocaine, crack, heroin, stimulants, alcohol, and others).^[69] Short and long-term substance abuse affects blood flow and metabolism, which negatively affect the way our central nervous system works [Table 5]. Fortunately, some researchers report that the damage associated with chronic use of alcohol, nicotine, inhalants, and solvents is at least partially reversible with de-addiction treatment. Brain SPECT, has shown disseminated CBF defects in abusers of cocaine, crack, heroin and alcohol.^[70-75] [Figures 7 and 8].

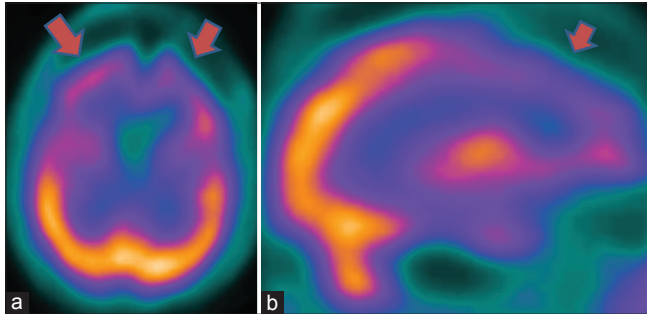


Figure 5: A 62-year-old female with severe depression, showing severe bilateral hypofrontality in technetium-99m-hexamethylpropyleneamineoxime brain perfusion single photon emission computed tomography (SPECT). (a) Transaxial and (b) sagittal view brain SPECT of the patient

Disappearance or improvement of the defects after a period of abstinence has been described, suggesting that arterial spasms may cause the defects.^[70,71,74,75] Some studies in cocaine abusers described abnormality in the OFC and superior temporal cortex, with evidence of minute differences between men and women.^[76,77] Patients with a history of inhalation of industrial solvents, such as glue, paint, and gasoline, have similar perfusion abnormalities.^[78]

Autism spectrum disorders

Autism spectrum disorders (ASD) are diagnosed today more than ever before. It has incidence rate of 2-5/10,000 births, males 1.5 times more commonly affected than females. This disorder is an early and severe development disorder, characterized by deficits in verbal and nonverbal languages, social skills, cognitive functioning and abnormal repetition of behavior (DSM-III R criteria). All children, teens, and adults with ASD are individuals and have unique brain patterns-one size does not fit all when it comes to ASD. Though SPECT studies are normal in many of the autism patients, it may show decreased temporal lobe perfusion. Up to 30% of autistic children eventually develop temporal lobe epilepsy.^[79] A study by Degirmenci *et al.* suggested the existence of regional brain perfusion alterations in frontal, temporal, and parietal cortex and in caudate nucleus in autistic children and in their first-degree family member.^[80]

SINGLE PHOTON EMISSION COMPUTED TOMOGRAPHY TO PERSONALISE TREATMENT IN PSYCHIATRIC DISORDERS

When brain SPECT scans detect the hyperfrontality pattern, it opens new avenues for intervention since this finding has been associated with predicting a positive treatment response to serotonergic medications in depression^[38,81-83] and OCD,^[84,85]

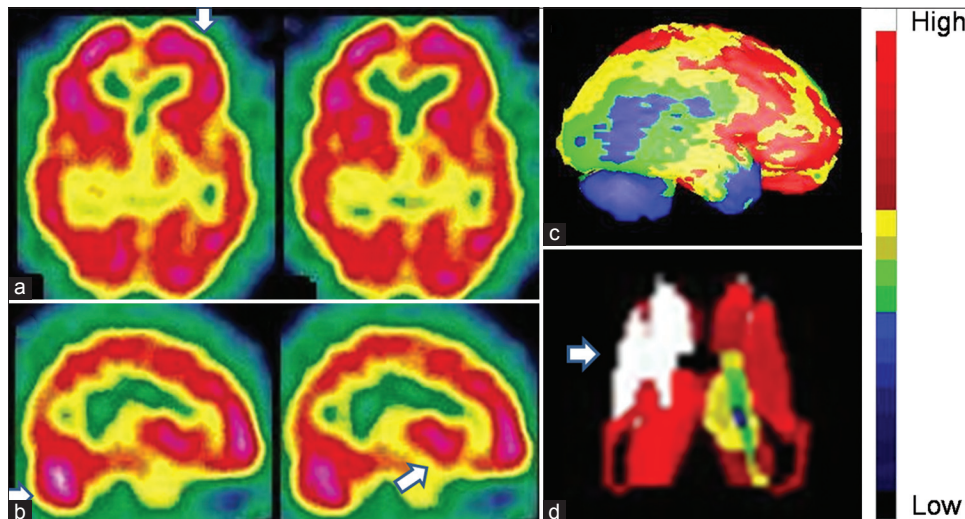


Figure 6: An 18-year-old male with severe anxiety neurosis revealed hyperactive prefrontal cortices and basal ganglia in technetium-99m-hexamethylpropyleneamineoxime brain perfusion single photon emission computed tomography images. (a) Transverse view, (b) sagittal view, (c) right lateral view of three-dimensional Talairach cortical perfusion report, (d) extracted basal ganglia and thalamus by "Neurogam" processing, (e) color scale for (c) and (d)

Table 4: Summary of important brain perfusion study findings in patients suffering from anxiety-depression disorder

Author	Year	Study group	Perfusion pattern (↓hypoperfusion, ↑hyperperfusion)
Kim <i>et al.</i>	2008	Depression in CKD	Negatively correlated with rCBF in the right insula, posterior cingulate gyrus, and left superior temporal gyrus Positively correlated with rCBF in the left fusiform gyrus ↓Frontal CBF related to cognitive decline
Yao <i>et al.</i>	2008	Depression in postmenopausal women	
Perico <i>et al.</i>	2004	Major depressive disorder	Depression inversely correlated with rCBF in left cingulate, lentiform nucleus, and parahippocampalgyrus, and directly correlated with right postero-lateral parietal cortex; anxiety directly correlated with right anterolateral orbito-frontal cortex, while cognitive performance correlated with right postero-medial orbito-frontal cortex and left lentiform nucleus
Carey <i>et al.</i>	2004	Anxiety disorder with citalopram	Responders had deactivation in left precentral, right mid and inferior frontal, left prefrontal and right precuneus
Gillin <i>et al.</i>	2001	Sleep deprivation as antidepressant treatment	Sleep deprivation normalizes hyperactive areas in orbital medial prefrontal cortex, and ventral anterior cingulate cortex
Brody <i>et al.</i>	2001	Major depressive disorder-symptom correlation	Sadness-↓DLPFC and dorsal AC, and ↑VMPFC and ventral AC (2) psychomotor retardation-↓left prefrontal activity (3) anxiety-↑left AC activity (4) impaired episodic memory-↓left prefrontal and medial temporal (5) attention deficit-↓right prefrontal and parietal
Fernández-Argüelles <i>et al.</i>	1998	Recurrent depression	↓B/L prefrontal and/or left posterior parietotemporal side
Lucey <i>et al.</i>	1997	Anxiety, panic, depression, PTSD	melancholies had ↓left posterior parietotemporal Whole brain blood flow correlated positively with anxiety, depression/ PTSD correlated negatively with B/L caudate rCBF
Philpot <i>et al.</i>	1993	Late life depression	↓Cortico-cerebellar ratios of tracer uptake in B/L parietal, left temporal and left occipital

**SPECT: Single photon emission computed tomography, ^{99m}Tc-HMPAO: Technetium-99m-hexamethyl propylene amine oxime, ^{99m}Tc-ECD: Technetium-99m-ethylcysteinate dimer, rCBF: Regional cerebral blood flow, DLPFC: Dorsolateral prefrontal cortex, VMPFC: Ventromedial prefrontal cortex, AC: Anterior cingulate, B/L: Bilateral, PTSD: Posttraumatic stress disorder, CKD: Chronic kidney disease, CBF: Cerebral blood flow

Table 5: Summary of important brain perfusion study findings in patients suffering from substance abuse disorders

Author	Year	Study group	Imaging	Perfusion pattern (↓hypoperfusion, ↑hyperperfusion)
Our findings	-	Multiple drug abuse	^{99m} Tc-HMPAO SPECT	Global hypoperfusion with diffuse involvement of cortical and subcortical structures
Jordaan <i>et al.</i>	2012, 2010	Alcohol-induced psychotic disorder	SPECT	Reversible generalized cerebral dysfunction in AIPD
Adinoff <i>et al.</i>	2012	Cocaine addicted	SPECT	↓Left caudolateral OFC, ↓left superior temporal cortex
Nehlig <i>et al.</i>	2010	Caffeine	SPECT	Generalized perfusion decrease low consumers displayed bilaterally ↑in inferior frontal, insular, left parietal cortex, and cerebellum; high consumers have ↑only in hypothalamus
Etchebehere <i>et al.</i>	2010	Multiple drug abuse	^{99m} Tc-HMPAO SPECT	Generalized cortical hypoperfusion. The younger the patients, the more regions of hypoperfusion are noted
Chung <i>et al.</i>	2009	Alcohol-related dementia	^{99m} Tc-ECD	Hypoperfusion in both cortical and subcortical regions
Pach <i>et al.</i>	2007	Alcohol dependence	^{99m} Tc-ECD	↓Frontal, temporal, basal ganglia, occipital inferior region, parietal superior
Botelho <i>et al.</i>	2006	Heroin abusers	^{99m} Tc-HMPAO SPECT	↓Global brain perfusion, more significant in the frontal (OFC), occipital and temporal lobes
Adinoff <i>et al.</i>	2006	Cocaine – sex difference	^{99m} Tc-HMPAO SPECT	↓B/L OFC in cocaine-dependent men and ↓medial OFC in cocaine-dependent women
Demir <i>et al.</i>	2002	Alcoholism-early and late onset	^{99m} Tc-HMPAO SPECT	Early onset-↓left superior frontal region while the late onset-↓B/L superior frontal regions
Gottschalk <i>et al.</i>	2002	Combined alcohol and cocaine	^{99m} Tc-ECD	↓Occipital and temporal cortex or cerebellum and ↑more likely in frontal and parietal cortex
Kucuk <i>et al.</i>	2000	Long term inhalant use	^{99m} Tc-HMPAO	Brain SPECT showed non-homogeneous uptake and hypoperfusion areas
Earnst <i>et al.</i>	2000	Abstinent cocaine abuser	^{99m} Tc-HMPAO	↑Frontal white matter and in the globus pallidus, and ↓putamen and temporal cortex
Gansler <i>et al.</i>	2000	Abstinent alcoholics	^{99m} Tc-HMPAO	Frontal brain abnormalities in alcoholics may subside with extended abstinence

**SPECT: Single photon emission computed tomography, ^{99m}Tc-HMPAO: Technetium-99m-exametazime-hexamethyl propyleneamineoxime, ^{99m}Tc-ECD: Technetium-99m-ethylcysteinate dimer, rCBF: Regional cerebral blood flow, DLPFC: Dorsolateral prefrontal cortex, OFC: Orbito-frontal cortex, AIPD: Alcohol induced psychotic disorder, DLPFC: Dorsolateral prefrontal cortex, B/L: Bilateral

predicting a positive response to sleep deprivation^[86,87] and repetitive transcranial magnetic stimulation^[88] for depression, predicting treatment response to a cingulotomy in OCD,^[89] and

help in distinguishing OCD from ADHD.^[90] Hypofrontality, that is, decreased perfusion or activity in the prefrontal cortex, is another important brain SPECT finding that is often helpful

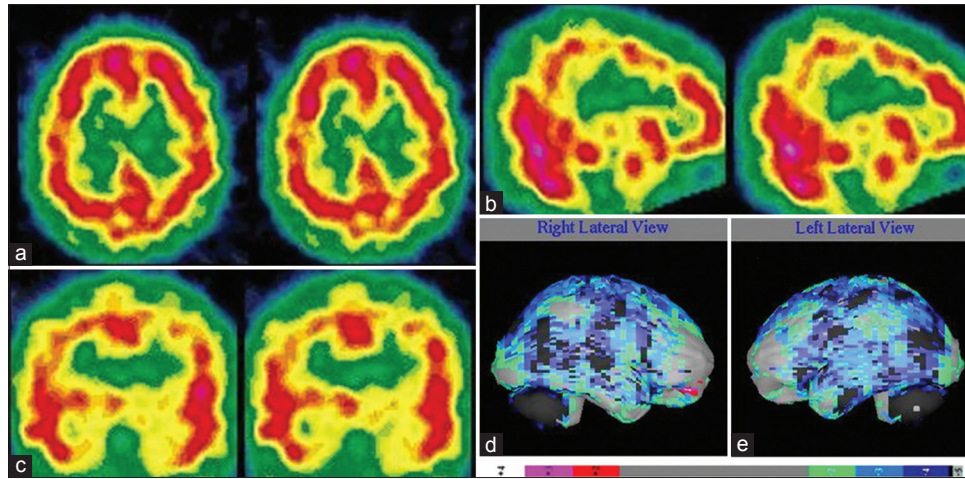


Figure 7: A 19-year-old female with multiple substance abuse disorder (predominantly alcohol and organic solvent) with induced-withdrawal behavioral problem showing diffuse cortical hypoperfusion on both side of cerebral cortex. (a) Transverse view, (b) sagittal view, (c) coronal view of technetium-99m-hexamethylpropyleneamineoxime brain single photon emission computed tomography, (d) right lateral, (e) left lateral surface projection views of "Neurogam" processed (compared with normal population adult database) images with color scale below (d and e)

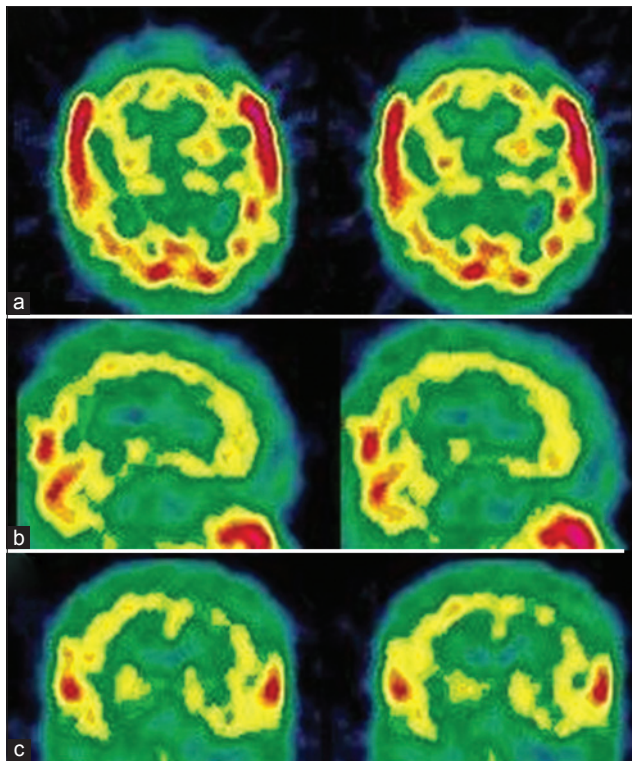


Figure 8: A 41-year-old male with multiple substance abuse disorder with significant decline in social and occupational performance showing severely decreased cortical perfusion globally. (a) Transverse view, (b) sagittal view, (c) coronal view of technetium-99m-hexamethylpropyleneamineoxime brain single photon emission computed tomography

in understanding and targeting treatment in individual patients. Hypofrontality is associated with a negative response to serotonergic medication in depression^[91] and clozapine in schizophrenia^[92] as well as with predicting relapse in alcoholics,^[93] improved response to acetylcholine-esterase inhibitors for memory and behavior in AD,^[94,95] predicting a poor response to ketamine in fibromyalgia patients^[96] and improved response

to stimulants in patients with ADHD symptoms during a concentration challenge.^[97] Hypofrontality is also associated with antisocial symptoms, impulsive behaviors, and murder^[98] as well as with completed suicide, which is often an impulsive act.^[99] When hypofrontality is present in depressed patients, it is important to be vigilant in their care, as well as involve family support, as they may be less likely to respond to typical antidepressant medications and they may not have the cognitive resources to follow through with recommendations.^[100] When abnormalities in the temporal lobes are seen (either hypo or hyperperfusion) and mood instability or temper problems are present, anticonvulsants provide a rational treatment option.^[101] If there are memory or learning issues (and low temporal lobe perfusion), acetylcholine-esterase inhibitors may be helpful,^[102] always taking into consideration the clinical picture.

CONCLUSIONS

Brain perfusion SPECT is a valuable tool in management of psychiatric disorders. It has a role in the diagnosis, therapeutic management, and follow-up of these patients. In addition, brain SPECT is a useful tool for research, because it is widely available and provides noninvasive *in vivo* assessment of human brain function. We can use this tool in psychiatric practice to evaluate the involvement of brain regions in a patient for a particular clinical condition, can individualize the treatment on basis of brain SPECT findings, can monitor the treatment response and modify the treatment, if necessary. There are a number of important areas where brain SPECT has the potential to provide relevant information to help personalize treatment to patients' specific brain system pathophysiology rather than rely solely on general diagnostic and/or therapeutic categories. Brain SPECT should always be evaluated in conjunction with clinical assessment since it adds value to routine clinical assessment.

REFERENCES

- Catafau AM, Parellada E, Lomeña F, Bernardo M, Pavia J, Ros D, *et al*. Baseline, visual deprivation and visual stimulation 99Tc^m-HMPAO-related changes in visual cortex can be detected with a single-head SPET system. *Nucl Med Commun* 1996;17:480-4.
- ACR Guidelines and Standards Committee. ACR-SPR Practice Guideline for the Performance of Single Photon Emission Computed Tomography (SPECT) Brain Perfusion and for Brain Death Examinations. Practice Guideline Revised; 2012, Resolution 25. p. 1-11.
- Juni JE, Waxman AD, Devous MD, Tikofsky RS, Ichise M, Van Heertum RL *et al*. Society of Nuclear Medicine Procedure Guideline for Brain Perfusion Single Photon Emission Computed Tomography (SPECT) Using Tc-99m Radiopharmaceuticals, Version 2.0. Society of Nuclear Medicine Procedure Guidelines Manual; June, 2002. p. 113-8.
- Kapucu OL, Nobili F, Varrone A, Boojij J, Vander Borgh T, Nägren K, *et al*. EANM procedure guideline for brain perfusion SPECT using 99mTc-labelled radiopharmaceuticals, version 2. *Eur J Nucl Med Mol Imaging* 2009;36:2093-102.
- Holman BL, Devous MD Sr. Functional brain SPECT: The emergence of a powerful clinical method. *J Nucl Med* 1992;33:1888-904.
- Vasile RG. Single photon emission computed tomography in psychiatry: Current perspectives. *Harv Rev Psychiatry* 1996;4:27-38.
- Camargo EE. Brain SPECT in neurology and psychiatry. *J Nucl Med* 2001;42:611-23.
- Neirinckx RD, Canning LR, Piper IM, Nowotnik DP, Pickett RD, Holmes RA, *et al*. Technetium-99m d,l-HM-PAO: A new radiopharmaceutical for SPECT imaging of regional cerebral blood perfusion. *J Nucl Med* 1987;28:191-202.
- Vallabhajosula S, Zimmerman RE, Picard M, Stritzke P, Mena I, Hellman RS, *et al*. Technetium-99m ECD: A new brain imaging agent: *In vivo* kinetics and biodistribution studies in normal human subjects. *J Nucl Med* 1989;30:599-604.
- Nakamura K, Tukatani Y, Kubo A, Hashimoto S, Terayama Y, Amano T, *et al*. The behavior of 99mTc-hexamethylpropyleneamineoxime (99mTc-HMPAO) in blood and brain. *Eur J Nucl Med* 1989;15:100-7.
- Piera C, Martínez A, Ramírez I. Radiochemical purity of technetium-99m-HMPAO depends on specific activity. *J Nucl Med* 1995;36:706.
- Barthel H, Kämpfer I, Seese A, Dannenberg C, Kluge R, Burchert W, *et al*. Improvement of brain SPECT by stabilization of Tc-99m-HMPAO with methylene blue or cobalt chloride. Comparison with Tc-99m-ECD. *Nuklearmedizin* 1999;38:80-4.
- Lassen NA, Andersen R, Friberg L, Paulson OB. The retention of [99mTc]-d,l-HM-PAO in the human brain after intracarotid bolus injection: A kinetic analysis. *J Cereb Blood Flow Metab* 1988;8 Suppl 1:S13-22.
- Friberg L, Andersen AR, Lassen NA, Holm S, Dam M. Retention of 99mTc-bicisate in the human brain after intracarotid injection. *J Cereb Blood Flow Metab* 1994;14 Suppl 1:S19-27.
- Koyama M, Kawashima R, Ito H, Ono S, Sato K, Goto R, *et al*. SPECT imaging of normal subjects with technetium-99m-HMPAO and technetium-99m-ECD. *J Nucl Med* 1997;38:587-92.
- Juni JE, Waxman AD, Devous MD, Tikofsky RS, Ichise M, Van Heertum RL *et al*. Procedure guideline for brain perfusion SPECT Using 99mTc Radiopharmaceuticals 3.0. *J Nucl Med Technol* 2009; 37:191-5.
- Catafau AM. Brain SPECT in clinical practice. Part I: Perfusion. *J Nucl Med* 2001;42:259-71.
- Szatmari P, Offort DR, Boyle MH. Ontario child health study; prevalence of attention deficit disorder with hyperactivity. *J Child Psychol Psychiatry* 1989;30:219-30.
- American Psychiatric Association. Diagnostic and statistical manual of mental disorders: DSM-IV [Internet]. 4th ed. Washington (DC): American Psychiatric Association; 1994. p. 866. Available from: <http://www.psychiatryonline.com/DSMPDF/dsm-iv.pdf>, last accessed on 03/07/2014.
- Laufer MW, Denhoff E. Hyperkinetic behavior syndrome in children. *J Pediatr* 1957;50:463-74.
- Zametkin AJ, Nordahl TE, Gross M, King AC, Semple WE, Rumsey J, *et al*. Cerebral glucose metabolism in adults with hyperactivity of childhood onset. *N Engl J Med* 1990;323:1361-6.
- Zametkin AJ, Liebenauer LL, Fitzgerald GA, King AC, Minkunas DV, Herscovitch P, *et al*. Brain metabolism in teenagers with attention-deficit hyperactivity disorder. *Arch Gen Psychiatry* 1993;50:333-40.
- Lou HC, Henriksen L, Bruhn P, Börner H, Nielsen JB. Striatal dysfunction in attention deficit and hyperkinetic disorder. *Arch Neurol* 1989;46:48-52.
- Zametkin AJ, Liotta W. The neurobiology of attention-deficit/hyperactivity disorder. *J Clin Psychiatry* 1998;59 Suppl 7:17-23.
- Daniel G, Amen MD, Blake D, Carmichael, high-resolution brain SPECT imaging in ADHD. *Ann Clin Psychiatry* 1997;9:81-6.
- Oner O, Oner P, Aysev A, Küçük O, Ibis E. Regional cerebral blood flow in children with ADHD: Changes with age. *Brain Dev* 2005;27:279-85.
- Kaya GC, Pekcanlar A, Bekis R, Ada E, Miral S, Emiroglu N, *et al*. Technetium-99m HMPAO brain SPECT in children with attention deficit hyperactivity disorder. *Ann Nucl Med* 2002;16:527-31.
- Lorberboym M, Waternberg N, Nissenkorn A, Nir B, Lerman-Sagie T. Technetium 99m ethylcysteinate dimer single-photon emission computed tomography (SPECT) during intellectual stress test in children and adolescents with pure versus comorbid attention-deficit hyperactivity disorder (ADHD). *J Child Neurol* 2004;19:91-6.
- Kim BN, Lee JS, Cho SC, Lee DS. Methylphenidate increased regional cerebral blood flow in subjects with attention deficit/hyperactivity disorder. *Yonsei Med J* 2001;42:19-29.
- Lee JS, Kim BN, Kang E, Lee DS, Kim YK, Chung JK, *et al*. Regional cerebral blood flow in children with attention deficit hyperactivity disorder: Comparison before and after methylphenidate treatment. *Hum Brain Mapp* 2005;24:157-64.
- Cho SC, Hwang JW, Kim BN, Lee HY, Kim HW, Lee JS, *et al*. The relationship between regional cerebral blood flow and response to methylphenidate in children with attention-deficit hyperactivity disorder: Comparison between non-responders to methylphenidate and responders. *J Psychiatr Res* 2007;41:459-65.
- Huysen C, Veltman DJ, de Haan E, Boer F. Paediatric obsessive-compulsive disorder, a neurodevelopmental disorder? Evidence from neuroimaging. *Neurosci Biobehav Rev* 2009;33:818-30.
- Machlin SR, Harris GJ, Pearson GD, Hoehn-Saric R, Jeffery P, Camargo EE. Elevated medial-frontal cerebral blood flow in obsessive-compulsive patients: A SPECT study. *Am J Psychiatry* 1991;148:1240-2.
- Hoehn-Saric R, Pearson GD, Harris GJ, Machlin SR, Camargo EE. Effects of fluoxetine on regional cerebral blood flow in obsessive-compulsive patients. *Am J Psychiatry* 1991;148:1243-5.
- Hoehn-Saric R, Harris GJ, Pearson GD, Cox CS, Machlin SR, Camargo EE. A fluoxetine-induced frontal lobe syndrome in an obsessive compulsive patient. *J Clin Psychiatry* 1991;52:131-3.
- Lucey JV, Costa DC, Blanes T, Busatto GF, Pilowsky LS, Takei N, *et al*. Regional cerebral blood flow in obsessive-compulsive disordered patients at rest. Differential correlates with obsessive-compulsive and anxious-avoidant dimensions. *Br J Psychiatry* 1995;167:629-34.
- Chang JW, Kim CH, Lee JD, Chung SS. Single photon emission computed tomography imaging in obsessive-compulsive disorder and for stereotactic bilateral anterior cingulotomy. *Neurosurg Clin N Am* 2003;14:237-50.
- Hoehn-Saric R, Schlaepfer TE, Greenberg BD, McLeod DR, Pearson GD, Wong SH. Cerebral blood flow in obsessive-compulsive patients with major depression: Effect of treatment with sertraline or desipramine on treatment responders and non-responders. *Psychiatry Res* 2001;108:89-100.
- Karadag F, Kalkan Oguzhanoglu N, Yüksel D, Kiraç S, Cura C, Ozdel O, *et al*. The comparison of pre-and post-treatment (99m) Tc HMPAO brain SPECT images in patients with obsessive-compulsive disorder. *Psychiatry Res* 2013;213:169-77.
- Santra A, Thukral RK. Brain perfusion single photon emission computed tomography with (99m) Tc-hexamethylpropyleneamineoxime in hereditary obsessive compulsive disorder. *Indian J Nucl Med* 2013;28:256-7.
- Woods SW. Regional cerebral blood flow imaging with SPECT in psychiatric disease: Focus on schizophrenia, anxiety disorders, and substance abuse. *J Clin Psychiatry* 1992;53 Suppl: 20-5.
- Sabri O, Erkwow R, Schreckenberger M, Owega A, Sass H, Buell U. Correlation of positive symptoms exclusively to hyperperfusion or hypoperfusion of cerebral cortex in never-treated schizophrenics. *Lancet* 1997;349:1735-9.
- Faget-Agius C, Boyer L, Padovani R, Richieri R, Mundler O, Lançon C, *et al*. Schizophrenia with preserved insight is associated with increased perfusion of the precuneus. *J Psychiatry Neurosci* 2012;37:297-304.

44. Hoptman MJ, Antonius D. Neuroimaging correlates of aggression in schizophrenia: An update. *Curr Opin Psychiatry* 2011;24:100-6.
45. Zhao J, He X, Liu Z, Yang D. The effects of clozapine on cognitive function and regional cerebral blood flow in the negative symptom profile schizophrenia. *Int J Psychiatry Med* 2006;36:171-81.
46. Moreno-Iñiguez M, Ortuño F, Arbizu J, Millán M, Soutullo C, Cervera-Enguix S. Regional cerebral blood flow SPECT study, at rest and during Wisconsin Card Sorting Test (WCST) performance, in schizophrenia naïve patients or treated with atypical neuroleptics. *Actas Esp Psiquiatr* 2005;33:343-51.
47. Li X, Tang J, Wu Z, Zhao G, Liu C, George MS. SPECT study of Chinese schizophrenic patients suggests that cerebral hypoperfusion and laterality exist in different ethnic groups. *World J Biol Psychiatry* 2005;6:98-106.
48. Wang CS, Yang YK, Chen M, Chiu NT, Yeh TL, Lee IH. Negative symptoms and regional cerebral blood flow in patients with schizophrenia: A single photon emission computed tomography study. *Kaohsiung J Med Sci* 2003;19:464-9.
49. Tsujino N, Nemoto T, Yamaguchi T, Katagiri N, Tohgi N, Ikeda R, *et al*. Cerebral blood flow changes in very-late-onset schizophrenia-like psychosis with catatonia before and after successful treatment. *Psychiatry Clin Neurosci* 2011;65:600-3.
50. Ertugrul A, Volkan-Salanci B, Basar K, Karli Oguz K, Demir B, Ergun EL, *et al*. The effect of clozapine on regional cerebral blood flow and brain metabolite ratios in schizophrenia: Relationship with treatment response. *Psychiatry Res* 2009;174:121-9.
51. Novak B, Milcinski M, Grmek M, Kocmur M. Early effects of treatment on regional cerebral blood flow in first episode schizophrenia patients evaluated with ^{99m}Tc-ECD-SPECT. *Neuro Endocrinol Lett* 2005;26:685-9.
52. Sharafi M. Comparison of Classical and Clozapine Treatment on Schizophrenia Using Positive and Negative Syndrome Scale of Schizophrenia (PANSS) and SPECT Imaging. *Int J Med Sci* 2005;2:79-86.
53. Kanahara N, Shimizu E, Sekine Y, Uchida Y, Shibuya T, Yamanaka H, *et al*. Does hypofrontality expand to global brain area in progression of schizophrenia?: A cross-sectional study between first-episode and chronic schizophrenia. *Prog Neuropsychopharmacol Biol Psychiatry* 2009;33:410-5.
54. Musalek M, Podreka I, Walter H, Suess E, Passweg V, Nutzinger D, *et al*. Regional brain function in hallucinations: A study of regional cerebral blood flow with ^{99m}Tc-HMPAO-SPECT in patients with auditory hallucinations, tactile hallucinations, and normal controls. *Compr Psychiatry* 1989;30:99-108.
55. Toone BK, Okocha CI, Sivakumar K, Syed GM. Changes in regional cerebral blood flow due to cognitive activation among patients with schizophrenia. *Br J Psychiatry* 2000;177:222-8.
56. Kaplan HI, Sadock BJ. *Synopsis of Psychiatry*. 6th ed. Baltimore, MD: Williams and Wilkins; 1991. p. 278-84, 363-82.
57. Devous MD Sr. Comparison of SPECT applications in neurology and psychiatry. *J Clin Psychiatry* 1992;53 Suppl:13-9.
58. Mayberg HS, Jeffery PJ, Wagner HN, Simpson SG. Regional cerebral blood flow in patients with refractory unipolar depression measured with Tc-99m HMPAO SPECT. *J Nucl Med* 1991;32 Suppl:951. [Abstract].
59. Van Heertum RL, O'Connell RA. Functional brain imaging in the evaluation of psychiatric illness. *Semin Nucl Med* 1991;21:24-39.
60. Ito H, Kawashima R, Awata S, Ono S, Sato K, Goto R, *et al*. Hypoperfusion in the limbic system and prefrontal cortex in depression: SPECT with anatomic standardization technique. *J Nucl Med* 1996;37:410-4.
61. Vasile RG, Schwartz RB, Garada B, Holman BL, Alpert M, Davidson PB, *et al*. Focal cerebral perfusion defects demonstrated by ^{99m}Tc-hexamethylpropyleneamine oxime SPECT in elderly depressed patients. *Psychiatry Res* 1996;67:59-70.
62. Galynker II, Cai J, Ongseng F, Finestone H, Dutta E, Sersen D. Hypofrontality and negative symptoms in major depressive disorder. *J Nucl Med* 1998;39:608-12.
63. Périco CA, Skaf CR, Yamada A, Duran F, Buchpiguel CA, Castro CC, *et al*. Relationship between regional cerebral blood flow and separate symptom clusters of major depression: A single photon emission computed tomography study using statistical parametric mapping. *Neurosci Lett* 2005;384:265-70.
64. Kim SJ, Song SH, Kim JH, Kwak IS. Statistical parametric mapping analysis of the relationship between regional cerebral blood flow and symptom clusters of the depressive mood in patients with pre-dialytic chronic kidney disease. *Ann Nucl Med* 2008;22:201-6.
65. Yao WJ, Pan HA, Yang YK, Chou YH, Wang ST, Yu CY, *et al*. Reduced frontal perfusion in depressed postmenopausal women: A SPECT study with WCST. *Maturitas* 2008;59:83-90.
66. Brody AL, Barsom MW, Bota RG, Saxena S. Prefrontal-subcortical and limbic circuit mediation of major depressive disorder. *Semin Clin Neuropsychiatry* 2001;6:102-12.
67. Lucey JV, Costa DC, Adshad G, Deahl M, Busatto G, Gacinovic S, *et al*. Brain blood flow in anxiety disorders. OCD, panic disorder with agoraphobia, and post-traumatic stress disorder on ^{99m}TcHMPAO single photon emission tomography (SPET). *Br J Psychiatry* 1997;171:346-50.
68. Fernández-Argüelles P, Castro Montaña J, García López O, Cambil Molina T. SPECT study of a group of patients with severe recurrent depression. *Actas Luso Esp Neurol Psiquiatr Cienc Afines* 1998;26:223-32.
69. Holman BL, Carvalho PA, Mendelson J, Teoh SK, Nardin R, Hallgring E, *et al*. Brain perfusion is abnormal in cocaine-dependent polydrug users: A study using technetium-99m-HMPAO and ASPECT. *J Nucl Med* 1991;32:1206-10.
70. Botelho MF, Relvas JS, Abrantes M, Cunha MJ, Marques TR, Rovira E, *et al*. Brain blood flow SPET imaging in heroin abusers. *Ann N Y Acad Sci* 2006;1074:466-77.
71. Jordaan GP, Warwick JM, Nel DG, Hewlett R, Emsley R. Alcohol-induced psychotic disorder: Brain perfusion and psychopathology-before and after anti-psychotic treatment. *Metab Brain Dis* 2012;27:67-77.
72. Jordaan GP, Warwick JM, Hewlett R, Emsley R. Resting brain perfusion in alcohol-induced psychotic disorder: A comparison in patients with alcohol dependence, schizophrenia and healthy controls. *Prog Neuropsychopharmacol Biol Psychiatry* 2010;34:479-85.
73. Chung YA, Choi SW, Joe KH, Jeong J, Cheon Y, Kim DJ. Regional cerebral blood flow in patients with alcohol-related dementia: A SPECT study. *Int J Neurosci* 2009;119:2100-11.
74. Holman BL, Mendelson J, Garada B, Teoh SK, Hallgring E, Johnson KA, *et al*. Regional cerebral blood flow improves with treatment in chronic cocaine polydrug users. *J Nucl Med* 1993;34:723-7.
75. Miller BL, Mena I, Giombetti R, Villanueva-Meyer J, Djenderedjian AH. Neuropsychiatric effects of cocaine: SPECT measurements. *J Addict Dis* 1992;11:47-58.
76. Adinoff B, Braud J, Devous MD, Harris TS. Caudolateral orbitofrontal regional cerebral blood flow is decreased in abstinent cocaine-addicted subjects in two separate cohorts. *Addict Biol* 2012;17:1001-12.
77. Adinoff B, Williams MJ, Best SE, Harris TS, Chandler P, Devous MD Sr. Sex differences in medial and lateral orbitofrontal cortex hypoperfusion in cocaine-dependent men and women. *Gen D* 2006;3:206-22.
78. Küçük NO, Kiliç EO, Ibis E, Aysev A, Gençoglu EA, Aras G, *et al*. Brain SPECT findings in long-term inhalant abuse. *Nucl Med Commun* 2000;21:769-73.
79. Lele RD. *Principles and practice of nuclear medicine and correlative medical imaging*. 1st ed. New Delhi: Jaypee Brothers Medical Publishers Pvt. Ltd.; 2009. p. 175.
80. Degirmenci B, Miral S, Kaya GC, Iyilikçi L, Arslan G, Baykara A, *et al*. Technetium-99m HMPAO brain SPECT in autistic children and their families. *Psychiatry Res* 2008;162:236-43.
81. Mayberg HS, Brannan SK, Mahurin RK, Jerabek PA, Brickman JS, Tekell JL, *et al*. Cingulate function in depression: A potential predictor of treatment response. *Neuroreport* 1997;8:1057-61.
82. Seminowicz DA, Mayberg HS, McIntosh AR, Goldapple K, Kennedy S, Segal Z, *et al*. Limbic-frontal circuitry in major depression: A path modeling metanalysis. *Neuroimage* 2004;22:409-18.
83. Mayberg HS, Brannan SK, Tekell JL, Silva JA, Mahurin RK, McGinnis S, *et al*. Regional metabolic effects of fluoxetine in major depression: Serial changes and relationship to clinical response. *Biol Psychiatry* 2000;48:830-43.
84. Saxena S, Brody AL, Maidment KM, Smith EC, Zohrabi N, Katz E, *et al*. Cerebral glucose metabolism in obsessive-compulsive hoarding. *Am J Psychiatry* 2004;161:1038-48.
85. Diler RS, Kibar M, Avci A. Pharmacotherapy and regional cerebral blood flow in children with obsessive compulsive disorder. *Yonsei Med J* 2004;45:90-9.
86. Wu JC, Gillin JC, Buchsbaum MS, Schacht C, Darnall LA, Keator DB, *et al*. Sleep deprivation PET correlations of Hamilton symptom improvement ratings with changes in relative glucose metabolism in patients with depression. *J Affect Disord* 2008;107:181-6.
87. Wu J, Buchsbaum MS, Gillin JC, Tang C, Cadwell S, Wiegand M, *et al*.

- Prediction of antidepressant effects of sleep deprivation by metabolic rates in the ventral anterior cingulate and medial prefrontal cortex. *Am J Psychiatry* 1999;156:1149-58.
88. Langguth B, Wiegand R, Kharraz A, Landgrebe M, Marienhagen J, Frick U, *et al.* Pre-treatment anterior cingulate activity as a predictor of antidepressant response to repetitive transcranial magnetic stimulation (rTMS). *Neuro Endocrinol Lett* 2007;28:633-8.
 89. Dougherty DD, Weiss AP, Cosgrove GR, Alpert NM, Cassem EH, Nierenberg AA, *et al.* Cerebral metabolic correlates as potential predictors of response to anterior cingulotomy for treatment of major depression. *J Neurosurg* 2003;99:1010-7.
 90. Oner P, Oner O, Aysev A, Küçük O, Ibis E. Comparison of cerebral blood flow in children with obsessive compulsive disorder and attention deficit hyperactivity disorder. *Türk Psikiyatri Derg* 2008;19:13-8.
 91. Brockmann H, Zobel A, Joe A, Biermann K, Scheef L, Schuhmacher A, *et al.* The value of HMPAO SPECT in predicting treatment response to citalopram in patients with major depression. *Psychiatry Res* 2009;173:107-12.
 92. Molina Rodríguez V, Montz André R, Pérez Castejón MJ, Capdevila García E, Carreras Delgado JL, Rubia Vila FJ. SPECT study of regional cerebral perfusion in neuroleptic-resistant schizophrenic patients who responded or did not respond to clozapine. *Am J Psychiatry* 1996; 153:1343-6.
 93. Noël X, Sferrazza R, Van Der Linden M, Paternot J, Verhas M, Hanak C, *et al.* Contribution of frontal cerebral blood flow measured by (99m) Tc-Bicisate spect and executive function deficits to predicting treatment outcome in alcohol-dependent patients. *Alcohol Alcohol* 2002;37:347-54.
 94. Kanetaka H, Hanyu H, Hirao K, Shimizu S, Sato T, Akai T, *et al.* Prediction of response to donepezil in Alzheimer's disease: Combined MRI analysis of the substantia innominata and SPECT measurement of cerebral perfusion. *Nucl Med Commun* 2008;29:568-73.
 95. Mega MS, Dinov ID, Lee L, O'Connor SM, Masterman DM, Wilen B, *et al.* Orbital and dorsolateral frontal perfusion defect associated with behavioral response to cholinesterase inhibitor therapy in Alzheimer's disease. *J Neuropsychiatry Clin Neurosci* 2000;12:209-18.
 96. Guedj E, Camilleri S, Colavolpe C, Taieb D, de Laforte C, Niboyet J, *et al.* Predictive value of brain perfusion SPECT for ketamine response in hyperalgesic fibromyalgia. *Eur J Nucl Med Mol Imaging* 2007;34:1274-9.
 97. Amen DG, Hanks C, Prunella J. Predicting positive and negative treatment responses to stimulants with brain SPECT imaging. *J Psychoactive Drugs* 2008;40:131-8.
 98. Goethals I, Audenaert K, Jacobs F, Van den Eynde F, Bernagie K, Kolindou A, *et al.* Brain perfusion SPECT in impulsivity-related personality disorders. *Behav Brain Res* 2005;157:187-92.
 99. Amen DG, Hanks C, Prunella JR, Green A. An analysis of regional cerebral blood flow in impulsive murderers using single photon emission computed tomography. *J Neuropsychiatry Clin Neurosci* 2007;19:304-9.
 100. Amen DG, Prunella JR, Fallon JH, Amen B, Hanks C. A comparative analysis of completed suicide using high resolution brain SPECT imaging. *J Neuropsychiatry Clin Neurosci* 2009;21:430-9.
 101. Gescher DM, Malevani J. Mood stabilizer in the psychopharmacotherapy of borderline personality disorder. *Fortschr Neurol Psychiatr* 2009;77:389-98.
 102. Freo U, Pizzolato G, Dam M, Ori C, Battistin L. A short review of cognitive and functional neuroimaging studies of cholinergic drugs: Implications for therapeutic potentials. *J Neural Transm* 2002;109:857-70.

How to cite this article: Santra A, Kumar R. Brain perfusion single photon emission computed tomography in major psychiatric disorders: From basics to clinical practice. *Indian J Nucl Med* 2014;29:210-21.

Source of Support: Nil. **Conflict of Interest:** None declared.

Author Help: Online submission of the manuscripts

Articles can be submitted online from <http://www.journalonweb.com>. For online submission, the articles should be prepared in two files (first page file and article file). Images should be submitted separately.

1) First Page File:

Prepare the title page, covering letter, acknowledgement etc. using a word processor program. All information related to your identity should be included here. Use text/rtf/doc/pdf files. Do not zip the files.

2) Article File:

The main text of the article, beginning with the Abstract to References (including tables) should be in this file. Do not include any information (such as acknowledgement, your names in page headers etc.) in this file. Use text/rtf/doc/pdf files. Do not zip the files. Limit the file size to 1 MB. Do not incorporate images in the file. If file size is large, graphs can be submitted separately as images, without their being incorporated in the article file. This will reduce the size of the file.

3) Images:

Submit good quality color images. Each image should be less than 4 MB in size. The size of the image can be reduced by decreasing the actual height and width of the images (keep up to about 6 inches and up to about 1800 x 1200 pixels). JPEG is the most suitable file format. The image quality should be good enough to judge the scientific value of the image. For the purpose of printing, always retain a good quality, high resolution image. This high resolution image should be sent to the editorial office at the time of sending a revised article.

4) Legends:

Legends for the figures/images should be included at the end of the article file.