

THREE DIFFERENT PRESENTATION OF SAME PATHOPHYSIOLOGY

AlGherbawe Mushtak¹, Fahmi Yousef Khan², Baidaa AlDehwe³, Ahmed Abdulrahman Al-Ani⁴

Department of medicine, Hamad General Hospital, Doha, Qatar¹

Department of medicine, Hamad General Hospital, Doha-Qatar²

Alwakrha primary health center, Doha, Qatar³

Department of medicine, Hamad General Hospital, Doha, Qatar⁴

Corresponding author: Al-Gherbawe Mushtak, MD, FRCP, Consultant Internal Medicine, Department of Medicine, Hamad general Hospital, Doha, Qatar, E-mail: amushtak@hotmail.com, PO Box 3050, Tel: 0097455220486, Fax 009744392273

Case report

ABSTRACT

We report three male patients of younger age group presented with acute vein thrombosis of different sites, right lower limb, cortical venous sinuses thrombosis with cerebral vascular accident and third case is mesenteric vein thrombosis. All patients were Vegetarian, had low level of cobalamin with marked hyper

homocysteinemia with normal serum and red cell folic acid. The low Cobalamin level was not suspected secondary to pernicious anemia, based on the fact that there was no evidence of atrophic gastritis and an absence of antiparietal cell antibodies. There were no evident of immobilization, recent surgery, malignancy, antiphospholipid antibody, myeloproliferative disorder, and hormone replacement therapy.

No deficiencies in protein C, protein S, or antithrombin III, normal factor V Leiden, no prothrombin gene mutation 20210A and no clone for paroxysmal nocturnal hemoglobinuria were detected, no cause was found for the thrombosis apart from their secondary hyperhomocysteinemia.

Key words: Homocysteine, Cobalamin deficiency, venous thrombosis.

1. INTRODUCTION

Hyper homocysteinemia is a risk factor for arterial and venous thrombosis. It is asserted that in deficiency of vitamin B12 will increase thrombotic incidences due to increase in homocysteine and upon substituting the vitamin, this risk decreases (1). However, this situation is not clear and there are a lot of conflict views.

2. THE CASES:

First Patient:

28 year old male Nepalese patient presented with swelling and pain of his right lower limb of four days durations, there were no history of trauma or such problem before, no mouth or genital ulcer, skin rash, no family history. Examination revealed that his chest and heart and abdomen were normal, his lower limb was erythematic and tender of both the calf and the thigh with difference of about 4 cm in comparison to the left side, ultra sound Doppler of the right lower limb showed

acute thrombosis involve the femoral, popliteal and the posterior tibial veins, His hemoglobin and MCV were normal while his B12 level was low 98 pmol/L normal (133-675) and very high level of homocysteine of 94 umol/L normal (4-12) after treatment with cobalamin his homocysteine level drop to less than ten.

Second patient:

29 year old Indian presented with sever headache and vomiting of one day duration, the headache was sever not associated with fever, the second day the patient had paralysis of the right side of the body, there were no fever, diplopia, incontinence. On examination was fully conscious oriented with right side upper motor neuron facial palsy with flaccid upper and lower limb with power of grade one and bilateral papilledema. His computed tomography with angiography, revealed venous sinus thrombosis along superior sagittal sinus and transverse sinuses with secondary hemorrhagic infarction more on the left side (Figure 1). His

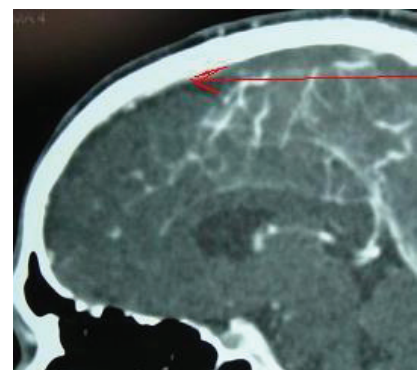

Figure 1. Venous sinus thrombosis along superior sagittal sinus and transverse sinuses with secondary hemorrhagic infarction more on the left side

Hemoglobin is 15.2 gm/dl and MCV of 106fl and peripheral smear showed macrocytosis with hyper segmented neutrophil, His vitamin 12 level of 92 pmol/L normal (133-675) and homocysteine level of 44.6 umol/L normal (4-12), with treatment his homocysteine level drop to 12.

Third patient:

32 year old Nepali presented with abdominal pain and vomiting of 4 day duration, there were no fever or

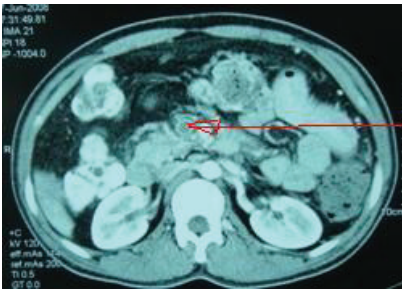


Figure 2. Portal vein, superior mesenteric, splenic vein thrombosis

diarrhea, his abdominal exam revealed tenderness all over abdomen with normal bowel sound. Computed tomography showed Portal vein, superior mesenteric, splenic vein thrombosis (Figure 2). His Hemoglobin is 11.2 gm/dl and MCV of 110fl and peripheral smear showed macroovalocytes red cell with hyper segmented neutrophil, His vitamin 12 less than 44 pmol/L normal (133-675) and homocysteine level of 54.4 umol/L normal (4-12), with treatment his homocysteine level drop to 10 and Cobalamin increase to 362.

Further history revealed all patients were Vegans due to religious issues and all had poor socio economic state, admitted to a profound aversion to most foods and textures, including meat, and avoided all but a limited diet since early childhood.

3. DISCUSSION

The prevalence of hyperhomocysteinemia in the general population is estimated to be approximately 1%, although it may vary from area to area (2). It could be caused by both genetic and acquired conditions, including folate and cobalamin deficiency (3).

Homocysteine is metabolized by one of two divergent pathways: one of them is remethylation in which homocysteine produces methionine, this reaction is catalyzed by methionine synthase, cobalamin is the precursor of methylcobalamin, which is the cofactor for methionine synthase (Figure 3).

Although studies demonstrated that hyperhomocysteinemia is an independent risk factor for premature arteriosclerotic disease in the coronary, cerebral, and peripheral arteries (4, 5), but there a lot of conflict regarding venous thrombosis, in spite of that recent meta-analyses support the notion that hyperhomocysteinemia is an independent risk factor for venous thrombosis (6, 7). Brattström et al. (8) found no sig-

ficancy and all are poor with low socioeconomic state, vegans for religious cause and their diet were deficient in meat and other B12 source like egg, milk etc. The vitamin B12 deficiency seen in our patient was considered not to be pernicious anemia, based on the fact that there was no evidence of atrophic gastritis and an absence of antiparietal cell antibodies.

In conclusion we think homocysteine is independent risk factor for deep venous thrombosis in patient with cobalamin deficiency, especially vegetarian and this may related to other associated factor which we have to look for.

Conflict of interest: none declared

REFERENCES

1. Remacha AF, Souto JC, Ramila E, Perea G, Sarda MP, Fontcuberta J. Enhanced risk of thrombotic disease in patients with acquired vitamin B12 and/or folate deficiency: role of hyperhomocysteinemia. *Ann Hematol.* 2002; 81: 616-621.
2. Mudd SH, Levy HL, Skovby F. Disorders of transsulfuration. In: Scriver CR, Beaudet WS, Sly S, Valle D, eds. *The Metabolic Basis of Inherited Disease.* New York, NY: McGraw-Hill, 1989: 693-734.
3. Ueland PM, Refsum H, Stabler SP, Malinow MR, Andersson A. et al. Total homocysteine in plasma or serum: methods and clinical applications. *Clin Chem.* 1993; 39: 1764-1779.
4. Stampfer MJ, Malinow MR, Willett WC, Newcomer LM, Upson B, Ullmann D. et al. A prospective study of plasma homocyst(e)ine and risk of myocardial infarction in US physicians. *JAMA.* 1992; 268: 877-881.
5. Homocysteine Studies Collaboration. Homocysteine and Risk of Ischemic Heart Disease and Stroke. *JAMA.* 2002; 288(16): 2015-2022.
6. Frederiksen J, Juul K, Grande P. et al. Methylene tetrahydrofolate reductase polymorphism (C677T), hyperhomocysteinemia, and risk of ischemic cardiovascular disease and venous thromboembolism: prospective and case-control studies from the Copenhagen City Heart Study. *Blood.* 2004; 10: 3046-3051.
7. den Heijer M, Rosendaal FR, Blom HJ. et al. Hyperhomocysteinemia and venous thrombosis: a meta-analysis. *Thromb Haemost.* 1998; 80: 874-877.
8. Brattström L, Tengborn L, Israelsson B, Hultberg B. Plasma homocysteine in venous thromboembolism. *Haemostasis.* 1991; 21: 51-57.
9. Bienvenu T, Ankri A, Chadeaux B, Montalescot G, Kamoun P. Elevated total plasma homocysteine, a risk factor for thrombosis: relation to coagulation and fibrinolytic parameters. *Thromb Res.* 1993; 70: 123-129.
10. Falcon CR, Cattaneo M, Panzeri D, Martinelli I, Mannucci PM. High prevalence of hyperhomocyst(e)inemia in patients with juvenile venous thrombosis. *Arterioscler Thromb.* 1994; 14: 1080-1083.
11. Amundsen TO, Ueland MG, Waage AN. Plasma Homocysteine Levels in Patients with Deep Venous Thrombosis. *Arteriosclerosis, Thrombosis, and Vascular Biology.* 1995; 15: 1321-1323.
12. Ducros V, Barro C, Yver J, Pernod G, Polack B et al. Should Plasma Homocysteine Be Used as a Biomarker of Venous Thromboembolism? A Case-Control Study. *Clinical and Applied Thrombosis/Hemostasis.* 2009; 15(5): 517-522.

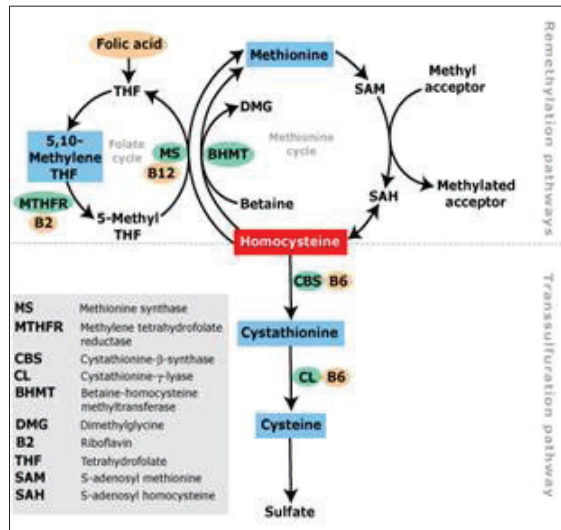


Figure 3. Pathways of homocysteine metabolism

nificant difference in plasma homocysteine concentrations between 42 patients with VTE and healthy control subjects, although the male patients showed a tendency toward higher plasma homocysteine than male control subjects. In contrast, Bienvenu et al. (9) demonstrated a significant association between fasting plasma homocysteine and VTE, and Falcon et al. (10) reported a high prevalence of hyperhomocysteinemia in patients less than 40 years of age who had VTE. Tore Amundsen et al, demonstrate that hyperhomocysteinemia is not a frequent cause of DVT (11). Ducros et al, showed that Mild or moderate hyperhomocysteinemia does not seem to be a strong determinant in VTE (12).

With such conflicting studies we report these three cases with secondary hyperhomocysteinemia secondary to nutritional deficiency of cobalamin. our patients had no apparent risk factors for venous thrombosis other than the hyperhomocysteinemia, all of them had cobalamin de-