

# Spinal epidural hematoma occurring at a distance from the transforaminal epidural injection site

## A case report

Sang-In Kim, MD\*, Dong-Hyun Lee, MD, Sun-Hee Kim, MD, Yong-Hyun Cho, MD

### Abstract

**Rationale:** Transforaminal epidural steroid injection (TFESI) is a conservative method to treat back pain due to radiculopathy. However, epidural hematoma can occur after the procedure by various mechanisms, which can cause serious complications.

**Patient concerns:** An 82-year-old man with spinal stenosis was treated with TFESI in the right intervertebral foramen at the L2-L3 level. The next morning, he experienced severe back pain and diffuse motor deficit.

**Diagnosis:** Emergency magnetic resonance imaging revealed fluid collection in the posterior epidural space at the T11-L1 level with central-canal stenosis.

**Interventions:** Emergency hematoma evacuation was performed to remove the epidural hematoma.

**Outcomes:** After the surgery, the back pain disappeared.

**Lessons:** Epidural hematoma may occur due to causes other than direct needle injury after TFESI. Therefore, careful observation of the patient is necessary after the procedure.

**Abbreviations:** MRI = magnetic resonance imaging, TFESI = transforaminal epidural steroid injection.

**Keywords:** epidural injections, lower back pain, spinal epidural hematoma, spinal stenosis

## 1. Introduction

Lower back pain is one of the most prevalent conditions that patients suffer from. Among the causes of lower back pain, radiculopathy is one of the most common, comprising around 9.9% to 25% of cases.<sup>[1]</sup> Radiculopathy occurs through nerve irritation and nerve root inflammation due to herniated nucleus pulposus, lumbar foraminal stenosis, and other disorders. Radiculopathy pain is located at the lower back and buttock and radiates to the legs.<sup>[2]</sup> Many studies have shown that injecting appropriate drugs such as local anesthetics or steroids into the epidural space can be helpful for radiculopathy pain relief and control. Lumbar epidural injection methods consist of 3 approaches: interlaminar, caudal canal, and transforaminal.<sup>[3]</sup> The transforaminal approach method, in particular, is increas-

ingly and widely performed nowadays. Accordingly, transforaminal epidural steroid injection (TFESI) has been considered a better method of injecting drugs into the ventral portion of the epidural space compared to other methods, and it has been shown that injecting drugs into the ventral portion of epidural space is more beneficial for pain relief and control.<sup>[4,5]</sup> However, one of the devastating complications of TFESI is epidural hematoma, which can lead to serious neurologic sequelae and can occur even though it is performed with appropriate skill under fluoroscopic guidance.<sup>[6]</sup> The prevalence of epidural hematoma after epidural anesthesia is around 1/150,000, but prevalence after TFESI has not been studied.<sup>[7]</sup> In pain practice, spinal hematoma complication is rare after epidural injection, and there are few case reports where epidural hematoma occurs elsewhere in the injection site. In this case, a patient developed acute severe back pain and lower extremity motor deficits due to an epidural hematoma located at a level distant from the injection site.

## 2. Case report

The patient, an 82-year-old Asian man, was admitted with lower back pain and bilateral buttock pain. Lumbar spinal stenosis at L1-L3 was found on the magnetic resonance imaging (MRI) taken at another hospital (Fig. 1). On physical examination, the patients' bilateral lower extremity motor and sensory functions were intact, but lower back pain and bilateral buttock pain were severe (measured as 4 points on the pain numeric rating scale) so conservative treatment and TFESI were scheduled for pain control.

The patient had undergone posterior lumbar interbody fusion at L3-L5 due to spinal stenosis in 2012 and was diagnosed with an L1-level compression fracture in 2017 for which he received

Editor: N/A.

The authors have no funding and conflicts of interest to disclose.

Department of Anesthesiology and Pain Medicine, Seoul Sacred Heart General Hospital, Seoul, Korea.

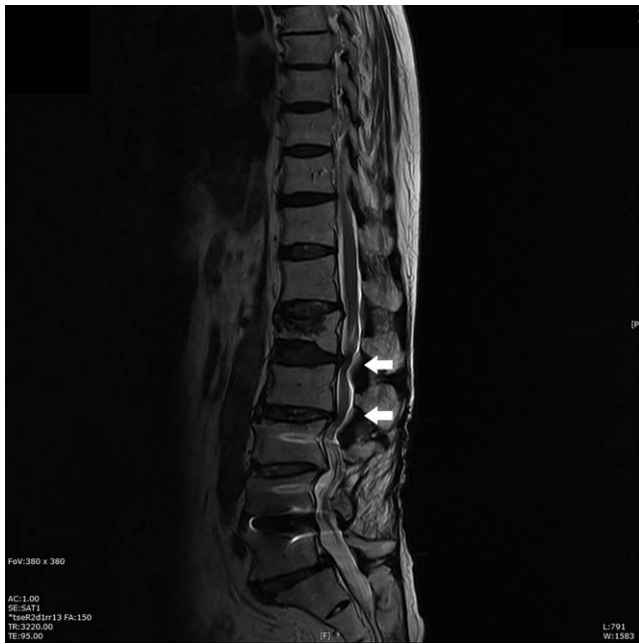\* Correspondence: Sang-In Kim, Department of Anesthesiology and Pain Medicine, Seoul Sacred Heart General Hospital, 259, Wangsan-ro, Dongdaemun-gu, Seoul 02488, Korea (e-mail: wcrew@gmail.com).

Copyright © 2019 the Author(s). Published by Wolters Kluwer Health, Inc. This is an open access article distributed under the terms of the Creative Commons Attribution-Non Commercial-No Derivatives License 4.0 (CCBY-NC-ND), where it is permissible to download and share the work provided it is properly cited. The work cannot be changed in any way or used commercially without permission from the journal.

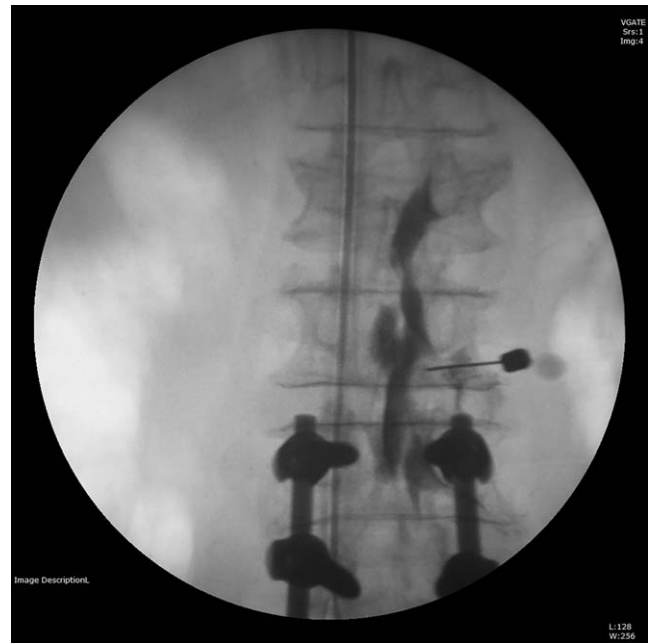Medicine (2019) 98:30(e16654)

Received: 24 January 2019 / Received in final form: 30 May 2019 / Accepted: 8 July 2019

<http://dx.doi.org/10.1097/MD.00000000000016654>



**Figure 1.** Lumbar sagittal T2 weighted magnetic resonance imaging showing lumbar spinal stenosis at L1-L3 (arrows).



**Figure 2.** Fluoroscopic anteroposterior view showing contrast spreading from L1 to L3 epidural space during transforaminal epidural injection.

conservative treatment and L2-level root blocks several times. He also had a previous medical history of type 2 diabetes mellitus and hypertension but was not taking any medications. The patient's blood pressure was stable and the average of the blood pressure measurements taken on admission was 140/70 mm Hg.

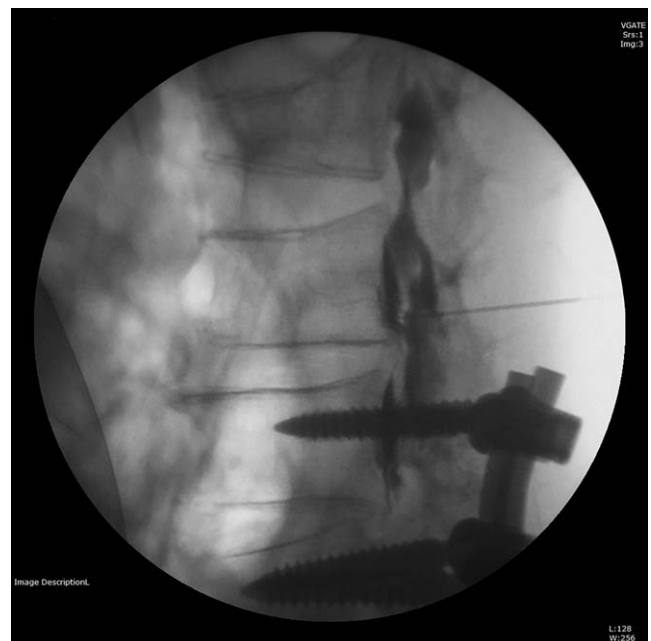
Laboratory findings after admission included: normal electrolyte levels, hematocrit 41.6%, platelet count 340,000/mm<sup>3</sup>, prothrombin time 11.3 seconds, and activated partial thromboplastin time 30.0 seconds.

The TFESI was performed at the right intervertebral foramen between L2 and L3 under fluoroscopic guidance. After sterilizing the skin, local anesthesia was applied to the area with 3 mL of 1% lidocaine. In the lateral oblique fluoroscopic images, a 20-gauge short bevel nerve block needle was placed at the L2 lumbar pedicle inferior margin (6 o'clock position of the pedicle). Then the needle was slightly advanced in the lateral view and placed in the dorsal periosteum of the vertebral body. We confirmed that the needle was placed in the epidural space by using 2 mL of contrast agent (Figs. 2 and 3). A 6 mL mixture of 10 mg of 0.5% bupivacaine (5 mg/mL), 3 mL of normal saline, and 5 mg of dexamethasone (5 mg/mL) was injected slowly; we observed no abnormalities during the procedure. After confirming that there were no complications, we moved the patient from the recovery room to the ward. The patient's back pain was slightly improved initially, but the next morning, the patient underwent emergency MRI due to severe right lower back pain and bilateral diffuse lower extremity motor deficit with motor function grade 4 on a 5-point severity scale.

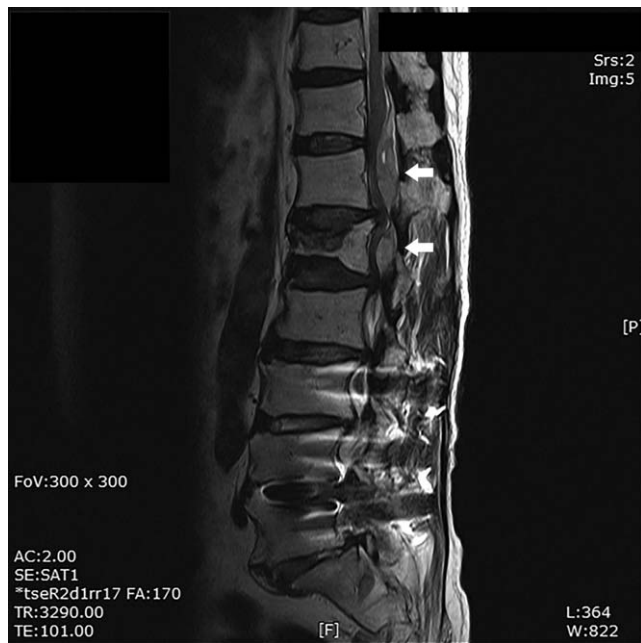
Lumbar spine MRI showed a fluid collection at the posterior epidural space from the T11 to L1 level with central canal stenosis (Figs. 4 and 5). Surgical evacuation was performed that evening for a suspected epidural hematoma.

Under the general anesthesia, the patient lay in the prone position and an incision was made over the spinous processes from T12 to L2. Laminectomy was performed bilaterally at the

T12-L2 level due to hematoma and preexisting spinal stenosis. There was a rubbery, hard, clotted hematoma mass over the thecal sac from T12 to L1 (Fig. 6). The entire compressing hematoma mass was removed. There was continuing bleeding at the proximal T12 body, posterior side, which was considered the origin of the epidural hematoma. After surgery, the sudden back pain dramatically disappeared. Two weeks later, the patient was discharged without any other symptoms.



**Figure 3.** Fluoroscopic lateral view showing contrast spreading from L1 to L3 epidural space during transforaminal epidural injection.

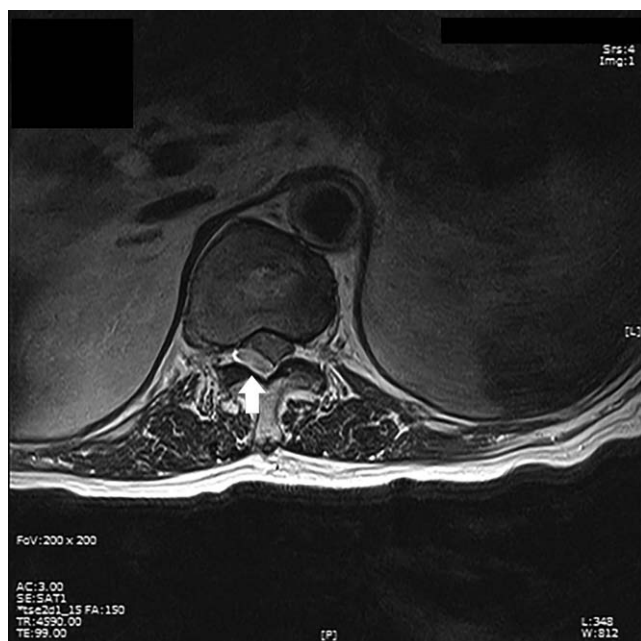

**Figure 4.** Lumbar sagittal T2 weighted magnetic resonance imaging showing heterogeneous high signal intensity (arrows) at the ventral epidural space spreading from T11 to L1.

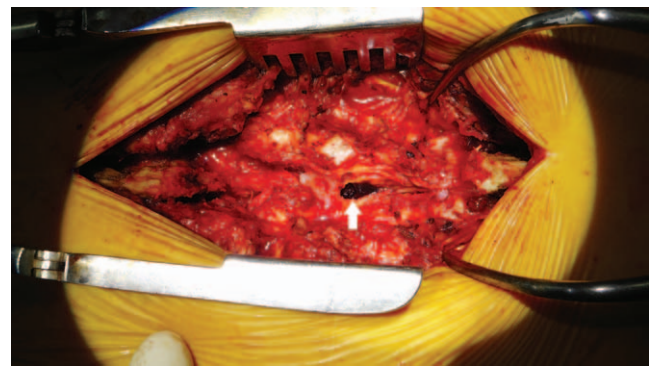### 3. Discussion

Known side effects of TFESI include infections, hematoma, intravascular injections, nerve trauma, dural puncture, and air embolism. The prevalence of epidural hematoma after TFESI has not yet been established.<sup>[8]</sup>

One of the causes of epidural hematoma is vessel injury near the foramen due to direct needle injury.<sup>[8]</sup> Vessel injury, which can



**Figure 5.** Lumbar axial T2 weighted magnetic resonance imaging showing heterogeneous signal intensity (arrow) at T12.



**Figure 6.** Intraoperative photograph showing a clotted mass of dark brownish hematoma at the T12 epidural space (arrow).

increase the likelihood of intravascular drug delivery, can lead to bleeding and hematoma formation. This risk is higher in patients taking anticoagulants and in patients with inherited and acquired coagulation disorders, but it can occur in patients without any history of medication use or other risk factors; therefore, considerable caution is required during the procedure.<sup>[9]</sup>

One of the blood vessels that can be damaged during TFESI procedures is the internal vertebral venous plexus.<sup>[6]</sup> This plexus, also referred to as Batson’s plexus, encircles the spinal canal. Its anterior part is located in the anterior epidural space and consists of two interconnected veins extending longitudinally through the back of the intervertebral disc and vertebral bodies. These veins are located behind the posterior longitudinal ligament; the closer the needle approaches to the anterior epidural space, the greater the likelihood of vessel damage by needle puncture.<sup>[6]</sup> Another vessel that can be damaged by direct needle injury is the radicular artery that runs alongside the spinal nerve root. The radicular arteries derive from the lumbar arteries originating from branches of the aorta and supply blood to the spinal nerves and nerve roots.<sup>[10]</sup> The radicular artery enters the intervertebral foramen along the nerve root; the probability that the artery is in the upper part of the foramen is around 2-fold greater than the probability of it being in the lower part, and there is an increased risk of damaging the vessel during needle entry through the “safe triangle.”<sup>[11]</sup>

In addition to direct needle injury, the cause of epidural hematoma may relate to vessel damage due to increased pressure in the epidural space. In a case described by Shanthanna and Park,<sup>[12]</sup> epidural hematoma occurred at the T10-T12 level after epidural block at L3-L4 level. They suggested the possibility of vessel rupture due to the pressure of drug injection as an explanation for the epidural hematoma occurring somewhat distant from the block point. In patients with spinal stenosis, the epidural pressure is increased by the narrow spinal canal. If pressure is applied during drug injection, the strength of the thinning vessel wall of the venous plexus is exceeded, resulting in hematoma. There have been other reported cases where hematoma is thought to result from a similar cause. In the case reported by Choi et al,<sup>[13]</sup> epidural hematoma occurred at the L2-L4 level after caudal block. In the cases reported by Gungor and Arier,<sup>[14]</sup> post-TFESI contralateral epidural hematoma occurred in the direction of injection. In the above 3 cases, warfarin or antiplatelet drugs were implicated but in our case, the patient was not taking any anticoagulant or antiplatelet drugs. The use of anticoagulants or antiplatelet drugs increases the risk of epidural

hematoma. According to Vandermeulen et al,<sup>[15]</sup> in 42 spinal hematomas in 61 patients, an associated hemostatic abnormality was identified.

We believe that the reason for the hematoma in our case was the increasing pressure in the epidural space rather than direct needle injury. The needle entered the right intervertebral foramen between L2 and L3 but the epidural hematoma was located at L1-T11 and the bulk of the hematoma was in the posterior T12 epidural space. Also, the origin of the epidural hematoma detected during surgery was suspected to be posterior to the 12th thoracic body. In a study reported by Usubiaga et al,<sup>[16]</sup> the pressure in the epidural space increased from  $-1$  to  $-10$  cmH<sub>2</sub>O before injection to a maximum of 65 cmH<sub>2</sub>O after injection of 10 mL of 2% lidocaine into the epidural space. The pressure was higher in the elderly than in the younger patients and the high epidural pressure was maintained until 2 minutes after injection. Furthermore, in the review by Kreppel et al,<sup>[17]</sup> 86 of 613 spinal hematomas (14%) were caused by coughing, defecation, or sex, which simple actions increased the pressure in the epidural space.

In conclusion, a clinician performing TFESI should always be mindful of the possibility of epidural hematoma, because it can be fatal or cause permanent damage to the patient. It should be considered that this can occur due to increased pressure at the time of drug injection, even if there is no indication of bleeding or no history of taking medications such as anticoagulant drugs. Proceed as slowly as possible when injecting the drug, and if resistance is felt, do not inject with force because of the possibility of hematoma due to increasing epidural pressure especially extremely care when carry out a patient who is expected to high epidural pressure such as an elderly or a patient with severe spinal stenosis. In addition, if the patient complains of severe pain after a TFESI procedure or has a specific symptom, the possibility of epidural hematoma should be evaluated by MRI without delay.

### Author contributions

**Conceptualization:** Sang-in Kim, Yong-Hyun Cho.

**Supervision:** Dong-Hyun Lee, Sun-Hee Kim, Yong-Hyun Cho.

**Visualization:** Sang-in Kim, Sun-Hee Kim.

**Writing – original draft:** Sang-in Kim.

**Writing – review & editing:** Yong-Hyun Cho.

### References

- [1] Konstantinou K, Dunn KM. Sciatica: review of epidemiological studies and prevalence estimates. *Spine (Phila Pa 1976)* 2008;33:2464–72.
- [2] Ropper AH, Zafonte RD. Sciatica. *N Engl J Med* 2015;372:1240–8.
- [3] Cohen SP, Bicket MC, Jamison D, et al. Epidural steroids: a comprehensive, evidence-based review. *Reg Anesth Pain Med* 2013;38:175–200.
- [4] Schaufele MK, Hatch L, Jones W. Interlaminar versus transforaminal epidural injections for the treatment of symptomatic lumbar intervertebral disc herniations. *Pain Physician* 2006;9:361–6.
- [5] Roberts ST, Willick SE, Rho ME, et al. Efficacy of lumbosacral transforaminal epidural steroid injections: a systematic review. *PM R* 2009;1:657–68.
- [6] Desai MJ, Dua S. Perineural hematoma following lumbar transforaminal steroid injection causing acute-on-chronic lumbar radiculopathy: a case report. *Pain Pract* 2014;14:271–7.
- [7] Moen V, Dahlgren N, Irestedt L. Severe neurological complications after central neuraxial blockages in Sweden 1990 – 1999. *Anesthesiology* 2004;101:950–9.
- [8] Goodman BS, Posecion LWF, Mallempati S, et al. Complications and pitfalls of lumbar interlaminar and transforaminal epidural injections. *Curr Rev Musculoskelet Med* 2008;1:212–22.
- [9] Windsor RE, Storm S, Sugar R. Prevention and management of complications resulting from common spinal injections. *Pain Physician* 2003;6:473–83.
- [10] Mandell JC, Czuczman GJ, Gaviola GC, et al. The lumbar neural foramen and transforaminal epidural steroid injections: An anatomic review with key safety considerations in planning the percutaneous approach. *AJR Am J Roentgenol* 2017;209:W26–35.
- [11] Melissano G, Chiesa R. Advances in imaging of the spinal cord vascular supply and its relationship with paraplegia after aortic interventions. A review. *Eur J Vasc Endovasc Surg* 2009;38:567–77.
- [12] Shanthanna H, Park J. Acute epidural haematoma following epidural steroid injection in a patient with spinal stenosis. *Anaesthesia* 2011;66:837–9.
- [13] Choi JJ, Chang YJ, Jung WS, et al. Discordant lumbar epidural hematoma after caudal steroid injection: a case report (CARE-compliant). *Medicine (Baltimore)* 2017;96:e7127.
- [14] Gungor S, Aiyer R. Epidural hematoma development contralateral to dura after lumbar transforaminal epidural steroid injection. *Pain Manag* 2017;7:367–75.
- [15] Vandermeulen EP, Van Aken H, Vermylen J. Anticoagulants and spinal-epidural anesthesia. *Anesth Analg* 1994;79:1165–77.
- [16] Usubiaga JE, Wikinski JA, Usubiaga LE. Epidural pressure and its relation to spread of anesthetic solutions in epidural space. *Anesth Analg* 1967;46:440–6.
- [17] Kreppel D, Antoniadis G, Seeling W. Spinal hematoma: a literature survey with meta-analysis of 613 patients. *Neurosurg Rev* 2003;26:1–49.