

Clinical and pathological features of metastatic adenocarcinoma of the prostate to the ileum

Thorsten H. Ecke¹, Stefan Koch², Jürgen Ruttloff¹, Steffen Hallmann¹

¹HELIOS Hospital, Department of Urology, Bad Saarow, Germany

²HELIOS Hospital, Institute of Pathology, Bad Saarow, Germany

Article history

Submitted: July 3, 2014

Accepted: Sept. 12, 2014

We present a case of a 74-year-old white male with a history of prostate cancer with unusual metastasis to the ileum, and with ileus as a very unusual first symptom of prostate cancer. This patient presented to us with histologically confirmed metastasis of the ileum after resection in the Department of Surgery.

Correspondence

Thorsten H. Ecke

HELIOS Hospital

Department of Urology

Pieskower Strasse 33

D-15526 Bad Saarow,

Germany

phone: +49 33 631 722 67

thorsten.ecke@helios-

kliniken.de

Key Words: prostate cancer ↔ metastasis ↔ ileum

INTRODUCTION

Prostate cancer is the most common malignancy in males, with an estimated incidence of more than 240,000 cases in 2013 [1]. Metastases of prostate cancer are mostly to the axial skeleton and local lymph nodes [2]. There are only a few cases reporting metastasis to the gastrointestinal system [3-6]. This is, to our knowledge, the first case report of a patient with histologically confirmed metastasis of prostate adenocarcinoma to the ileum.

CASE REPORT

This report presents a very rare case of an ileum metastasis as the first symptom-presenting and diagnostic organ of prostate cancer. A 74-year-old Caucasian male was referred to our Department of Urology after laparotomy with partial resection of the ileum caused by ileus in July 2013. In the resected part of the ileum the histological diagnosis was described as metastasis of prostate cancer. In the history of the

patient a resection of the rectum, pelvic lymphadenectomy and anus praeter in July 2012 is known. Until September 2012 radio-chemo-therapy with 5-FU and radiotherapy up to 50.4 Gy, because of adenocarcinoma of the rectum pT3 pN1(2/10) M0 L1 V1 G2, were performed. After this surgical treatment, no other macroscopic abnormalities were reported.

At the first presentation in our department in July 2013, physical examination revealed a undernourished man (height 1.68 m, weight 57 kg) with an unsuspecting abdomen. Digital rectal examination of the prostate was not possible, because the rectum had been resected. He denied any symptoms of nausea, vomiting, abdominal pain, melena, changes in bowel habit, or hematuria. At the first presentation in our department the value of PSA was 36.02 ng/ml. A prostate biopsy via perineum was performed and the histology revealed adenocarcinoma of prostate, Gleason 3+3 G1. Further diagnostics in July 2013 included a CT scan of thorax – abdomen, with enlarged retroperitoneal lymph nodes (maximum 1.5 cm) and a disputable bone metastasis in the pelvis;

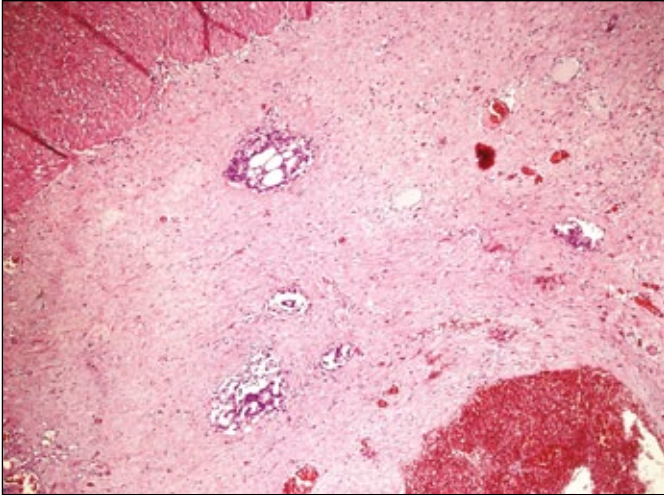


Figure 1. Overview of the resected ileum (H&E, scale 4x).

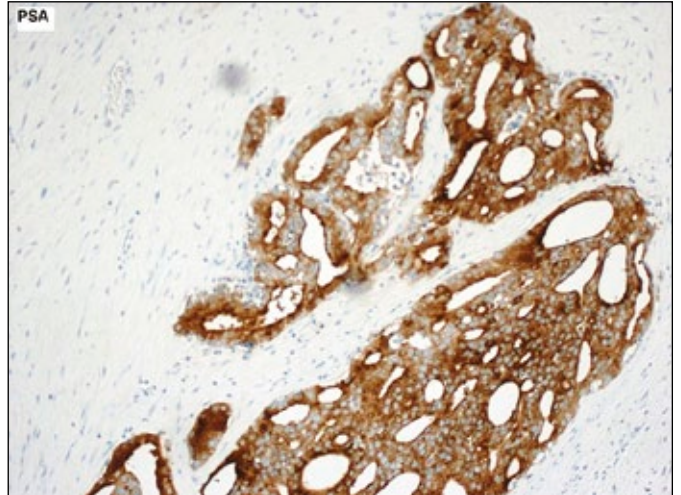


Figure 4. PSA positive reaction in ileum metastasis (PSA, scale 10x).

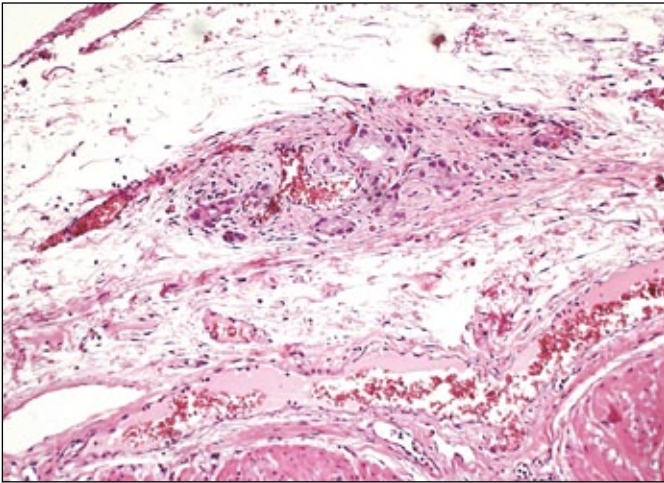


Figure 2. Broadened adventitia of the ileum with infiltration by tumour cells (H&E, scale 10x).

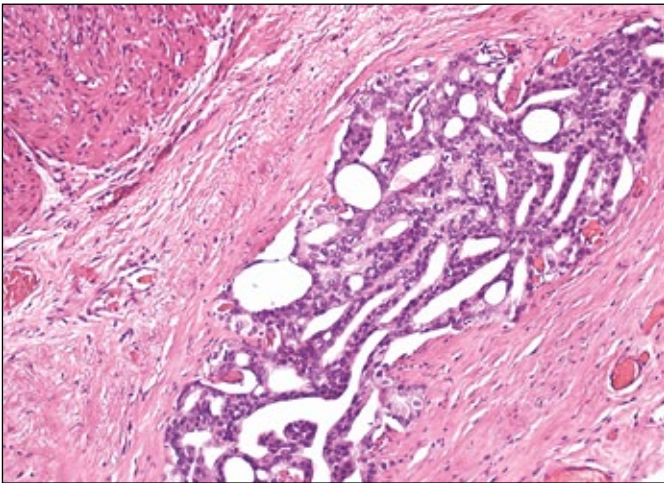


Figure 3. Muscularis propria with cribriform glands, prostate cancer cells in subserous connective tissue (H&E, scale 10x).

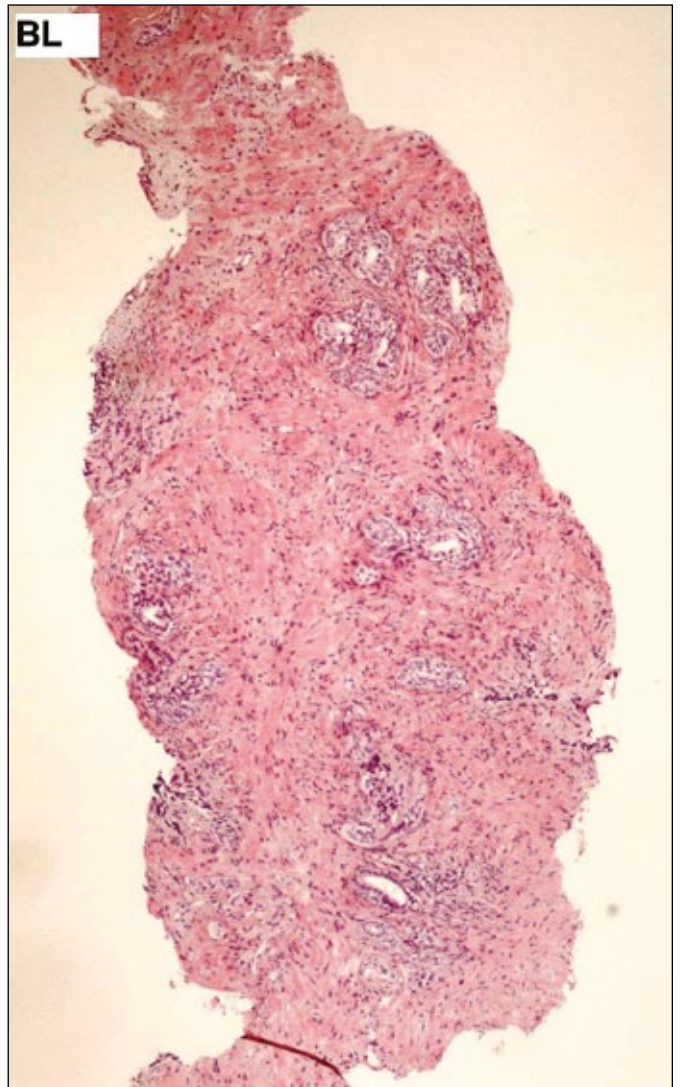


Figure 5. Prostate biopsy sample in position BL (H&E, scale 4x).

no other relevant visceral metastasis was identified. A bone scan showed only degenerative changes, not typical for metastases of prostate cancer. The recommended treatment was hormonal therapy starting with Bicalutamid 50 mg/day p.o., and since August 2013, leuprolide acetate (luteinizing hormone-releasing hormone (LHRH) agonist). The PSA decreased to normal levels within 3 months.

Since the ileum is a very unusual location for metastasis of prostate cancer, we compared the original paraffin blocks of the ileum with our prostate cancer material. Surprisingly, we could demonstrate that this is a metastasis of adenocarcinoma of prostate cancer, and not of rectal cancer. Figure 1 shows an overview of the resected ileum and in Figure 2, the broadened adventitia of the ileum with infiltration of prostate cancer tumour cells. As a sign of prostate cancer cells in subserous connective tissue, Figure 3 presents the muscularis propria with the cribriform glands. All ileum samples are PSA positive as shown in Figures 1–4. The paraffin blocks from the resected ileum have been supervised by two pathologists in different departments. For comparison prostate biopsy samples are visible in normal HE in Figure 5 and with positive P405S (AMACR) in Figure 6.

In the CT scan from October 2013, a partly response of retroperitoneal lymph nodes could be described. The next CT scan in January 2014 showed a 5 cm measured structure presacraly; in colposcopy a semicircular tumor 10 cm ab colostoma was confirmed. Histologically, now adenocarcinoma of the colon with mutation of exon 2 in *K-RAS* was described. In the oncological office, palliative chemotherapy treatment with 5-FU, folin and oxaliplatin was performed. The last CT scan in August 2014 showed no changes from January 2014.

DISCUSSION

To our knowledge this is the first case presentation of a metastasis of prostate cancer to the ileum.

Common sites of prostate carcinoma metastasis, in descending order of frequency, include regional

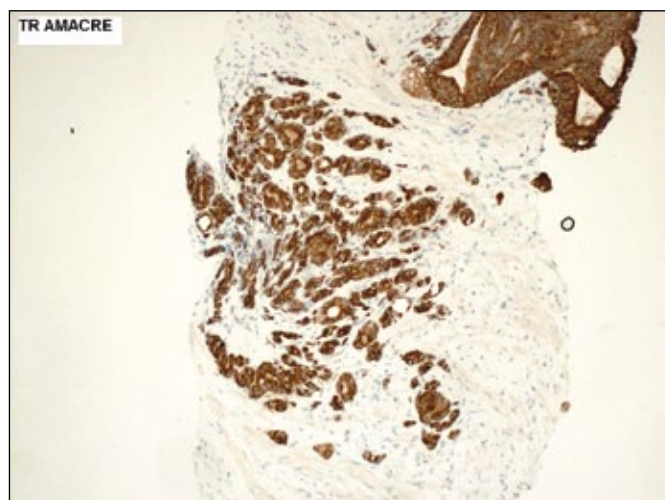


Figure 6. Prostate biopsy sample in position TR (P405S/AMACR, 10x).

lymph nodes, bone, distant lymph nodes, lung, and liver. Prostate carcinoma with gastric metastasis is rare; a literature review has revealed only six other cases diagnosed by histology premortem [3, 4, 5, 7, 8, 9]. Another four case reports describe metastatic disease to nongastric upper gastrointestinal tract sites (3 of the esophagus [6, 10, 11] and 1 of the duodenum [12]). In postmortem studies, the incidence of gastric metastasis was reported as 1-4% [2, 4, 8, 9].

On histopathology, prostatic adenocarcinoma classically demonstrates a relative lack of nuclear anaplasia, with nuclear informity, paucity of mitotic figures, and the absence of signet-ring cell forms. The diagnosis is confirmed by immunohistochemical staining with a positive PSA stain as shown in the Figures 1-6.

CONCLUSIONS

This case is the first report in the literature of a metastasis of prostate cancer to the ileum. Although a very rare, it is imperative for oncologists, gastroenterologists, and urologists to consider the possibility of prostate cancer metastasis in the intestinal tract.

References

- Malvezzi M, Bertuccio P, Levi F, La Vecchia C, Negri E. European cancer mortality predictions for the year 2014. *Ann Oncol*. 2014; 25: 1650-1656
- Gandaglia G, Abdollah F, Schiffmann J, Trudeau V, Shariat SF, Kim SP, et al. Distribution of metastatic sites in patients with prostate cancer: A population-based analysis. *Prostate* 2014; 74: 210-216.
- Patel H, Kumar A, Shaaban H, Nguyen N, Baddoura W, Maroules M, Shaikh S. Synchronous metastasis of prostate adenocarcinoma to the stomach and colon: a case report. *North American journal of medical sciences*. 2014; 6: 152-154.
- Hong KP, Lee SJ, Hong GS, Yoon H, Shim BS. Prostate cancer metastasis to the stomach. *Korean journal of urology*. 2010; 51: 431-433.

5. Christoph F, Grünbaum M, Wolkers F, Müller M, Miller K. Prostate cancer metastatic to the stomach. *Urology*. 2004; 63: 778-779.
6. Eaves R, Lambert J, Rees J, King RW. Achalasia secondary to carcinoma of prostate. *Dig Dis Sci*. 1983; 28: 278-284.
7. Holderman WH, Jacques JM, Blackstone MO, Brasitus TA. Prostate cancer metastatic to the stomach. Clinical aspects and endoscopic diagnosis. *J Clin Gastroenterol*. 1992; 14: 251-254.
8. Onitilo AA, Engel JM, Resnick JM. Prostate carcinoma metastatic to the stomach: report of two cases and review of the literature. *Clin Med Res*. 2010; 8: 18-21.
9. Bowrey DJ, Otter MI, Billings PJ. Rectal infiltration by prostatic adenocarcinoma: report on six patients and review of the literature. *Ann R Coll Surg Engl*. 2003; 85: 382-385.
10. Nakamura T, Mohri H, Shimazaki M, Ito Y, Ohnishi T, Nishino Y, et al. Esophageal metastasis from prostate cancer: diagnostic use of reverse transcriptase-polymerase chain reaction for prostate-specific antigen. *J Gastroenterol*. 1997; 32: 236-240.
11. Gore RM, Sparberg M. Metastatic carcinoma of the prostate to the esophagus. *Am J Gastroenterol*. 1982; 77: 358-359.
12. Malhi-Chowla N, Wolfsen HC, Menke D, Woodward TA. Prostate cancer metastasizing to the small bowel. *J Clin Gastroenterol*. 2001; 32: 439-440. ■