

This is an Open Access article licensed under the terms of the Creative Commons Attribution-NonCommercial 3.0 Unported license (CC BY-NC) (www.karger.com/OA-license), applicable to the online version of the article only. Distribution permitted for non-commercial purposes only.

An Unexpected Result of Obesity Treatment: Orlistat-Related Acute Pancreatitis

Murat Kose^a Samim Emet^b Timur Selcuk Akpınar^a Mehmet Ilhan^c
Ali Fuat Kaan Gok^c Mubariz Dadashov^b Tufan Tukek^a

Departments of ^aInternal Medicine, ^bCardiology and ^cGeneral Surgery, Istanbul University Faculty of Medicine, Istanbul, Turkey

Key Words

Orlistat · Obesity · Acute pancreatitis · Adverse event

Abstract

Orlistat is a pancreatic lipase inhibitor which is used to treat obesity. Due to the increasing prevalence of obesity, orlistat use is thought to rise progressively. We report an interesting case caused by orlistat use caught in the early stages of acute pancreatitis through imaging; in addition, the case had significantly elevated serum amylase levels. A 54-year-old male who had a history of orlistat treatment started 7 days before was admitted to the emergency department with complaints of abdominal pain, nausea and vomiting lasting for 24 h. Abdominal computed tomography revealed peripancreatic fat tissue edema and a heterogeneous appearance of the pancreas. Based on these findings, it was concluded that edematous pancreatitis was in its initial stage. Orlistat is a drug that is increasingly widespread use due to obesity. More attention must be paid when planning to prescribe orlistat to patients if there are risk factors for acute pancreatitis (alcohol use, height, serum calcium and lipid levels).

© 2015 S. Karger AG, Basel

Introduction

Acute pancreatitis is characterized by the onset of parenchymal and peripancreatic fat necrosis with associated inflammation in a previously healthy individual. Acute pancreatitis should be suspected in patients with acute severe abdominal pain and can be classified based on severity. The Atlanta classification divides acute pancreatitis into two groups: in-

terstitial edematous acute pancreatitis and necrotizing acute pancreatitis. The first category is characterized by pancreatic parenchymal and peripancreatic inflammation without necrosis, while the latter category involves inflammation and some degree of necrosis. The diagnosis of drug-induced acute pancreatitis first requires a diagnosis of acute pancreatitis. Elevations in several biomarkers are indicative of pancreatitis, including serum lipase and amylase that are secreted in bulk by pancreatic acinar cells and thus are most commonly measured. Other laboratory tests with diagnostic implications include serum trypsinogen, pancreatic proteases, C-reactive protein, interleukin-6 and interleukin-8. The next step in diagnosing drug-induced pancreatitis requires ruling out more common etiologies such as gallstone pancreatitis and ethanol-induced acute pancreatitis. A thorough medical history and the patient's medications must be recorded. The history should focus on previous symptoms and any record of gallstones, ethanol abuse, hypercalcemia, hypertriglyceridemia and trauma. Serum amylase, lipase, triglyceride level, calcium level and liver function tests should be ordered. Abdominal and endoscopic ultrasounds should be performed to evaluate for gallstones and other obstructive possibilities such as tumors of the pancreas head [1].

Orlistat is a pancreatic lipase inhibitor which is used to treat obesity [2]. Due to the increasing prevalence of obesity, orlistat use is thought to rise progressively. The indications of orlistat are body mass index (BMI) >30 without any risk factors or BMI >27 with additional risk factors such as hypertension, hyperlipidemia or diabetes [3]. Orlistat has been reported to be associated with adverse events such as hepatic cholestasis, subacute hepatic failure and hepatic necrosis. However, placebo-controlled studies have shown no relationship with acute pancreatitis [4–9]. Only four cases of acute pancreatitis associated with orlistat have been reported in the literature, and one of those cases did not demonstrate an increase in serum amylase [10–12]. We report an interesting case caused by orlistat use caught in the early stages of acute pancreatitis through imaging; in addition, the case had significantly elevated serum amylase levels.

Case Report

A 54-year-old male with a history of hypertension was admitted to the emergency department with complaints of abdominal pain, nausea and vomiting lasting for 24 h. It was learned from his medical history that he had been using irbesartan for 7 years, and in addition to this drug, orlistat treatment had been started 7 days before for obesity. The obese-looking patient had a height of 1.72 m, a weight of 94 kg and a BMI of 31. He was afebrile with a blood pressure of 140/90 mm Hg and a pulse of 102 bpm. Diffuse abdominal tenderness was present at abdominal examination. Routine biochemical tests and complete blood count were performed. The results were: white blood cells 12,600/ μ l, serum amylase 2,409 U/l, C-reactive protein 136 mg/l and lactate dehydrogenase 835 U/l. The serum calcium and lipid profile were normal. Hepatobiliary ultrasound was performed to exclude biliary pancreatitis and was found to be normal. Abdominal computed tomography revealed peripancreatic fat tissue edema and a heterogeneous appearance of the pancreas (fig. 1). Based on these findings, it was concluded that edematous pancreatitis was in its initial stage. The patient's oral intake and medications were discontinued. An intravenous antibiotic was given for prophylaxis. On the third day after admission, abdominal pain, nausea and vomiting were improved. Serum amylase levels were normal and the patient was told to take specific measures addressed to his obesity.

Discussion

Alcohol use and gallstones are responsible for the development of more than 80% of acute pancreatitis cases. Other common causes of acute pancreatitis are hypertriglyceridemia and hypercalcemia. Drugs are implicated in the etiology of approximately 2% of cases [13]. Drug-induced acute pancreatitis has a good prognosis and can be diagnosed by exclusion. Absence of gallstones, lack of a history of alcohol use with normal serum lipid and calcium levels and history of a recently started new medication support the diagnosis [13, 14]. Orlistat blocks intestinal fat absorption by inhibiting gastric and pancreatic lipase and thus can cause symptoms such as rectal pain, oily feces, frequent defecation, nausea and vomiting. All these lead to a modification of the patient's behavior and eating habits to avoid eating fat, with the patient consequently losing weight [5]. Orlistat is metabolized in the gastrointestinal tract and its direct destructive effect is shown in intestinal villi of animal models [4]. However, the mechanism in the development of acute pancreatitis is not known; a possible mechanism may be direct toxicity or hypersensitivity such as in other drug-induced acute pancreatitis.

Conclusion

We report a case of drug-induced acute pancreatitis about 1 week after initiation of orlistat. The patient in our case had a very high serum amylase level, although imaging studies showed that he was in a very early stage of edematous pancreatitis. Serum amylase levels were found to be normal in a previously reported case of acute pancreatitis associated with orlistat [12].

Orlistat is a drug with an increasingly widespread use due to obesity. Therefore, acute pancreatitis must be kept in mind when faced with newly developed abdominal pain in patients under orlistat treatment. In addition, imaging techniques (such as hepatobiliary ultrasound and abdominal computed tomography) should be requested. More attention must be paid when planning to prescribe orlistat to patients if there are risk factors for acute pancreatitis (alcohol use, height, serum calcium and lipid levels).

Disclosure Statement

The authors have no conflict of interest.

References

- 1 Jones MR, Hall OM, Kaye AM, Kaye AD: Drug-induced acute pancreatitis: a review. *Ochsner J* 2015;15:45–51.
- 2 Guerciolini R: Mode of action of orlistat. *Int J Obes Relat Metab Disord* 1997;21(suppl 3):S12–S23.
- 3 National Institute for Clinical Excellence: Obesity Guidance on the Prevention, Identification, Assessment and Management of Overweight and Obesity in Adults and Children. Clinical Guideline 43. London, NICE, 2006.
- 4 Caner M, Dogruman H, Taskin E, Kandil A, Demirci C: Effects of orlistat and its relationship with nitric oxide in the small intestinal mucosa. *Chin J Physiol* 2005;48:217–222.
- 5 Filippatos TD, Derdemezis CS, Gazi IF, Nakou ES, Mikhailidis DP, Elisaf MS: Orlistat-associated adverse effects and drug interactions: a critical review. *Drug Saf* 2008;31:53–65.
- 6 Kim DH, Lee EH, Hwang JC, Jeung JH, Kim do H, Cheong JY, Cho SW, Kim YB: A case of acute cholestatic hepatitis associated with orlistat (in Korean). *Taehan Kan Hakhoe Chi* 2002;8:317–320.

Kose et al.: An Unexpected Result of Obesity Treatment: Orlistat-Related Acute Pancreatitis

- 7 Montero JL, Muntané J, Fraga E, Delgado M, Costán G, Serrano M, Padillo J, de la Mata M, Miño G: Orlistat associated subacute hepatic failure. *J Hepatol* 2001;34:173.
- 8 Thurairajah PH, Syn WK, Neil DA, Stell D, Haydon G: Orlistat (Xenical)-induced subacute liver failure. *Eur J Gastroenterol Hepatol* 2005;17:1437–1438.
- 9 Lau G, Chan CL: Massive hepatocellular [correction of hepatocellular] necrosis: was it caused by orlistat? *Med Sci Law* 2002;42:309–312.
- 10 García Aguilera X, Teruel Sánchez-Vegazo C, Crespo Pérez L, Moreira Vicente V: Orlistat-induced acute pancreatitis. *Med Clin (Barc)* 2008;130:557.
- 11 Ahmad FA, Mahmud S: Acute pancreatitis following orlistat therapy: report of two cases. *JOP* 2010;11: 61–63.
- 12 Napier S, Thomas M: 36 year old man presenting with pancreatitis and a history of recent commencement of orlistat case report. *Nutr J* 2006;5:19.
- 13 Wilmlink T, Frick TW: Drug-induced pancreatitis. *Drug Saf* 1996;14:406–423.
- 14 Whitcomb DC: Clinical practice. Acute pancreatitis. *N Engl J Med* 2006;354:2142–2150.

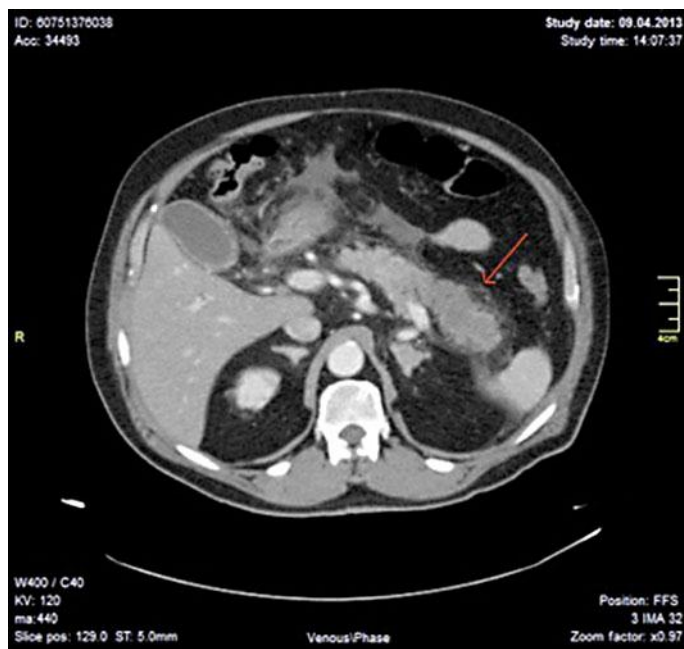


Fig. 1. Abdominal computed tomography revealed peripancreatic fat tissue edema and a heterogeneous appearance of the pancreas (arrow). Based on these findings, it was concluded that edematous pancreatitis was in its initial stage.