



Since January 2020 Elsevier has created a COVID-19 resource centre with free information in English and Mandarin on the novel coronavirus COVID-19. The COVID-19 resource centre is hosted on Elsevier Connect, the company's public news and information website.

Elsevier hereby grants permission to make all its COVID-19-related research that is available on the COVID-19 resource centre - including this research content - immediately available in PubMed Central and other publicly funded repositories, such as the WHO COVID database with rights for unrestricted research re-use and analyses in any form or by any means with acknowledgement of the original source. These permissions are granted for free by Elsevier for as long as the COVID-19 resource centre remains active.

Vicente Palop Larrea^{a,b}, Miguel Ángel Hernández Rodríguez^{a,c,*}

^a Medicina Familiar y Comunitaria, Grupo de Trabajo de Utilización de Fármacos de la Sociedad Española de Medicina Familiar y Comunitaria, Spain

^b Unidad de Aparato Locomotor, Consulta de Fibromialgia, Hospital de Dénia-Marina Salud, Asesor Médico de Ribera Salud, Dénia, Alicante, Spain

^c Servicio Canario de la Salud, Plan de Salud de Canarias, Santa Cruz de Tenerife, Spain

* Corresponding author.

E-mail address: miguelahr@gmail.com (M.Á. Hernández Rodríguez).

2387-0206/ © 2020 Elsevier España, S.L.U. All rights reserved.

Cross-reactions between rheumatoid factor and IgM SARS-CoV-2[☆]



Reacciones cruzadas entre factor reumatoide e IgM SARS-CoV-2

To the Editor:

After the onset of the SARS-CoV-2 infection, special attention has been paid to the protection and transmission reduction in vulnerable populations. Of the methods described by Hernández-Pérez et al.¹ and the rapid immunoglobulin tests,² the most widely used methods are nucleic acid detection and tests based on the antigen-antibody reaction. We consider it important to focus attention on the possibility of IgM cross-reactivity between rheumatoid factors and IgM SARS-CoV-2 in patients with chronic inflammatory diseases and elevated rheumatoid factors, such as rheumatoid arthritis and Sjögren's syndrome.

The reverse transcription-polymerase chain reaction (RT-PCR) requires at least 4–6 h and it is very costly. It is the technique that is most used to diagnose active infection and it should be considered a technique of choice since: a) it detects the presence of the virus in nasopharynx samples in the acute phase; b) samples such as endotracheal aspirate, bronchial aspirate, and bronchoalveolar lavage can be used; c) it allows a large number of patients to be studied, due to the ease of automation of the procedures, and d) it is greater sensitivity (Se) and specificity (Sp) than the other methods available. It has fewer false positives (FP) and false negatives (FN). PCR-interpretation must be performed carefully and within the appropriate clinical context, especially when the result is negative.

Recent papers on COVID-19 have also focused on immunoassays (enzyme-linked immunosorbent assay [ELISA]) and on rapid antigen and antibody tests.² The ELISA test is an immunoenzymatic assay that determines the presence of IgM and IgG antibodies, or a combination of IgM + IgA. Within the second group there are those that detect antigens or those that detect antibodies (IgM / IgG).

Regarding antigen-detection, there are not many studies that demonstrate the Se and Sp of nasopharyngeal swabs in SARS-CoV-2. However, it appears that the viral load is higher in the nasal passages than in the oropharynx, and that in the first days of infection the viral load ranges from 10⁴ to 10⁸ RNA copies per mL. This would suggest that the SARS-CoV-2 Ag detection could have good Se if a good antibody is available. The advantages of this test are the adequate Se and the speed, since immunochromatography tests usually produce results in about 15–30 min. The main disadvantage is the difficulty in processing a large number of samples in a short period of time.

The detection of specific IgM and IgG antibodies allows the immune response to the virus to be qualitatively and quantitatively characterised. Once infected by SARS-CoV-2, IgM is detected from 3–5 days from the onset of symptoms and disappears around day 21 post-infection. IgG appears later, and is normally detected after 14 days, increasing during the convalescence period. IgG remain in the blood beyond the convalescence period, providing the hoped-for long-term immunity which is yet to be confirmed.^{3,4}

Recently, the techniques *gold immunochromatography assay* (GICA) and ELISA were used to study the possible interaction in the detection test for SARS-CoV-2 IgM antibodies. A total of 86 serum samples from different patients were used: 5 influenza A virus (flu A) IgM-positive sera, 5 influenza B virus (flu B) IgM-positive sera, 5 *Mycoplasma pneumoniae* IgM-positive sera, 5 *Legionella pneumophila* IgM-positive sera, 6 sera of HIV infection patients, 36 for rheumatoid factor IgM (RF-IgM)-positive sera, 5 sera from hypertensive patients, 5 sera from diabetes mellitus patients, and 14 sera with SARS-CoV-2 infection.⁵ The factors causing FP IgM antibodies were analysed. In addition, the urea dissociation test was used to dissociate the SARS-CoV-2 IgM-positive serum of using the best dissociation concentration. Positive SARS-CoV-2 IgM was detected in 22 middle-high level RF-IgM-positive sera and, as expected, in all 14 samples from COVID-19 patients. The other 50 sera were negative. When using GICA and ELISA to detect SARS-CoV-2 IgM, the level of RF-IgM in the serum is indirectly quantified and the urea dissociation test should be performed to avoid the risk of FP results. When the urea dissociation concentration was 6 mol/L, SARS-CoV-2 IgM was positive in one middle-high level RF-IgM-positive serum and in all 14 sera from COVID-19 patients. When the urea dissociation concentration was 4 mol/L and the avidity index (AI) lower than 0.371 was set to negative, the test results were positive for SARS-CoV-2 in 3 middle-high level RF-IgM-positive sera, as well as in the 14 COVID-19 sera. The authors concluded that, to detect SARS-CoV-2 IgM, the level of RF-IgM in the serum should be assessed and the urea dissociation test should be performed to avoid the risk of FP results.

However, the urea dissociation test cannot completely eliminate RF-IgM interference. Therefore, when SARS-CoV-2 IgM results are still positive after urea dissociation, PCR should be used for viral nucleic acid diagnosis. These data suggest that the methods described should be used to eliminate or reduce the impact of cross-reaction when using GICA and ELISA methods for the detection of SARS-CoV-2 IgM. This fact would mean an improvement in the screening of suspected cases and high-risk groups, as well as in the evaluation, prevention and control of SARS-CoV-2.

The rapid evolution of the pandemic has required an agile and accelerated response. Knowledge about SARS-CoV-2 is increasing, but there is still a need to study the discrepancies in the methods of diagnosing the disease. It is important to intensify studies of each of the tests and the causes of the possible FP results, and especially in RF-positive diseases such as rheumatoid arthritis and Sjögren's syndrome.

[☆] Please cite this article as: Vinyé Bausà M, Bausà Peris R, Corominas H. Reacciones cruzadas entre factor reumatoide e IgM SARS-CoV-2. Med Clin (Barc). 2020;155:417–18.

References

- Hernandez-Perez JM, Martin-Gonzalez E, Pino-Yanes M. Virtudes y dificultades en los test diagnósticos de la infección por el SARS-CoV-2. Med Clin. 2020. <http://dx.doi.org/10.1016/j.medcli.2020.05.019>.
- Constan Rodríguez J, Fernández Roldán C, López Robles C. El test rápido de inmunoglobulinas confirma un caso sospechoso de COVID-19. Med Clin. 2020. <http://dx.doi.org/10.1016/j.medcli.2020.04.008>.
- Sociedad Española de Enfermedades Infecciosas y Microbiología Clínica: Documento de posicionamiento de la SEIMC sobre el diagnóstico microbiológico de COVID-19. <https://seimc.org/documentoscientificos/recomendaciones/seimc-rc-2020>.
- López J, Mitja O. Salida coordinada del confinamiento. Propuesta de intervenciones de salud pública para el control de la infección SARS-CoV-2 en la comunidad. https://www.diariandorra.ad/uploads/documentos/2020/04/03/document_5f7df7f4.pdf.
- Wang Q, Du Q, Guo B, et al. A method to prevent SARS-CoV-2 IgM false positives in gold immunochromatography and enzyme-linked immunosor-

rent assays. J Clin Microbiol. 2020. JCM.00375-20. doi:10.1128/JCM.00375-20. <https://jcm.asm.org/content/jcm/early/2020/04/09/JCM.00375-20.full.pdf>.

Marta Vinyé Bausà^a, Rosa Bausà Peris^b, Hèctor Corominas^{a,c,*}

^a Universitat Autònoma de Barcelona (UAB), Barcelona, Spain

^b Servei de Salut Laboral, Hospital Universitari de la Sant creu i Sant Pau, Barcelona, Spain

^c Servei de Reumatologia, Hospital Universitari de la Sant creu i Sant Pau, Barcelona, Spain

* Corresponding author.

E-mail address: vancor@yahoo.com (H. Corominas).

2387-0206/ © 2020 Elsevier España, S.L.U. All rights reserved.

Glucagonoma-related necrolytic migratory erythema[☆]



Eritema necrolítico migratorio asociado a glucagonoma

Dear Editor,

Necrolytic migratory erythema (NME) is a rare dermatosis usually associated to glucagonoma, a neuroendocrine tumour of the alpha-cells of the pancreatic islets. There is often a delay of years in the diagnosis of this neoplasm, which can be due to its low incidence rate or to its nonspecific symptoms. Below we present the

case of a woman diagnosed with glucagonoma as a result of skin lesions suggestive of NME. We believe it is important to promulgate this dermatosis, as it is a clinical sign that can help establish an earlier diagnosis of the neoplasm.

We present the case of a 45-year-old woman with a 2-year history of recalcitrant skin lesions without complete improvement after topical and oral corticosteroid treatment. The physical examination revealed multiple, inflammatory, erythematous to violaceous coloured, annular plaques with well-defined borders and central epidermal detachment on both legs (Fig. 1A),

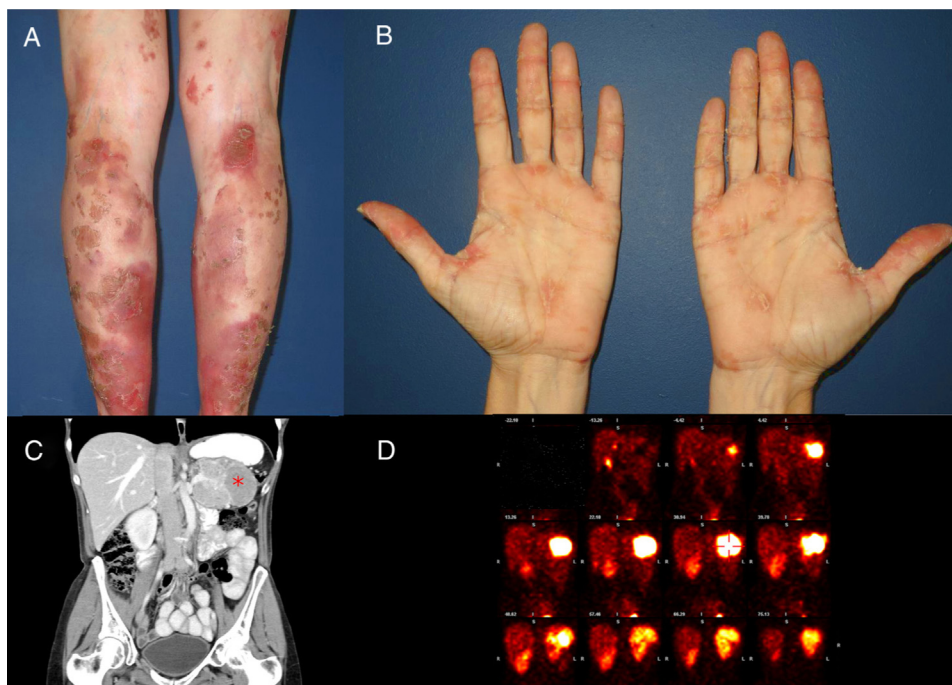


Fig. 1. A) Erythematous to violaceous coloured, annular plaques on both legs, with well-defined borders and central epidermal detachment suggestive of migratory necrolytic erythema. B) Epidermal detachment and desquamation on both palms. C) Computed tomography: polylobulated mass in the pancreatic tail of 82 × 53 × 61 mm (*) compatible with primary pancreatic tumour. D) A SPECT scan using radiopharmaceutical ¹¹¹In-octreotide: neoplastic process in the pancreatic tail with somatostatin receptors suggestive of glucagonoma.

[☆] Please cite this article as: Bosch-Amate X, Riera-Monroig J, Iranzo Fernández P. Eritema necrolítico migratorio asociado a glucagonoma. Med Clin (Barc). 2020;155:418–19.