

[CASE REPORT]

A Combination of Indomethacin Farnesyl and Amitriptyline Is Effective for Continuous Interictal Pain with Probable Chronic Paroxysmal Hemicrania

Shoji Kikui, Junichi Miyahara, Hanako Sugiyama, Mutsuo Kohashi, Kuniko Ota, Daisuke Danno, Yoshihiro Kashiwaya and Takao Takeshima

Abstract:

A 26-year-old woman with a history of migraine reported right-sided, severe stabbing orbital pain with cranial autonomic symptoms (CASs) for approximately 2 years. The attack duration was approximately 30 minutes, with a frequency of twice per day. Taking loxoprofen was ineffective. Six months earlier, moderate pressing continuous interictal pain without CASs had developed. Indomethacin farnesyl completely resolved the attacks but had no effect on the interictal pain. The patient was diagnosed with probable chronic paroxysmal hemicrania in accordance with the International Classification of Headache Disorders (ICHD-3) (third version). Continuous interictal pain gradually disappeared with a combination of indomethacin farnesyl and amitriptyline.

Key words: chronic paroxysmal headache, interictal pain, indomethacin farnesyl, amitriptyline, migraine

(Intern Med 61: 413-417, 2022)

(DOI: 10.2169/internalmedicine.7511-21)

Introduction

Paroxysmal hemicrania (PH) is a rare primary headache belonging to a group of trigeminal autonomic cephalalgias (TACs) (1). The current third edition of the International Classification of Headache Disorders (ICHD-3) requires at least 20 attacks of severe unilateral orbital, supraorbital, or temporal pain, lasting 2-30 minutes, accompanied by cranial autonomic symptoms (CASs), such as ipsilateral conjunctival injection, lacrimation, nasal congestion, rhinorrhea, forehead and facial sweating, miosis, ptosis or eyelid edema, and restlessness or agitation (1).

PH is estimated to account for 11-37% of cluster headaches, with a prevalence of approximately 0.02% in the general population (2). Previous studies have reported a mean age range at the PH onset of 37-42 years old (2). The disorder has an absolute response to indomethacin, such that patients are rendered pain-free by therapeutic doses (1).

PH can be divided into episodic PH and chronic PH (CPH), distinguished by the presence or absence of a remis-

sion period lasting at least three months on an annual basis (1). CPH accounts for 80% of cases of PH (2, 3). PH is not typically characterized by interictal pain. However, mild and intermittent interictal pain can be experienced in the same distribution as typical PH attacks (3).

We herein report a case of probable CPH with moderate and continuous interictal pain. To our knowledge, this represents the first clinical case report of treatment for interictal pain with PH.

Case Report

The patient was a 26-year-old Japanese woman who presented to our headache center with a 2-year history of right-sided, excruciatingly severe, stabbing pain located in her orbit. The attacks were associated with lacrimation and rhinorrhea, as well as restlessness and migrainous features, such as nausea. The duration of the attacks was approximately 30 minutes, with a frequency of twice per day. Occasionally, mild intermittent pressing interictal pain without CAS developed in the same distribution as the severe attacks. Her par-

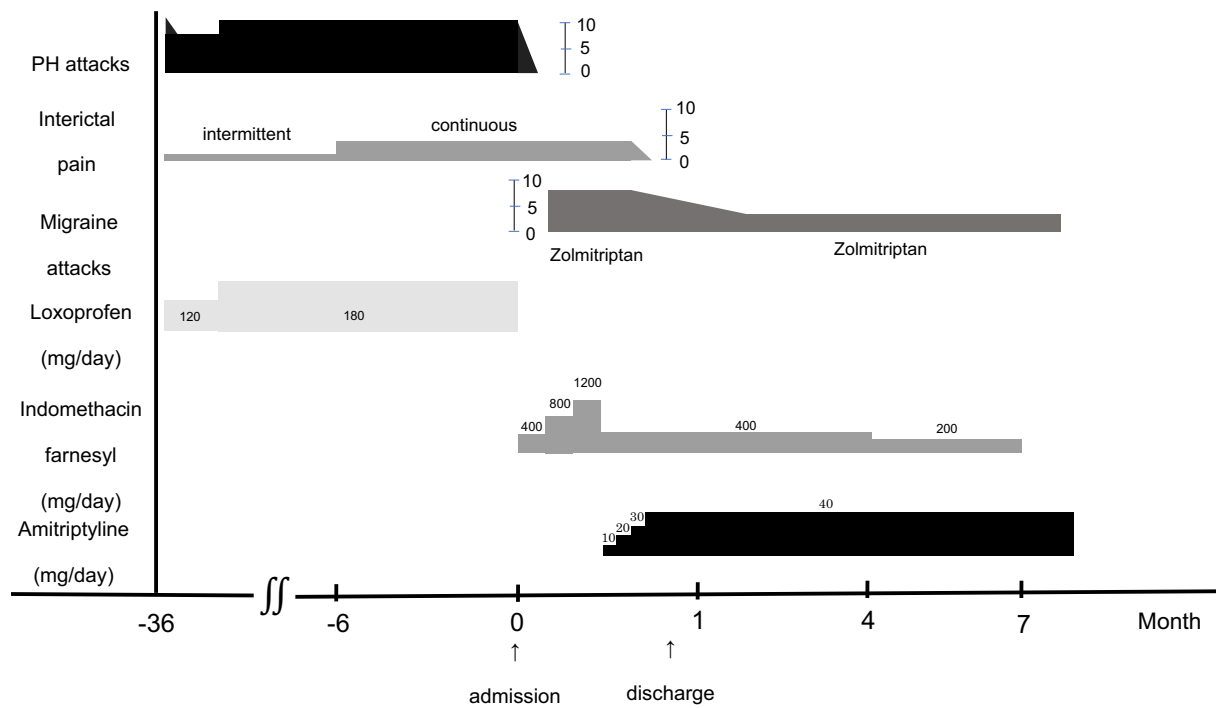


Figure. The patient's clinical course. A numeric rating scale (NRS) was used to evaluate patient's pain. The NRS consists of a numeric version of the visual analog scale. It is a horizontal line with an 11-point numeric range, labeled from 0 to 10, with 0 being an example of someone with no pain and 10 being the worst pain possible. PH: paroxysmal hemicrania

ents reported no history of headache disorders. She was a non-smoker and a non-alcoholic drinker. The patient had also experienced a throbbing pain in both temples that lasted approximately 12 hours with nausea several times per month since high school. These headaches improved by resting or taking over-the-counter medications and were suggested to be migraines. However, these medications had little effect on the new headache attacks. The migraine symptoms described by the patient rarely appeared after the onset of the new headaches.

She initially visited a general physician, where she was diagnosed with a tension-type headache and prescribed loxoprofen. Loxoprofen had a mild effect on her new headaches, but the effect gradually diminished. Three months after visiting the general physician, she began to take the drug three times daily. Starting six months prior to visiting our center, her interictal pain became continuous and moderate. She visited the neurosurgery department and was suspected of having a medication-overuse headache. Thus, she was referred and admitted to our headache center.

Her vital signs and physical and neurological examination results were normal. No trigger factors were identified. Electrocardiograms and laboratory testing results were also normal. Brain magnetic resonance imaging, magnetic resonance angiography, and venography showed normal findings. A diagnosis of PH was considered.

The clinical courses are shown in Figure. She was prescribed indomethacin farnesyl (400 mg/day; equivalent to approximately 50 mg/day indomethacin), and her severe at-

tacks completely resolved after 3 days. However, the continuous interictal pain did not resolve. To differentiate hemicrania continua (HC), the dose of indomethacin farnesyl was increased to 1,200 mg/day (equivalent to approximately 150 mg/day indomethacin) with the informed consent of the patient. However, the interictal pain did not disappear. We considered CPH with continuous interictal pain, although the number of attacks per day was low for a CPH diagnosis. Therefore, the patient was diagnosed with probable CPH in accordance with the ICHD-3 (1).

After remission of the PH attack, moderate throbbing pain in both temples with nausea that lasted approximately six hours once or twice daily appeared. This pain was diagnosed as a migraine without aura. Zolmitriptan (2.5 mg) was prescribed, although it had a poor effect. Migraine prophylaxis was needed. Valproate was not selected because the patient was a young woman of childbearing years. Alternative drugs, including cyclooxygenase-2 inhibitors (celecoxib, rofecoxib), anti-epileptic drugs (topiramate, gabapentin), calcium channel blockers (flunarizine, verapamil), have been used for PH and HC patients with poor tolerability for long-term indomethacin treatment (4). The additional administration of these drugs may make it difficult to distinguish between PH and HC. To our knowledge, amitriptyline has not been reported as an alternative drug for PH and HC. Thus, amitriptyline was selected as a migraine prophylaxis. The dose of indomethacin farnesyl was decreased to 400 mg/day, and amitriptyline was started at 10 mg/day for migraine prophylaxis, with a gradual increase to 40 mg/day. Zolmitriptan

Table 1. General Differences and Similarities between Paroxysmal Hemicrania Attack and Interictal Pain.

	PH attack	Interictal pain
Intensity	Severe	Mild
Duration	2-30 min	Intermittent
Distribution pattern of pain	Orbital, supraorbital, temporal or in any combination of these sites	Same distribution of PH attacks
Accompanied with ipsilateral CAS	Yes	No
Response to indomethacin	Yes	N.D.

The interictal pain in our patient was moderate and continuous.

PH: paroxysmal hemicrania, CAS: cranial autonomic symptoms, N.D.: no data

became effective, and the continuous interictal pain gradually disappeared. Mild drowsiness was observed with the increased amitriptyline dosing but was gradually ameliorated. The patient was eventually discharged from our headache center.

In the first three months following discharge, she had about five monthly migraine days (MMDs), and the effect of zolmitriptan was sustained. The PH with interictal pain did not appear. Over the next 3 months, the dose of indomethacin farnesyl was decreased to 200 mg. However, the MMDs did not change, and the PH with interictal pain remained in remission. Eventually, indomethacin farnesyl was discontinued. However, the PH attacks and interictal pain did not appear.

In the future, we intend to decrease the dose of amitriptyline while monitoring the MMDs.

Discussion

PH typically has prominent CASs, whereas in HC, these features are modest or inconstant (5-7). Furthermore, in PH, the attacks are much more severe and the attack length shorter than in HC (5-7). A careful history supplemented with a headache diary allows these two headache types to be differentiated. However, it can sometimes be challenging to differentiate between PH and HC, particularly in patients with CPH and continuous interictal pain.

In our case, the diagnosis of HC was inconsistent with the finding that pain, including interictal pain, was not completely resolved by indomethacin. In adults, the ICHD-3 recommends that oral indomethacin be used initially at a dose of ≥ 150 mg daily and increased if necessary up to 225 mg daily (1). Approximately 40-50% of HC patients show a complete response at ≤ 150 mg/day, while $>40\%$ patients may require ≥ 225 mg/day (7, 8). Compared with the international standard, the dose of indomethacin farnesyl might be insufficient for the diagnosis of HC. However, the Japanese clinical practice guidelines for chronic headache recommend a lower dose of indomethacin (up to 75 mg/day orally or 100 mg/day as a suppository) (9). As production of the oral formulation of indomethacin was discontinued in April 2020 and the insurance coverage of indomethacin farnesyl is 400 mg/day in Japan, we refrained from the further administra-

tion of indomethacin farnesyl.

In an earlier review of 84 patients, 28 (33%) had interictal pain or discomfort (10). Prakash et al. (6) also reported that 8 of 17 (47%) PH patients had reported interictal pain, including 7 (88%) with intermittent pain and 1 (12%) with continuous pain that had been intermittent during the early years of the disease, similar to our case. In that study, the authors compared patients with interictal pain to those with no pain. PH with interictal pain had a longer duration of illness (69.0 vs. 10.7 months, respectively; $p=0.0006$) and required a high dose of indomethacin (188 vs. 114 mg, respectively; $p=0.0018$).

Cittadini et al. (5) reported that 18 of 31 (58%) PH patients had interictal pain, 16 (51%) had a personal history positive for migraine, 18 (58%) had a family history positive for migraine (and/or headache not otherwise specified), and 10 (32%) had medication overuse. Regarding PH with interictal pain only, 14 patients (78%) had a personal or family history positive for migraine (and/or headache not otherwise specified), and 8 (44%) had medication overuse. In that study, interictal pain was relatively mild compared with the attack pain with PH (5).

The differences and/or similarities in headache frequency, location, severity, and accompanying features between PH attack and interictal pain are shown in Table 1. The possibility of overlap with tension-type headache is difficult to mitigate. Since interictal pain has the same distribution as PH attacks, we may be able to distinguish it from tension-type headache. Because HC is the most important differential disease for PH with interictal pain, it is essential to confirm the reactivity for indomethacin. Paradoxically, if the administration of a sufficient dose with indomethacin causes residual pain without CASs, it may be interictal pain.

Primary headaches, such as migraine and TACs, are commonly associated with interictal pain (11) (Table 2). However, there had been few reports of interictal pain in primary headaches, and the cause is unclear. Medication overuse may be a major contributor to chronic daily headache. It was previously suggested that longstanding chronic pain may lead to cortical changes in the brain, which may be responsible for interictal pain and refractoriness to therapy (11-13). Migraine patients are much more likely to experience worsening with acute medication overuse than

Table 2. Frequency of Interictal Pain in Migraine and Trigeminal Autonomic Cephalalgias.

Headache disorder	Frequency	Characteristics
Migraine	Most patients with chronic migraine	Can be mild, moderate or severe
Cluster headache	42-54%	Especially if chronic CH. Unilateral and mild
Paroxysmal hemicrania	58%	Usually mild, intermittent
SUNHA	46% in SUNCT, 28% in SUNA	N.D.
Hemicrania continua	100%	Moderate or severe, continuous

Modified from reference 11 with permission from Springer Nature.

SUNHA: short-lasting unilateral neuralgiform headache, SUNCT: short-lasting unilateral neuralgiform headache attacks with conjunctival injection and tearing, SUNA: short-lasting unilateral neuralgiform headache attacks with cranial autonomic symptoms, N.D.: no date

those with other pain disorders (14), and cluster headache patients with a personal or family history of migraine are also susceptible (15). Marmura et al. (12) reported that 27 out of 50 (54%) cluster headache patients had some sort of interictal pain, including 16 (59%) who had pain more than half the time and 10 (37%) who had continuous pain. In that study, cluster headache patients with interictal pain more than half the time were more likely to have an increased disease severity, such as chronic cluster headache, a suboptimal response to sumatriptan, cutaneous allodynia during and outside of the attacks, and a disease duration ≥ 15 years (12). Given the clinical similarities, such as unilateral headache attacks associated with CASs, between the different TACs, it has been hypothesized that these headache forms share pathophysiological mechanisms (16). Not only cluster headache patients but also PH patients with a personal or family history of migraine may be susceptible to medication overuse.

Based on these findings, we conclude that interictal pain in PH is not uncommon and is associated with a long illness duration, refractoriness to therapy, history of migraine, and medication overuse. Our present patient had a short illness duration of PH. Therefore, a history of migraine may be involved in the development of interictal pain, which can become continuous and intense during the course of medication overuse. Loxoprofen overuse may have suppressed the appearance of our patient's migraines after the onset of the PH attacks. Due to the remission of the PH attacks and discontinuation of loxoprofen overuse, her latent migraines may have become active. The disappearance of the continuous interictal pain with migraine prophylaxis following amitriptyline treatment in our case suggests that the pain was associated with migraine biology and medication overuse.

Interictal pain with PH is usually intermittent and mild, so it does not necessarily require treatment. That may be the reason why there have been no reports of treatment for interictal pain with PH. However, continuous and moderate interictal pain with PH, such as in our case, requires treatment. For refractory cluster headache patients with interictal pain or allodynia, the use of cyclooxygenase-2 inhibitors (17) or preventatives that inhibit allodynia [e.g., gabapentin (18, 19)] should be considered for optimal results. These drugs may be effective for interictal pain with PH,

but their use makes it difficult to distinguish between PH and HC. The combination of indomethacin and migraine prophylaxis, such as amitriptyline, may be effective against interictal pain with PH if PH patients have comorbid migraine biology. It is important to confirm a history of migraine and medication overuse when examining PH patients with interictal pain. By considering cases of interictal pain with PH, we may be able to determine the pathological mechanism underlying interictal pain in other types of primary headache.

The authors state that they have no Conflict of Interest (COI).

References

- Headache Classification Subcommittee of the International Headache Society. The international classification of headache disorders 3rd edition. *Cephalalgia* **38**: 1-211, 2018.
- Prakash S, Patell R. Paroxysmal hemicrania: an update. *Curr Pain Headache Rep* **18**: 407, 2014.
- Osman C, Bahra A. Paroxysmal hemicrania. *Ann Indian Acad Neurol* **21** (Suppl 1): 16-22, 2018.
- Miller S, Matharu M. Trigeminal autonomic cephalalgias: beyond the conventional treatments. *Curr Pain Headache Rep* **18**: 438, 2014.
- Cittadini E, Matharu MS, Goadsby PJ. Paroxysmal hemicrania: a prospective clinical study of 31 cases. *Brain* **131**: 1142-1155, 2008.
- Prakash S, Belani P, Susvirkar A, Trivedi A, Ahuja S, Patel A. Paroxysmal hemicrania: a retrospective study of a consecutive series of 22 patients and a critical analysis of the diagnostic criteria. *J Headache Pain* **14**: 26, 2013.
- Cittadini E, Goadsby PJ. Hemicrania continua: a clinical study of 39 patients with diagnostic implications. *Brain* **133**: 1973-1986, 2010.
- Prakash S, Golwala P. A proposal for revision of hemicrania continua diagnostic criteria based on critical analysis of 62 patients. *Cephalalgia* **32**: 860-868, 2012.
- Araki N, Takeshima T, Ando N, et al. Clinical practice guideline for chronic headache 2013. *Neurol Clin Neurosci* **7**: 252-254, 2019.
- Antonaci F, Sjaastad O. Chronic paroxysmal hemicrania (CPH): a review of the clinical manifestations. *Headache* **29**: 648-656, 1989.
- Marmura MJ, Young WB. Interictal pain in primary headache syndromes. *Curr Pain Headache Rep* **16**: 170-174, 2012.
- Marmura MJ, Pello SJ, Young WB. Interictal pain in cluster headache. *Cephalalgia* **30**: 1531-1534, 2010.
- Prakash S, Golwala P. Phantom headache: pain memory-emotion

- hypothesis for chronic daily headache? *J Headache Pain* **12**: 281-286, 2011.
- 14.** Ferrari A, Leone S, Tacchi R, et al. The link between pain patient and analgesic medication is greater in migraine than in rheumatic disease patients. *Cephalgia* **29**: 31-37, 2009.
- 15.** Paemeleire K, Evers S, Goadsby PJ. Medication-overuse headache in patients with cluster headache. *Curr Pain Headache Rep* **12**: 122-127, 2008.
- 16.** Giani L, Proietti Cecchini A, Leone M. Cluster headache and TACs: state of the art. *Neurol Sci* **41** (Suppl 2): 367-375, 2020.
- 17.** Prakash S, Dholakia SY, Shah KA. A patient with chronic cluster headache responsive to high-dose indomethacin: is there an overlap with chronic paroxysmal hemicrania? *Cephalgia* **28**: 778-781, 2008.
- 18.** Schuh-Hofer S, Israel H, Neeb L, Reuter U, Arnold G. The use of gabapentin in chronic cluster headache patients refractory to first-line therapy. *Eur J Neurol* **14**: 694-696, 2007.
- 19.** Berry JD, Petersen KL. A single dose of gabapentin reduces acute pain and allodynia in patients with herpes zoster. *Neurology* **65**: 444-447, 2005.

The Internal Medicine is an Open Access journal distributed under the Creative Commons Attribution-NonCommercial-NoDerivatives 4.0 International License. To view the details of this license, please visit (<https://creativecommons.org/licenses/by-nc-nd/4.0/>).