



Effect of Ultrasound-Guided Fascia Iliac Compartment Block with Nalbuphine and Ropivacaine on Preoperative Pain in Older Patients with Hip Fractures: A Multicenter, Triple-Blinded, Randomized, Controlled Trial

Fengyi Huang · Haitao Qian · Fei Gao · Jianghu Chen ·
Guopan Zhang · Yonglin Liu · Yijia Chen · Xinqiang Lin ·
Fei Chen · Wei Song · Daihe Yang · Wenbin Chen · Changcheng Jiang ·
Chuyun Liu · Ting Zheng · Cansheng Gong · Peng Ye ·
Xiaochun Zheng

Received: April 14, 2022 / Accepted: May 17, 2022 / Published online: June 8, 2022
© The Author(s) 2022

ABSTRACT

Introduction: Pain management for older patients with hip fractures is challenging. This study aimed to investigate the effect of ultrasound-guided fascia iliac compartment block (UGFICB) using different doses of nalbuphine in

combination with ropivacaine on preoperative analgesia in older patients with hip fractures.

Methods: In this multicenter randomized controlled trial, 280 elderly patients with hip fracture were randomly allocated into four UGFICB groups ($n = 70$ in each group): a ropivacaine group (30 mL 0.1% ropivacaine + 0.9% normal saline) and three ropivacaine plus nalbuphine groups (5, 10, and 20 mg nalbuphine, respectively). The primary outcomes were the duration of analgesia at rest and on passive movement. Secondary outcomes included sen-

Fengyi Huang, Haitao Qian, Fei Gao, and Jianghu Chen contributed equally to this work.

F. Huang · H. Qian · F. Gao · J. Chen · T. Zheng ·
C. Gong · P. Ye · X. Zheng (✉)
Department of Anesthesiology, Shengli Clinical
Medical College of Fujian Medical University, Fujian
Provincial Hospital, No. 134 Dong Street, Fuzhou
350001, Fujian, China
e-mail: zhengxiaochun7766@163.com

G. Zhang · Y. Liu
Department of Anesthesiology, Quanzhou
Orthopedic-Traumatological Hospital, Quanzhou,
China

Y. Chen
Department of Anesthesiology, Longyan People's
Hospital, Longyan, Fujian, China

X. Lin
Department of Anesthesiology, The Affiliated
Hospital of Putian College, Putian, China

F. Chen
Department of Anesthesiology, Min Dong Hospital
of Ningde, Ningde, China

W. Song
Department of Anesthesiology, Zhengxing Hospital
of Zhangzhou, Zhangzhou, China

D. Yang
Department of Anesthesiology, The Second
Affiliated Hospital of Fujian University of
Traditional Chinese Medicine, Fuzhou, China

W. Chen
Department of Anesthesiology, Ningde Municipal
Hospital of Ningde Normal University, Ningde,
China

C. Jiang
Department of Anesthesiology, The First Hospital of
Quanzhou, Quanzhou, China

sory block area, side effects, and vital signs. The doses of rescue analgesia with parecoxib sodium were also analyzed.

Results: The addition of nalbuphine dose-dependently increased the duration of analgesia at rest and on passive movement ($P < 0.05$) and expanded the area of sensory block ($P < 0.05$). Compared with the ropivacaine group, the pain scores at rest and on movement at 6 and 8 h after the block were lower in three ropivacaine plus nalbuphine groups ($P < 0.05$), without between-group differences at 2, 4, and 12 h. The four groups had comparable side effects (nausea and vomiting) and vital signs ($P > 0.05$).

Conclusions: UGFICB with 5, 10, and 20 mg nalbuphine added to ropivacaine prolonged the analgesia duration, increased sensory block area, reduced pain, and decreased the doses of rescue parecoxib sodium for older patients after hip fracture, without obvious side effects. Among these three doses, nalbuphine 20 mg in combination with ropivacaine provided the longest duration of analgesia and the largest sensory block area.

Trial Registration: Chinese Clinical Trial Registry (ChiCTR2000029934).

Keywords: Nalbuphine; Ropivacaine; Fascia iliac compartment block; Preoperative; Hip fracture

Key Summary Points

In 2000, there were approximately 1.6 million people with hip fractures worldwide, and that number is expected to be 6.3 million by the year 2050. Patients with hip fractures often experience severe preoperative pain. Inadequate pain control leads to an increased risk of postoperative complications and delayed recovery after surgery.

The aim of our study was to investigate the efficacy of different doses of nalbuphine adjunct to ropivacaine for ultrasound-guided fascia iliac compartment block (UGFICB) on preoperative analgesia in older patients with hip fractures. We hypothesized that UGFICB with a higher dose of nalbuphine in combination with ropivacaine would provide the most effective pain relief with a long duration of analgesia and a favorable safety profile in these patients.

UGFICB with 5, 10, and 20 mg nalbuphine added to ropivacaine prolonged the analgesia duration, increased sensory block area, reduced pain, and decreased the doses of rescue parecoxib sodium for older patients after hip fracture, without obvious side effects. Among these three doses, nalbuphine 20 mg in combination with ropivacaine provides the longest duration of analgesia and the largest sensory block area.

C. Liu

Department of Anesthesiology, The Second Affiliated Hospital of Fujian Medical University, Quanzhou, China

X. Zheng

Fujian Provincial Institute of Emergency Medicine, Fujian Provincial Key Laboratory of Emergency Medicine, Fujian Provincial Key Laboratory of Critical Care Medicine, Joint Laboratory of Fujian's Belt and Road, Fuzhou, China

INTRODUCTION

Hip fracture surgery is one of the most commonly performed surgical procedures in older patients. In 2000, there were approximately 1.6 million hip fracture surgeries worldwide, and that number is expected to be 6.3 million by the year 2050 [1]. Patients with hip fractures often

experience severe preoperative pain. Inadequate pain control leads to an increased risk of postoperative complications and delayed recovery after surgery [2]. Opioids are effective intravenous anesthetics for patients undergoing surgery. However, the use of opioids is associated with opioid-related complications [3], such as oversedation, nausea, vomiting, urinary retention, and respiratory depression [4].

Nerve block techniques are widely performed for analgesia during the perioperative course. The implementation of nerve blocks helps to reduce opioid consumption and improve pain management after surgery [5]. Ultrasound-guided fascia iliac compartment block (UGFICB) is a technique that blocks several nerves (femoral nerve, lateral femoral cutaneous nerve, and obturator nerve), providing good analgesic effects in patients with hip fractures [6]. Studies showed that the use of UGFICB relieved preoperative pain and reduced the need for opioids [7, 8]. However, a notable shortcoming of UGFICB is the short analgesic duration of local anesthetics, which may not provide sufficient analgesia from the time of surgical ward admission to operation. Adjuvants such as dexmedetomidine, dexamethasone, clonidine, and fentanyl have been applied in combination with local anesthetics to prolong the duration of analgesia [9–12].

Recently, using adjuvants combined with local anesthetics to improve analgesia has become an interest of research in nerve blocks [13]. Nalbuphine, an opioid agonist–antagonist, has been used as an adjuvant to local anesthetics for intrathecal block [14] and brachial plexus block. Kalika et al. found that brachial plexus block with nalbuphine adjunct to ropivacaine prolonged the duration of sensory block and motor block compared with ropivacaine alone [15]. Additionally, nalbuphine combined with local anesthetics was associated with fewer adverse events such as respiratory depression and pruritus. However, there is no report on UGFICB with ropivacaine and nalbuphine for preoperative analgesia. Whether this combination prolongs the duration of analgesia of UGFICB in hip fracture surgery, as well as the optimal dose of nalbuphine, remains unclear.

Therefore, the aim of our study was to investigate the efficacy of different doses of nalbuphine adjunct to ropivacaine for UGFICB on preoperative analgesia in older patients with hip fractures. We hypothesized that UGFICB with a higher dose of nalbuphine in combination with ropivacaine would provide the most effective pain relief with a long duration of analgesia and a favorable safety profile in these patients.

METHODS

Study Patients

This is a multicenter, triple-blinded, randomized, controlled trial conducted in ten hospitals in Fujian, China. We initially planned to recruit patients in 12 hospitals. Two hospitals did not participate in this study owing to limited manpower, leaving ten hospitals. The trial protocol was approved by the ethics committee of Fujian Provincial Hospital (approval no. K2019-05-002), and approved by all participating hospitals: the ethics committee of Min Dong Hospital of Ningde (approval no. 1209-17), the Ethics Committee of Ningde Municipal Hospital of Ningde Normal University (approval no. 1209-17), the ethics committee of Quanzhou Orthopedic-Traumatological Hospital, the ethics committee of Longyan People's Hospital, the ethics committee of the Affiliated Hospital of Putian College, the ethics committee of Zhengxing Hospital of Zhangzhou, the ethics committee of the Second Affiliated Hospital of Fujian University of Traditional Chinese Medicine, the ethics committee of Normal University, the First Hospital of Quanzhou, and the ethics committee of the Second Affiliated Hospital of Fujian Medical University. Written informed consent was obtained from each patient or their next of kin. This study was conducted in accordance with the Declaration of Helsinki. This trial was prospectively registered at the Chinese Clinical Trial Registry (registration no. ChiCTR2000029934).

We enrolled older patients (aged 65–85 years) with hip fracture who were scheduled for surgery with the American Society of

Anesthesiologists (ASA) classification I–III and had a body mass index of 18.5–30 kg/m². We excluded patients with chronic pain, preoperative opioid use within the preoperative 24 h, allergy to ropivacaine or nalbuphine, blood coagulation abnormality, infection at the puncture site, severe systemic diseases, and refusal to participate. A total of 280 patients were randomly allocated into four study groups ($n = 70$ in each group): the ropivacaine group (the R group, 30 mL 0.1% ropivacaine + 0.9% normal saline), the ropivacaine and low-dose nalbuphine group (the R + LN group, 30 mL 0.1% ropivacaine + 5 mg nalbuphine), the ropivacaine and medium-dose nalbuphine group (the R + MN group, 30 mL 0.1% ropivacaine + 10 mg nalbuphine), and the ropivacaine and high-dose nalbuphine group (the R + HN group, 30 mL 0.1% ropivacaine + 20 mg nalbuphine).

Randomization and Blinding

Patients were randomized with an allocation ratio of 1:1:1:1 using computer-generated random numbers. The grouped results were concealed in sealed envelopes and kept by the research coordinator. A research assistant prepared the study medications according to the randomization results. The operators who performed UGFICB, data collectors, and the patients were all blinded to group assignment throughout the study.

UGFICB Procedure

After entering the treatment room in the surgical ward, patients received supplementary oxygen (3 L/min) via a nasal catheter. Blood pressure, electrocardiograph (ECG), and pulse oxygen saturation (SpO₂) were monitored. Patients were in supine position with hip abduction. Ultrasonography was performed using a portable color ultrasound device (EDGE, Sonosite) with a 6–13 MHz high-frequency probe. The UGFICB was performed using an inferior-inguinal approach. The area between the anterior–superior spine and symphysis was divided equally into three parts. The ultrasound

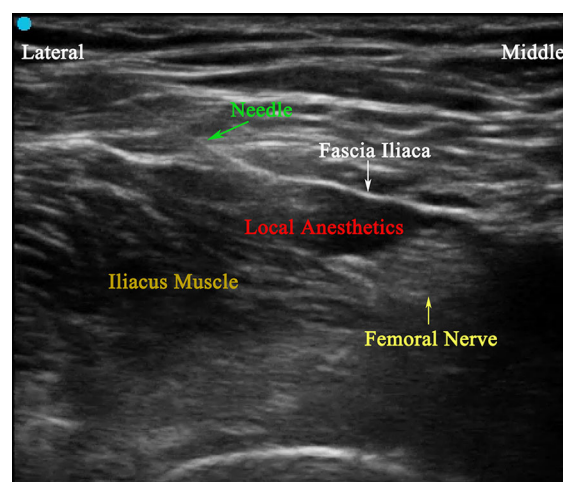


Fig. 1 Ultrasound image of UGFICB

probe was placed at the middle and lateral part parallel to the inguinal ligament to identify the femoral artery and femoral nerve. The needle was inserted in-plane from the lateral site to the fascia iliaca at the junction of the sartorius and iliacus muscles (Fig. 1). If there was no blood and gas during syringe aspiration, 2 mL normal saline was injected. After a good diffusion was observed, the study medications were slowly injected under visualization using ultrasonography. After UGFICB, the patients returned to their surgical ward.

Sensory Block Area

At 30 min after administration of the study medication, cold stimulation with an ice cube was used to test the sensation in the block area (the upper boundary was the inguinal ligament; the lower boundary was two fingers above the lower edge of patella; the medial boundary was the longitudinal line of medial femoral condyle; and the lateral boundary was the longitudinal of lateral femoral condyle). Dichotomy [16] (successful nerve block, effective/failed nerve block, ineffective) was applied to assess the level of sensation in the skin. Successful block was defined as lost or significantly decreased sensation to cold stimulation. Failed block was defined as normal sensation to cold stimulation. A transparent plastic film was used to draw a map of block area. Then, the block area (cm²)

was calculated using the Eloam S1500A2 (Shenzhen Liang tian Technology Co., Ltd) and Adobe Photoshop CC2017 (Adobe System, San Jose, California, USA). The block area at 2 h after UGFICB was used as reference (100%), and the percentage of block area at later study time-points was calculated.

Study Variables

Patient characteristics included age, gender, weight, height, body mass index (BMI), ASA status, comorbidities, fracture type, and time interval from the injury to nerve block. Visual analog scale (VAS, 0–10; 0 = no pain, 10 = the worst pain) was used to evaluate the pain intensity. Duration of analgesia at rest was defined as the time interval from the block to VAS pain scores at rest ≥ 3 . Pain on passive movement was assessed every hour after the block when the injured lower limb was elevated by 15°. Duration of analgesia on passive movement was defined as the time interval from the block to VAS pain scores on movement ≥ 3 . Rescue analgesia with 40 mg parecoxib sodium was administered intravenously for treatment of pain scores at rest ≥ 3 . No other analgesics were used throughout this study. The VAS pain scores were recorded at 2, 4, 6, 8, and 12 h after the block. Sensory block area was measured at 2 h and 8 h after the block. Heart rate (HR), mean artery blood pressure (MAP), and SpO₂ were recorded at 0, 10, 30, 60, and 120 min after the block. Side effects including nausea and vomiting were also recorded.

Statistical Analysis

The sample size calculation was based on the hypothesis that 10 mg nalbuphine as an adjunct to ropivacaine for UGFICB could prolong the analgesia duration. Our pilot observation showed that the analgesia duration on passive movement was 6.8 ± 2.8 h in the R group, 7.9 ± 3.0 h in the R + LN group, 8.6 ± 3.3 h in the R + MN, and 9.8 ± 3.8 h in the R + HN group. It was hypothesized that the addition of 10 mg nalbuphine could prolong the analgesia duration on passive movement by about 25%.

Thus, 62 patients were needed in each group with $\alpha = 0.05$ (two-tailed) and power = 0.9. To account for a 10% drop-out rate, the total sample size was 280 participants ($n = 70$ in each group). The sample size calculation was performed using the PASS software (version 15.0, NCSS, Kaysville, UT, USA).

Statistical analyses were performed using the SPSS software (version 23.0). Categorical data are presented as numbers (percentages) and were analyzed with Pearson chi-square test or Fisher exact test. Continue variable data are presented as mean \pm standard deviation or median (interquartile range) depending on distributions and were analyzed with one-way analysis of variance (ANOVA) if normally distributed or Kruskal–Wallis test if not normally distributed. A two-sided $P < 0.05$ was considered statistically significant.

RESULTS

A total of 312 older patients with hip fractures were assessed for eligibility. Of these, 32 patients were excluded due to refusal for participation and not meeting the eligibility criteria. Thus, 280 older patients were randomly assigned into four groups (Fig. 2). There were no differences in patient demographics and pre-operative comorbidities among the four groups ($P > 0.05$, Table 1).

Compared with ropivacaine alone, the addition of nalbuphine to ropivacaine dose-dependently prolonged the analgesia duration at rest (R group, 7.7 ± 1.4 h; R + LN group, 8.8 ± 1.1 h; R + MN group, 10.2 ± 1.1 h; R + HN group, 11.2 ± 1.4 h) and on passive movement (R group, 6.2 ± 1.0 h; R + LN group, 7.4 ± 1.0 h; R + MN group, 8.3 ± 1.2 h; R + HN group, 9.5 ± 1.1 h) (Table 2).

The VAS pain scores at rest and on movement were significantly lower at 6 and 8 h after UGFICB in the R + LN, R + MN, and R + HN groups than in the R group. In addition, the R + HN group had the lowest VAS pain scores both at rest and on movement ($P < 0.05$, Table 3; $P < 0.05$; Table 4). There were no significant differences in pain scores at 2, 4, and 12 h after the blocks among the three groups.

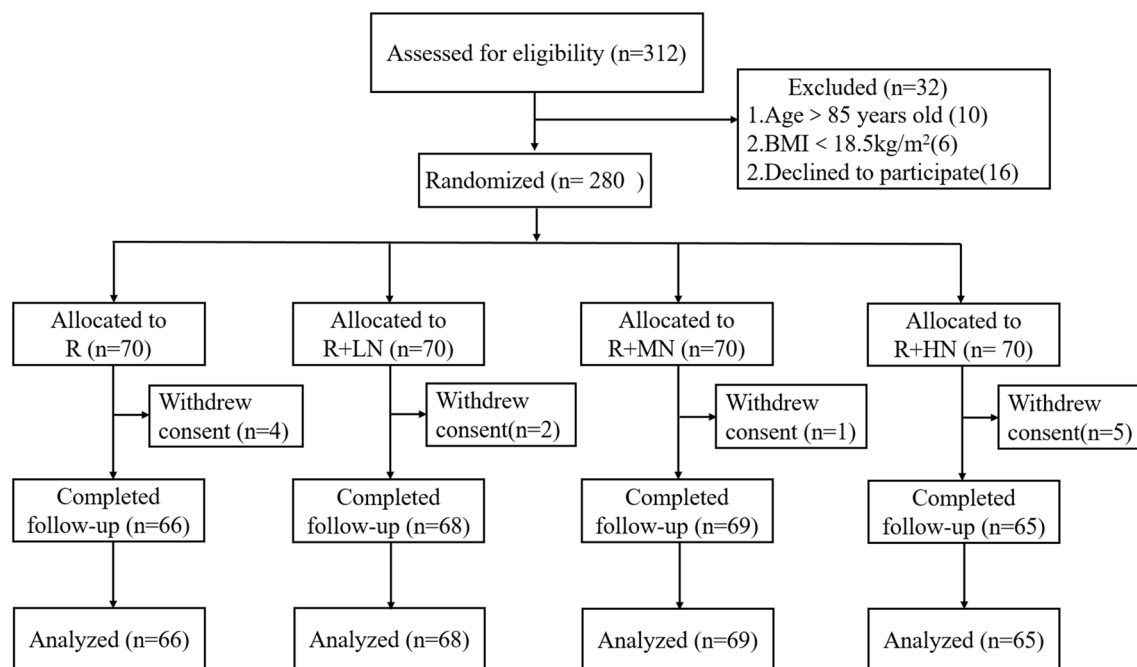


Fig. 2 Flowchart of the study. Group R: 30 mL 0.1% ropivacaine and 2 mL 0.9% normal saline; Group R + LN: 30 mL 0.1% ropivacaine and 5 mg (2 mL 0.25%) nalbuphine; Group R + MN: 30 mL 0.1%

ropivacaine and 10 mg (2 mL 0.5%) nalbuphine; Group R + HN: 30 mL 0.1% ropivacaine and 20 mg (2 mL 1%) nalbuphine

The area of sensory block was 100% in four groups at 2 h after UGFICB. Compared with ropivacaine alone, nalbuphine added to ropivacaine increased the percentage of sensory block area at 4 h after UGFICB (R group, $28.3 \pm 5.8\%$; R + LN group, $50.5 \pm 5.2\%$; R + MN group, $67.7 \pm 5.3\%$; R + HN group, $81.8 \pm 4.7\%$) (Table 5). The percentage of sensory block area in the R + HN group was larger than in the other groups. The percentage of sensory block area in the R + MN and R + HN groups was larger than in the R and R + LN groups (Table 5).

There were no differences in the incidence of nausea and vomiting among the four groups ($P > 0.05$, Table 6). None of the patients in this study developed respiratory depression or pruritus. Besides, the values of HR, MAP, and SpO₂ were comparable during the study period among the four groups ($P > 0.05$, Figs. 3, 4, 5).

DISCUSSION

The results of this study suggested that 5, 10, and 20 mg nalbuphine added to ropivacaine prolonged the analgesia duration, decreased the rescue parecoxib sodium doses, and increased the sensory block area compared with UGFICB using ropivacaine alone. Of these three doses, 20 mg nalbuphine was associated with the longest analgesia duration at rest and on passive movement and the largest sensory block area.

The VAS pain scores were measured at 2, 4, 6, 8, and 12 h after the block. The vital signs were recorded at 0, 10, 30, 60, and 120 min after the block. We only recorded the vital signs in the early postprocedure period. Overall, the patients in all groups had satisfactory pain relief at 2 h after the block, with a median VAS pain score of 0 both at rest and on movement. Of note, nalbuphine as an adjuvant to ropivacaine in UGFICB did not increase the incidence of side effects or influence vital signs in older patients with hip fractures.

Table 1 Patient demographic characteristics among the four groups

Variable	Group R (n = 66)	Group R + LN (n = 68)	Group R + MN (n = 69)	Group R + HN (n = 65)	P value
Age	76.7 ± 6.2	76.2 ± 6.1	75.1 ± 5.7	76.9 ± 5.6	0.12
Sex (male/female)	28/38	29/39	33/36	31/34	0.86
BMI (kg/m ²)	22.2 ± 3.1	23.1 ± 3.4	22.5 ± 3.6	22.8 ± 3.4	0.35
ASA status (I–II/III)	26/40	25/43	31/38	29/36	0.72
Type of fracture (neck of femur/ intertrochanteric)	29/37	32/36	38/31	30/35	0.59
Time interval from the injury to nerve block (h)	5.9 ± 1.5	6.3 ± 1.2	6.0 ± 1.2	6.3 ± 1.3	0.16
Preoperative comorbidities (number, %)					
Hypertension	31 (47.0)	37 (54.4)	31 (44.9)	32 (49.2)	0.71
Coronary heart disease	12 (18.2)	14 (20.6)	9 (13.0)	12 (18.5)	0.69
Diabetes mellitus	13 (19.7)	7 (10.3)	11 (15.9)	8 (12.3)	0.43
COPD	5 (7.6)	7 (10.3)	9 (13.2)	6 (9.2)	0.76

Data are expressed as mean ± standard deviation, or number (percentage)

BMI body mass index, ASA American Society of Anesthesiologist, COPD chronic obstructive pulmonary disease

Table 2 Duration of analgesia among the four groups

	Group R (n = 66)	Group R + LN (n = 68)	Group R + MN (n = 69)	Group R + HN (n = 65)	P value
Analgesia duration at rest (h)	7.7 ± 1.4	8.8 ± 1.1 ^a	10.2 ± 1.1 ^b	11.2 ± 1.4 ^c	<i>P</i> ^{abc} < 0.05
Analgesia duration on passive movement (h)	6.2 ± 1.0	7.4 ± 1.0 ^a	8.3 ± 1.2 ^b	9.5 ± 1.1 ^c	<i>P</i> ^{abc} < 0.05

Data are expressed as mean ± standard deviation

P^a < 0.05 (group R + LN versus group R), *P*^b < 0.05 (group R + MN versus group R + LN), *P*^c < 0.05 (group R + HN versus group R + MN)

Fascia iliac compartment is a potential compartment that consists of fascia iliac, iliopsoas, and iliopsoas fascia. Several nerves, including femoral nerve, lateral femoral cutaneous nerve, and obturator nerve, are located in the fascia iliac compartment. During fascia iliac compartment blocks, a sufficient volume of local anesthetics is generally needed with diffusing of the medications in the fascia iliac compartment. Fascia iliac compartment block was proposed by Dalens et al. in 1989 [17].

However, the failure rate was high in early fascia iliac compartment blocks using a landmark-guided technique [18, 19]. With the increasing use of the ultrasound technique, the successful rate of fascia iliac compartment has improved, and UGFICB is associated with significantly reduced rates of nerve injury and local anesthetic toxicity [20–22]. Hence, UGFICB procedures have been widely applied in patients undergoing lower limb surgery [23, 24].

Table 3 VAS scores at rest after UGFICB in the four groups and rescue parecoxib sodium dose

Time after UGFICB	Group R (n = 66)	Group R + LN (n = 68)	Group R + MN (n = 69)	Group R + HN (n = 65)	P value
2 h	0 (0–0)	0 (0–0)	0 (0–0)	0 (0–0)	0.65
4 h	0 (0–0)	0 (0–0)	0 (0–0)	0 (0–0)	0.47
6 h	2 (2–2)	2 (1–2) ^a	1 (1–1) ^b	1 (1–1) ^c	$P^{abc} < 0.05$
8 h	3 (2–3)	3 (2–3) ^a	1 (1–2) ^b	1 (1–1) ^c	$P^{abc} < 0.05$
12 h	3 (3–3)	3 (3–3)	3 (2–3)	3 (2–3)	0.79
Parecoxib sodium (mg)	43.7 ± 16.4	34.7 ± 13.7 ^a	26.7 ± 19.0 ^b	25.2 ± 19.0	$P^{ab} < 0.05$

Data are expressed as median (interquartile range) or mean ± standard deviation

$P^a < 0.05$ (group R + LN versus group R), $P^b < 0.05$ (group R + MN versus group R + LN), $P^c < 0.05$ (group R + HN versus group R + MN)

Ropivacaine, a long-acting amino amide local anesthetic, is widely used in nerve blocks. Ropivacaine causes less cardiac toxicity and a higher safety margin compared with bupivacaine [25]. For these reasons, ropivacaine was selected for UGFICB in our study. Studies showed that nerve blocks with 0.1% ropivacaine exerted a good analgesic action of sensory block without motor block [26–28]. Fascia iliaca compartment block with 30 mL 0.1% ropivacaine has been reported to block all nerves in the fascia iliaca compartment. In our study, a low concentration of 0.1% ropivacaine 30 mL was applied with or without the addition of nalbuphine. The relatively short duration of analgesia after a single injection of ropivacaine is a major limitation of UGFICB.

Nalbuphine is an opioid agent with μ antagonist and κ agonist properties. Studies have shown that opioids as an adjuvant improved the analgesic effects of local anesthetics [29, 30]. In this study, we found that UGFICB with ropivacaine plus nalbuphine prolonged the analgesia duration at rest and on passive movement, which is consistent with previous reports [15]. Furthermore, to investigate whether nalbuphine added to ropivacaine would result in a dose-dependent analgesic effect, we selected three dosages of nalbuphine: 5 mg (0.1%), 10 mg (0.5%), and 20 mg (1%). The results of this study demonstrated that

20 mg nalbuphine exerted a longer analgesia duration than the other groups without side effects. Besides that, the R + HN group had the lowest VAS pain score at rest and on movement, which suggested that nalbuphine added to ropivacaine could alleviate pain intensity in older patients with hip fractures. There were no differences in the incidences of nausea and vomiting among groups, but three patients in the R + HN group experienced nausea after surgery and two of them experienced vomiting. Prior studies have shown that nalbuphine added to ropivacaine or levobupivacaine prolonged the duration of sensory block and motor block in upper limb surgery [15, 31]. Rao et al. found that nalbuphine or dexmedetomidine as an adjuvant to ropivacaine in ultrasound-guided erector spinae plane block provided comparable pain control and prolonged sensory block duration in video-assisted thoracoscopic lobectomy surgery [32]. Consistent with previous studies, we found that the addition of nalbuphine prolonged the duration of analgesia and increased the sensory block area compared with ropivacaine alone. As the testing of sensory block area was a preliminary investigation of this study, we included 20 patients in each group for this test.

There are some possible mechanisms on the analgesic effects of opioids in peripheral nerve blocks. Nalbuphine acts on the opioid receptors

Table 4 VAS scores on passive movement after UGFICB in the four groups

Time after UGFICB	Group R (n = 66)	Group R + LN (n = 68)	Group R + MN (n = 69)	Group R + HN (n = 65)	P value
2 h	0 (0–0)	0 (0–0)	0 (0–0)	0 (0–0)	0.34
4 h	0 (0–1)	0 (0–1)	0 (0–1)	0 (0–1)	0.41
6 h	3 (2–3)	2 (2–3) ^a	2 (2–2) ^b	2 (1–2) ^c	$P^{abc} < 0.05$
8 h	4 (3–4)	3 (3–4) ^a	3 (2–3) ^b	2 (2–2) ^c	$P^{abc} < 0.05$
12 h	4 (4–4)	4 (3–4)	4 (3–4)	4 (3–4)	0.29

Data are expressed as median (interquartile range)

$P^a < 0.05$ (group R + LN versus group R), $P^b < 0.05$ (group R + MN versus group R + LN), $P^c < 0.05$ (group R + HN versus group R + MN)

Table 5 Percentage of block area at different times after UGFICB among the four groups

Time after UGFICB	Group R (n = 20)	Group R + LN (n = 20)	Group R + MN (n = 20)	Group R + HN (n = 20)	P value
2 h (%)	100 ± 0	100 ± 0	100 ± 0	100 ± 0	
6 h (%)	28.3 ± 5.8	50.5 ± 5.2 ^a	67.7 ± 5.3 ^b	81.8 ± 4.7 ^c	$P^{abc} < 0.05$
8 h (%)	0	0	25.9 ± 5.7 ^b	38.0 ± 3.0 ^c	$P^{bc} < 0.05$

Data are expressed as mean ± standard deviation

$P^a < 0.05$ (group R + LN versus group R), $P^b < 0.05$ (group R + MN versus group R + LN), $P^c < 0.05$ (group R + HN versus group R + MN)

Table 6 Side effects of nalbuphine among the four groups

	Group R (66)	Group R + LN (n = 68)	Group R + MN (n = 69)	Group R + HN (n = 65)	P value
Nausea	0 (0)	0 (0)	2 (2.9)	3 (4.6)	0.09
Vomit	0 (0)	0 (0)	2 (2.9)	2 (3.1)	0.24

Data are expressed as numbers (percentages). $P > 0.05$

in the spinal cord and peripheral nerves to exert analgesic effects. Nalbuphine inhibits the release of neurotransmitters, such as substance P, through activating κ receptors, thus providing a prolonged analgesic effect. Further, opioids may enhance the duration of analgesia of local anesthetics via synergistic effects with local anesthetics [33]. Opioids inhibit the transition of signal along the nerves by blocking

Ca^{2+} channels and activating inward K^+ channels [33]. Lastly, systemic absorption of nalbuphine also contributes to its analgesic effects [31]. While these putative mechanisms may contribute to the analgesic effect, the exact mechanisms of perineural administration of nalbuphine are not fully understood, necessitating further studies.

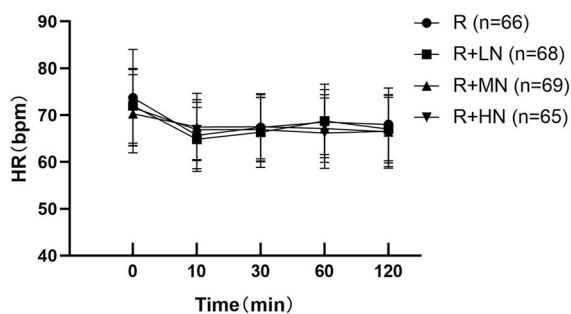


Fig. 3 Heart rate before and after UGFICB. There were no differences among the four groups at each time point ($P > 0.05$)

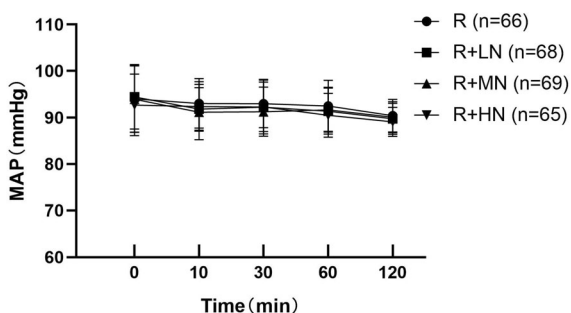


Fig. 4 Mean blood pressure before and after UGFICB. There were no differences among the four groups at each time point ($P > 0.05$)

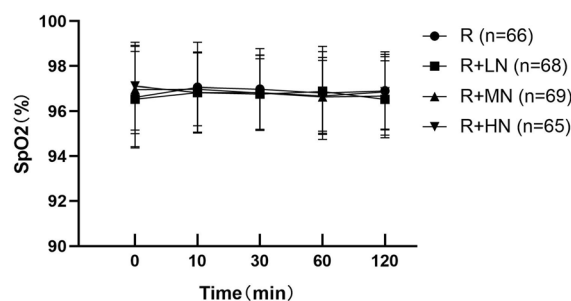


Fig. 5 SpO₂ before and after UGFICB. There were no differences among the four groups at each timepoint ($P > 0.05$)

Nausea and vomiting are the most frequent side effects of nalbuphine. Our results showed that there were no differences in nausea and vomiting among the four groups. To study the safety of nalbuphine as an adjuvant to ropivacaine, vital signs during the study period were

recorded. All patients had stable HR, MAP, and SpO₂, which suggested a high safety profile of UGFICB with nalbuphine and ropivacaine in older patients undergoing hip fracture surgery. Our results are in agreement with a previous study by Kalika et al. [15].

This study has several limitations. First, we showed that 20 mg nalbuphine added to ropivacaine had a longer analgesia duration than 5 or 10 mg nalbuphine. Further trials may still be required for nalbuphine with a dose higher than 20 mg. Second, we did not explore the mechanism of the analgesic effects of nalbuphine, which may be related to systemic absorption of the drug. Thus, further studies are needed to detect the plasma level of nalbuphine. Third, we tested the sensory block area in 20 patients only in each group. The limited number of patients may introduce bias for this outcome. Next, the VAS pain scores in our patients were measured for a total of 12 h after the block. This study would have been even more impactful if the pain scores were documented for 24 h. Last, this study was designed to ascertain the effects of duration of analgesia and different doses of nalbuphine plus ropivacaine for UGFICB on preoperative pain relief, and to quantify the area of sensory block. In theory, optimized preoperative analgesia contributes to reduction in preoperative stress response and improvements of patients' outcomes. However, we did not measure these variables in the present clinical trial. Future studies are warranted to assess the stress responses and longer-term outcomes in older patients with hip fractures receiving UGFICB with nalbuphine and ropivacaine.

CONCLUSION

This study suggests that nalbuphine added to ropivacaine in UGFICB for older patients with hip fractures provided better analgesia than ropivacaine alone. Twenty milligrams of nalbuphine may be the optimal dose with the strongest analgesic effects and longest duration of analgesia.

ACKNOWLEDGEMENTS

Funding. This study was funded by the Guidance Project of the Fujian Provincial Department of Science and Technology (2021Y0050), Natural Science Foundation of Fujian Province (2020J011078), Training Project for Talents of Fujian Provincial Health Commission (2019-ZQN-1), and the Education and Teaching Reform Project of Fujian Medical University (J200026). The journal's Rapid Service Fee was funded by all these resources.

Medical Writing and/or Other Assistance. This manuscript was proofread using the service of Medjaden, with the funding from the Guidance Project of the Fujian Provincial Department of Science and Technology (2021Y0050), Natural Science Foundation of Fujian Province (2020J011078), Training Project for Talents of Fujian Provincial Health Commission (2019-ZQN-1), and the Education and Teaching Reform Project of Fujian Medical University (J200026).

Author Contributions. Fengyi Huang and Haitao Qian designed the study and wrote the first draft of the manuscript. All named authors performed the ultrasound-guided fascia iliac compartment block and collected the clinical data. Xiaochun Zheng designed the study and revised the manuscript.

Disclosures. Fengyi Huang, Haitao Qian, Fei Gao, Jianghu Chen, Guopan Zhang, Yonglin Liu, Yijia Chen, Xinqiang Lin, Fei Chen, Wei Song, Daihe Yang, Wenbin Chen, Changcheng Jiang, Chuyun Liu, Ting Zheng, Cansheng Gong, Peng Ye and Xiaochun Zheng have nothing to disclose.

Compliance with Ethics Guidelines. The trial protocol was approved by the Ethics Committee of Fujian Provincial Hospital (Approval No. K2019-05-002), the Ethics Committee of Min Dong Hospital of Ningde (Approval No. 1209-17), the Ethics Committee of Ningde Municipal Hospital of Ningde Normal University (Approval No. 1209-17), the

Ethics Committee of Quanzhou orthopedic-traumatological hospital, the Ethics Committee of Longyan People's Hospital, the Ethics Committee of the Affiliated Hospital of Putian College, the Ethics Committee of Zhengxing Hospital of Zhangzhou, the Ethics Committee of the Second Affiliated Hospital of Fujian University of Traditional Chinese Medicine, the Ethics Committee of Normal University, the First Hospital of Quanzhou, and the Ethics Committee of the Second Affiliated Hospital of Fujian Medical University. Written informed consent was obtained from each patient or their next of kin. This study was conducted in accordance with the Declaration of Helsinki.

Data Availability. The datasets generated during and/or analyzed during the current study are available from the corresponding author on reasonable request.

Open Access. This article is licensed under a Creative Commons Attribution-NonCommercial 4.0 International License, which permits any non-commercial use, sharing, adaptation, distribution and reproduction in any medium or format, as long as you give appropriate credit to the original author(s) and the source, provide a link to the Creative Commons licence, and indicate if changes were made. The images or other third party material in this article are included in the article's Creative Commons licence, unless indicated otherwise in a credit line to the material. If material is not included in the article's Creative Commons licence and your intended use is not permitted by statutory regulation or exceeds the permitted use, you will need to obtain permission directly from the copyright holder. To view a copy of this licence, visit <http://creativecommons.org/licenses/by-nc/4.0/>.

REFERENCES

1. Cooper C, Cole ZA, Holroyd CR, Earl SC, Harvey NC, Dennison EM, et al. Secular trends in the incidence of hip and other osteoporotic fractures. *Osteoporos Int.* 2011;22:1277–88.

2. Feldt KS, Ryden MB, Miles S. Treatment of pain in cognitively impaired compared with cognitively intact older patients with hip-fracture. *J Am Geriatr Soc.* 1998;46:1079–85.
3. Dai W, Leng X, Hu X, Cheng J, Ao Y. The effect of fascia iliaca block on postoperative pain and analgesic consumption for patients undergoing primary total hip arthroplasty: a meta-analysis of randomized controlled trials. *J Orthop Surg Res.* 2021;16:444.
4. Madadi P, Ross CJ, Hayden MR, Carleton BC, Gaedigk A, Leeder JS, et al. Pharmacogenetics of neonatal opioid toxicity following maternal use of codeine during breastfeeding: a case-control study. *Clin Pharmacol Ther.* 2009;85:31–5.
5. Helander EM, Kaye AJ, Eng MR, Emelife PI, Motejunas MW, Bonneval LA, et al. Regional nerve blocks—best practice strategies for reduction in complications and comprehensive review. *Curr Pain Headache Rep.* 2019;23:43.
6. Kumar D, Hooda S, Kiran S, Devi J. Analgesic efficacy of ultrasound guided FICB in patients with hip fracture. *J Clin Diagn Res.* 2016;10:13–6.
7. Aprato A, Audisio A, Santoro A, Grosso E, Devivo S, Berardino M, et al. Fascia-iliaca compartment block vs intra-articular hip injection for preoperative pain management in intracapsular hip fractures: a blind, randomized, controlled trial. *Injury.* 2018;49:2203–8.
8. Williams H, Paringe V, Shenoy S, Michaels P, Ramesh B. Standard preoperative analgesia with or without fascia iliaca compartment block for femoral neck fractures. *J Orthop Surg (Hong Kong).* 2016;24:31–5.
9. Qian H, Zhang Q, Zhu P, Zhang X, Tian L, Feng J, et al. Ultrasound-guided transversus abdominis plane block using ropivacaine and dexmedetomidine in patients undergoing caesarian sections to relieve post-operative analgesia: a randomized controlled clinical trial. *Exp Ther Med.* 2020;20:1163–8.
10. Farooq N, Singh RB, Sarkar A, Rasheed MA, Choubey S. To evaluate the efficacy of fentanyl and dexmedetomidine as adjuvant to ropivacaine in brachial plexus block: a double-blind, prospective, randomized study. *Anesth Essays Res.* 2017;11:730–9.
11. Sakae TM, Marchioro P, Schuelter-Trevisol F, Trevisol DJ. Dexamethasone as a ropivacaine adjuvant for ultrasound-guided interscalene brachial plexus block: a randomized, double-blinded clinical trial. *J Clin Anesth.* 2017;38:133–6.
12. Singh R, Kumar N, Jain A, Joy S. Addition of clonidine to bupivacaine in transversus abdominis plane block prolongs postoperative analgesia after cesarean section. *J Anaesthesiol Clin Pharmacol.* 2016;32:501–4.
13. Abd-Elshafy SK, Abdallal F, Kamel EZ, Edwar H, Allah EA, Maghraby HHM, et al. Paravertebral dexmedetomidine in video-assisted thoracic surgeries for acute and chronic pain prevention. *Pain Physician.* 2019;22:271–80.
14. Chetty DK, Ahmed F, Chatterjee R, Rathore M. Comparison of intrathecal nalbuphine hydrochloride and clonidine hydrochloride as an adjuvant to hyperbaric bupivacaine in abdominal hysterectomy. *Anesth Essays Res.* 2018;12:402–6.
15. Kalika P, Xue R, Zheng J, Xiao Y, Zhen M, Ran R. Efficacy of nalbuphine as an adjuvant to ropivacaine in ultrasound-guided supraclavicular brachial block: a prospective randomized controlled study. *Clin J Pain.* 2020;36:267–72.
16. Chen Y, Shi K, Xia Y, Zhang X, Papadimos TJ, Xu X, et al. Sensory assessment and regression rate of bilateral oblique subcostal transversus abdominis plane block in volunteers. *Reg Anesth Pain Med.* 2018;43:174–9.
17. Dalens B, Vanneuville G, Tanguy A. Comparison of the fascia iliaca compartment block with the 3-in-1 block in children. *Anesth Analg.* 1989;69:705–13.
18. Minville V, Gozlan C, Asehnoune K, Zetlaoui P, Chassery C, Benhamou D. Fascia-iliaca compartment block for femoral bone fracture in prehospital medicine in a 6-yr-old child. *Eur J Anaesthesiol.* 2006;23:715–6.
19. Foss NB, Kristensen BB, Bundgaard M, Bak M, Heiring C, Virkelyst C, et al. Fascia iliaca compartment blockade for acute pain control in hip fracture patients: a randomized, placebo-controlled trial. *Anesthesiology.* 2007;106:773–8.
20. Dolan J, Williams A, Murney E, Smith M, Kenny GN. Ultrasound guided fascia iliaca block: a comparison with the loss of resistance technique. *Reg Anesth Pain Med.* 2008;33:526–31.
21. Fujihara Y, Fukunishi S, Nishio S, Miura J, Koyanagi S, Yoshiya S. Fascia iliaca compartment block: its efficacy in pain control for patients with proximal femoral fracture. *J Orthop Sci.* 2013;18:793–7.
22. Deniz S, Atım A, Kürklü M, Çaycı T, Kurt E. Comparison of the postoperative analgesic efficacy of an ultrasound-guided fascia iliaca compartment block versus 3 in 1 block in hip prosthesis surgery. *Agri.* 2014;26:151–7.

23. Jung J, Lee M, Chung YH, Cho SH. Successful use of ultrasound-guided peripheral nerve block for lower limb surgery in a patient with heart failure with reduced ejection fraction: a case report. *J Int Med Res.* 2021;49:3000605211045230.
24. Zheng T, Hu B, Zheng CY, Huang FY, Gao F, Zheng XC. Correction to: Improvement of analgesic efficacy for total hip arthroplasty by a modified ultrasound-guided supra-inguinal fascia iliaca compartment block. *BMC Anesthesiol.* 2021;21:99.
25. Rashmi HD, Komala HK. Effect of dexmedetomidine as an adjuvant to 0.75% ropivacaine in interscalene brachial plexus block using nerve stimulator: a prospective, randomized double-blind study. *Anesth Essays Res.* 2017;11:134–9.
26. Wong AK, Keeney LG, Chen L, Williams R, Liu J, Elkassabany NM. Effect of local anesthetic concentration (0.2% vs 0.1% ropivacaine) on pulmonary function, and analgesia after ultrasound-guided interscalene brachial plexus block: a randomized controlled study. *Pain Med.* 2016;17:2397–403.
27. Okajima H, Tanaka O, Ushio M, Higuchi Y, Nagai Y, Iijima K, et al. Ultrasound-guided continuous thoracic paravertebral block provides comparable analgesia and fewer episodes of hypotension than continuous epidural block after lung surgery. *J Anesth.* 2015;29:373–8.
28. Zhang T, Yu Y, Zhang W, Zhu J. Comparison of dexmedetomidine and sufentanil as adjuvants to local anesthetic for epidural labor analgesia: a randomized controlled trial. *Drug Des Dev Ther.* 2019;13:1171–5.
29. Jiang C, Xie W, Xie H, Xie W, Kang Z, Liu N. Nalbuphine exhibited a better adjuvant than dexmedetomidine in supraclavicular brachial plexus block in youths. *Clin Neuropharmacol.* 2020;43:134–8.
30. El Sherif FA, Abd El-Rahman AM, Othman AH, Shouman SA, Omran MM, Hassan NA, et al. Analgesic effect of morphine added to bupivacaine in serratus anterior plane block following modified radical mastectomy. Only a local effect? Randomized clinical trial. *J Pain Res.* 2020;13:661–8.
31. Abdelhamid BM, Omar H. Nalbuphine as an adjuvant to 0.25% levobupivacaine in ultrasound-guided supraclavicular block provided prolonged sensory block and similar motor block durations (RCT). *J Anesth.* 2018;32:551–7.
32. Rao J, Gao Z, Qiu G, Gao P, Wang Q, Zhong W, et al. Nalbuphine and dexmedetomidine as adjuvants to ropivacaine in ultrasound-guided erector spinae plane block for video-assisted thoracoscopic lobectomy surgery: a randomized, double-blind, placebo-controlled trial. *Medicine (Baltimore).* 2021;100: e26962.
33. Hirota K, Okawa H, Appadu BL, Grandy DK, Lambert DG. Interaction of local anaesthetics with recombinant mu, kappa, and delta-opioid receptors expressed in Chinese hamster ovary cells. *Br J Anaesth.* 2000;85:740–6.