

Received: 2018.01.22
Accepted: 2019.02.20
Published: 2019.04.30

Persistent Severe Hiccups After Dexamethasone Intravenous Administration

Authors' Contribution:
Study Design A
Data Collection B
Statistical Analysis C
Data Interpretation D
Manuscript Preparation E
Literature Search F
Funds Collection G

B 1 **Nantawit Sugandhavesa***
ABCDEF 2,3 **Passakorn Sawaddiruk***
B 1 **Torphong Bunmaprasert**
BDEF 3,4 **Sintip Pattanakuhar**
ACDEFG 3 **Siriporn C. Chattipakorn**
ABCDEFG 3 **Nipon Chattipakorn**

1 Department of Orthopedics, Faculty of Medicine, Chiang Mai University, Chiang Mai, Thailand
2 Department of Anesthesiology, Faculty of Medicine, Chiang Mai University, Chiang Mai, Thailand
3 Cardiac Electrophysiology Research and Training Center, Faculty of Medicine, Chiang Mai University, Chiang Mai, Thailand
4 Department of Rehabilitation Medicine, Faculty of Medicine, Chiang Mai University, Chiang Mai, Thailand

Corresponding Author:
Conflict of interest:
Source of support:

* Nantawit Sugandhavesa and Passakorn Sawaddiruk contributed equally to this work
Nipon Chattipakorn, e-mail: nchattip@gmail.com
None declared
Thailand Research Fund [grant RTA 6080003 (SC)] and the NSTDA Research Chair grant from the National Science and Technology Development Agency (NC)

Patient: Male, 49
Final Diagnosis: Hiccups
Symptoms: Hiccups
Medication: Dexamethasone
Clinical Procedure: Drug termination
Specialty: General and Internal Medicine

Objective: Adverse events of drug therapy





Background: Hiccups induced by steroids administration is not common. Although it is not life-threatening and is always recognized as a transient and minor complication, it can be severely uncomfortable and significantly diminished patient quality of life. In this case report, persistent hiccups were observed in 2 middle-aged Thai men receiving low-dose intravenous dexamethasone. This case report highlights the awareness of severe dexamethasone-induced hiccups.

Case Report: A 49-year-old man and a 38-year-old man were admitted to our hospital and received IV dexamethasone. The hiccups started after each patient received a single dose of dexamethasone. The frequency and severity of their hiccups increased over time during dexamethasone treatment. Hiccups still continued to occur despite the discontinuation of dexamethasone and lasted for 72 h after drug termination.

Conclusions: Dexamethasone can cause persistent hiccups. Although hiccups are not life-threatening, it should not be neglected since it can be severely uncomfortable and significantly diminish patient quality of life. Termination of dexamethasone can gradually relieve hiccups. Dexamethasone should be used cautiously and clinicians must be aware of this undesirable effect.

MeSH Keywords: Dexamethasone • Drug-Related Side Effects and Adverse Reactions • Hiccup

Full-text PDF: <https://www.amjcaserep.com/abstract/index/idArt/915282>

 983   1  21



Background

Steroids have been widely used in patients when severe inflammation needs to be rapidly attenuated, or used as antiemetics postoperatively or in cancer patients treated with chemotherapy. Steroids may cause some adverse effects such as indigestion, high blood sugar, and osteoporosis. Although hiccups induced by administration of steroids has been sporadically reported, it is not common. Hiccups are sudden and uncontrolled contractions of the diaphragm. Hiccups are always followed by an immediate inspiration and glottis closure over the trachea, producing the “hiccup” sound. Hiccups may result in severe dehydration, malnourishment, and distress [1]. Among corticosteroids, dexamethasone has the greatest risk of causing hiccups [2]. Dexamethasone has been occasionally reported as causing hiccups in cancer patients treated with chemotherapy [3–5]. The incidence of hiccups in white patients with cancer who used dexamethasone, as antiemetics for cisplatin-induced nausea/vomiting prophylaxis, varies from 0.6% to 35.5% [6–15]. Only 1 report showed a high incidence (61%) in patients receiving dexamethasone 120 mg in 5 days [7]. Although, hiccups are self-limiting and occur over a short period [16], discontinuation of dexamethasone or rotating dexamethasone and methylprednisolone have been reported to relieve hiccups [3–5]. Men have a significant higher incidence of hiccups than women [5,6,17]. Most cases experiencing steroids-induced hiccups were receiving dexamethasone [3,5,17–19], methylprednisolone [5,20], betamethasone, or triamcinolone via different routes of administration, including oral [3,19], epidural, intraarticular, and intravenous [3,5,17,18,20]. The dosages of dexamethasone which were reported as causing hiccups also varied, from 8 to 40 mg oral [3,19], 8 to 20 mg intravenous [3,17,18], and 8 to 15 mg epidural [1,20,21]. As steroids are commonly used in patients, they may cause some adverse effects such as hiccups, which can be almost intolerable and significantly diminish the quality of life in patients. Our report is the first to describe severe hiccups induced by intravenous dexamethasone administration in Thai patients. This case report highlights the awareness of dexamethasone administration.

Case Report

The first case was a 49-year-old Asian man who was admitted to the hospital with a 2-week history of severe lower back pain radiating to the left leg, without neurological deficit. Magnetic resonance imaging (MRI) revealed disc extrusion of approximately 1.2×1×0.7 cm at L5–S1 left paracentral region causing compression of the left S1 traversing nerve root and nerve root edema (Figure 1). The patient initially denied surgical treatment. Conservative treatment was given intravenously by an initial 10 mg dose of dexamethasone followed by 5 mg every

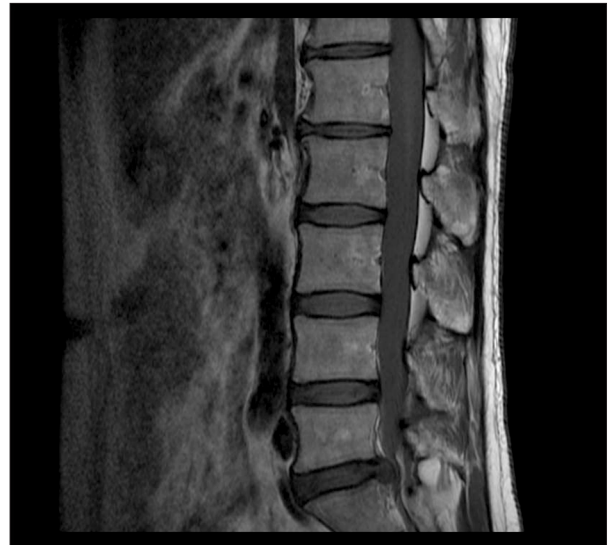


Figure 1. MRI image of the spine shows L5–S1 disc extrusion causing compression of the left S1 traversing nerve root and nerve root edema.

6 h for 3 days. One hour after injection, the hiccups started and resolved a few hours later without any treatment. Then, after the patient received each single dose of dexamethasone, hiccups occurred. After the patient received a total of 30 mg of dexamethasone, he complained of severe persistent hiccups. The frequency and severity of his hiccups increased over time during dexamethasone treatment. The attending physician decided to stop dexamethasone and scheduled the patient for surgery. However, severe persistent hiccups still continued to occur despite the discontinuation of dexamethasone and the persistent hiccups lasted for another 72 h after drug termination, when they stopped completely.

The second case was a 38-year-old Asian man who was scheduled for elective bilateral tonsillectomy. Dexamethasone 10 mg was given 5 min before the general anesthesia started. The operation took approximately 40 min. Then, the patient was reversed and transferred to the postanesthetic care unit (PACU). After 2 h in the PACU, the patient was transferred to the ward without any complications. Hiccups started approximately 6 h after the injection and lasted for 72 h after drug termination.

Discussion

Hiccups have been reported to start at between 1 h to 18 h and may last from 1–9 days [21]. The mechanisms related to steroids-induced hiccups have been postulated. The neural process involving the hiccup reflex arc consists of afferent nerves, efferent nerves, and the central nervous system. The afferent limb is composed of the phrenic nerve, vagus nerve, and a T6 to T12 sympathetic chain. Invasion of cancer, chemicals,

or other factors that irritate the afferent limb can stimulate hiccups. The central limb is linked to the afferent and efferent limbs and consists of C3–C5 nerves in the spinal cord that connect to the respiratory center, phrenic nerve nuclei, hypothalamus, and medullary reticular formation. Drugs or treatments that influence the hiccup center in this area may trigger hiccups. The efferent limb consists of the phrenic nerve, accessory respiratory muscles, autonomic processes involving the medullary reticular formation and hypothalamus, and the glottis. It has been proposed that dexamethasone decreases the threshold for synaptic transmission in the midbrain and ultimately induces hiccups [5]. Factors associated with steroid-induced severe persistent hiccups remain unclear. Although they are rare, hiccups are much more frequent with dexamethasone than with other corticosteroids [4]. Hiccups can be almost intolerable and significantly diminish the quality of life in these patients. High-dose dexamethasone (40 mg orally) administration previously was reported to result in hiccups [19]. However, in this case report, a single dose of 10 mg may have triggered hiccups. The pharmacologic treatment, including steroid rotation [5], chlorpromazine, metoclopramide, haloperidol, and baclofen had been reported to stop hiccups [21]. However, nonpharmacologic treatment which results in the

interruption of the vagal afferent limb of reflex arc or stimulating the vagal nerve was shown to successfully resolve the hiccups [21]. This is the first report of persistent severe hiccups after dexamethasone intravenous administration in Thai patients. Future studies are needed to investigate the potential biomarkers that can help indicate who is susceptible to induction of severe persistent hiccups by steroids.

Conclusions

Dexamethasone has been reported to cause hiccups. Although hiccups are not life-threatening, they are important because they can be almost intolerable and significantly diminish quality of life in patients. Discontinuation of dexamethasone or switching from dexamethasone to other corticosteroids have been reported to relieve hiccups. Dexamethasone should be used with caution due to this adverse effect.

Conflict of interest

None.

References:

- Odonkor CA, Smith B, Rivera K, Chhatre A: Persistent singultus associated with lumbar epidural steroid injections in a septuagenarian: A case report and review. *Am J Phys Med Rehabil*, 2017; 96(1): e1–4
- Hosoya R, Uesawa Y, Ishii-Nozawa R, Kagaya H: Analysis of factors associated with hiccups based on the Japanese Adverse Drug Event Report database. *PLoS One*, 2017; 12(2): e0172057
- Kang JH, Hui D, Kim MJ et al: Corticosteroid rotation to alleviate dexamethasone-induced hiccup: A case series at a single institution. *J Pain Symptom Manage*, 2012; 43(3): 625–30
- Go SI, Koo DH, Kim ST et al: Antiemetic corticosteroid rotation from dexamethasone to methylprednisolone to prevent dexamethasone-induced hiccup in cancer patients treated with chemotherapy: A randomized, single-blind, crossover phase III trial. *Oncologist*, 2017; 22(11): 1354–61
- Lee GW, Oh SY, Kang MH et al: Treatment of dexamethasone-induced hiccup in chemotherapy patients by methylprednisolone rotation. *Oncologist*, 2013; 18(11): 1229–34
- Liaw CC, Wang CH, Chang HK et al: Gender discrepancy observed between chemotherapy-induced emesis and hiccups. *Support Care Cancer*, 2001; 9(6): 435–41
- Sekine I, Nishiwaki Y, Kakinuma R et al: Phase II study of high-dose dexamethasone-based association in acute and delayed high-dose cisplatin-induced emesis – JCOG study 9413. *Br J Cancer*, 1997; 76(1): 90–92
- Kris MG, Gralla RJ, Tyson LB et al: Controlling delayed vomiting: Double-blind, randomized trial comparing placebo, dexamethasone alone, and metoclopramide plus dexamethasone in patients receiving cisplatin. *J Clin Oncol*, 1989; 7(1): 108–14
- Nicolai N, Mangiarotti B, Salvioni R et al: Dexamethasone plus ondansetron versus dexamethasone plus alizapride in the prevention of emesis induced by cisplatin-containing chemotherapies for urological cancers. *Eur Urol*, 1993; 23(4): 450–56
- Italian Group of Antiemetic Research: Ondansetron versus granisetron, both combined with dexamethasone, in the prevention of cisplatin-induced emesis. *Ann Oncol*, 1995; 6(8): 805–10
- Italian Group for Antiemetic Research: Cisplatin-induced delayed emesis: Pattern and prognostic factors during three subsequent cycles. *Ann Oncol*, 1994; 5(7): 585–89
- The Italian Group for Antiemetic Research: Ondansetron versus metoclopramide, both combined with dexamethasone, in the prevention of cisplatin-induced delayed emesis. *J Clin Oncol*, 1997; 15(1): 124–30
- Goedhals L, Heron JF, Kleisbauer JP et al: Control of delayed nausea and vomiting with granisetron plus dexamethasone or dexamethasone alone in patients receiving highly emetogenic chemotherapy: A double-blind, placebo-controlled, comparative study. *Ann Oncol*, 1998; 9(6): 661–66
- Gralla RJ, Rittenberg C, Peralta M et al: Cisplatin and emesis: aspects of treatment and a new trial for delayed emesis using oral dexamethasone plus ondansetron beginning at 16 hours after cisplatin. *Oncology*, 1996; 53(Suppl. 1): 86–91
- Shi Q, Li W, Li H et al: Prevention of cisplatin-based chemotherapy-induced delayed nausea and vomiting using triple antiemetic regimens: A mixed treatment comparison. *Oncotarget*, 2016; 7(17): 24402–14
- Gilbar P, McPherson I: Severe hiccups during chemotherapy: Corticosteroids the likely culprit. *J Oncol Pharm Pract*, 2009; 15(4): 233–36
- Liaw CC, Wang CH, Chang HK et al: Cisplatin-related hiccups: Male predominance, induction by dexamethasone, and protection against nausea and vomiting. *J Pain Symptom Manage*, 2005; 30(4): 359–66
- Errante D, Bernardi D, Bianco A et al: Recurrence of exhausting hiccup in a patient treated with chemotherapy for metastatic colon cancer. *Gut*, 2005; 54(10): 1503–4
- Cersosimo RJ, Brophy MT: Hiccups with high dose dexamethasone administration: A case report. *Cancer*, 1998; 82(2): 412–14
- Abubaker AK, Rabadi DK, Kassab M, Al-Qudah MA: Persistent hiccups after cervical epidural steroid injection. *Am J Case Rep*, 2018; 19: 397–99
- Abbasi A, Roque-Dang CM, Malhotra G: Persistent hiccups after interventional pain procedures: A case series and review. *PM R*, 2012; 4(2): 144–51