



Arrhythmia in COVID-19

Savalan Babapoor-Farrokhran¹ · Roozbeh Tarighati Rasekhi² · Deanna Gill³ · Shaghayegh Babapoor⁴ · Aman Amanullah^{1,5}

Accepted: 10 August 2020 / Published online: 14 August 2020
© Springer Nature Switzerland AG 2020

Abstract

The current outbreak of severe acute respiratory syndrome coronavirus-2 (SARS-CoV-2) also known as coronavirus disease 2019 (COVID-19) has quickly progressed to a global pandemic. There are well-documented cardiac complications of COVID-19 in patients with and without prior cardiovascular disease. The cardiac complications include myocarditis, heart failure, and acute coronary syndrome resulting from coronary artery thrombosis or SARS-CoV-2-related plaque ruptures. There is growing evidence showing that arrhythmias are also one of the major complications. Myocardial inflammation caused by viral infection leads to electrophysiological and structural remodeling as a possible mechanism for arrhythmia. This could also be the mechanism through which SARS-CoV-2 leads to different arrhythmias. In this review article, we discuss arrhythmia manifestations in COVID-19.

Keywords Coronavirus disease 2019 · Arrhythmias · Severe acute respiratory syndrome · Middle east respiratory syndrome · Viral infection · Ventricular arrhythmias · Ventricular tachycardia · Ventricular fibrillation · Sinus tachycardia · Sinus bradycardia · Atrial fibrillation · QT prolongation · Torsade de pointes

Introduction

The current outbreak of severe acute respiratory syndrome coronavirus-2 (SARS-CoV-2) also known as coronavirus disease 2019 (COVID-19) has quickly progressed to a global pandemic. As of June 2020, 7.4 million people worldwide have been infected with the virus since its origin in December 2019, according to the Johns Hopkins COVID-19 Resource Center [1]. Respiratory distress is the most

significant manifestation of COVID-19. In addition, there are well-documented cardiac complications of COVID-19 in patients with and without prior cardiovascular disease. The cardiac complications include myocarditis, heart failure, and acute coronary syndrome resulting from coronary artery thrombosis or SARS-CoV-2-related plaque ruptures [2]. There is growing evidence showing that arrhythmias are also one of the major complications. Liu et al. reported that about 7% of patients report palpitations as a presenting symptom [3]. In a recent report from Wuhan, China, 16.7% of hospitalized and 44.4% of ICU patients with COVID-19 had cardiac arrhythmias [4]. Recent studies have suggested that myocardial injury is common especially in critically ill COVID-19-infected patients through different mechanisms mainly due to direct damage of cardiomyocytes and systemic inflammation [2]. There are more than 20 viruses that have been implicated in myocardial inflammation and myocarditis, the most common are parvovirus B19, human herpesvirus 6, adenovirus, and coxsackievirus B3 [5]. The proposed mechanisms for arrhythmogenicity in viral infections in general are through the interplay between host factors and viral characteristics. These mechanisms include altered intercellular coupling, interstitial edema, and cardiac fibrosis that lead to abnormal conduction in addition to abnormal Ca²⁺ handling and down-regulation of K⁺ channels that results in repolarization

This article is part of the Topical Collection on *COVID-19*

✉ Savalan Babapoor-Farrokhran
Babapoor@einstein.edu

¹ Department of Medicine, Division of Cardiology, Einstein Medical Center, 5501 Old York Road, Philadelphia, PA 19141, USA

² Department of Radiology and Imaging Sciences, Emory University School of Medicine, Atlanta, GA 30322, USA

³ Department of Medicine, Emory University School of Medicine, Atlanta, GA 30322, USA

⁴ Department of Dermatology, Sina Hospital, Tabriz, Iran

⁵ Sidney Kimmel Medical College, Thomas Jefferson University, Philadelphia, PA 19107, USA

abnormalities and action potential conduction abnormalities [6]. Gaaloul et al. reported that myocardial inflammation caused by viral infection leads to ion channel dysfunction or electrophysiological and structural remodeling as a mechanism for arrhythmia [5].

In vivo studies on mice and rabbits infected with SARS-CoV demonstrated direct viral RNA inclusion in cardiomyocytes and conduction system disease [7]. Furthermore, it has been reported that patients with the SARS-CoV infection experience different cardiac manifestations including arrhythmias and sudden death [8]. To date, our knowledge of arrhythmia complications of COVID-19 is still in its infancy. However, our understanding regarding arrhythmogenicity of the novel coronavirus is rapidly evolving and there is growing evidence demonstrating different arrhythmia manifestations of COVID-19. In this paper, we summarize important studies regarding arrhythmia manifestations of COVID-19 and shed light on this potentially fatal complication (Fig. 1).

Arrhythmias in Viral Infections

Cardiac conduction system disease involving the sinoatrial (SA) node and atrioventricular (AV) node has been shown to be caused by various infections including viral myocarditis [9]. According to Liu et al., the myocarditis process has three phases: phase one, viral infection, the entry of the virus and proliferation in the myocardium that may lead to the second phase (autoimmune phase) with T cell activation, cytokine

production, and cross-reacting antibodies formation and ultimately lead to phase 3, cardiac remodeling and progressive cardiac dilatation [10]. Acute viral myocarditis and acute pericarditis are self-limiting conditions that ordinarily have a benign course with minimal symptoms. However, ventricular arrhythmia is a frequent complication in viral myocarditis [11]. Case reports have demonstrated the occurrence of arrhythmias in association with many viral infections including the influenza virus, Epstein-Barr virus (EBV), human immuno-deficiency virus (HIV), and others [12–17]. In a study by Sardana et al., over 17 million people with HIV were followed for a median period of 4.7 years and they found that people with HIV were at an increased risk of developing atrial fibrillation AF with a hazard ratio of 1.46 after adjusting for race, age, gender, socio-economic status, obesity, etc. [18]. A case of a 45-year-old male who had transient non-sustained ventricular tachycardia reported by Andrea Frustaci et al. indicated influenza virus focal myositis with inflammatory infiltration of conduction tissue on samples of left ventricular endomyocardial biopsy [12]. Another case report of an 18-year-old female who presented with respiratory failure secondary to H1N1 infection and who subsequently developed high-degree atrioventricular (AV) block highlights the potential impact of the H1N1 influenza virus on the cardiac conduction system [13]. Abdalla et al. reported a case of atrial fibrillation in an individual with acute Zika infection. They reported that levels of CCL5, IL-1β, TNF-α, IFN-γ, IL-9, G-CSF, and GM-CSF were elevated in the Zika patient with atrial fibrillation, compared with other Zika patients [14]. The

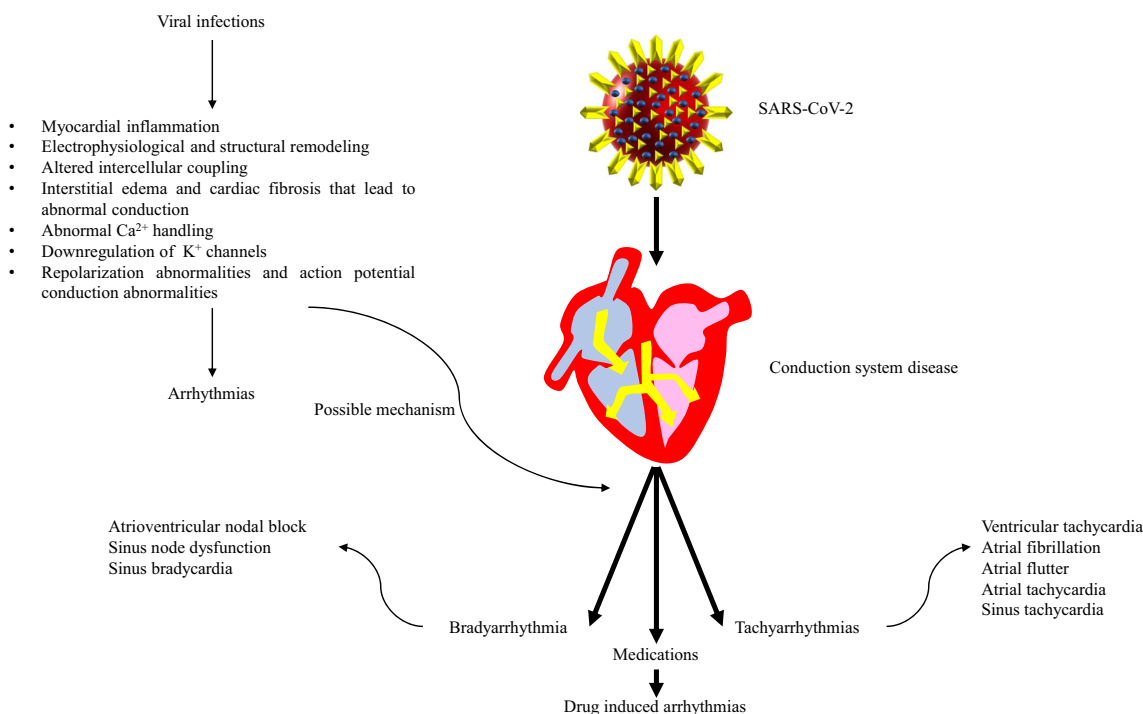


Fig. 1 Arrhythmia manifestations of COVID-19 and possible mechanisms

increased levels of these cytokines may justify the inflammation of conduction tissue and subsequent arrhythmias. Cardiac involvement in healthy immunocompetent patients is not a common complication of the EBV infection; a case of a young female with acute EBV infection and myocarditis who had a cardiac arrest and malignant ventricular arrhythmia was reported by Watanabe et al. This study indicates, although viral myocarditis often has a benign course, it is serious and life-threatening complications should not be underestimated [15]. In a study by Stulova et al., 75 patients who had acute respiratory infections and/or other viral diseases (influenza, parainfluenza, and adenovirus) that were complicated by myocarditis were followed up from 3 to 26 years (mean 14.6 years). They reported that 42.3% of patients had frequent and complicated ventricular extrasystole on resting electrocardiogram (ECG) for many years and 89% of them had fibrous lesions of the pericardium indicating involving the pericardium in addition to myocardial involvement [16].

Arrhythmias in MERS and SARS

Cardiac arrhythmia was remarked as a complication of SARS-COV in the outbreak of 2003. In a Chinese report, 8 out of 77 hospitalized patients showed cardiac arrhythmia during the course of the disease [19]. In another study of 121 cases, tachycardia was the most common arrhythmia among the patients. Eighty-seven of the patients had tachycardia during the disease and, notably, this finding was independent of fever. Additionally, sinus bradycardia was noted in 18 patients in this study. They also reported a self-limited transient atrial fibrillation in a patient without any cardiovascular disease [8]. Follow-up in this study revealed persistent tachycardia in 38.8% of the patients and this was consistent with another small study on 15 patients [20]. They proposed this persistent arrhythmia might be either due to autonomic dysfunction or medical deconditioning following long bedridden time.

The other cousin of COVID-19, MERS, showed a significant incidence of cardiac arrhythmias in one cohort study. In a total number of 70 patients, 11 cases experienced different types of arrhythmias including tachyarrhythmias and bradycardia [21].

Arrhythmias in COVID-19

Our understanding of arrhythmic complications in COVID-19 is still evolving. Multiple cases of different arrhythmia complications have been reported and the number is still growing. However, the literature lacks studies specifically aiming directly at arrhythmias in COVID-19 patients.

One of the most common arrhythmias discussed in relation to COVID-19 is sinus bradycardia. Despite the perceived association, as of now, only case reports have explored the

phenomenon. In a report by Kir et al., bradycardia and intermittent high-degree AV block were seen in a patient with COVID-19 infection who had normal echocardiography and cardiac biomarkers [22]. Peigh et al. reported sinus node dysfunction in two cases of COVID-19. They reported that these patients presented with sinus bradycardia followed by episodes of accelerated idioventricular rhythm. Importantly, the patients remained in sinus bradycardia for 2 weeks following the onset of sinus node dysfunction [23].

As discussed previously, Wang et al. reported that among 138 patients who were hospitalized with COVID-19-related pneumonia in Wuhan, arrhythmias were reported in 17% of the patients and more commonly in 44% of patients admitted to an intensive care unit [4]. In a cohort of 393 patients with COVID-19 patients in New York, rates of atrial arrhythmias were higher among patients requiring mechanical ventilation reporting 17.7% in mechanically ventilated patients compared with 1.9% in non-invasive ventilation groups [24]. Similarly, in an analysis of 115 patients (69 admitted to medical ICU and 46 general medicine ward) admitted to the hospital, Colon et al. reported that new-onset atrial tachyarrhythmia including atrial fibrillation, atrial flutter, and atrial tachycardia was seen in 19 patients (16.5%), all of which were admitted to the ICU (27.5% of ICU patients). However, no atrial arrhythmias were seen in patients admitted to the general medicine service [25]. According to a Danish study, following a national lockdown in Denmark, a 47% drop in registered new-onset atrial fibrillation cases was observed. The authors conclude that the risk of undiagnosed atrial fibrillation patients with complications could lead to worse outcomes in patients with atrial fibrillation in the COVID-19 pandemic [26].

Atrial fibrillation was the most common cardiac arrhythmia observed in patients with COVID-19 infection according to one survey [27]. The mechanisms that might cause atrial fibrillation in these patients are possibly due to systemic infection, direct viral cardiomyocyte injury, hypoxemia, and susceptibility of the population due to advanced age and their comorbidities, and, finally, sympathetic nervous system overactivity [28].

Seecheran et al. also reported a case of new-onset atrial fibrillation and flutter in a COVID-19 patient further demonstrating the atrial arrhythmogenicity of COVID-19 infection [29].

Finally, additional arrhythmias including atrial and ventricular arrhythmias have been witnessed in COVID-19 patients, without any history of arrhythmia. In one of the earliest cohorts, Gou et al. reported that among 187 hospitalized patients, 13 patients (7%) had ventricular tachyarrhythmias while hospitalized. They further reported that malignant arrhythmias, including ventricular tachycardia/ventricular fibrillation, were more common in patients with elevated troponin T levels compared with patients with normal troponin T levels (6 patients [11.5%] vs 7 patients [5.2%]) [30]. There are also reports of ventricular arrhythmias and torsade de pointes due

to QT-prolonging medications especially azithromycin and hydroxychloroquine [31–34].

Discussion

Arrhythmias and conduction system disease are not an early or common manifestation of COVID-19, and the majority of symptoms are related to respiratory system involvement. While sinus tachycardia is reported secondary to the physiologic response of viral infection [2], the development of arrhythmias outside of sinus tachycardia has been reported at a significant rate in COVID-19 patients. Arrhythmias are not an uncommon manifestation of viral infections, and it appears that it is typically initiated by viral myocarditis affecting the cardiac conduction system [9, 12–18]. Specifically, infection with SARS and MERS, close relatives of the current COVID-19 virus, has demonstrated a propensity to cause arrhythmias including sinus bradycardia [8, 21]. In COVID-19, arrhythmias could be secondary to medication side effects [35], hypoxia and pulmonary disease, activated protein kinase C, direct oxidized Ca²⁺/calmodulin-dependent protein kinase II activity [36], and myocarditis [2, 37]. Sinus bradycardia is one of the most common arrhythmias seen in COVID-19 patients, and it can be persistent for up to 2 weeks [22, 23]. However, other atrial and ventricular arrhythmias including malignant arrhythmias such as ventricular fibrillation have also been witnessed in patients who had no previous evidence of arrhythmia and were not on QT-prolonging medications [30]. With that being said, there have been reports about COVID-19 patients receiving QT-prolonging medications such as hydroxychloroquine and/or azithromycin who then develop arrhythmias such as torsade de pointes (TdP) [31]. Further research should be done to determine if patients with viral myocarditis secondary to COVID-19 infection are at an increased risk of developing TdP when given QT-prolonging medications when compared with patients receiving the same medications without evidence of viral myocarditis. If drugs that have QT-prolonging effects are deemed necessary to be administered in an inpatient setting, a baseline 12-lead ECG should be acquired. Telemetry monitoring is reasonable when patients have multiple cardiovascular risk factors, and/or there is a risk for clinical decompensation [38]. The incidence of arrhythmias has also been associated with disease severity. It has been reported that patients with elevated troponin I levels are at higher risk of severe disease, ICU admission, and death. Furthermore, new-onset arrhythmia, elevated biomarkers including creatinine kinase, creatinine kinase-MB, lactate dehydrogenase (LDH), inflammatory biomarkers including C-reactive protein (CRP), and interleukin-6 levels are associated with severe disease [37, 39]. Moreover, atrial arrhythmias were more common among COVID-19 patients requiring mechanical ventilation [24]. Since an exaggerated inflammatory

response plays a major role in the complications of COVID-19, anti-inflammatory medications have been proposed as potential therapeutic agents against cardiovascular complications of COVID-19 [35, 40]. Despite the growing number of case reports demonstrating arrhythmias in COVID-19 patients, evidence establishing COVID-19 as the direct cause is lacking. Additionally, even if COVID is to blame, it is unclear whether or not the development of arrhythmias in these patients has long-term consequences. Based on this review of arrhythmias in COVID-19 patients, we believe that further research needs to be done to determine if COVID-19 infection is a causal factor of arrhythmias and to establish what are the long-term consequences of this specific complication.

Conclusions

Arrhythmias have been seen historically with viral infections causing viral myocarditis and existing anecdotal evidence suggests this may be at play in COVID-19-infected patients as well.

Current literature lacks detailed primary studies on arrhythmias and possible mechanisms. This makes it difficult to distinguish between arrhythmias caused by hypoxemia, metabolic abnormalities, inflammatory syndrome, comorbidities, and medications as opposed to direct viral effects on the heart. In order to firmly establish this relationship and to determine long-term consequences, further research is required.

Acknowledgments The authors are grateful to our colleagues, who contributed invaluable information.

Compliance with Ethical Standards

Conflict of Interest The authors declare that they have no conflict of interest.

References

1. COVID-19 Map.In: Johns Hopkins Coronavirus Resource Center [Internet]. [cited 9 Apr 2020]. Available: <https://coronavirus.jhu.edu/map.html>. Accessed 11 June 2020.
2. Babapoor-Farrokhran S, Gill D, Walker J, Rasekhi RT, Bozorgnia B, Amanullah A. Myocardial injury and COVID-19: possible mechanisms. *Life Sci.* 2020;253:117723. <https://doi.org/10.1016/j.lfs.2020.117723>.
3. Liu K, Fang Y-Y, Deng Y, Liu W, Wang M-F, Ma J-P, et al. Clinical characteristics of novel coronavirus cases in tertiary hospitals in Hubei Province. *Chin Med J.* 2020;133(9):1025–31. <https://doi.org/10.1097/CM9.0000000000000744>.
4. Wang D, Hu B, Hu C, Zhu F, Liu X, Zhang J, et al. Clinical characteristics of 138 hospitalized patients with 2019 novel coronavirus-infected pneumonia in Wuhan, China. *JAMA.* 2020;323:1061. <https://doi.org/10.1001/jama.2020.1585>.
5. Gaaloul I, Riabi S, Harrath R, Evans M, Salem NH, Mlayeh S, et al. Sudden unexpected death related to enterovirus myocarditis:

- histopathology, immunohistochemistry and molecular pathology diagnosis at post-mortem. *BMC Infect Dis.* 2012;12:212. <https://doi.org/10.1186/1471-2334-12-212>.
6. Tse G, Yeo JM, Chan YW, Lai ETHL, Yan BP. What is the arrhythmic substrate in viral myocarditis? Insights from clinical and animal studies. *Front Physiol.* 2016;7:308. <https://doi.org/10.3389/fphys.2016.00308>.
 7. Alexander LK, Keene BW, Small JD, Yount B, Baric RS. Electrocardiographic changes following rabbit coronavirus-induced myocarditis and dilated cardiomyopathy. *Adv Exp Med Biol.* 1993;342:365–70. https://doi.org/10.1007/978-1-4615-2996-5_56.
 8. Yu CM, Wong RSM, Wu EB, Kong SL, Wong J, Yip GWK, et al. Cardiovascular complications of severe acute respiratory syndrome. *Postgrad Med J.* 2006;82(964):140–4. <https://doi.org/10.1136/pgmj.2005.037515>.
 9. Kirmser R, Umbach R, Rowett D, Ross A. Complete heart block due to acute nonspecific carditis. *Chest.* 1977;71(5):682–4. <https://doi.org/10.1378/chest.71.5.682>.
 10. Liu PP, Mason JW. Advances in the understanding of myocarditis. *Circulation.* 2001;104(9):1076–82. <https://doi.org/10.1161/hc3401.095198>.
 11. Baksi AJ, Kanaganayagam GS, Prasad SK. Arrhythmias in viral myocarditis and pericarditis. *Card Electrophysiol Clin.* 2015;7(2):269–81. <https://doi.org/10.1016/j.ccep.2015.03.009>.
 12. Frustaci A, Petrosillo N, Ippolito G, Chimenti C. Transitory ventricular tachycardia associated with influenza A infection of cardiac conduction tissue. *Infection.* 2016;44(3):353–6. <https://doi.org/10.1007/s15010-016-0892-0>.
 13. Beinart R, Morganti K, Ruskin J, Mela T. H1N1 influenza A virus induced atrioventricular block. *J Cardiovasc Electrophysiol.* 2011;22(6):711–3. <https://doi.org/10.1111/j.1540-8167.2010.01931.x>.
 14. Abdalla LF, Santos JHA, Barreto RTJ, Souza EME, D'Assunção FF, Borges MA, et al. Atrial fibrillation in a patient with Zika virus infection. *Virol J.* 2018;15(1):23. <https://doi.org/10.1186/s12985-018-0938-2>.
 15. Watanabe M, Panetta GL, Piccirillo F, Spoto S, Myers J, Serino FM, et al. Acute Epstein-Barr related myocarditis: an unusual but life-threatening disease in an immunocompetent patient. *J Cardiol Cases.* 2020;21(4):137–40. <https://doi.org/10.1016/j.jccase.2019.12.001>.
 16. Stulova MA, Konstantinova EV. Ventricular extrasystole as manifestation of viral myocarditis and myopericarditis in young patients. *Ter Arkh.* 2007;79(12):28–34.
 17. Pastori D, Mezzaroma I, Pignatelli P, Violi F, Lip GYH. Atrial fibrillation and human immunodeficiency virus type-1 infection: a systematic review. Implications for anticoagulant and antiarrhythmic therapy. *Br J Clin Pharmacol.* 2019;85(3):508–15. <https://doi.org/10.1111/bcp.13837>.
 18. Sardana M, Hsue PY, Tseng ZH, Vittinghoff E, Nah G, Dewland TA, et al. Human immunodeficiency virus infection and incident atrial fibrillation. *J Am Coll Cardiol.* 2019;74(11):1512–4. <https://doi.org/10.1016/j.jacc.2019.07.027>.
 19. Lin L, Xu Y-J, He D-P, Han Y, Tang G-H, Yang Z-M, et al. A retrospective study on clinical features of and treatment methods for 77 severe cases of SARS. *Am J Chin Med.* 2003;31(6):821–39. <https://doi.org/10.1142/S0192415X03001521>.
 20. Lau S-T, Yu W-C, Mok N-S, Tsui P-T, Tong W-L, Cheng SWC. Tachycardia amongst subjects recovering from severe acute respiratory syndrome (SARS). *Int J Cardiol.* 2005;100(1):167–9. <https://doi.org/10.1016/j.ijcard.2004.06.022>.
 21. Saad M, Omrani AS, Baig K, Bahloul A, Elzein F, Matin MA, et al. Clinical aspects and outcomes of 70 patients with Middle East respiratory syndrome coronavirus infection: a single-center experience in Saudi Arabia. *Int J Infect Dis.* 2014;29:301–6. <https://doi.org/10.1016/j.ijid.2014.09.003>.
 22. Kir D, Mohan C, Sancassani R. Heart brake: an unusual cardiac manifestation of coronavirus disease 2019 (COVID-19). *JACC Case Rep.* 2020;2:1252–5. <https://doi.org/10.1016/j.jaccas.2020.04.026>.
 23. Peigh G, Leya MV, Baman JR, Cantey EP, Knight BP, Flaherty JD. Novel coronavirus 19 (COVID-19) associated sinus node dysfunction: a case series. *Eur Heart J - Case Rep.* 2020. <https://doi.org/10.1093/ehjcr/ytaa132>.
 24. Goyal P, Choi JJ, Pinheiro LC, Schenck EJ, Chen R, Jabri A, et al. Clinical characteristics of Covid-19 in New York City. *N Engl J Med.* 2020;382:2372–4. <https://doi.org/10.1056/NEJMc2010419>.
 25. Colon CM, Barrios JG, Chiles JW, McElwee SK, Russell DW, Maddox WR, et al. Atrial arrhythmias in COVID-19 patients. *JACC: Clinical Electrophysiology.* 2020. <https://doi.org/10.1016/j.jacep.2020.05.015>.
 26. Holt A, Gislason GH, Schou M, Zareini B, Biering-Sørensen T, Phelps M, et al. New-onset atrial fibrillation: incidence, characteristics, and related events following a national COVID-19 lockdown of 5.6 million people. *Eur Heart J.* 2020. <https://doi.org/10.1093/eurheartj/ehaa494>.
 27. Gopinathannair R, Merchant FM, Lakkireddy DR, Etheridge SP, Feigofsky S, Han JK, et al. COVID-19 and cardiac arrhythmias: a global perspective on arrhythmia characteristics and management strategies. *J Interv Card Electrophysiol.* 2020. <https://doi.org/10.1007/s10840-020-00789-9>.
 28. Russo V, Rago A, Carbone A, Bottino R, Ammendola E, Della Cioppa N, et al. Atrial fibrillation in COVID-19: from epidemiological association to pharmacological implications. *J Cardiovasc Pharmacol.* 2020. <https://doi.org/10.1097/FJC.0000000000000854>.
 29. Seecheran R, Narayansingh R, Giddings S, Rampaul M, Furlonge K, Abdool K, et al. Atrial arrhythmias in a patient presenting with coronavirus disease-2019 (COVID-19) infection. *J Investig Med High Impact Case Rep.* 2020;8:2324709620925571. <https://doi.org/10.1177/2324709620925571>.
 30. Guo T, Fan Y, Chen M, Wu X, Zhang L, He T, et al. Cardiovascular implications of fatal outcomes of patients with coronavirus disease 2019 (COVID-19). *JAMA Cardiol.* 2020;5:811. <https://doi.org/10.1001/jamacardio.2020.1017>.
 31. Chorin E, Wadhvani L, Magnani S, Dai M, Shulman E, Nadeau-Routhier C, et al. QT interval prolongation and torsade de pointes in patients with COVID-19 treated with hydroxychloroquine/azithromycin. *Heart Rhythm.* 2020. <https://doi.org/10.1016/j.hrthm.2020.05.014>.
 32. Saleh M, Gabriels J, Chang D, Kim BS, Mansoor A, Mahmood E, et al. The effect of chloroquine, hydroxychloroquine and azithromycin on the corrected QT interval in patients with SARS-CoV-2 infection. *Circ Arrhythm Electrophysiol.* 2020;13:e008662. <https://doi.org/10.1161/CIRCEP.120.008662>.
 33. Mercuro NJ, Yen CF, Shim DJ, Maher TR, McCoy CM, Zimetbaum PJ, et al. Risk of QT interval prolongation associated with use of hydroxychloroquine with or without concomitant azithromycin among hospitalized patients testing positive for coronavirus disease 2019 (COVID-19). *JAMA Cardiol.* 2020. <https://doi.org/10.1001/jamacardio.2020.1834>.
 34. Chorin E, Dai M, Shulman E, Wadhvani L, Bar-Cohen R, Barbhuiya C, et al. The QT interval in patients with COVID-19 treated with hydroxychloroquine and azithromycin. *Nat Med.* 2020;26:808–9. <https://doi.org/10.1038/s41591-020-0888-2>.
 35. Zhand S, Saghaeian Jazi M, Mohammadi S, Tarighati Rasekhi R, Rostamian G, Kalani MR, et al. COVID-19: the immune responses and clinical therapy candidates. *Int J Mol Sci.* 2020;21(15):5559. <https://doi.org/10.3390/ijms21155559>.

36. Sattar Y, Ullah W, Rauf H, Ul H, Virk H, Yadav S, Chowdhury M, et al. “COVID-19 cardiovascular epidemiology, cellular pathogenesis, clinical manifestations and management,” *IJC Heart and Vasculature*, vol. 29. Elsevier Ireland Ltd, p. 100589 2020, doi: <https://doi.org/10.1016/j.ijcha.2020.100589>.
37. Azevedo RB, Botelho BG, de Hollanda JVG, Ferreira LVL, Junqueira de Andrade LZ, Oei SSML, et al., “Covid-19 and the cardiovascular system: a comprehensive review,” *J Hum Hypertens*, pp. 1–8, 2020, doi: <https://doi.org/10.1038/s41371-020-0387-4>.
38. Varma N, Marrouche NF, Aguinaga L, Albert CM, Arbelo E, Il Choi J, et al. HRS/EHRA/APHRs/LAHRs/ACC/AHA worldwide practice update for telehealth and arrhythmia monitoring during and after a pandemic. *Circ Arrhythm Electrophysiol*. 2020;13(7): e009007. <https://doi.org/10.1161/CIRCEP.120.009007>.
39. Li X, Pan X, Li Y, An N, Xing Y, Yang F, et al. Cardiac injury associated with severe disease or ICU admission and death in hospitalized patients with COVID-19: a meta-analysis and systematic review. *Crit Care*. 2020;24(1):468. <https://doi.org/10.1186/s13054-020-03183-z>.
40. Papadopoulos C, Patoulas D, Teperikidis E, Mouselimis D, Tsarouchas A, Toumpourleka M, Boulmpou A, Bakogiannis C, Doumas M, Vassilikos VP, “Colchicine as a potential therapeutic agent against cardiovascular complications of COVID-19: an exploratory review,” *SN Compr Clin Med*, pp. 1–11, 2020, doi: <https://doi.org/10.1007/s42399-020-00421-x>.

Publisher's Note Springer Nature remains neutral with regard to jurisdictional claims in published maps and institutional affiliations.