

Double mandibular osteotomy with segmental mandibular swing approach to parapharyngeal space

Department of ENT and Head Neck Oncology, Chittaranjan National Cancer Institute, Kolkata, West Bengal, India

Shouvanik Satpathy, Aniruddha Dam, Mollah Arafat Hossain, Jayanta Chatterjee

ABSTRACT

Surgical removal of benign tumors of the Parapharyngeal space (PPS) is the treatment of choice. PPS tumors may remain undetected for long periods of time and large tumors in the PPS can extend into the Retropharyngeal Space or into the Infra-Temporal Fossa. Anatomically, the mandible represents a significant obstacle to successful PPS surgery. Except for very small tumors, it is difficult to remove larger tumors from this region without some form of mandibular retraction. The standard mandibular “swing” approach involves splitting of the lower lip and a single parasymphysis osteotomy for retraction of the mandible laterally to expose the PPS. However, the morbidity associated with midline lip split and anesthesia of the hemi-labial region caused by the severing of the mental nerve is an unwanted complication of this approach. In this article, we describe an easier double mandibular osteotomy (Segmental Mandibular Swing Approach) which avoids the morbidity associated with lip splitting or intra-oral mucosal incision but allows excellent exposure of the superior and lateral aspect of PPS for easier removal of large tumors in this region.

Address for correspondence:

Dr. Shouvanik Satpathy, Department of ENT and Head Neck Oncosurgery, Chittaranjan National Cancer Institute, 37 SP Mukherjee Road, Kolkata - 700 026, West Bengal, India. E-mail: shouvanikgrmc@gmail.com

Key words: Large tumors, mandible, midline-lip-split, osteotomy, parapharyngeal space

INTRODUCTION

Otolaryngologist dealing with the surgical removal of benign tumors of the Parapharyngeal space (PPS) can be confused regarding the best approach for its complete removal. The numerous techniques described in the literature have to be carefully studied and understood. Some of these approaches are technically demanding, requiring the expertise of trained skull base surgeons and is to be avoided by the occasional surgeon. In this article, we describe a relatively simple technique, without a facial scar to access this potential

space through the neck for the removal of large benign tumors of the PPS.^[1,2]

Surgical anatomy

The Parapharyngeal Space (PPS) is a potential space in the lateral aspect of the neck and tumors in this region usually presents to the Otolaryngologist as a gradually expanding neck mass. Tumors in the PPS may originate from any of the structures normally found this space, which is an inverted pyramid-like area, starting at the base of the skull with the apex reaching the greater cornu of the hyoid bone. Descriptively, the space is divided into the pre-styloid and post-styloid compartments.^[3] The deep lobe of the parotid gland and its accompanying lympho-areolar tissue are found in the prestyloid space, while the internal carotid artery, the internal jugular vein, the IX, X, XI, and XII cranial nerves, the sympathetic chain, and the lymph nodes are found in the post-styloid compartment. The PPS can communicate into the retropharyngeal

Access this article online	
Quick Response Code: 	Website: www.njms.in
	DOI: 10.4103/0975-5950.154840

space at the level of the oropharynx through the infra-temporal fossa. The retropharyngeal space is a potential space between the buccopharyngeal fascia of the pharynx and the alar layer of the prevertebral fascia, extending from the skull base to the superior mediastinum. Hence, a gradually expanding tumor in the PPS can potentially extend to all these areas by gradual displacement and compression of the intervening facial planes.

PPS tumors are not very frequent, accounting for some 0.5% of neoplasms of the head and neck. Most of these tumors (70-80%) are benign. Approximately 50% of the tumors have a salivary origin, 20% are neurogenic and the remaining 30% are represented by tumors such as benign and malignant lymphoreticular lesions, metastatic lesions, and carotid body tumors.^[4]

PPS tumors may remain undetected for long periods of time, and generally present as a symptomatic lump in the neck with medial displacement of oropharyngeal structures. Because of its anatomical complexity, complementary MRI and CT scanning are necessary for diagnosis. Fine Needle Aspiration Cytology (FNAC) is very specific in the histological diagnosis of these tumors and open biopsy is not advised, due to the risk of bleeding, opening of the capsule with relapse, and seeding to neighboring tissues. PPS tumors display very few symptoms. The usual presentation is that of an enlarging lateral neck mass. Larger tumors may additionally present intraorally as a smooth submucosal mass displacing the lateral pharyngeal wall, tonsils, and soft palate antero-medially. A gradually enlarging tumor involving the structures in this space can grow to a considerable size by extending from parapharynx into the infra temporal fossa and even into the nasopharynx to block the posterior choanae.

Surgical approach

Complete removal of the lesion surgically is the treatment of choice for benign parapharyngeal space tumors. In order to treat these kind of tumors correctly, it is first necessary to select the right surgical approach for each case, balancing maximum exposition, for complete and safe removal of the tumor with minimum aesthetic and functional morbidity. It is very important to take the time to perform a detailed history and physical examination when selecting which approach to take. The surgeon must also consider the type, size, and location of the tumor to be excised. Bony involvement must be assessed as well. Selecting the proper approach preoperatively will save the surgeon time and frustration and benefit the patient by assuring adequate tumor resection.^[5-7]

Anatomically, the mandible represents a significant obstacle to successful PPS surgery and hence different mandibulotomy techniques have been suggested to overcome this problem.^[8] Except for small parapharyngeal tumors restricted to the neck, it may be difficult to remove larger tumor (s) from this region without some form of mandible retraction.

With larger PPS tumors, there will be extension into the retropharyngeal space which will clinically present as bulging of the tonsillar fossa and soft palate with obliteration of the nasopharyngeal space. Removal of tumors occupying such large potential spaces may require modification of the various standard approaches to these spaces. Bony involvement must be assessed as well. Selecting the proper approach preoperatively will save the surgeon time and frustration and benefit the patient by assuring adequate tumor resection. When dealing with such tumors, an additional transpalatal incision will offer direct visualization of the tumor mass in this region and can provide space to control the superior and contralateral extent of the tumor.^[9]

Ariel *et al.*^[7] first proposed the mandibular osteotomy as a complement to the other approaches, in order to improve and increase access to the PPS. Many variations of the transmandibular approaches have since been developed.

Single mandibular osteotomy swing

In the standard mandibular “swing,” the mandible is retracted laterally to expose the PPS as much as possible while preserving the mental nerve. This “swing” is commonly done through a parasymphysis osteotomy, anterior to the mental nerve, after splitting of the lower lip and extending an intraoral incision along the floor of the mouth. This may be combined with a transcervical approach to enlarge PPS exposure. The main disadvantage of this approach is the limited visualization of the superior and upper lateral aspect of the tumor. Aggressive retraction of the mandible in the attempt to access these regions may cause subdislocation of the temporal-mandibular articulation with its resultant trismus. In addition, there is the morbidity associated with midline lip split and dysfunction-like anesthesia of the hemi-mental and low hemi-labial region caused by the severing of the mental nerve. To avoid these complications while improving visualization as well as adequate access to the tumor and the neurovascular structures in this region, the “segmental mandibular swing” through double osteotomy is easy to perform.

Double mandibular osteotomy swing

A generous curved transverse incision is placed in the ipsilateral neck about two-finger breaths below the

margin of the mandible, extending from the mastoid tip to the midline just below mentum. This incision is placed through a natural skin crease for better cosmesis. The skin flap is elevated carefully, preserving the marginal mandibular branch of the facial nerve till the entire mandibular body is exposed. Anteriorly, the exit of the alveolar nerve at the mental foramen is identified and the flap is raised further preserving the continuity of the nerve. Posteriorly, the lower pole of the parotid gland is identified and carefully dissected laterally along with the anterior fibers of the masseter muscle from the angle of the mandible after incising the periosteum to retract the muscle along with the parotid gland laterally. This allows adequate exposure of the superior portion of the mandible for both visualization and palpation of the sigmoid notch.

Then with the help of Fischer Bur and small osteotomes, two osteotomies are made, one through the parasymphysis and one through the sigmoid notch just inferior to the condyle of the mandible [Figure 1]. The site of the first mandibulotomy should be made anterior to the mental foramen through a tooth socket to help support the reconstruction plate. This may necessitate extraction of the canine since mandibulotomy performed between two teeth is best avoided as both teeth may be lost. The lateral mandibulotomy is then carefully made through the neck of the condyle, just beyond the opening of superior alveolar canal to avoid division of the nerve as well as the artery in the mental canal which can result in ischemic necrosis. Before completion of the osteotomy, cuts position of the mini-reconstruction plates are selected and adapted to the mandible.

Retraction of the mobilized middle segment of the mandible upward now will dramatically open up the

PPS and its communication with ipsilateral ITF. This provides excellent exposure of the superior and lateral aspect of these potential spaces for identification of the neurovascular structures. This approach provides good control of tumor extension toward the skull base, the pterygomaxillary fossa as well as visualization of the large neck vessels. Under direct visualization, larger tumors of the PPS can be carefully dissected out. This may be combined with an additional transpalatal incision to control the superior and contralateral extent of the tumor and partly freed through the transpalatal route.

After completion of the procedure and checking the region for any potential bleeding, the osteotomy cuts are carefully approximated by fixing the mini-reconstruction plates in the previously drilled screw holes resulting in excellent approximation of the mandibular segment. The neck wound can be closed in layers after securing a suction drain. The palatal incision, if given, is approximated with a few sutures per orally [Figure 2]. Except for the postoperative edema of face, which can be significant for the first 72 hours, complication after this surgery is minimal. Removal of large parapharyngeal tumors by this approach can leave significant dead space that is prone to hematoma formation and infection. A broad-spectrum antibiotic is recommended. Patient should be rested in head elevated position and oral feeds should be avoided. Nutrition is maintained through nasogastric tube for the first week to give rest to the muscles of mastication. Some degree of temporary paresis of the marginal mandibular nerve may occur which recovers in about 4 to 6 weeks time. Hypoglossal nerve paralysis is rare. Dental occlusion with mini-plate fixation for osteosynthesis gives excellent result with minimal cosmetic deformity or malocclusion.

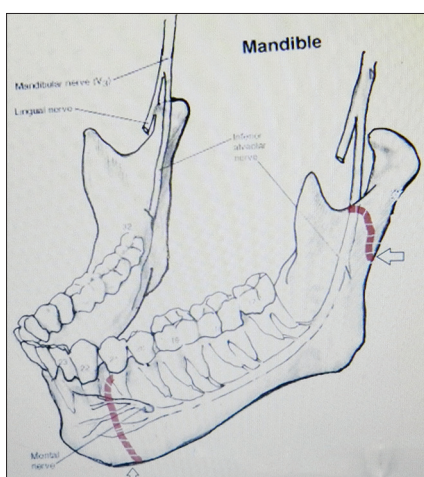


Figure 1: Site of double mandibular osteotomy for segmental mandibular swing

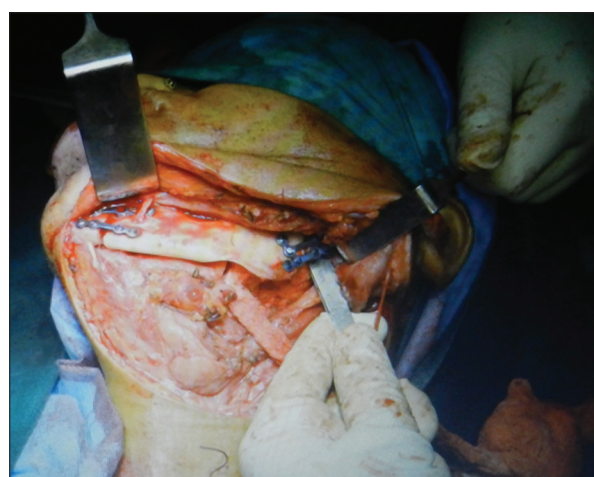

Figure 2: Per-operative view of fixation of mandibular segment with titanium plates and screw

CONCLUSION

When confronted with large PPS tumor extending to skull base, the Otolaryngologist can use the technique of Segmental Mandibulotomy Swing or Double Mandibular Osteotomy approach for complete access to this potential space. Combined with the application of a rigid mini-plate fixation, segmental mandibulotomy offers superior result compared to the standard single parasymphysis osteotomy mandibular swing.

REFERENCES

1. Lazaridis N, Antoniadis K. Double mandibular osteotomy with coronoidectomy for tumours in the parapharyngeal space. *Br J Oral Maxillofac Surg* 2003;41:142-6.
2. Gadre PK, Gadre KS, Halli RC, Kukarni A, Bhosale G. Mandibular subsigmoid access osteotomy in the management of parapharyngeal space tumors. *J Craniofac Surg* 2013;24:579-82.
3. Olsen KD. Tumors and surgery of the parapharyngeal space. *Laryngoscope* 1994;104 (5 Pt 2 Suppl 63):1-28.
4. Khafif A, Segev Y, Kaplan DM, Gil Z, Fliss DM. Surgical management of parapharyngeal space tumors: A 10-year review. *Otolaryngol Head Neck Surg* 2005;132:401-6.
5. Guinto G, Abello J, Molina A, Gallegos F, Oviedo A, Nettel B, *et al.* Zygomatic-transmandibular approach for giant tumors of the infratemporal fossa and parapharyngeal space. *Neurosurgery* 1999;45:1385-98.
6. Papadogeorgakis N, Petsinis V, Goutzanis L, Kostakis G, Alexandridis C. Parapharyngeal space tumors: Surgical approaches in a series of 13 cases. *Int J Oral Maxillofac Surg* 2010;39:243-50.
7. Ariel IM, Jerome AP, Pack GT. Treatment of tumors of the parotid salivary gland. *Surgery* 1954;35:124-58.
8. Bozza F, Vigili MG, Ruscito P, Marzetti A, Marzetti F. Surgical management of parapharyngeal space tumours: Results of 10-year follow-up. *Acta Otorhinolaryngol Ital* 2009;29:10-5.
9. Rodríguez-Ciurana J, Rodado C, Sáez M, Bassas C. Giant parotid pleomorphic adenoma involving the parapharyngeal space: Report of a case. *J Oral Maxillofac Surg* 2000;58:1184-7.

How to cite this article: Satpathy S, Dam A, Hossain MA, Chatterjee J. Double mandibular osteotomy with segmental mandibular swing approach to parapharyngeal space. *Natl J Maxillofac Surg* 2014;5:213-6.

Source of Support: Nil. **Conflict of Interest:** None declared.