

- 4 Rice SM, Ferree SD, Mesinkovska NA *et al.* The art of prevention: COVID-19 vaccine preparedness for the dermatologist. *Int J Womens Dermatol.* 2021; 7: 209–212.
- 5 Jedlowski PM, Jedlowski MF. Morbiform rash after administration of Pfizer-BioNTech COVID-19 mRNA vaccine. *Dermatol Online J* 2021; 27: 13030. PMID: 33560802.

DOI: 10.1111/jdv.17248

Skin manifestations of the BNT162b2 mRNA COVID-19 vaccine in healthcare workers. ‘COVID-arm’: a clinical and histological characterization

Dear Editor,

The coronavirus disease 2019 (COVID-19) has been associated to a wide clinical spectrum of skin manifestations, including chilblain-like, urticarial, vesicular, maculopapular, livedoid and vasculitic lesions, among others.^{1,2} However, the exact pathophysiology for the appearance of skin lesions is still unknown. Several hypotheses have been suggested, including viral hypersensitivity reactions, overexpression of type I interferons, COVID-19 induced coagulopathy, thrombotic microangiopathy and direct viral damage.^{3–6} Potentially, some skin manifestations could also appear after vaccination with mRNA vaccines encoding the spike (S) protein of SARS-CoV-2. A delayed hypersensitivity reaction at the injection site of Moderna (mRNA-1273)⁷ and Pfizer-BioNTech, Puurs, Belgium (BNT162b2)⁸ vaccines has been recently described in the mass media as ‘COVID-arm’. The mRNA-1273 vaccine clinical trial reported delayed injection-site reactions (onset after day 8) in 0.8% participants after the first dose and in 0.2% after the second dose.⁷ The BNT162b2 clinical trial does not differentiate between immediate and delayed injection-site reactions, with an overall incidence of 5–7% after the first and second dose.⁸ In addition, delayed inflammatory reactions to dermal fillers have also been described.⁹

We designed a retrospective study to characterize the skin manifestations of the BNT162b2 mRNA COVID-19 vaccine in a tertiary referral hospital of Spain. A registry of vaccine-related side effects was created by the Occupational Health Department, including delayed injection-site reactions (Table 1). This vaccination campaign was conducted from January 11 to February 12 2021. Physical examination and duration of the skin manifestations were either directly evaluated or indirectly evaluated through clinical pictures. A skin biopsy was also performed in two cases.

Table 1 Characteristics and demographic data of the subjects with delayed injection-site reaction obtained from the registry of the BNT162b2 mRNA COVID-19 vaccine

Characteristics	
Number of subjects	103
Age, mean, years (range)	40.4 (20–64)
Sex, male (%)	12 (11.7%)
Sex, female (%)	91 (88.3%)
After 1 st dose	49 (47.6%)
After 2 nd dose	54 (52.4%)
Itch (%)	70 (68.0%)
Duration <8h (%)	23 (22.3%)
Duration 8–24h (%)	28 (27.1%)
Duration 24–72h (%)	38 (36.9%)
Duration >72h (%)	14 (13.6%)

From 4775 subjects that underwent BNT162b2 mRNA vaccination, a total of 864 overall side effects were registered (18.1%). The mean age was 43.2 years (range 19–72), and 721 (83.4%) patients were female. A delayed injection-site reaction (Fig. 1a) was present in 103 subjects (2.1%), either after the first dose (49/103; 47.6%) or after the second dose (54/103, 52.4%). 16/49 subjects (32.7%) had recurrent lesions with the second dose. It lasted for less than 8 h in 23 patients (22.3%), between 8 and 24 h in 27 patients (26.2%), between 48 and 72 h in 38 patients (36.9%) and more than 72 h in 14 patients (13.6%). Itch was reported in 70 patients (68.0%). Five patients (4.9%) also presented disseminated lesions. None of these patients developed anaphylactic symptoms. In addition, two cases (2/4775; 0.04%) of vaccine-related urticaria were registered, lasting less than a week and responding to oral antihistamines. Histologic examination of a delayed injection-site reaction (Fig. 1b) showed a superficial and deep perivascular lymphocytic infiltrate, with dilated vessels and intraluminal neutrophils. Immunohistochemistry for the SARS-CoV-2 spike 1A9 protein (GeneTex, Irvine, CA, USA) was negative.

Currently, there are scarce reports of skin side effects related to COVID-19 vaccines. Recently, a case series of delayed large local reactions to the mRNA-1273 vaccine has been published, including 12 cases.¹⁰ The median onset was on day 8 (range 4–11) after the first dose and resolved in a median of 6 days (range 2–11). Half of the patients had similar recurrent reactions after the second dose.

This delayed injection-site reaction shows similar features to COVID-19 exanthems.³ Whether it corresponds to a hypersensitivity reaction to the spike protein or to different components of the vaccine is still unknown. We also found two cases of urticaria triggered by the vaccine, in a similar fashion to the actual SARS-CoV-2 infection.⁶ The main limitation of the study is the self-reported and retrospective nature of the registry, so skin manifestations are probably under-ascertained. No severe cutaneous reactions were present in the study, suggesting that the

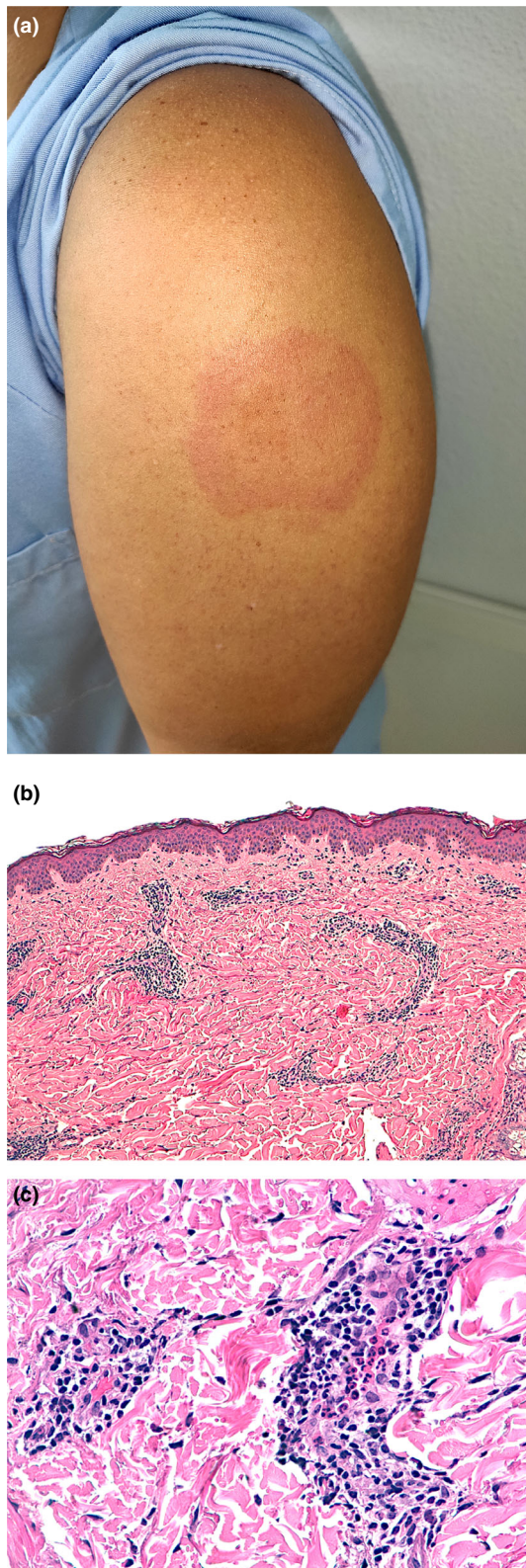


Figure 1 (a) A 34-year-old female healthcare worker showing a slightly indurated erythematous targetoid patch at the injection-site reaction of 6×4.5 cm diameter, 8 days after the first dose of the BNT162b2 vaccine. (b) Histologic examination shows a superficial and deep perivascular lymphocytic infiltrate (H-E $\times 100$). (c) Close-up examination shows dilated vessels, repleted with intraluminal neutrophils. An increased number of eosinophils or mast cells was not present (H-E $\times 400$).

BNT162b2 mRNA vaccine has a good safety profile regarding skin side effects.

Acknowledgements

The patients in this manuscript have given written informed consent to publication of their case details. Written consent was obtained from the patients included in this study. All human studies are approved by an Institutional Review Board.

Funding source

This article has no funding source.

Conflict of interest

The authors have no conflict of interest to declare.

D. Fernandez-Nieto,^{1,*} J. Hammerle,²
 M. Fernandez-Escribano,² C.M. Moreno-del Real,³
 P. Garcia-Abellas,³ I. Carretero-Barrio,³
 E. Solano-Solares,⁴ B. de-la-Hoz-Caballer,⁴
 J. Jimenez-Cauhe,¹ D. Ortega-Quijano,¹
 M. Fernandez-Guarino¹

¹Dermatology Department, Ramon y Cajal University Hospital, Instituto de investigación Sanitaria del Hospital Ramón y Cajal (Irycis), Madrid, Spain,

²Occupational Health Department, Ramon y Cajal University Hospital, Instituto de investigación Sanitaria del Hospital Ramón y Cajal (Irycis), Madrid, Spain, ³Pathology Department, Ramon y Cajal University

Hospital, Instituto de investigación Sanitaria del Hospital Ramón y Cajal (Irycis), Madrid, Spain, ⁴Allergy Department, Ramon y Cajal University Hospital, Instituto de investigación Sanitaria del Hospital Ramón y Cajal (Irycis), Madrid, Spain

*Correspondence: D. Fernandez-Nieto. E-mail: fnietodiego@gmail.com

References

- Galván Casas C, Català A, Carretero Hernández G *et al*. Classification of the cutaneous manifestations of COVID-19: a rapid prospective nationwide consensus study in Spain with 375 cases. *Br J Dermatol* 2020; **183**: 71–77. <https://doi.org/10.1111/bjd.19163>
- Marzano AV, Genovese G, Moltrasio C *et al*. The clinical spectrum of COVID-19-associated cutaneous manifestations: an Italian multicentre study of 200 adult patients. *J Am Acad Dermatol* 2021; **84**: 1356–1363. <https://doi.org/10.1016/j.jaad.2021.01.023>
- Garrido Ruiz MC, Santos-Briz Á, Santos-Briz Á *et al*. Spectrum of clinicopathologic findings in COVID-19-induced skin lesions: demonstration of direct viral infection of the endothelial cells. *Am J Surg Pathol* 2021; **45**: 293–303.
- Zhang Y, Cao W, Xiao M *et al*. Clinical and coagulation characteristics in 7 patients with critical COVID-2019 pneumonia and acro-ischemia. *Zhonghua Xue Ye Xue Za Zhi Zhonghua Xueyexue Zazhi* 2020; **41**: 302–307.

- 5 Kolivras A, Dehavay F, Delplace D *et al.* Coronavirus (COVID-19) infection-induced chilblains: a case report with histopathologic findings. *JAAD Case Rep* 2020; **6**: 489–492.
- 6 Kubanov AA, Deryabin DG. Skin manifestations in COVID-19 provide a clue for disease's pathophysiology understanding. *J Eur Acad Dermatol Venereol JEADV* 2021; **35**: e3–e4. <https://doi.org/10.1111/jdv.16902>
- 7 Baden LR, El Sahly HM, Essink B *et al.* Efficacy and Safety of the mRNA-1273 SARS-CoV-2 Vaccine. *N Engl J Med* 2021; **384**: 403–416.
- 8 Polack FP, Thomas SJ, Kitchin N *et al.* Safety and efficacy of the BNT162b2 mRNA Covid-19 vaccine. *N Engl J Med* 2020; **383**: 2603–2615.
- 9 Munavalli GG, Guthridge R, Knutsen-Larson S *et al.* COVID-19/SARS-CoV-2 virus spike protein-related delayed inflammatory reaction to hyaluronic acid dermal fillers: a challenging clinical conundrum in diagnosis and treatment. *Arch Dermatol Res* 2021; **9**: 1–15. <https://doi.org/10.1007/s00403-021-02190-6>
- 10 Blumenthal KG, Freeman EE, Saff RR *et al.* Delayed large local reactions to mRNA-1273 vaccine against SARS-CoV-2. *N Engl J Med* 2021; **384**: 1273–1277. <https://doi.org/10.1056/NEJMc2102131>

DOI: 10.1111/jdv.17250

Position statement of the EADV Melanoma Task Force on recommendations for the management of cutaneous melanoma patients during COVID-19

Dear Editor,

This article prepared by the EADV Task Force on Melanoma aims at providing consensus-based recommendations on how to address the main challenges in management of patients with cutaneous melanoma during the COVID-19 pandemic.^{1,2}

- 1 In-person physical examinations remain irreplaceable for patients who have noticed new suspicious lesions or are referred by a clinician with a lesion suspicious for melanoma. For individuals who need periodical examinations due to increased melanoma risk, intervals between visits may be extended by a maximum of 2–3 months. For routine check-ups, the use of teledermatology is recommended. These efforts aim at limiting the risk of potential exposure to COVID-19.
- 2 Dermoscopy remains the gold standard for diagnosis of melanoma. Even though no transmission of COVID-19 via dermatoscopes has been reported, dermoscopy should be performed with careful disinfection between patients, to avoid the transmission of infectious agents, including bacteria, fungi and viruses. Epidemiological triage, proper hand hygiene and adequate personal protection equipment by physicians and patients are warranted.

- 3 Once a lesion is clinically suspicious of melanoma, an excisional biopsy with the intent to remove the whole clinically visible lesion should be performed as soon as possible. The timing of additional surgical procedures might require modification depending on the availability of operating rooms. A proposed approach after complete excision of primary melanoma during restrictions and limitations due to the pandemic is shown in Table 1.
- 4 In case of a COVID-19 lockdown, follow-up visits and imaging procedures may be postponed in asymptomatic patients with melanoma stage 0-IIA by up to 3 months. Teleconsultations with asymptomatic patients can help to foster the physician-patient relationship, reassure patients and strengthen compliance. Tumour-free, high-risk patients should continue to have physical and imaging examinations especially during the first 3 years after surgery of the primary tumour. All patients should be educated and encouraged to perform skin self-examination once per month.
- 5 Adjuvant melanoma treatment with approved drugs is recommended during the COVID-19 pandemic and should be initiated within the first 12 weeks after complete resection. PD-1 antibodies should be given using the longest approved treatment intervals: pembrolizumab 400 mg q6w and nivolumab 480 mg q4w.⁸ Targeted therapy allows for less frequent hospital visits, shorter time spent in the hospital/facility and telemedicine symptom checks. Yet, one needs to consider that the frequently occurring adverse event pyrexia might trigger false alarms in people and physicians unfamiliar with the safety profile of the dabrafenib + trametinib drug combination.

Table 1 Practical approach to melanoma surgery during the COVID-19 pandemic

Wide excision should be performed as soon as possible but within 3 months at the latest for both melanoma in situ and invasive melanoma ^{3,4}
Sentinel lymph node biopsy may be delayed by up to 3 months ^{5,6}
Therapeutic lymph node dissection should be limited to patients with clinically evident regional lymph node metastases ⁷
High surgical priority should be given to all invasive primary melanomas, resectable stage III melanomas and oligo-metastatic disease

Table 2 General recommendations for melanoma care at a glance

The COVID-19 pandemic mandates precautions to minimize the risk of infections, while ensuring most effective cancer care
Teledermatology is a valuable tool in times of lockdown and limitation of face-to-face visits
The initiation of adjuvant and therapeutic melanoma therapy should not be delayed during the COVID-19 pandemic
Treatment decisions require the consideration of individual risk factors and melanoma characteristics