



Arthroplasty in patients with rare conditions

Total knee arthroplasty in hemophilia A

Neil Pathak, BS^a, Alana M. Munger, MD^{a,*}, Ahmad Charifa, MD^b, William B. Laskin, MD^b,
Emily Bisson, APRN, CPNP^c, Gary M. Kupfer, MD^c, Lee E. Rubin, MD^a

^a Department of Orthopaedics and Rehabilitation, Yale School of Medicine, New Haven, CT, USA

^b Department of Pathology, Yale School of Medicine, New Haven, CT, USA

^c Department of Pediatric Hematology, Yale School of Medicine, New Haven, CT, USA

ARTICLE INFO

Article history:

Received 19 October 2019

Received in revised form

9 December 2019

Accepted 26 December 2019

Available online 6 March 2020

Keywords:

Hemophilia A

Total knee arthroplasty

Factor VIII

Hemophilic arthropathy

ABSTRACT

Hemophilia A is a rare genetic disorder involving a deficiency of clotting factor VIII. Coagulation factor replacement therapy has prolonged the life expectancy of patients with hemophilia, but recurrent hemarthrosis of major joints is often a common occurrence. Therefore, orthopaedic adult reconstructive surgeons increasingly encounter hemophilic arthropathy in young adults and consider treating with total joint arthroplasty. In this report, the authors describe a patient with hemophilia A and severe knee osteoarthritis, who was subsequently treated with primary total knee arthroplasty. This rare case is an opportunity to explore a variety of unique clinical scenarios specific to patients with hemophilia, including the maintenance of optimal factor VIII levels through clotting factor infusions and prevention of a venous thromboembolic event.

© 2019 The Authors. Published by Elsevier Inc. on behalf of The American Association of Hip and Knee Surgeons. This is an open access article under the CC BY-NC-ND license (<http://creativecommons.org/licenses/by-nc-nd/4.0/>).

Introduction

Hemophilia A and B are rare, inherited bleeding disorders that occur owing to mutations in the factor VIII or factor IX gene, respectively. Each of these clotting factors plays a role in the intrinsic pathway of blood coagulation [1]. These disorders are known to be X-linked recessive and are thus much more commonly seen in males. The prevalence of hemophilia A is approximately 1 in 5000 male live births and that of hemophilia B is about 1 in 30,000 male live births [1,2]. Patients with hemophilia can have mild, moderate, or severe types of the condition, defined by plasma factor levels of 6%–40%, 1%–5%, or less than 1%, respectively [3].

One or more of the authors of this paper have disclosed potential or pertinent conflicts of interest, which may include receipt of payment, either direct or indirect, institutional support, or association with an entity in the biomedical field which may be perceived to have potential conflict of interest with this work. For full disclosure statements refer to <https://doi.org/10.1016/j.artd.2019.12.008>.

The authors declare that they have no known competing financial interests or personal relationships that could have appeared to influence the work reported in this paper.

* Corresponding author. Department of Orthopaedics and Rehabilitation, Yale School of Medicine, 800 Howard Avenue, PO Box 208071, New Haven, CT 06520-8071, USA. Tel.: +1-203 785 2579.

E-mail address: dr.alana.munger@gmail.com

<https://doi.org/10.1016/j.artd.2019.12.008>

2352-3441/© 2019 The Authors. Published by Elsevier Inc. on behalf of The American Association of Hip and Knee Surgeons. This is an open access article under the CC BY-NC-ND license (<http://creativecommons.org/licenses/by-nc-nd/4.0/>).

Lifelong factor replacement therapy is essential to increase life expectancy and minimize complications, including musculoskeletal bleeding. However, such orthopaedic complications may still occur due to suboptimal dosing of factor therapy, poor medication adherence, or the development of inhibitors (antibodies that target factor VIII or factor IX) [1]. As a result, patients with hemophilia may develop orthopaedic manifestations such as hemarthrosis. Repeated bleeding into the joints, most commonly the ankle, elbow, and knee, leads to cartilage damage and degenerative articular changes, potentially leading to severe osteoarthritis [4]. Hemophilic arthropathy has been found to be present in approximately 90% of hemophilia patients by the third decade of life [4].

Given the consequences of hemophilia on articular tissues, elective procedures such as arthroscopic synovectomy, osteotomy, arthrodesis, arthroplasty, and revision arthroplasty may be considered in select patients [5,6]. As the life expectancy for patients with hemophilia continues to improve with medical advancements, orthopaedic surgeons may be increasingly tasked with performing elective total joint arthroplasty in these patients.

Surgery in patients with hemophilia is challenging given the high risk of bleeding and infection [1]. The purpose of this article is three fold: (1) to outline the clinical course of a patient with hemophilia A who underwent elective total knee arthroplasty (TKA), (2) to review the reported outcomes of total joint arthroplasty for hemophilic arthropathy, and (3) to describe the clinical and surgical considerations for managing these patients.

Case history

A 24-year-old man with moderate hemophilia A (factor VIII deficiency) and history of recurrent hemarthroses presented to the arthroplasty clinic for evaluation of right knee pain. His baseline factor VIII level was 3%, and he had no history of a factor VIII inhibitor. His chief complaints included left ankle pain and right knee pain spanning a few years. He denied pain in his left knee or either hip. To ambulate, he used 2 crutches and an Arizona ankle brace (ArizonaAFO, Inc., Mesa, AZ) due to pain. At this time, he was receiving antihemophilic factor recombinant (Kogenate, Bayer Pharmaceuticals, Leverkusen, Germany) 4000 units ($\pm 10\%$) infusions 3 times weekly at the recommendation of his pediatric hematologist. On physical examination, he walked with an antalgic gait and could not rise from a seated position without using his hands to push off for assistance. He lacked 20 degrees of flexion and did not exhibit any apparent valgus or varus deformity. A radiograph of the right knee demonstrated well-preserved joint space with some arthritic changes. A magnetic resonance imaging examination without contrast showed tricompartmental arthritis with erosive changes and extensive hemosiderin deposition lining the joint (Fig. 1). Given his World Health Organization (WHO) classification of morbid obesity (BMI: 42.43), the patient was advised to undertake conservative measures such as physical therapy, weight loss, and exercise to optimize his health before considering total joint arthroplasty.

Approximately 2 years later, he returned to the clinic and expressed that his right knee discomfort had become refractory to conservative measures and thus requested consultation to proceed with surgical intervention. At this time, his BMI had decreased to 39.14, and he was now taking antihemophilic factor recombinant (Eloctate, Bioverativ Therapeutics Inc., Waltham, MA) 4500 units 2 times weekly. Approximately 5 months before this presentation, the patient's regimen was changed from Kogenate to Eloctate—an extended half-life antihemophilic recombinant factor VIII product. The transition to Eloctate decreased the frequency of his infusions from 3 times weekly to 2 times weekly.

On physical examination, he had increased difficulty transitioning from chair to standing. Range of motion progressed from full extension to approximately 120 degrees of gross flexion. A mild

knee effusion was present. Updated radiographs of the right knee demonstrated joint space narrowing and cystic changes beneath the joint line, suggesting progressively worsening tricompartmental osteoarthritic degenerative changes (Fig. 2).

Given the fact that his symptoms had worsened, radiographs suggested further arthritic damage, and he had failed conservative management, the option of surgical intervention was reviewed with the patient. The risks, benefits, and alternatives to TKA were discussed with the patient. Short-term risks included hemarthrosis in the knee joint, wound drainage, and infection. Long-term risks included uncertainty concerning the longevity of the implants in younger patients and the possibility of subsequent revision surgeries. Although previous reports have assessed longevity of TKA implants overall, the lifespan of implants in younger patients is not well studied. The 20-year TKA implant survival rate is estimated to be 89.7%, with the lifetime revision rate for males 50–54 years of age (the youngest age group studied in this investigation) is estimated to be 29.6% [7].

The patient decided to pursue elective right TKA. With the diagnosis of hemophilia A and associated higher risk of bleeding and infection [1], the standardized preoperative, intraoperative, and postoperative protocols would need to be adjusted. For this reason, a team-based approach was used to optimize the clinical management of the patient. In the weeks before the surgery, the pediatric hematology team at our institution recommended that the patient remain on Eloctate 4500 units twice weekly until surgery to protect against bleeding. Ten days before surgery, the patient completed a pharmacokinetic (PK) study using antihemophilic factor recombinant (Kogenate) 5000 units ($\pm 10\%$). This allowed the hematology team to create an individualized plan for the dosing and frequency of factor VIII infusions to assure adequate hemostasis during and after the procedure. Kogenate was used (rather than Eloctate) as the former product is on formulary at our institution and the patient had a 20-year history of good response to this agent. Finally, the patient was advised to stop all over-the-counter nonsteroidal anti-inflammatory drugs and vitamins 7 days before surgery per standard protocol.

Immediately before surgery, the patient received a preoperative dose of antihemophilic factor recombinant (Kogenate) 5000 units ($\pm 10\%$). The hematology team recommended that pharmacologic

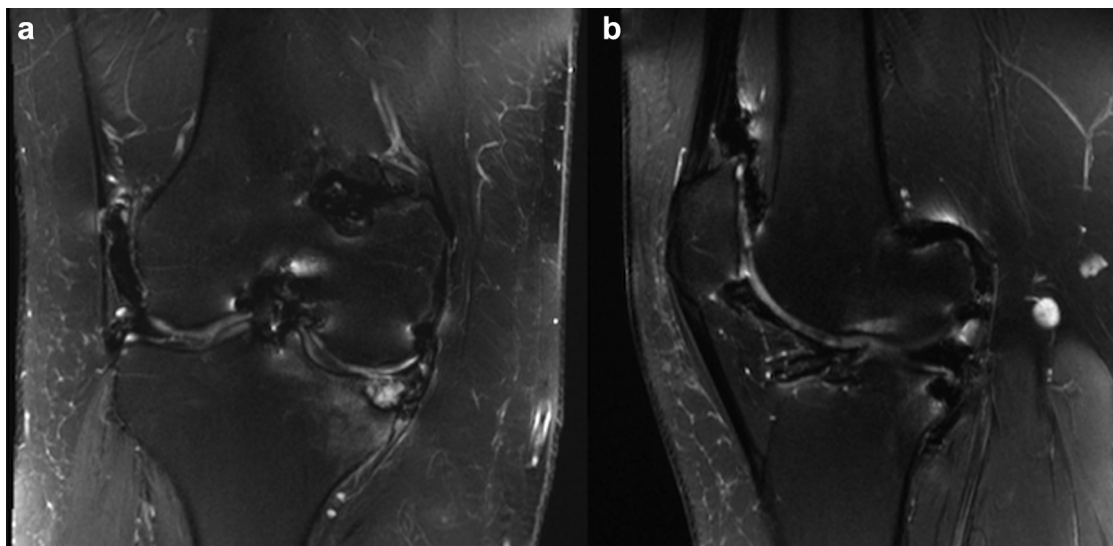


Figure 1. Coronal (a) and sagittal (b) fat-suppressed T2-weighted magnetic resonance images of the patient's right knee demonstrates hemosiderin deposition within the lining of the joint, extensive erosive changes in the posterior aspect of the femur and medial tibial plateau, and extensive tricompartmental osteoarthritis.

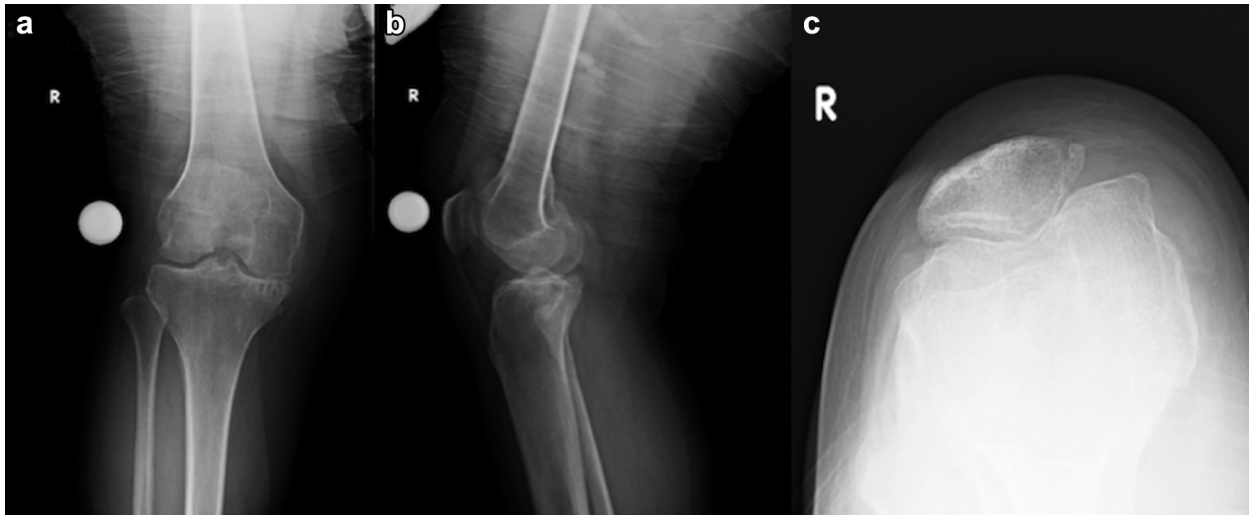


Figure 2. Preoperative (a) anteroposterior; (b) lateral; (c) axial radiographs. There is tricompartmental osteoarthritis manifested by medial tibiofemoral joint space narrowing, subchondral sclerosis, subchondral cysts, and osteophyte formation.

venous thromboembolic event (VTE) prophylaxis was not to be given as the risk for bleeding was greater than the risk for either a deep venous thrombosis (DVT) or fatal pulmonary embolism. However, intermittent pneumatic compression devices (IPCDs) were recommended to be used perioperatively and postoperatively. Intraoperatively, an additional dose of Kogenate was available in case of unexpected or excessive bleeding.

Postoperatively, the hematology team recommended measuring the factor VIII activity level, and a regimen of Kogenate 5000 units every 8 hours for the first 24 hours after surgery. On the first day after surgery (postoperative day 1), the patient's Kogenate 5000 units infusion frequency was anticipated to be changed to once every 12 hours and titrated based on his recorded factor VIII trough levels. The dose of the Kogenate infusion was anticipated to be titrated to maintain a factor VIII level of greater than 80% 3 days

postoperatively and greater than 50% for the remainder of the inpatient hospitalization. Discharge was anticipated when the patient exhibited a stable hemoglobin level, postoperative hemostasis was assured, and adequate factor VIII levels were consistently obtained. At discharge, the infusion protocol was developed by our Hemophilia Treatment Center team. In addition, nonsteroidal anti-inflammatory drugs were not given for pain control due to their anti-platelet effect.

On the day of surgery, the patient received 2 grams of intravenous (IV) cefazolin, 160 mg of IV gentamicin, and 1 gram of IV tranexamic acid before incision. Preoperative examination under anesthesia of the right knee demonstrated range of motion of 0 to 110 degrees, with 5 degrees of passively correctable varus. In addition, it was noted that there was no tibial or femoral deformity present that would preclude the use of intramedullary guides. A

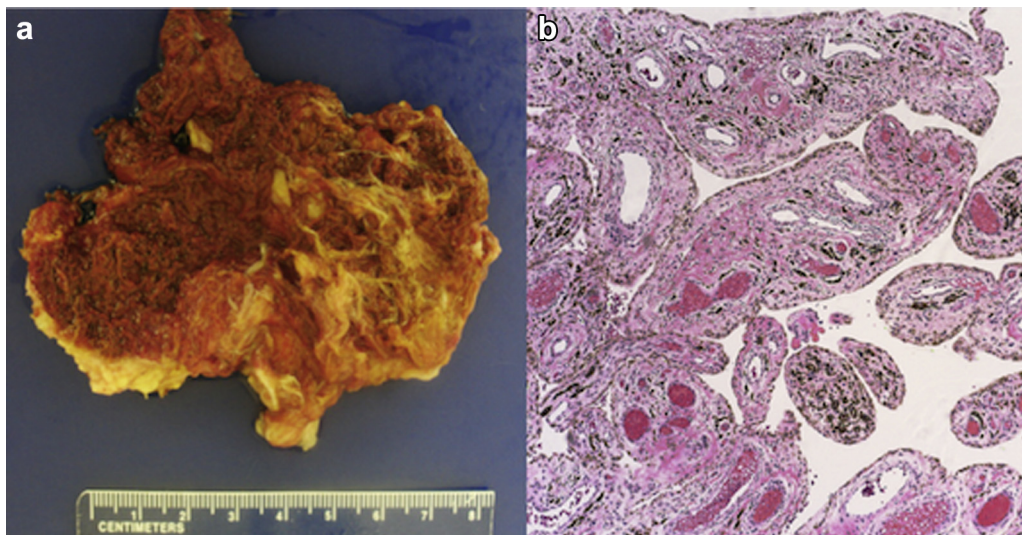


Figure 3. (a) The synovial tissue removed at surgery (right knee) was large and, unlike rheumatoid synovium, had a distinct color of burnt sienna. Similar to rheumatoid and other types of proliferative synovitis, the surface of the synovial lining had multiple small and large villous projections. (b) Histologic sections revealed synovial cell hyperplasia, an increase in small blood vessels, and deposition of hemosiderin pigment.

tourniquet was placed appropriately before the surgery. A medial parapatellar arthrotomy was performed to expose the knee joint. On entering the knee, we observed significant cartilage wear in addition to tricompartmental osteoarthritis. There was also abundant synovial hypertrophy with hemosiderin staining. Fronds of synovium were systematically debrided and sent to pathology (Figs. 3 and 4), which were consistent with changes seen with recurrent hemarthroses.

When the prosthetic implants were placed, final range of motion was 0 to 130 degrees with smooth patellar tracking and well-balanced collateral ligament stability at 0, 30, 45 and 90 degrees. Meticulous hemostasis was obtained after final tourniquet release. Once the capsule was closed in a watertight manner, 1 gram of intra-articular tranexamic acid (TXA) was injected into the joint for topical hemostasis. After the surgery, he was placed in a compressive dressing with a knee immobilizer, and IPCDs were appropriately applied. Postoperative radiographs demonstrated successful prosthesis placement (Fig. 5).

Postoperatively, the patient was given a dose of 2 grams of IV cefazolin. His postoperative factor VIII levels were noted to be 134%. The patient's Kogenate infusion frequency followed the anticipated postoperative protocol of every 8 hours for the first 24 hours after

surgery. On the first postoperative day, he was transferred to our local sister hospital which houses both the special coagulation laboratory and the Hemophilia Treatment Center staff, thereby facilitating closer clinical and laboratory monitoring. The patient continued to receive Kogenate 5000 units \pm 10% as per the original protocol until postoperative day 3, when his factor VIII level was noted to be 171%. At the guidance of the Hemophilia Treatment Center team, his infusion protocol was then adjusted to Kogenate 3500 units \pm 10% twice a day. On the fourth postoperative day, his knee immobilizer was removed, and gentle active seated knee range of motion was initiated. On the fifth postoperative day, he was discharged. It was decided that this infusion protocol be adjusted to Kogenate 5000 units \pm 10% once a day for the week after discharge. One week after discharge, his protocol was changed to Kogenate 5000 U \pm 10% every other day and before physical therapy sessions. One month after discharge, the same regimen was maintained, with the adjustment of the dosage to Kogenate 3000 units \pm 10%.

During his hospitalization, early ambulation was encouraged by the in-patient physical therapy team, and IPCDs were used for DVT prophylaxis. He received Tylenol as needed for pain management, and all nonsteroidal anti-inflammatory drugs were avoided.

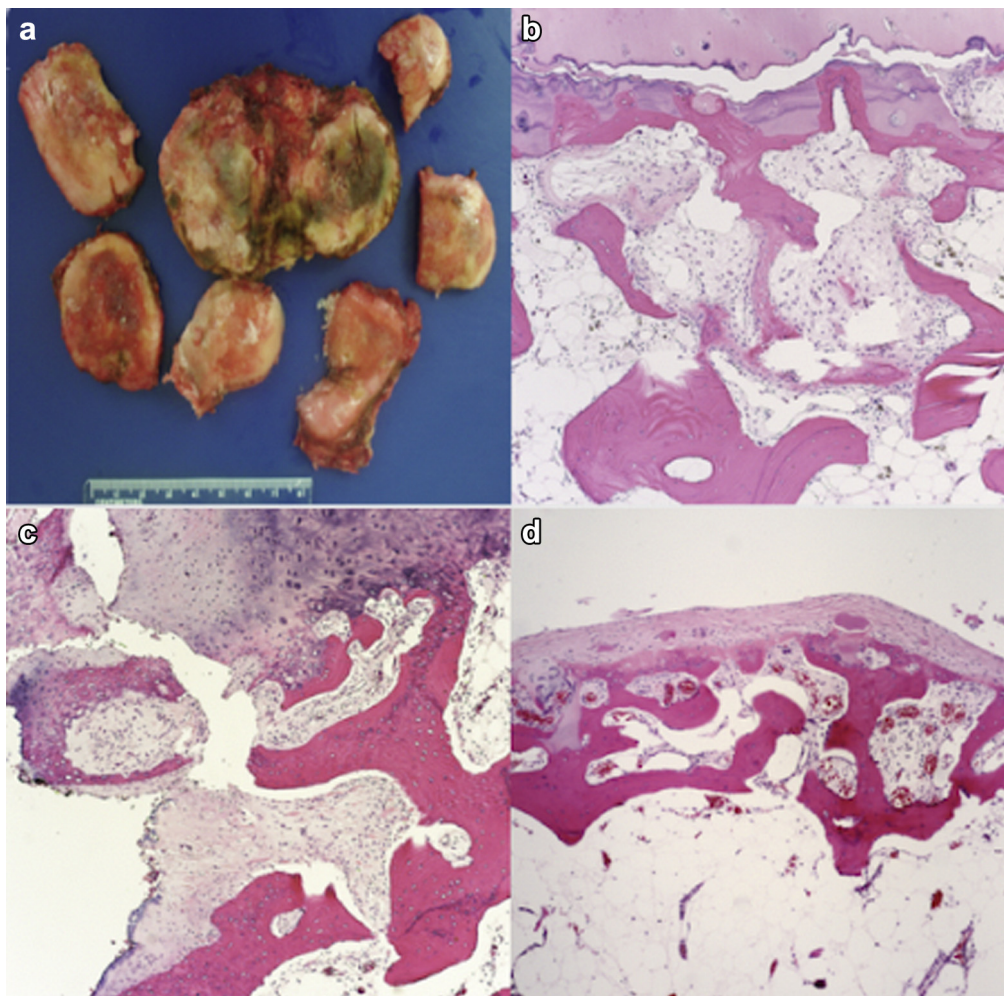


Figure 4. (a) The right knee joint bones showed erosion and cracking of articular surface with areas of denudation and exposure of underlying bone. (b) Histologic sections showed duplication of “the tide mark” with marked irregularity. Subchondral cysts were noted showing sparsely cellular, and loose connective tissue. (c) Endochondral ossification with osteoblastic proliferation and increased vascularity and immature woven bone formation were also seen at the bone-cartilage interface. (d) Pannus formation was also seen in the form of synovial growth into the joint.

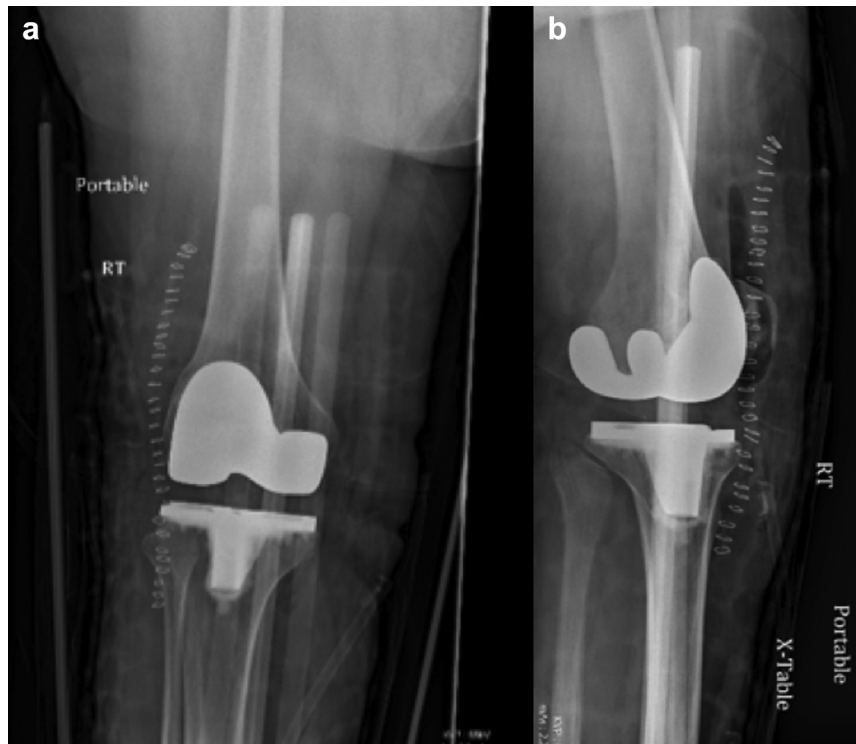

Figure 5. Postoperative (a) anteroposterior and (b) lateral radiographs of the patient. Prosthesis appears in correct position with no radiographic evidence of hardware complication.

Furthermore, on discharge, the patient was advised to avoid all elective dental procedures for 6 months.

Pathologic review of the specimens collected intraoperatively (Figs. 3 and 4) revealed synovial cell hyperplasia and deposition of hemosiderin pigment.

At 2 weeks postoperatively, his antimicrobial occlusive dressing was removed, and skin staples were removed. At the 6-week postoperative follow-up appointment, the patient stated that his right knee pain had resolved and that he was able to ambulate independently. He also denied any bleeding or discharge from the incision site since the day of surgery. Follow-up anteroposterior and lateral radiographs were ordered (Fig. 6) and noted that the implants remained in acceptable position. He exhibited nonpainful range of motion from 0 to 108 degrees of flexion.

Discussion

In this article, we present a patient with hemophilia A who underwent right TKA. This case raises several special considerations regarding preoperative, perioperative, and postoperative management.

TKA in patients with hemophilia has been shown to be effective and to significantly improve quality of life [8–10]. Ten-year survival rates for knee arthroplasty implants have been reported to be as high as 94.3% [11]. However, investigations have found that TKA in these patients is associated with high rates of infection, intraoperative complications, and revision surgeries [6,12–18]. The prevalence of infection after primary TKA in patients with hemophilia ranges from 0 to 17% in the literature, which is higher than the reported prevalence of 1–2% seen in TKA patients

who do not have hemophilia [12]. Feng et al. [19] suggested that patients with hemophilic arthropathy may be at higher risk of an intraoperative popliteal artery injury. Another investigation found an overall complication rate (major and minor, including infection) of 31.5% in patients with hemophilic arthropathy undergoing TKA [10]. Finally, revision surgery rates after primary TKA performed in patients with hemophilia have been reported to be as high as 30% [12].

The hematologic protocols from our institution highlight the importance of adjusting daily infusions based on daily factor VIII trough levels. Some centers have optimized factor levels by using a pharmacokinetic-guided, maximum a posteriori Bayesian analysis to adjust the clotting factor infusion dosage on a day-to-day basis [20]. In addition, optimizing factor VIII levels in patients with hemophilia undergoing TKA is of utmost importance in reducing the rates of bleeding as well as infection. In fact, postoperative clotting factor levels of 100% have been associated with a decreased infection and failure rate [21]. The optimal target clotting factor level after TKA, however, has been subject to discussion in the hemophilia population. Various studies have reported different postoperative clotting factor target levels after TKA. In a meta-analysis of studies assessing hemophilia patients undergoing TKA [10], 9 of 10 clinical studies included demonstrated the target clotting factor level to be 70% (range 50%–100%) for the first week postoperatively [13,22–30]. In these reports, a taper was subsequently applied for a hospitalization longer than 1 week.

Our case also shows the importance of using intra-articular TXA to decrease intraoperative and postoperative bleeding risk in the hemophilia population. A prior investigation of 34 patients with hemophilia undergoing TKA showed that a combination of IV

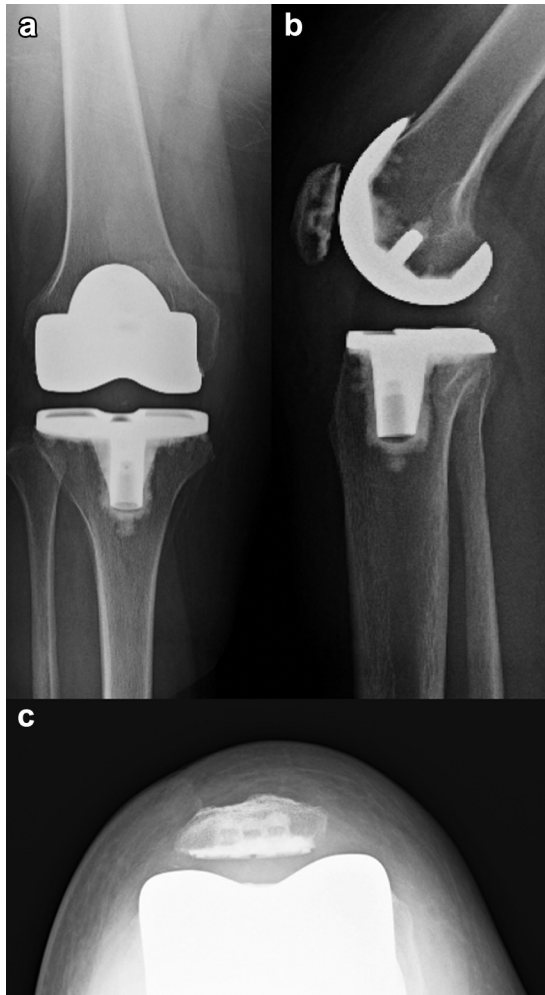


Figure 6. Six-week postoperative radiographs of the patient: (a) anteroposterior; (b) lateral; (c) axial.

and intra-articular TXA significantly reduced perioperative blood loss, transfusion rates, and postoperative knee swelling [31]. This referenced study also showed that that total amount of factor VIII administered postoperatively was reduced in cases using TXA.

Although the use of DVT prophylaxis is of standard protocol in most patients undergoing total joint arthroplasty, the hemophilia population represents a unique cohort in which the risk of bleeding with pharmacologic DVT prophylaxis must be weighed with the risk of venous thromboembolism. The incidence of major bleeding in patients with hemophilia undergoing total hip arthroplasty or total knee arthroplasty in the setting of low-weight molecular heparin use is estimated to be 50% [32]. Moreover, the overall incidence of major bleeding for patients with hemophilia undergoing total joint arthroplasty regardless of prophylaxis type is estimated to be 39.1% [32]. The authors' institution as well as previous reports recommend the use of nonpharmacologic DVT prophylaxis such as IPCDs and early ambulation [10]. Weighing the risk of surgical site bleeding against risk of DVT/pulmonary embolism is challenging. As DVTs typically occur more frequently in older patients, nonpharmacologic VTE prophylaxis may be preferred over chemoprophylaxis in the generally younger population of patients with hemophilia undergoing TKA [33]. However, in older patients or patients with additional comorbidities, VTE chemoprophylaxis may be considered on a case-by-case basis.

Current controversies and future considerations

The optimal clotting factor type, dosing protocols, and target factor levels in the perioperative and postoperative period for patients with hemophilia undergoing TKA have been a subject of debate and several controversies exist. Currently, there is no definitive clotting factor infusion protocol for patients with hemophilia undergoing TKA. Therefore, investigations should be performed to determine optimal dosing regimens and narrow factor level target ranges to prevent the catastrophic complication of hemarthrosis. Furthermore, an improved understanding of the risk of pharmacologic VTE prophylaxis in patients with hemophilia undergoing TKA may be warranted for different age groups. The question of whether nonpharmacologic prophylactic measures are acceptable for higher-risk patients (such as older patients or patients with other conditions such as obesity or malignancy) should be investigated further across a larger sample size. For our patient, the use of IPCDs and early ambulation was used as the risk for major bleeding and infection was felt to outweigh the risk for VTE.

Summary

Medical innovations in the clinical management of patients with hemophilia A or B have allowed for greater survival and improved quality of life, but recurrent hemarthrosis of major joints remains a common problem, leading to hemophilic arthropathy of the knee, ankle, and elbow. As a result, there is likely to be a higher incidence of total joint arthroplasty in this patient population at a young age. Given the associated increased risks of revision, loosening, and infection, patients with this disorder warrant additional precautions and planning in the perioperative and postoperative periods. One should medically optimize the patient and take great care to avoid the complications of major bleeding or infection by optimizing factor VIII levels in the perioperative period. During surgery, meticulous hemostasis must be obtained at each step of the surgical exposure, using electrocautery, canal plug(s), and TXA. Knee compression and an initial period of immobilization for 5–7 days should be considered to reduce the risk of postoperative hemarthrosis, and the surgeon should likely avoid VTE chemoprophylaxis in low-risk patients. Establishing close collaboration and co-management strategies with an expert hematology team are critical to ensure the safety of the procedure, and long-term maintenance of factor VIII level is also needed to help prevent future hemarthrosis in the knee joint after arthroplasty.

KEY POINTS

- In patients with hemophilia, there is a high risk for recurrent hemarthroses of major joints, which may eventually lead to hemophilic arthropathy and the need for joint replacement.
- Clotting factor infusion protocols should be developed in collaboration with the institution's hematology staff to minimize risk of bleeding. In the perioperative period, dosing amount and frequency should be titrated based on daily factor VIII levels.
- If possible, chemoprophylaxis for venous thromboembolic events can be avoided given the high risk of major bleeding and hemarthrosis at the surgical site. Instead, non-pharmacologic prophylaxis including IPCDs and early ambulation can be used.

References

- [1] Franchini M, Mannucci PM. Past, present and future of hemophilia: a narrative review. *Orphanet J Rare Dis* 2012;7:24.
- [2] Bolton-Maggs PH, Pasi KJ. Haemophilias A and B. *Lancet* 2003;361:1801.
- [3] Mannucci PM, Tuddenham EG. The hemophilias—from royal genes to gene therapy. *N Engl J Med* 2001;344:1773.
- [4] Rodriguez-Merchan EC, Valentino LA. Orthopedic disorders of the knee in hemophilia: a current concept review. *World J Orthop* 2016;7:370.
- [5] Rizzo AR, Zago M, Carulli C, Innocenti M. Orthopaedic procedures in haemophilia. *Clin Cases Miner Bone Metab* 2017;14:197.
- [6] Mortazavi SM, Haghpanah B, Ebrahimi MM, Baghdadi T, Toogeh G. Functional outcome of total knee arthroplasty in patients with haemophilia. *Haemophilia* 2016;22:919.
- [7] Bayliss LE, Culliford D, Monk AP, et al. The effect of patient age at intervention on risk of implant revision after total replacement of the hip or knee: a population-based cohort study. *Lancet* 2017;389:1424.
- [8] Song SJ, Bae JK, Park CH, Yoo MC, Bae DK, Kim KI. Mid-term outcomes and complications of total knee arthroplasty in haemophilic arthropathy: a review of consecutive 131 knees between 2006 and 2015 in a single institute. *Haemophilia* 2018;24:299.
- [9] Solimeno LP, Pasta G. Knee and ankle arthroplasty in hemophilia. *J Clin Med* 2017;6:107.
- [10] Moore MF, Tobase P, Allen DD. Meta-analysis: outcomes of total knee arthroplasty in the haemophilia population. *Haemophilia* 2016;22:e275.
- [11] Santos Silva M, Rodrigues-Pinto R, Rodrigues C, Morais S, Costa ECJ. Long-term results of total knee arthroplasty in hemophilic arthropathy. *J Orthop Surg (Hong Kong)* 2019;27. 2309499019834337.
- [12] Ernstbrunner L, Hingsammer A, Catanzaro S, et al. Long-term results of total knee arthroplasty in haemophilic patients: an 18-year follow-up. *Knee Surg Sports Traumatol Arthrosc* 2017;25:3431.
- [13] Feng B, Weng XS, Lin J, et al. Outcome of total knee arthroplasty combined patelloplasty for end-stage type A hemophilic arthropathy. *Knee* 2012;19:107.
- [14] Mortazavi SMJ, Sobhan MR, Mazoocy H. Brucella arthritis following total knee arthroplasty in a patient with hemophilia: a case report. *Arch Bone Joint Surg* 2017;5:342.
- [15] Cancienne JM, Werner BC, Browne JA. Complications after TKA in patients with hemophilia or Von Willebrand's Disease. *J Arthroplasty* 2015;30:2285.
- [16] Wang SH, Chung CH, Chen YC, Cooper AM, Chien WC, Pan RY. Does hemophilia increase risk of adverse outcomes following total hip and knee arthroplasty? A propensity score-matched analysis of a nationwide, population-based study. *J Arthroplasty* 2019;34:2329.
- [17] Jiang C, Zhao Y, Feng B, et al. Simultaneous bilateral total knee arthroplasty in patients with end-stage hemophilic arthropathy: a mean follow-up of 6 years. *Sci Rep* 2018;8:1608.
- [18] Kotela A, Wilk-Franczuk M, Zbikowski P, Legosz P, Ambroziak P, Kotela I. Revision knee arthroplasty in patients with inherited bleeding disorders: a single-center experience. *Med Sci Monit* 2017;23:129.
- [19] Feng B, Xiao K, Shao J, Fan Y, Weng X. Open repair of intraoperative popliteal artery injury during total knee arthroplasty in a patient with severe hemophilia A: a case report and literature review. *Medicine (Baltimore)* 2017;96:e8791.
- [20] Preijers T, Laros-vanGorkom BA, Mathot RA, Cnossen MH. Pharmacokinetic-guided dosing of factor VIII concentrate in a morbidly obese severe haemophilia A patient undergoing orthopaedic surgery. *BMJ Case Rep* 2019;12.
- [21] Figgie MP, Goldberg VM, Figgie 3rd HE, Heiple KG, Sobel M. Total knee arthroplasty for the treatment of chronic hemophilic arthropathy. *Clin Orthop Relat Res* 1989:98.
- [22] Atilla B, Caglar O, Pekmezci M, Buyukasik Y, Tokgozlu AM, Alpaslan M. Pre-operative flexion contracture determines the functional outcome of haemophilic arthropathy treated with total knee arthroplasty. *Haemophilia* 2012;18:358.
- [23] Chiang CC, Chen PQ, Shen MC, Tsai W. Total knee arthroplasty for severe haemophilic arthropathy: long-term experience in Taiwan. *Haemophilia* 2008;14:828.
- [24] Heeg M, Meyer K, Smid WM, Van Horn JR, Van der Meer J. Total knee and hip arthroplasty in haemophilic patients. *Haemophilia* 1998;4:747.
- [25] Sheth DS, Oldfield D, Ambrose C, Clyburn T. Total knee arthroplasty in hemophilic arthropathy. *J Arthroplasty* 2004;19:56.
- [26] Innocenti M, Civinini R, Carulli C, Villano M, Linari S, Morfini M. A modular total knee arthroplasty in haemophilic arthropathy. *Knee* 2007;14:264.
- [27] Solimeno LP, Mancuso ME, Pasta G, Santagostino E, Perfetto S, Mannucci PM. Factors influencing the long-term outcome of primary total knee replacement in haemophiliacs: a review of 116 procedures at a single institution. *Br J Haematol* 2009;145:227.
- [28] Strauss AC, Schmolders J, Friedrich MJ, et al. Outcome after total knee arthroplasty in haemophilic patients with stiff knees. *Haemophilia* 2015;21:e300.
- [29] Unger AS, Kessler CM, Lewis RJ. Total knee arthroplasty in human immunodeficiency virus-infected hemophiliacs. *J Arthroplasty* 1995;10:448.
- [30] Zingg PO, Fucentese SF, Lutz W, Brand B, Mamisch N, Koch PP. Haemophilic knee arthropathy: long-term outcome after total knee replacement. *Knee Surg Sports Traumatol Arthrosc* 2012;20:2465.
- [31] Huang ZY, Huang Q, Zeng HJ, et al. Tranexamic acid may benefit patients undergoing total hip/knee arthroplasty because of haemophilia. *BMC Musculoskelet Disord* 2019;20:402.
- [32] Peng HM, Wang LC, Zhai JL, et al. Incidence of symptomatic venous thromboembolism in patients with hemophilia undergoing hip and knee joint replacement without chemoprophylaxis: a retrospective study. *Orthop Surg* 2019;11:236.
- [33] Buckner TW, Leavitt AD, Ragni M, et al. Prospective, multicenter study of postoperative deep-vein thrombosis in patients with haemophilia undergoing major orthopaedic surgery. *Thromb Haemost* 2016;116:42.

Appendix

Multiple choice questions

1. Which joints are most commonly affected by osteoarthritis in patients with hemophilia?
 - a. Knees
 - b. Knees and hips
 - c. Ankles and knees
 - d. Hips, elbows, and shoulders
 - e. Knees, ankles, and elbows

Answer E: Based on literature and clinical findings, the knees, ankles, and elbows are the most commonly affected joints in hemophilic arthropathy.

2. For most patients with hemophilia, what is the preferred means of postoperative venous thromboembolic event prophylaxis in patients with hemophilia?
 - a. Low-weight molecular heparin
 - b. Fondaparinux
 - c. IPCDs and nonpharmacologic means of prophylaxis

- d. Apixaban
- e. Dabigatran

Answer C: Given the high risk of intraoperative and postoperative bleeding (and the ensuing risk for infection), non-pharmacologic means of DVT prophylaxis is preferred. The key to this question is the use of “most.” Some patients may be deemed high risk for developing a DVT, and thus, the choice for using chemoprophylaxis must be performed on a case-by-case basis.

3. On sending the synovium from a patient with hemophilia undergoing TKA to pathology, what would be the pigment isolated?
 - a. Lipofuscin
 - b. Hemosiderin
 - c. Melanin
 - d. Bilirubin
 - e. None

Answer B: On pathology analysis, patients with hemophilia will have hemosiderin lining the synovium in the setting of hemarthrosis.