



Long-term follow-up of post hematopoietic stem cell transplantation for Hurler syndrome: Clinical, biochemical, and pathological improvements



Eriko Yasuda^{a,b,1}, William G. Mackenzie^{a,1}, Kristen D. Ruhnke^a, Tsutomu Shimada^a, Robert W. Mason^a, Jozef Zustin^d, Paul L. Martin^e, Mihir M. Thacker^a, Tadao Orii^c, Yoshimichi Sai^b, Shunji Tomatsu^{a,c,1,*}

^a Nemours/Alfred I. duPont Hospital for Children, Wilmington, DE, United States

^b Department of Medical Informatics, Graduate School of Medical Sciences, Kanazawa University, Japan

^c Department of Pediatrics, Gifu University, Gifu, Japan

^d Institute of Pathology, University Medical Center Muenster, Germany

^e Division of Pediatric Blood and Marrow Transplant, Children's Health Center, Duke University Medical Center, United States

ARTICLE INFO

Article history:

Received 24 December 2014

Accepted 24 December 2014

Available online 23 January 2015

Keywords:

Hurler syndrome

HSCT

Skeletal dysplasia

Cognitive function

ADL

ABSTRACT

Mucopolysaccharidosis type I (MPS I; Hurler syndrome) is a lysosomal storage disease caused by a deficiency of the enzyme α -L-iduronidase which affects multiple organs such as central nervous system (CNS), skeletal system, and physical appearance.

Hematopoietic stem cell transplantation (HSCT) is recommended as a primary therapeutic option at an early stage of MPS I with a severe form to ameliorate CNS involvement; however, no description of pathological improvement in skeletal dysplasia has been investigated to date.

We here report a 15-year-old male case with MPS I post-HSCT. This patient received successful HSCT at the age of 2 years and 1 month, followed for over 10 years. His activity of daily living including cognitive performance has been kept normal and the present height and weight are 162 cm and 55 kg. Bone deformity has been still developed, resulting in hemiepiphysiodesis of bilateral medial proximal tibia at 12 years of age and successive arthrodesis of thoraco-lumbar spine at 13 years of age; however, skeletal histopathology from surgical remnants showed substantial improvement in bone lesion with markedly reduced occurrence and cell size of vacuolated cells. After a series of surgical procedures, he became ambulant and independent in daily activity. The levels of GAGs in blood were substantially reduced.

In conclusion, this long-term post-HSCT observation should shed light on a new aspect of therapeutic effect associated with skeletal pathology and GAG levels as a biomarker, indicating that HSCT is a primary choice at an early stage for not only CNS but also skeletal system in combination of appropriate surgical procedures.

© 2014 The Authors. Published by Elsevier Inc. This is an open access article under the CC BY-NC-ND license (<http://creativecommons.org/licenses/by-nc-nd/4.0/>).

1. Introduction

Mucopolysaccharidoses (MPS) are a group of 11 lysosomal storage diseases caused by a deficiency of enzymes that degrade glycosaminoglycans (GAGs), leading to accumulation of GAGs in multiple tissues.

Mucopolysaccharidosis type I (MPS I) has historically been divided into three phenotypes according to the clinical severity; a severe form – Hurler syndrome (MPS IH), an intermediate form – Hurler/Scheie syndrome (MPS IH/IS), and a mild form – Scheie syndrome (MPS IS) [1,2]. MPS I is an autosomal recessive disorder, caused by mutations in the α -L-iduronidase (IDUA) gene. The resultant IDUA

Abbreviations: AB, alcian blue; AB/PAS, alcian blue/periodic acid–Schiff; ADL, activity of daily living; AIDHC, Alfred I. duPont Hospital for Children; BMI, body mass index; BMT, bone marrow transplantation; CDC, the centers for disease control and prevention; CI/VG, colloidal iron/van Gieson; CNS, central nervous system; DS, dermatan sulfate; ECM, extracellular matrix; EM, electron microscopy; ERT, enzyme replacement therapy; GAG, glycosaminoglycan; HE, hematoxylin and eosin; HS, heparan sulfate; HSCT, hematopoietic stem cell transplantation; IDUA, α -L-iduronidase; IRB, institutional review board; IS, internal standard; LC–MS/MS, liquid chromatography–tandem mass spectrometry; LM, light microscopy; MPS, mucopolysaccharidoses; MPS I, mucopolysaccharidosis I; QOL, quality of life; Saf. O/FG, safranin O/fast green.

* Corresponding author at: Skeletal Dysplasia Center, Department of Biomedical Research, Nemours/Alfred I. duPont Hospital for Children, 1600 Rockland Rd., Wilmington, DE 19899-0269, United States.

E-mail addresses: stomatsu@nemours.org, stomatsu@gifu-u.ac.jp (S. Tomatsu).

¹ The first two authors should be regarded as joint first authors.

deficiency generates the progressive accumulation of undegraded GAGs, dermatan sulfate (DS) and heparan sulfate (HS) in lysosome and extracellular matrix (ECM), leading to apoptosis of cells and successive organ dysfunction. IDUA deficiency is characterized by multi-systemic disease, and thus produces a wide range of clinical manifestations. Clinical features in patients with MPS I include dysostosis multiplex, corneal clouding, hepatosplenomegaly, and airway obstruction as well as central nervous system (CNS) involvement.

MPS I as well as other types of MPS result in premature morbidity and mortality. Enzyme replacement therapy (ERT) and hematopoietic stem cell transplantation (HSCT) have been conducted as a primary therapeutic option for MPS I.

Intravenous ERT reverses some aspects of MPS I (e.g., hepatomegaly, splenomegaly and glycosaminoglycanuria) and ameliorates others (e.g., pulmonary function, cardiac disease, arthropathy and exercise tolerance). However, neurologic benefits are thought to be negligible because the blood brain barrier (BBB) blocks enzyme from reaching the CNS. At present, while available for some conditions, exogenous ERT cannot correct cognitive and CNS disease [3,4].

HSCT has been proposed as a treatment for inherited lysosomal storage diseases to correct other cells, which take up enzyme secreted by the bone marrow-derived cells. HSCT has been performed on patients with MPS IH, resulting in clinical improvement of somatic manifestations and cognitive function if it is completed under 2 years of age [5, 6]. Tanaka et al. has addressed that HSCT in patients with MPS II provides a positive effect in cognitive function, when HSCT is conducted before signs of brain atrophy and that HSCT is one of the options in an early stage of the disease [7]. HSCT also shows some benefits in physical activity and growth. Those studies state that allogeneic HSCT could be potential primary care for MPS I, MPS II [7,8], and MPS VII [9].

Thus, introduction of HSCT at an early stage of the disease maintains or ameliorates the neuro-cognitive functions associated with MPS [3].

Accumulated cases support that morbidity, quality of life (QOL), and survival in these patients can be improved by allogeneic HSCT [3]. Especially, HSCT is effective when it is introduced to the patients with MPS IH before 2 years of age with over 80 of IQ score. Early HSCT has been recognized as the standard of care for patients with the severe phenotype of MPS I.

HSCT of patients with MPS I improves QOL with restoration of CNS involvement; however, therapeutic effect remains unknown in bone pathology [10]. Skeletal manifestations observed in MPS IH has been known as dysostosis multiplex [3–6], consisting of abnormally shaped vertebrae and ribs, enlarged skull, spatulate ribs, hypoplastic epiphyses, thickened diaphyses, bullet-shaped metacarpals, hip dysplasia, genu valgum, and spinal cord compression [7].

There are several reports on skeletal and growth improvement post-HSCT on MPS I [11–24]. With successful engraftment, substantial clinical improvements of joint mobility, coarse facial features, and claw hands were reported [21]. Meanwhile, the skeletal manifestations still seem to provide a problem in the QOL in transplanted patients with MPS IH [19]. With age, clinical and radiographic musculoskeletal abnormalities still developed. This is presumably due to the limited penetration of the expressed enzyme into the bone, especially cartilage [14]. However, there has been no report on bone pathology in post-HSCT patients with MPS IH.

DS and HS (primary storage materials) and KS (secondary storage material) have been proposed to be surrogate biomarkers for MPS I [25]: however, to date no report has been described on improvement of skeletal pathology and relevant biomarker.

Until now, we have no clear answer of how extent the enzyme secreted from engrafted stem cells penetrate and fix the bone lesion in correlation with reduction of storage materials (GAGs).

In this report, we first describe the clinical history and improvement in bone histopathology and relevant biomarker as well as CNS and skeletal manifestations after over 10 years post-HSCT in a male patient with MPS IH.

2. Material and methods

2.1. Case report

2.1.1. Initial clinical course

The patient was born at a full term via a C-section because of a failure of the normal delivery to progress. Birth weight was 4224 g (above 90th percentile), and birth length was 54.6 cm (above 95th percentile) of age compared with control subjects from the centers for disease control and prevention (CDC), suggesting that the present case has excessive growth at birth as described previously in patients with MPS I [26]. His mother initially noticed the clinical problems of kyphosis and corneal clouding at 2 months of age, and these clinical features were pointed out at every pediatric physical check-up. The initial findings in this case include bone deformity, failure of thrive, kyphosis, scoliosis, abnormal gait, difficulty of joint movement, umbilical and inguinal hernias, knee problem, corneal clouding, chronic ear infections, short neck, and heart murmur. In MPS IH, developmental delay is often apparent by 12 to 24 months of age [2] while in Hurler–Scheie syndrome, onset of symptoms occurs between ages 3 and 8 years [2].

With the progression of the disease, he was diagnosed as MPS IH at 11 months of age, and underwent cord blood transplantation at Duke University at the age of 2 years and 1 month before CNS involvement became prominent [6]. α -L-Iduronidase enzyme activity in peripheral-blood leukocytes was 0.16 nmol/h/mg of protein (normal level: 30–70 nmol/h/mg of protein). The patient had a cord blood transplant with an A+, male, 5/6 matched cord blood units with mismatch at the B locus. The total mononuclear cell dose was 5.6×10^7 cells/kg. The patient had the full engraftment with grade I GVHD, and the enzyme activity was normalized to 57.8 nmol/h/mg of protein after HSCT.

With age, he underwent surgical procedures of adenoidectomy, tonsillectomy, and multiple myringotomy tube placements. This patient was referred to Alfred I. duPont Hospital for Children (AIDHC) for evaluation of progressive bilateral hand weakness at the age of 5 years. He had locking of both hands since the age of 11 months and had possible trigger fingers and carpal tunnel syndrome, both of which are common in children with MPS I. He did not complain of pain or paresthesias; however, his hands were stiff in the morning.

2.1.2. Orthopedic surgical history

Until the age of 6.5 years, the patient had no significant scoliosis; however, a kyphotic deformity at the thoracolumbar junction secondary to hypoplasia of L2 and retrolisthesis of L2. Diffuse bony changes of dysostosis multiplex were evident (Fig. 1). There was no leg length discrepancy; however, genu valgum was present bilaterally.

At 7 years and 7 months of age, the alignment of cervical spine was anatomic. No instability of the cervical spine was observed. The vertebrae have an oval configuration consistent with MPS I. The odontoid was mildly decreased in height (data not shown). Kyphotic deformity at the thoracolumbar junction was not significantly changed. Mild deformity of the anterior margin of the lumbar vertebral bodies appeared stable without scoliosis. The femoral heads well seated bilaterally in small acetabula.

At the age of 12 years, the cervical spine remained stable, although the vertebrae were mildly flattened and elongated with an oval shape and the odontoid was hypoplastic. The atlantodental interval was stable in neutral, flexion, and extension positions, consistent with no instability. Cervical alignment remained stable in all positions. Until 12 years of age, bilateral genu valgum remained stable, and reduced acetabular coverage was observed bilaterally. The patient had a gibbous deformity with the apex of the kyphotic curve at L2. There was retrolisthesis of L3 on L4 (Fig. 2).

At the age of 12 years and 5 months, the bones of the cervical spine were properly corticated. There was no evidence of atlantoaxial instability with mild dysmorphic changes of the odontoid. Dysmorphic changes of the cervical vertebrae were observed with widening of the disc spaces

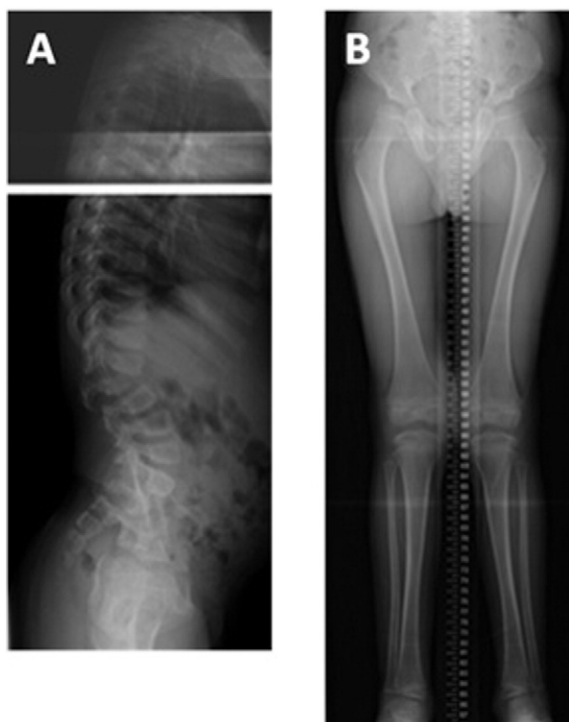

Fig. 1. X-rays at 6.5 years of age. Diffuse bony changes consistent with dysostosis multiplex. A) Kyphotic deformity (gibbus) at the thoracolumbar junction due to hypoplasia of L2. B) Bilateral genu valgum. No leg length discrepancy is noted.

and narrowing of the spinal canal (Fig. 3A). Bilateral genu valgum with the femoral shaft to tibial shaft angle increased with 19° on the right and 16° on the left (Fig. 3B). At the age of 12 years and 6 months, hemiepiphyodesis procedure for bilateral medial proximal tibia was conducted. Post operational changes for epiphyodesis were present at the medial aspect of the bilateral proximal tibia with fixation plate and screws. Bilateral genu valgus appeared stable (Fig. 3C). The femorotibial shaft angle was improved with 17° bilaterally. Diffuse muscular atrophy was noted.

At the age of 13 years, diffuse bony changes were more evident. A severe kyphotic deformity at L2 secondary to hypoplasia of the vertebral body was observed. The spinal canal was narrowed at this level, and there was bulging of the L1–2 and the L2–3 discs. Disc space narrowing was present at T3–4, T4–5, T5–6, T6–7, and T8–9 (Fig. 4A). Thoracolumbar spinal fusion surgery was conducted. Dual fusion rods with pedicle screws extended from T5–L3 with overlying graft material (Fig. 4B). A vertebral spacer was seen between L1 and L2 where the hypoplastic vertebral body was removed. The spine became straight.

2.1.3. Growth

Growth charts for his height, body mass index (BMI), and weight are shown in Fig. 5. From 5 to 14 years of age, the height of the patient was below 50 percentile of the CDC control subjects. His current height at 15 years of age was 162 cm (above 25 percentile of the mean height in the CDC control subjects) (Fig. 5A).

From 5 to 14 years of age, body weight of the patient was similar to that of control subjects (Fig. 5B). The patient did show a decline in his body weight at 13 years and 1 month of age after orthopedic surgical procedures. His current body weight was 55 kg (above 50 percentile).

From 5 to 9 years of age, BMI of the patient was constantly higher than that in average control subjects (Fig. 5C); however, by 14 years of age, the patient treated with orthopedic surgical procedures had lower BMIs than the average control subjects (Fig. 5C).

2.1.4. Activity of daily living (ADL) questionnaire

To address quality of ADL in patients with MPS objectively, we developed the ADL questionnaire with a scoring system. The questionnaire consisted of the four main sections; 1) movement (walking, climbing stairs, hand movement, endurance), 2) movement accompanied by cognitive performance (toileting, changing clothes, bathing, eating), 3) cognitive performance (understanding, conversation, social participation, problem solving), and 4) other 12 symptoms related with MPS (work/study, behavioral problems, sleep, pain, joint motion, respiratory status, infection, vision, hearing, skin, hair, appetite) and provided scores from 0 to 5 (0 = disabled, 5 = healthy). ADL questionnaire was performed at 15 years of age (13 years later post-HSCT).

2.1.5. GAG assay

2.1.5.1. Samples. The plasma samples of MPS I patient with HSCT treated were collected. The plasma samples from the normal controls (11–15 years) were collected at Department of Pediatrics, Shimane University. A written informed consent was obtained from each individual prior to initiation of the study at each institute.

The study was approved by the institutional review boards (IRBs) of Shimane University and Nemours/AIDHC.

2.1.5.2. Standards and enzymes. DS, HS, and KS in specimens were digested to disaccharides by the enzymes of chondroitinase B, heparitinase, and keratanase II, respectively (Seikagaku Corporation, Tokyo, Japan). Chondrosine was used for internal standard (IS), while unsaturated disaccharides, [Δ Di-4S, 2-acetamido-2-deoxy-4-O-(4-deoxy-a-L-threo-hex-4-enopyranosyluronic acid)-4-O-sulfo-D-glucose; Δ DiHS-OS, 2-acetamido-2-deoxy-4-O-(4-deoxy-a-L-threo-hex-4-enopyranosyluronic acid)-D-glucose; Δ DiHS-NS, 2-deoxy-2-sulfamino-4-O-(4-deoxy-a-L-threo-hex-4-enopyranosyluronic acid)-D-glucose], and KS were used for making standard curves [27].

2.1.5.3. Sample preparation. Briefly, after centrifuging the sample, 10 μ L of sample and 90 μ L of 50 mM Tris-HCl Buffer (pH 7.0) were supplied into the wells of AcroPrep™ Advance 96-Well Filter Plates (Ultrafiltration Omega 10 K membrane filters; PALL corporation, NY, USA). The filter plates were placed on the receiver and centrifuged at 2000 g for 15 min to remove free disaccharides. The membrane plates were transferred to a fresh receiver plate. Filters were transferred to a new column plate and 10 μ L of IS (5 μ g/mL chondrosine), 60 μ L of 50 mM Tris-HCl buffer (pH 7.0) and 10 μ L of chondroitinase B (50 mU/10 μ L), heparitinase (200 mU/10 μ L), and keratanase II (200 mU/10 μ L) were added into filter. Each sample was reacted at 37 °C for 3 h for digesting GAGs and centrifuged at 2000 g for 15 min. The receiver plate containing disaccharides was stored at –20 °C until injection to liquid chromatography–tandem mass spectrometry (LC–MS/MS).

2.1.5.4. Liquid chromatography–tandem mass spectrometry (LC–MS/MS)

The chromatographic system consisted of 1260 infinity (Agilent Technologies, Palo Alto, CA) and a Hypercarb column (2.0 mm i.d. 50 mm, 5 μ m, Thermo Electron, Waltham, MA). The 6460 Triple Quad mass spectrometer (Agilent Technologies) was operated in the negative ion detection mode. The procedure was described previously [28]. Samples were removed from the –20 °C and were allowed to thaw at an ambient temperature. Samples were applied to the LC–MS/MS. The files from LC–MS/MS were merged to identify peaks and analyzed to determine the AUC.

2.1.6. Tissue collection

Remnant tissue samples (lumbar bone, cartilage, bone marrow) were collected during surgical procedure at Nemours/AIDHC after the informed consent was obtained.

We analyzed tissue samples by light microscopy (LM).

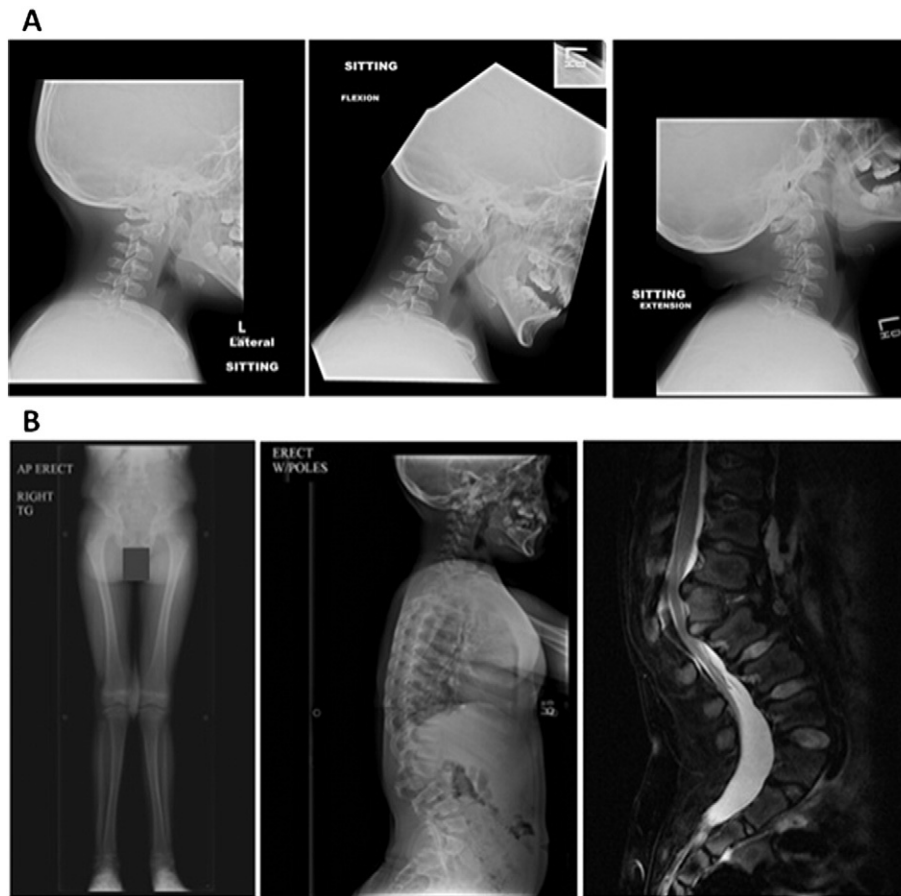


Fig. 2. X-rays at 11.5 years of age. A) Cervical spine: Three views of the cervical spine are taken in lateral projection with neutral (left), flexion (middle), and extension (right) positions. Bone changes are consistent with the patient's clinical history of MPS I. There is subluxation of C2 on C3 with flexion; however, improved alignment with extension is noted. Neither instability of C1–C2 and nor prevertebral soft tissue swelling is apparent. B) Hips, pelvis, and lower extremities: There is invagination of the superior and inferior endplates of several of the lower dorsal vertebrae and the vertebrae appear flattened. Posterior scalloping of the lumbar vertebrae is observed. There is a mild dextroscoliosis of the lumbar spine. Overall appearance of the spine is not significantly changed, compared with the findings at 6 years of age. A composite erect view of the hips, pelvis, and lower extremities demonstrates persistent genu valgum. Medial tilt of the ankle mortise is noted. The lateral aspects of the femoral heads are not fully covered by the acetabular roof. Bony changes of the lumbar spine and flaring of the pelvic ilia are seen.

2.1.6.1. Toluidine blue staining. After decalcification, the formula of fixative is as follows; 0.1 M cacodylic acid formaldehyde (final Ca. 1.5%) and glutaraldehyde (final 1%) (pH 7.2–7.4 adjusted by HCl). Following aldehyde fixation, tissue was washed in 0.1 M sodium cacodylate buffer pH 7.2 containing 5% sucrose, and was post-fixed in 1% osmium tetroxide in cacodylate buffer containing 1% sucrose. Excess osmium was washed out with cacodylate buffer and distilled water, and the tissue was dehydrated with graded ethanol and propylene oxide. Following infiltration with Embed resin, blocks were polymerized at 80 °C, and thin sections were cut with Leica EM UC7 ultramicrotome, collected on copper grids and post-stained with uranyl acetate and lead citrate. Electron micrographs were obtained using a JEOL 1200EX EM. For evaluation of lysosomal storage, toluidine blue-stained 0.5- μ m-thick sections of tissue were assessed by LM.

2.1.6.2. Other staining. Tissues were fixed in 10% neutral buffered formalin for 24–36 h. Bone samples were decalcified in Regular Cal Immuno™ (BBC Biochemicals, Mount Vernon, WA), washed in running water and checked for end-point decalcification. Bone sections were held in 70% ethanol prior to processing. All tissues were auto-processed through graded ethanol at 70%, 80%, 95%, 100%, cleared in Safe-Clear™ (Thermo-Fisher, Kalamazoo, MI), and embedded in paraffin. Sections were cut at 5 μ m and floated onto poly-lysine coated slides and heat immobilized for 1 h at 60 °C. Slides were cooled to room temperature prior to staining. All sections were deparaffinized, hydrated to distilled water and stained with Alcian blue (AB), Alcian blue/periodic acid–

Schiff (AB/PAS), hematoxylin and eosin (HE), colloidal iron/van Gieson (CI/VG), and safranin O/fast green (Saf. O/FG). In AB/PAS, slides were stained manually as follows: tissue sections were placed in a 2.5 pH Alcian Blue solution for 30 min. Excess stain was blotted from the slides and placed in a 1% periodic acid solution for 10 min. Sections were then rinsed in running tap water for 5 min, placed in Schiff's reagent for 10 min, and subsequently washed for 10 min in lukewarm water. HE stains were performed on a Sakura DRS-601 automated stainer using a standard HE protocol. CI/VG stains were stained manually using a modified Mowery's technique [29].

All slides were dehydrated in graded ethanol, cleared in Histo-Clear™ (National Diagnostics, Atlanta, GA) and cover-slipped in Permount.

HE staining portrays the morphology of the cell. In AB staining, acidic mucopolysaccharides (glycosaminoglycans) become blue. In PAS staining, sugars are stained in red. Safranin O distinguishes cartilage from non-cartilage; red = cartilage, blue = connective tissue, ligament, muscle. CI/VG stains acidic mucopolysaccharides in blue, while van Gieson stains collagen in pink or deep red.

3. Results

3.1. ADL score

At 15 years of age, the patient scored 59 out of 60 in the first three ADL sections at post-HSCT (the age-matched healthy control group:

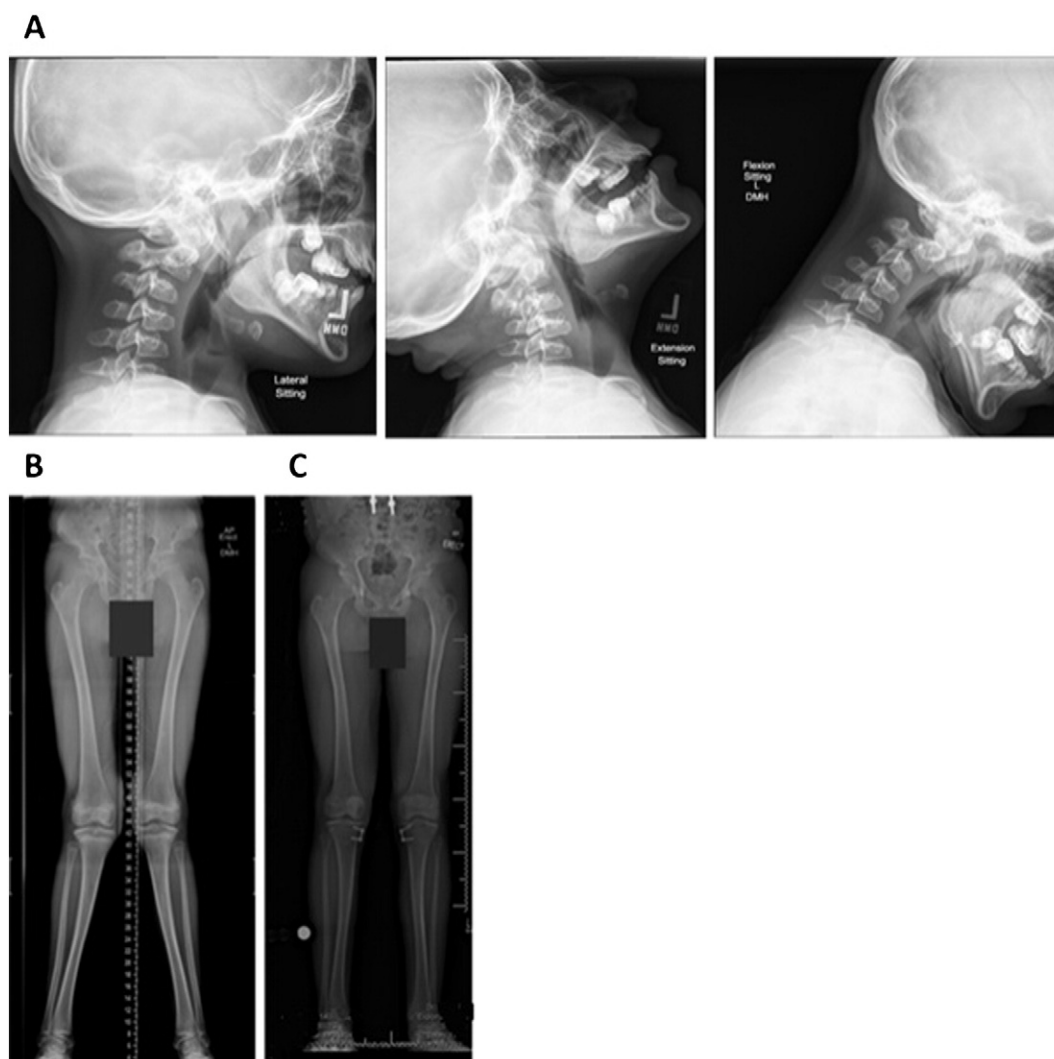


Fig. 3. X-rays at 12.4 years of age. A) Cervical spine: Dysmorphic changes of the cervical vertebra with widening of disc spaces and narrowing of the spinal canal consistent with underlying MPS I. No evidence of cervical spine instability is seen. B) Lower extremities: Pre-operation – The bony mineralization is within normal limits. Redemonstrated is the bilateral genu valgum, right greater than left. Both femoral heads are well covered by their respective acetabula and better covered than they had been on the prior examination. There is no acute fracture, dislocation or joint abnormality. C) Post-operation – Postoperative changes for epiphysiodesis in the medial aspect of the bilateral proximal tibia remain in place. Bilateral hips are well located. Bilateral genu valgus is still noted. No focal abnormality is seen. Joint spaces are maintained. Soft tissues are unremarkable. Stable mild bilateral genu valgus with generalized osteopenic is observed.

60, $n = 10$), suggesting that no difference was observed in ADL between the patient and the age-matched controls. The patient scored 50 in MPS symptoms at post-HSCT (the age-matched healthy control group: 56, $n = 10$). There were lower scores in pain, joint mobility, vision, and appetite. The patient had migraine occasionally although no interference with daily life. Slight rigidity of joints was recognizable. The most concern was reduced visual power with glaucoma and thick corneal clouding and the patient could see the bigger letter. He had an unbalanced diet.

The normal condition was observed in activity at work/study, sleep, respiratory status, hair, skin, and infection, indicating that HSCT provides a better quality of daily life for a long-term follow-up.

3.2. GAG assay

The specimens (plasma) were obtained at 13.1 years old. Untreated MPS I patients had a significant elevation of Δ DiHS-OS, Δ DiHS-NS, and Δ Di-4S (DS), compared with the normal controls [30]. Δ DiHS-OS of untreated MPS I patients is 7.62 times higher than normal controls. Δ DiHS-NS of untreated MPS I patients is 10.8 times higher than normal

controls. Δ Di-4S (DS) of untreated MPS I patients is 5.64 times higher than normal controls [30,31].

The levels of DS and HS in the indexed patient treated with HSCT were within normal control levels (Table 1), matched with the findings of ADL score including normal cognitive performance. KS levels remained still higher, reflecting the skeletal problems.

3.3. Pathology

3.3.1. Light microscopy

3.3.1.1. Cartilage and ECM

3.3.1.1.1. Spinous process lumbar spine. TB staining: The cell size of chondrocytes appeared nearly normal with regular round nucleus. Chondrocytes (fibrocartilage) appeared almost normal but collagen fibers in ECM appeared disorganized (Fig. 7). Fig. 7A shows that the fibrocartilaginous tissue in spinous process of lumbar spine displayed slightly enlarged chondrocyte lacunae; however, the hyaline matrix matured appropriately. Throughout the analyzed fibrocartilaginous tissue, neither pannus tissue nor macrophage infiltration was apparent.

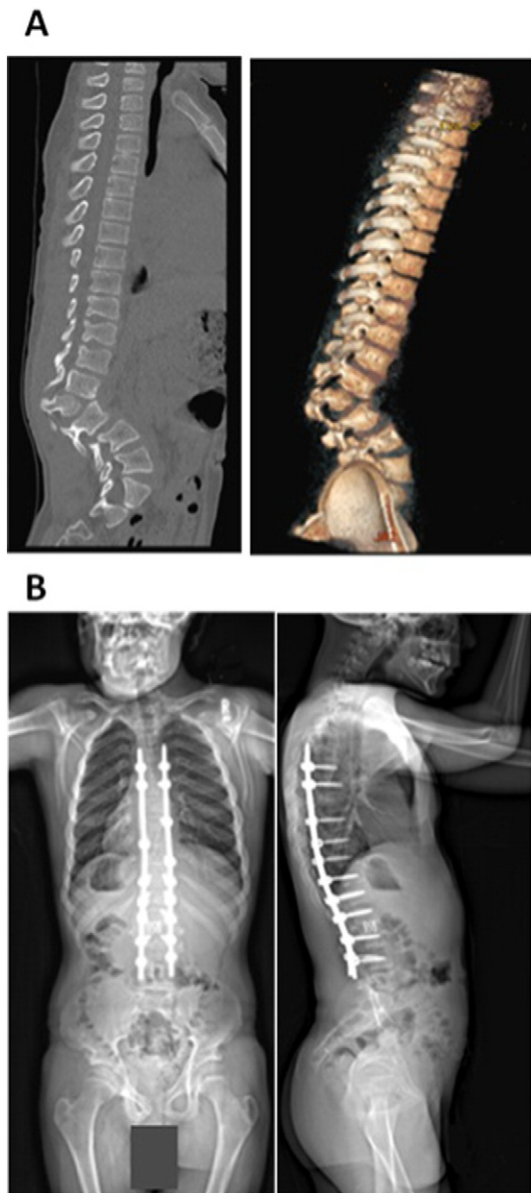


Fig. 4. CT for spine and 3D reconstruction at 13 years of age (pre-operation) and X-rays for spine (front and side views) at 14 years of age (post-operation). A) Severe kyphosis of the upper lumbar spine is seen. There is anterolisthesis above and posterior listhesis at the level of the L2 hemivertebra. There are bulging discs at multiple levels with a new rightward disc protrusion at T9–10. Bulging discs in the lumbar region contribute to neuroforaminal stenosis at multiple levels. Extruded disc material is noted anteriorly at the L2 level and also at L4–5 and L3–4. Compression of the nerve roots of the cauda equina due to narrowing of the thecal sac is observed. Mild disc space narrowing at multi-levels in the thoracic spine is observed. B) Spinal rods and disc spacer device appear stable. The iliac crests are at approximately equal heights. The soft tissues appear normal. Rods and pedicle screws appear to be intact. Stable appearance of the thoracolumbar spine is seen following posterior spinal fusion.

Other staining: The chondrocytes in spinous process appear normal in number, size, and morphology. Collagen fibers in ECM are partially disorganized. Anti-KS antibody stains fibrocartilage and ECM (Fig. 6).

3.3.1.1.2. Facet joint. Other staining: The cell size of chondrocytes was nearly normal with normal nuclei. Column structure of growth cartilage was partially disorganized (Fig. 8).

3.3.1.1.3. Intervertebral disc L2. TB staining: The MPS IH patient chondrocyte in intervertebral disc size is kept normal and appeared normal morphologically, and chondrocytes did not display vacuoles compared with control slides in knee joint at 8 years of age (Fig. 9).

3.3.1.1.4. Bone and bone marrow. TB staining: A bone trabecula of lumbar vertebra with normal microarchitecture of bone matrix is observed and regular lamellar structure of the mineralized ECM is also present. Portions of the trabecular surface are covered by new formed osteoid and seam of active osteoblasts. No pathological bone resorption is observed. Altogether, the bone tissue displayed normal bone remodeling. There were no pathological accumulations of macrophages within the bone marrow (Fig. 10A). Few small vacuoles were present within the active osteoblasts and pre-osteocytes embedded in osteoid. The osteocytes, however, showed no vacuolated cytoplasm (Fig. 10B). Similarly, the bone tissue from facet joint showed regular structure and normal number of osteocytes (Fig. 10C). The osteocytes within the osteocyte lacunae were viable and showed no pathologic changes (Fig. 10C).

Overall, no evidence of abnormal storage material in bone marrow, cartilage, and bone was seen. Osteocytes, chondrocytes, and macrophages in bone marrow were morphologically intact.

4. Discussion

As far as our knowledge, this is the first report to describe the bone pathology post-HSCT of the patient with MPS IH. The patient has received HSCT at 2 years of age and has nearly normal growth and joint mobility with an active ADL. The 15-year-old male patient with MPS IH, who had HSCT at 2 years and 1 month, underwent serial of surgical procedures of adenoidectomy, tonsillectomy, multiple myringotomy tube placements, hemiepiphysiodesis for bilateral medial proximal tibia, and thoraco-lumbar spinal fusion. We have demonstrated 1) that HSCT is effective in amelioration of neuro-cognitive and functional ability of patient, 2) that growth is larger than the untreated patients with MPS I, compatible with the age-matched controls, 3) that skeletal dysplasia remains still unresolved and is required for surgical procedures, 4) that skeletal pathology from the remnant tissues displays nearly normal in chondrocytes and ECM, and 5) that the levels of specific GAGs in blood are markedly reduced and correlated with improvements of specific clinical improvements.

His ADL including cognitive performance and movement is kept normal at 15 years of age. His cognitive function is far better, compared to untreated MPS IH patients who have not undergone HSCT. Generally, developmental delay is evident in MPS IH by the end of the first year, and patients usually stop developing between the ages of 2 and 4 years. The patient here treated by HSCT can speak, read, and write at an age-appropriate level (8th grade), and is mainstreamed at school. Many children with MPS I develop a short body trunk and a maximum stature of less than 120 cm [26,31]. Additional effectiveness is demonstrated physically; the patient is 162 cm tall and weighs 55.0 kg. This finding indicates that the growth post-HSCT is far bigger than untreated patients with MPS I and that the height is just below 25th percentile of age-matched CDC controls. Overall, HSCT at early stage gives an impact to ADL and the growth.

Patients with MPS IH often die by 10 years of age because of respiratory complications or cardiomyopathy if untreated [2]. This patient at 15 years of age is considered healthy without any life-threatening issue and can live independently without any problem of daily activities in walking, toileting, changing clothes, shopping, and taking a bath. The most concern in treatment of patients with MPS IH is to ameliorate developmental delay and skeletal abnormalities to provide a maximum QOL. The care of this patient included several surgical interventions as well as umbilical cord blood transplantation. The present case and the published cases treated with HSCT demonstrate that HSCT is effective in restoration of neuro-cognitive ability and reduced dystosis multiplex, proving usefulness of HSCT in MPS I.

However, he needs to have several surgical procedures with progression of skeletal abnormalities as described previously in other MPS IH patients [32,33]. Detailed pathological analyses showed that there is no pathological accumulation in chondrocytes and that bone

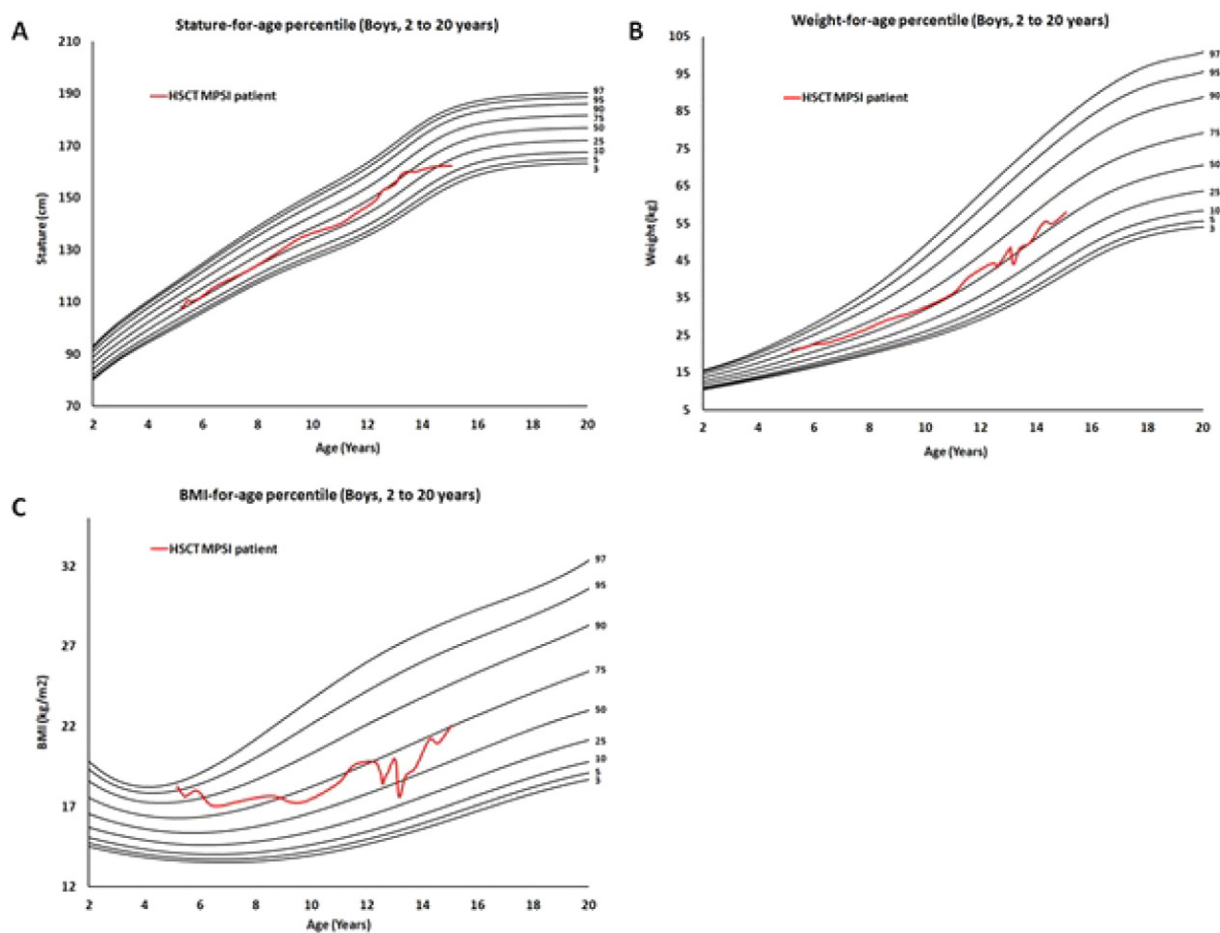


Fig. 5. Growth chart of HSCT patient with MPS I. A) Height of HSCT MPS IH patient vs. normal age-matched control. B) Weight of HSCT MPS IH patient vs. normal age-matched control. C) BMI of HSCT MPS IH patient vs. normal age-matched control. Red lines represent HSCT-treated patient. Growth charts demonstrate normalized growth patterns for height, weight, and BMI.

and cartilage structure display somewhat abnormal fibers in ECM. These findings suggest that HSCT attenuates the skeletal manifestations but does not provide complete remission.

We speculate the following mechanisms of the effect of HSCT on the affected bone and cartilage. 1. Cord blood includes not only hematopoietic stem cell but mesenchymal stem cells even though the population of mesenchymal stem cells is low. These mesenchymal cells differentiate into healthy chondrocytes which will replace affected chondrocytes with vacuoles to some degree. 2. Osteoclasts and macrophages derived from donor hematopoietic stem cells may phagocytose and digest unrequired storage materials at the extracellular matrix. 3. Lysosomal enzymes can be excreted by healthy cells such as osteoclasts and macrophages and taken up by deficient chondrocytes. Otherwise, the combination of those factors will contribute to clearance of storage materials in bone and cartilage.

It is noteworthy that DS and HS levels are normalized after post-HSCT in this patient while KS level remains high. Elevation of KS level in blood specimens is deemed as the hallmark of MPS IV since the deficient enzyme directly engage in catabolism of KS; however, MPS disorders except for MPS IV are also associated with elevated blood KS

levels as well as the GAGs originating from the primary enzyme defect [34,35]. The majority of KS is synthesized in cartilage, and the metabolized KS is secreted in the blood. MPS IV is caused by deficiency of the enzyme directly involved in KS degradation pathway, leading to accumulation of undegraded KS mainly in cartilage. The mechanism how the KS is elevated in other types of MPS remains puzzled since the present theory on the pathway of KS catabolism cannot account for this event. One of the hypotheses is that the elevation of KS is a secondary consequence due to the skeletal dysplasia. Excessive KS secretion into the circulation derives from damaged cartilage due to accumulation of other GAGs and its subsequent inflammation in joints. This hypothesis is supported by the fact that KS levels in patients with MPS I are elevated, compared with that in MPS III with less skeletal dysplasia [34,35]. MPS I mouse model with the severe skeletal abnormality elevates blood KS level more, compared with other MPS mice [36]. Thus, it is useful to investigate the KS levels in the blood as a biomarker of MPS I with skeletal dysplasia [37–41]. KS level in blood also correlates with the improvement of skeletal manifestations [36].

Accumulated data in patients with MPS IH indicate that HSCT does show improvement in CNS involvement if conducted at an early stage,

Table 1
GAG concentration in plasma in an MPS I patient treated by HSCT and age-matched normal controls.

Plasma sample	n	Age (years)	Di-4S (ng/mL)	DiHS-0S (ng/mL)	DiHS-NS (ng/mL)	Mono-sulfated	Di-sulfated KS (μg/mL)
Patient	1	13.1	11.1	67	10.6	5.98	3.46
Age-matched normal controls	9	13.1 ± 1.55	11.4 ± 8.96	29.4 ± 10.4	7.22 ± 2.16	2.14 ± 0.66	1.10 ± 0.35

Note: mono-sulfated KS, Gal β 1 → 4GlcNAc(6S), di-sulfated KS, Gal(6S) β 1 → 4GlcNAc(6S).

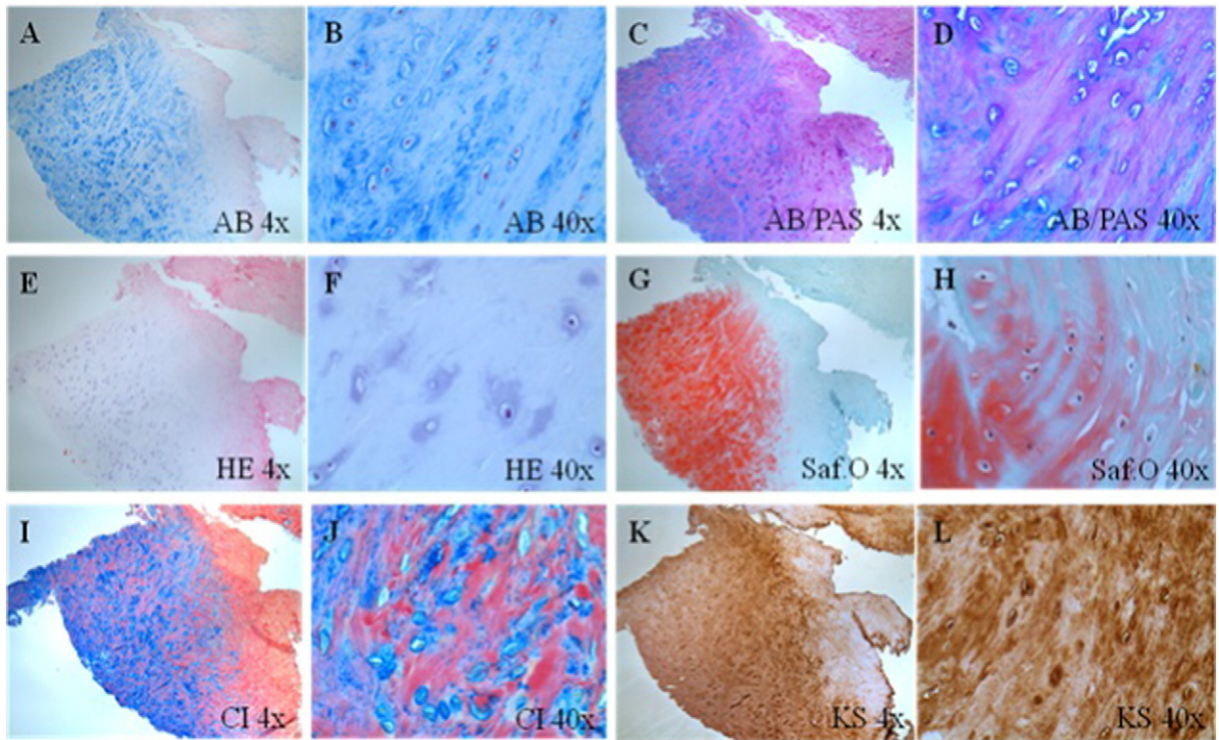


Fig. 6. Histopathologic findings in fibrocartilage and ECM of spinous process lumbar spine by different staining methods of HSCT MPS IH patient. A), B) AB staining: Acidic mucopolysaccharides are stained in blue and nucleus is in red. C), D) AB/PAS staining: PAS stains glycogen and neutral viscous liquid polysaccharides in red to purple. E), F) HE staining: Eosin stains basic structures and the cytoplasm in red or pink. Hematoxylin is used to stain acidic structures a purplish blue. The nucleus is stained purple. G), H) Saf. O/FG staining: Saf. O stains GAGs in cartilage in orange while fast green stains the background (non-collagen). I), J) CI/VG staining: CI stains acidic mucopolysaccharides in blue and VG stains fiber in red. K), L) Anti-KS antibody immunostaining: Anti-KS antibody stains chondrocytes and their ECM in brown. (A, C, E, G, I and K: $\times 4$, B, D, F, H, J and L: $\times 40$).

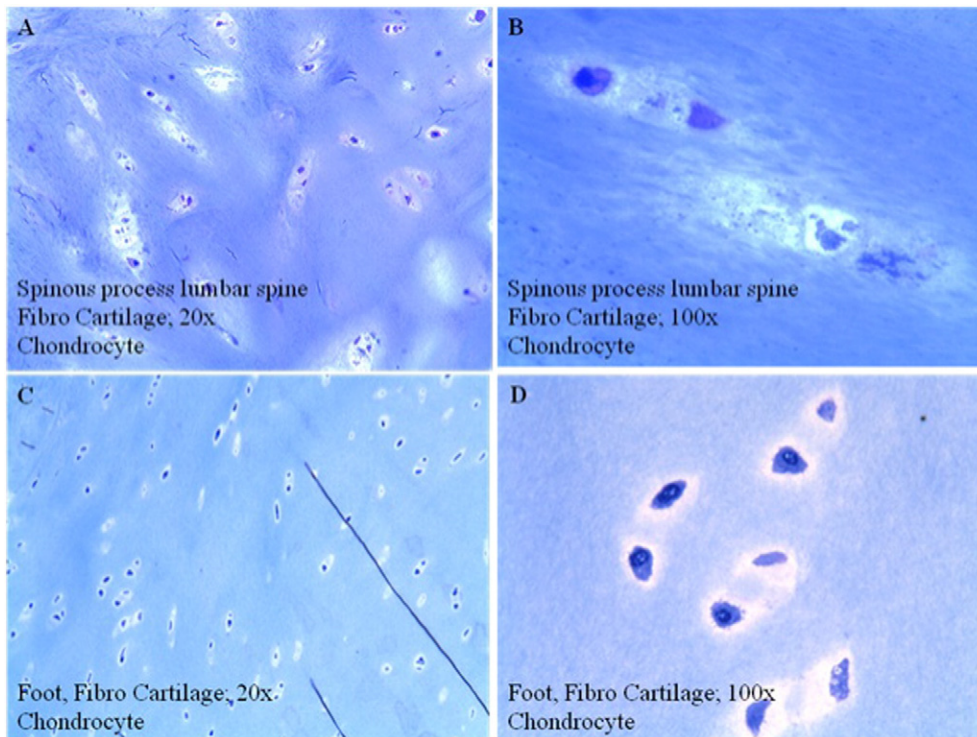


Fig. 7. Histopathologic findings in fibro-cartilaginous tissue of spinous process lumbar spine of HSCT MPS IH patient. A and B show an MPS IH patient treated by HSCT (spinous process lumbar spine) while C and D show an 8-year-old male control (knee joint). A) MPS IH patient treated by HSCT (spinous process lumbar spine); $\times 20$. B) MPS IH patient treated by HSCT (spinous process lumbar spine); $\times 100$. C) 8-year-old male control (knee joint); $\times 20$, hyaline cartilage of a control tissue. D) 8-year-old male control (knee joint); $\times 100$, detail of chondrocytes in control tissue. (A–D: embedding in methyl-methacrylate; staining: toluidine blue).

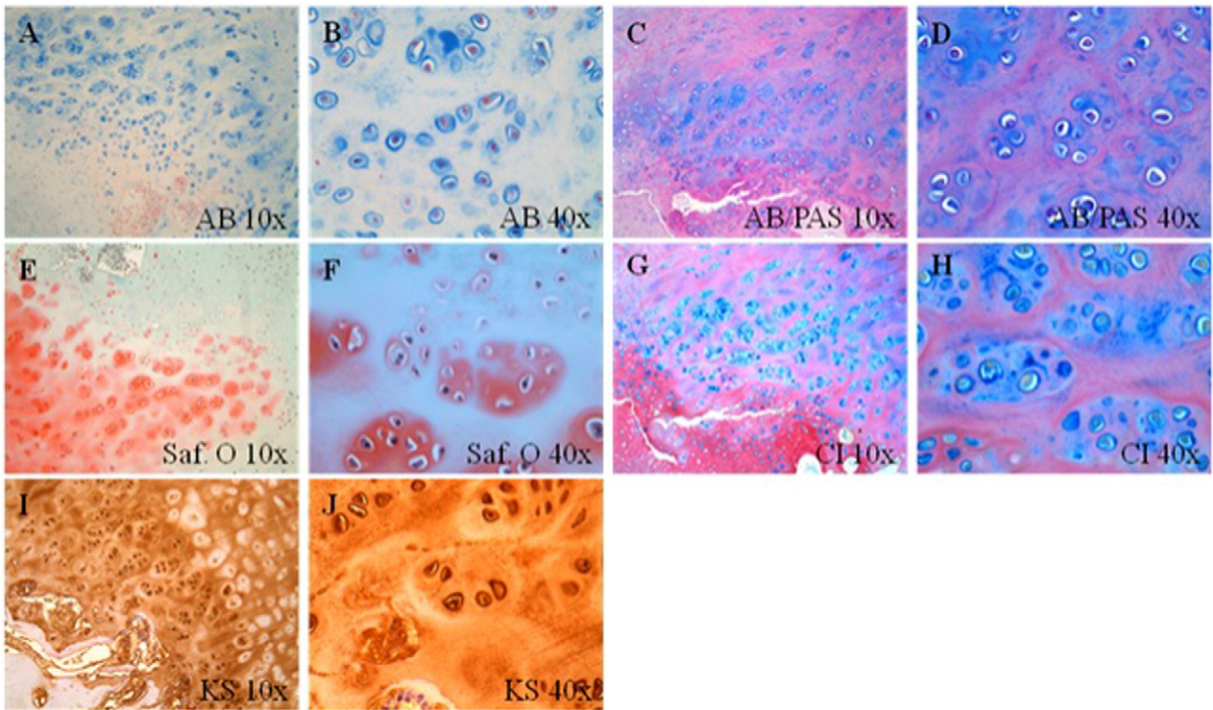


Fig. 8. Histopathologic findings in growth cartilage of facet joint by different staining methods of HSCT MPS IH patient. A), B) AB staining: Acidic mucopolysaccharides are stained in blue and nucleus is in red. C), D) AB/PAS staining: PAS stains glycogen and neutral viscous liquid polysaccharides in red to purple. E), F) Saf. O/Fast Green staining: Saf. O stains GAGs in cartilage in orange while fast green stains the background (non-collagen). G), H) CI/VG staining: CI stains acidic mucopolysaccharides in blue and VG stains fiber in red. I), J) Anti-KS antibody immunostaining: Anti-KS antibody stains chondrocytes and their ECM in brown. (A, C, E, G and I: $\times 4$, B, D, F, H and J: $\times 40$).

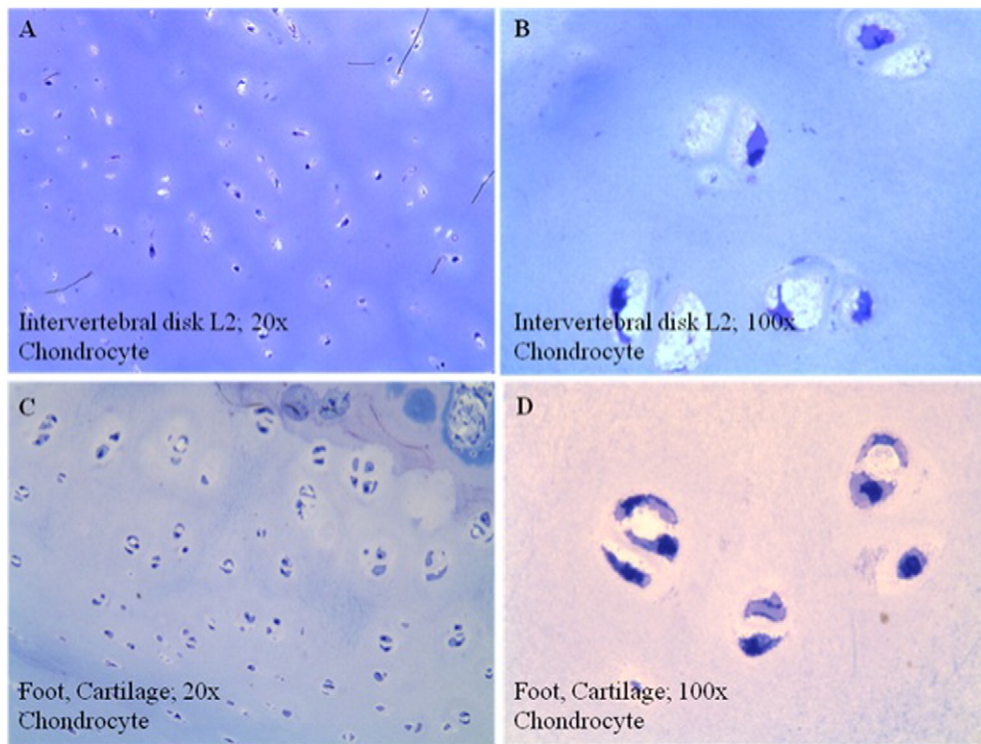


Fig. 9. Histopathologic findings in intervertebral disc of HSCT MPS IH patient. A and B show an MPS IH patient treated by HSCT (intervertebral disc) while C and D show an 8-year-old male control (knee joint). A) MPS IH patient treated by HSCT (intervertebral disc L2): $\times 20$. B) MPS IH patient treated by HSCT (intervertebral disc L2): $\times 100$. C) 8-year-old male control (knee joint): $\times 20$, hyaline cartilage of a control tissue. D) 8-year-old male control (knee joint): $\times 100$, detail of chondrocytes in control tissue. (A–D: embedding in methyl-methacrylate; staining: toluidine blue; original magnification).

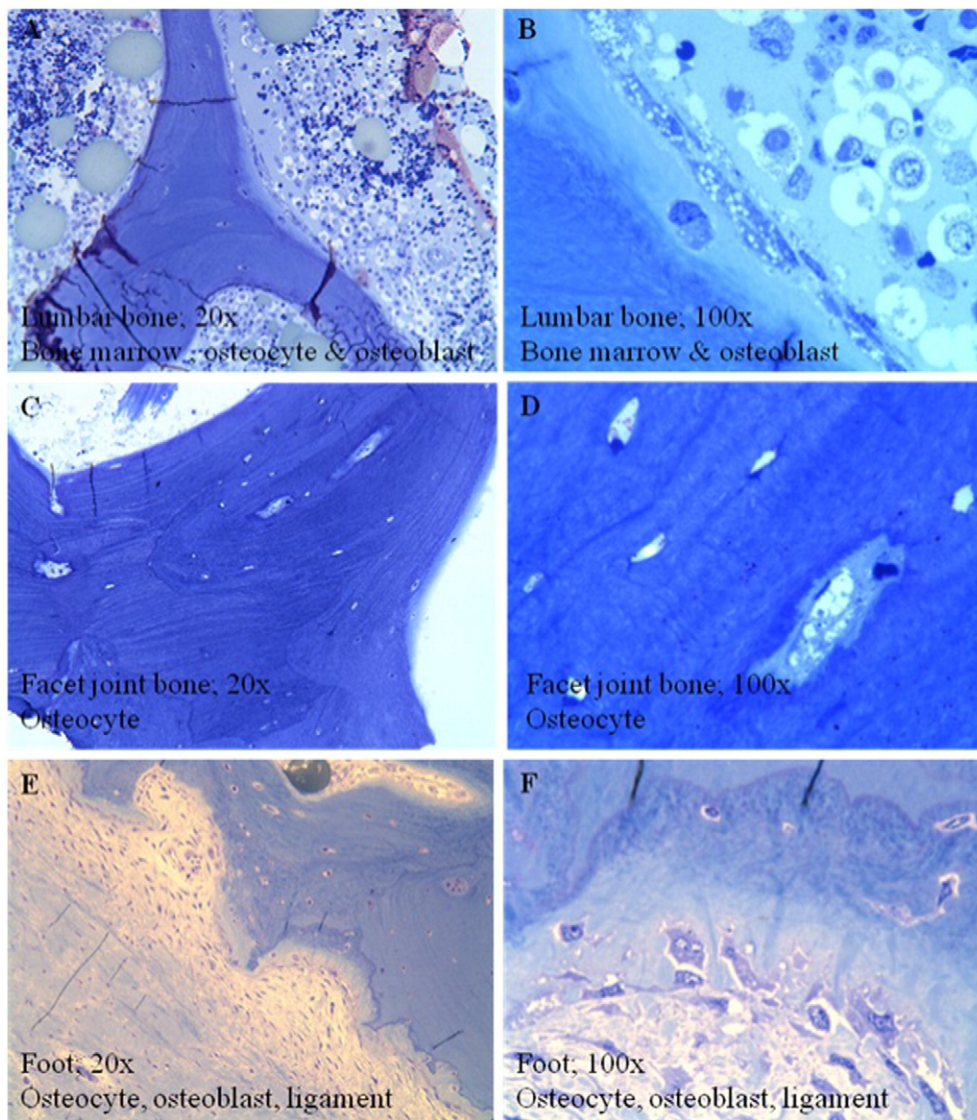


Fig. 10. Histopathologic findings in bone tissue of HSCT MPS IH patient. A and B show an MPS IH patient treated by HSCT (lumbar bone) and C and D show an MPS IH patient treated by HSCT (facet joint bone) while E and F show an 8-year-old male control (knee joint). A) MPS IH patient treated by HSCT (lumbar bone): $\times 20$. B) MPS IH patient treated by HSCT (lumbar bone): $\times 100$. C) MPS IH patient treated by HSCT (facet joint bone): $\times 20$. D) MPS IH patient treated by HSCT (facet joint bone): $\times 100$. E) 8-year-old male control (knee joint): $\times 20$, cartilage of a control tissue. F) 8-year-old male control (knee joint): $\times 100$, detail of chondrocytes in control tissue. (A–F: embedding in methyl-methacrylate; staining: toluidine blue; original magnification: A, C and D: $\times 20$, B, D and F: $\times 100$).

while conventional ERT does not provide effectiveness in CNS [42]. Therefore, HSCT should be considered as the first treatment option for MPS IH. Long-term follow-up studies on MPS IH patients treated with HSCT allowed the therapeutic efficacy of HSCT to be assessed. Results presented in this study show that HSCT has a positive effect on both CNS and growth development with reduction of GAG levels and normal ADL. The clinical consequence of HSCT relies on 1) the age and clinical condition of the patient at the time of transplantation, 2) the severity of clinical phenotype, 3) the type of donor, and 4) the course of preparative regimen. Especially, early introduction of HSCT provides more impact on therapeutic efficacy for CNS and skeletal involvement.

A potential merit of HSCT for treating MPS I is that marrow-derived donor macrophages can provide a continuous secreting source of enzyme and that these cells can gain access to sites throughout the body where GAGs are stored. Consequently, advantages of HSCT over ERT include; 1) one time permanent treatment if engraftment is successful, 2) active enzyme secreted from bone marrow can access many tissues including brain, bone, and heart valves, 3) continuous expression of the enzyme during the life-time of the patient, 4) improvement of

cognitive function with early treatment, and 5) cost-effective (less than cost of ERT for one year). Disadvantages of HSCT include 1) a chance of mortality during treatment (although the risk has been diminished substantially), 2) age limitation for a severe phenotype of patients with CNS involvement, 3) limited by patient health condition, 4) limited by expertise at medical facility, and 5) requires a rigorous regimen in hospital before and after HSCT for 2–3 months. In early studies, the mortality rate of HSCT was approximately 20–25% [43,44]. With advanced techniques and earlier introduction of HSCT, the survival rate after treatment of MPS improved to 88.5% during the period from 1990 to 2003 [45]. All twenty patients with MPS treated by HSCT since 2000 have survived (personal communication with Dr. Yabe, Tokai University). Thus, HSCT is much safer than before, although survival rates could still depend upon the institution and expertise of their staff.

One of the reasons why the mortality rate of HSCT was high during initial attempts in 1980–1990 is that patients who underwent HSCT were already at an advanced or even a terminal stage of disease progression. It will not always be suitable for patients with advanced stage disease to complete the rigorous regimen of HSCT.

However, with the advanced technology and awareness of the disease, newborn screening is being conducted. Such newborn screening programs for patients with MPS IH may offer an opportunity to consider HSCT even in the first months of life before signs and symptoms appear [46–48].

The improvement of skeletal phenotype by HSCT in the present and reported cases was incomplete likely because bone abnormalities are irreversible at the time of the transplant (median age at BMT, 16 months old). Meanwhile, during prenatal and perinatal life, children with MPS IH appear nearly normal at the skeletal development [22,23]. Therefore, one can speculate that the first months of life is the best window of opportunity for preventing bone deformities in patients with MPS IH. According to this perspective, a long-term clinical outcome of patients with MPS IH depends upon whether HSCT prevents the progression of the disorder and provides maximal benefit when performed early in life [24].

In conclusion, we have shown that HSCT at an early stage of MPS IH provides a marked positive impact on clinical CNS and skeletal manifestations, bone pathology, and GAG levels, resulting in preservation of normal ADL. Thus, HSCT should be a primary standard care of MPS IH at an early stage.

Compliance with ethics

The study protocol was in accordance with the standards of the Ethics Committee.

Conflicts of interest

All the authors have contributed to this “Original Article” and have no conflict of interest with any other party. Eriko Yasuda, Shunji Tomatsu, Kristen Ruhnke, Tsutomu Shimada, Jozef Zustin, Paul Martin, Robert Mason, William Mackenzie, and Tadao Orii declare that they have no conflict of interests.

Informed consent

Informed consent included in this article for human subject was taken at Nemours/Alfred I. duPont Hospital for Children.

Animal rights

Not applicable.

Author contributions

Eriko Yasuda: She has contributed to the concept of the project, planning, analysis of data, and reporting of the work described in the article.

William G. Mackenzie: He has contributed to the concept of the project, planning and conduction of surgical procedures, follow up of the patient, analysis of data, and reporting of the work described in the article.

Kristen Ruhnke: She has contributed to collecting samples, data analysis, and reporting of the work described in the article.

Tsutomu Shimada: He has contributed to the concept of the project, planning, performance of experiments (LC–MS/MS), data analysis, and reporting of the work described in the article.

Robert W. Mason: He has contributed to the planning, performance of LC–MS/MS, data analysis, and reporting of the work described in the article.

Jozef Zustin: He has contributed to the planning, interpretation of pathology, data analysis, and reporting of the work described in the article.

Paul Martin: He has contributed to execution of HSCT on the patient, data collection of HSCT, and reporting of the work described in the article.

Mihir Thacker: He has contributed to collecting samples, data analysis, and reporting of the work described in the article.

Tadao Orii: He has contributed to collecting samples, data analysis, and reporting of the work described in the article.

Yoshimichi Sai: He has contributed to the concept of the project, planning, analysis of data, and reporting of the work described in the article. He organized and communicated the entire team for this project with Dr. Tomatsu.

Shunji Tomatsu: He is a Principal Investigator and is responsible for the entire project. He has contributed to the concept of the project, planning, analysis of data, and reporting of the work described in the article. He organized and communicated the entire team for this project.

Acknowledgments

This work was supported by grants from the Austrian MPS Society and International Morquio Organization (Carol Ann Foundation). R.W.M. and S.T. were supported by an Institutional Development Award (IDeA) from the National Institute of General Medical Sciences of NIH under grant number P20GM103464. The content of the article has not been influenced by the sponsors. Editorial assistance to the manuscript was provided by Michelle Stofa at Nemours/Alfred I. duPont Hospital for Children.

References

- [1] L.A. Clarke, The mucopolysaccharidosis: a success of molecular medicine, *Expert. Rev. Mol. Med.* 10 (2008) 1462–3994.
- [2] E. Neufeld, J. Muenzer, The mucopolysaccharidoses, in: 8th edn, C. Scriver, A. Beaudet, W.S. Sly, D. Valle (Eds.), *The Metabolic and Molecular Bases of Inherited Disease*, vol. 3, McGraw-Hill, New York, 2001, pp. 3421–3452.
- [3] V.K. Prasad, J. Kurtzberg, Cord blood and bone marrow transplantation in inherited metabolic diseases: scientific basis, current status and future directions, *Br. J. Haematol.* 148 (2010) 356–372.
- [4] L. Ou, T. Herzog, B.L. Koniar, R. Gunther, C.B. Whitley, High-dose enzyme replacement therapy in murine Hurler syndrome, *Mol. Genet. Metab.* 111 (2014) 116–122.
- [5] C. Peters, E.G. Shapiro, J. Anderson, P.J. Henslee-Downey, M.R. Klemperer, M.J. Cowan, et al., Hurler syndrome: II. Outcome of HLA-genotypically identical sibling and HLA-haploidentical related donor bone marrow transplantation in fifty-four children. The Storage Disease Collaborative Study Group, *Blood* 91 (1998) 2601–2608.
- [6] S.L. Staba, M.L. Escolar, M. Poe, Y. Kim, P.L. Martin, P. Szabolcs, et al., Cord-blood transplants from unrelated donors in patients with Hurler's syndrome, *N. Engl. J. Med.* 350 (2004) 1960–1969.
- [7] A. Tanaka, T. Okuyama, Y. Suzuki, N. Sakai, H. Takakura, T. Sawada, et al., Long-term efficacy of hematopoietic stem cell transplantation on brain involvement in patients with mucopolysaccharidosis type II: a nationwide survey in Japan, *Mol. Genet. Metab.* 107 (2012) 513–520.
- [8] P. Patel, Y. Suzuki, M. Maeda, E. Yasuda, T. Shimada, K.E. Orii, et al., Growth charts for patients with Hunter syndrome, *Mol. Genet. Metab.* 1 (2014) 5–18.
- [9] Y. Yamada, K. Kato, K. Sukegawa, S. Tomatsu, S. Fukuda, S. Emura, et al., Treatment of MPS VII (Sly disease) by allogeneic BMT in a female with homozygous A619V mutation, *Bone Marrow Transplant.* 21 (1998) 629–634.
- [10] A. Vellodi, E. Young, A. Cooper, V. Lidchi, B. Winchester, J.E. Wraith, Long-term follow-up following bone marrow transplantation for Hunter disease, *J. Inherit. Metab. Dis.* 22 (1999) 638–648.
- [11] M.H. van der Linden, M.C. Kruyt, R.J. Sakkars, T.J. de Koning, F.C. Oner, R.M. Castelein, Orthopaedic management of Hurler's disease after hematopoietic stem cell transplantation: a systematic review, *J. Inherit. Metab. Dis.* 34 (2011) 657–669.
- [12] E. Miebach, H. Church, A. Cooper, J. Mercer, K. Tylee, R.F. Wynn, et al., The craniocervical junction following successful hematopoietic stem cell transplantation for mucopolysaccharidosis type I H (Hurler syndrome), *J. Inherit. Metab. Dis.* 34 (2011) 755–761.
- [13] C. Taylor, P. Brady, A. O'Meara, D. Moore, F. Dowling, E. Fogarty, Mobility in Hurler syndrome, *J. Pediatr. Orthop.* 28 (2) (2008) 163–168.
- [14] R.E. Field, J.A. Buchanan, M.G. Copplemans, P.M. Aichroth, Bone-marrow transplantation in Hurler's syndrome. Effect on skeletal development, *J. Bone Joint Surg. Br.* 76 (6) (1994) 975–981.
- [15] J.S. Weisstein, E. Delgado, L.S. Steinbach, K. Hart, S. Packman, Musculoskeletal manifestations of Hurler syndrome: long-term follow-up after bone marrow transplantation, *J. Pediatr. Orthop.* 24 (1) (2004) 97–101.
- [16] G.M. Pastores, P.A. Meere, Musculoskeletal complications associated with lysosomal storage disorders: Gaucher disease and Hurler–Scheie syndrome (mucopolysaccharidosis type I), *Curr. Opin. Rheumatol.* 17 (1) (2005) 70–78.

- [17] K.K. White, Orthopaedic aspects of mucopolysaccharidoses, *Rheumatology (Oxford)* 50 (5) (2011) 26–33.
- [18] M. Aldenhoven, R.J. Sakkera, J. Boelens, T.J. de Koning, N.M. Wulffraat, Musculoskeletal manifestations of lysosomal storage disorders, *Ann. Rheum. Dis.* 68 (11) (2009) 1659–1665.
- [19] M. Aldenhoven, J.J. Boelens, T.J. de Koning, The clinical outcome of Hurler syndrome after stem cell transplantation, *Biol. Blood Marrow Transplant.* 14 (5) (2008) 485–498.
- [20] C. Peters, C.G. Steward, Hematopoietic cell transplantation for inherited metabolic diseases: an overview of outcomes and practice guidelines, *Bone Marrow Transplant.* 31 (4) (2003) 229–239.
- [21] A.M. Rovelli, The controversial and changing role of haematopoietic cell transplantation for lysosomal storage disorders: an update, *Bone Marrow Transplant.* 41 (2) (2008) 87–89.
- [22] M.A. Cleary, J.E. Wraith, The presenting features of mucopolysaccharidosis type IH (Hurler syndrome), *Acta Paediatr.* 84 (3) (1995) 337–339.
- [23] A. Chakrapani, M.A. Cleary, J.E. Wraith, Detection of inborn errors of metabolism in the newborn, *Arch. Dis. Child. Fetal Neonatal Ed.* 84 (3) (2001) 205–210.
- [24] J.J. Boelens, R.F. Wynn, A. O'Meara, P. Veys, Y. Bertrand, G. Souillet, et al., Outcomes of hematopoietic stem cell transplantation for Hurler's syndrome in Europe: a risk factor analysis for graft failure, *Bone Marrow Transplant.* 40 (3) (2007) 225–233.
- [25] S. Tomatsu, K. Okamura, H. Maeda, T. Taketani, S.V. Castrillon, M.A. Gutierrez, et al., Keratan sulphate levels in mucopolysaccharidoses and mucopolipidoses, *J. Inherit. Metab. Dis.* 28 (2005) 187–202.
- [26] S. Tomatsu, A. Montaño, H. Oikawa, R. Giugliani, P. Harmatz, M. Smith, et al., Impairment of body growth in mucopolysaccharidoses, in: V.R. Preedy (Ed.) *Handbook of Growth and Growth Monitoring in Health and Disease*, 2012, pp. 2091–2116.
- [27] T. Oguma, S. Tomatsu, A.M. Montano, O. Okazaki, Analytical method for the determination of disaccharides derived from keratan, heparan, and dermatan sulfates in human serum and plasma by high-performance liquid chromatography/turbo ionspray ionization tandem mass spectrometry, *Anal. Biochem.* 368 (2007) 79–86.
- [28] S. Tomatsu, T. Fujii, M. Fukushi, T. Oguma, T. Shimada, M. Maeda, et al., Newborn screening and diagnosis of mucopolysaccharidoses, *Mol. Genet. Metab.* 110 (2013) 42–53.
- [29] D.C. Sheehan, *Theory and practice of histotechnology*, Battelle Press, P157.
- [30] S. Tomatsu, A.M. Montaño, T. Oguma, V.C. Dung, H. Oikawa, M.L. Gutiérrez, et al., Validation of disaccharide compositions derived from dermatan sulfate and heparan sulfate in mucopolysaccharidoses and mucopolipidoses II and III by tandem mass spectrometry, *Mol. Genet. Metab.* 99 (2010) 124–131.
- [31] S. Tomatsu, A.M. Montaño, T. Oguma, V.C. Dung, H. Oikawa, T.G. de Carvalho, et al., Dermatan sulfate and heparan sulfate as a biomarker for mucopolysaccharidosis I, *J. Inherit. Metab. Dis.* 33 (2010) 141–150.
- [32] E.J. Langereis, A. Borgo, E. Crushell, P.R. Harmatz, P.M. van Hasselt, S.A. Jones, P.M. Kelly, et al., Treatment of hip dysplasia in patients with mucopolysaccharidosis type I after hematopoietic stem cell transplantation: results of an international consensus procedure, *Orphanet J. Rare Dis.* 3 (8) (2013) 155.
- [33] G. Khanna, A.E. Van Heest, J. Agel, K. Bjoraker, S. Grewal, S. Abel, et al., Analysis of factors affecting development of carpal tunnel syndrome in patients with Hurler syndrome after hematopoietic cell transplantation, *Bone Marrow Transplant.* 39 (6) (2007) 331–334.
- [34] S. Tomatsu, K. Okamura, T. Taketani, K.O. Orii, T. Nishioka, M.A. Gutierrez, et al., Development and testing of new screening method for keratan sulfate in mucopolysaccharidosis IVA, *Pediatr. Res.* 55 (4) (2004) 592–597.
- [35] S. Tomatsu, A.M. Montaño, T. Oguma, V.C. Dung, H. Oikawa, T.G. de Carvalho, et al., Validation of keratan sulfate level in mucopolysaccharidosis type IVA by liquid chromatography–tandem mass spectrometry, *J. Inherit. Metab. Dis.* 33 (3) (2010) 35–42.
- [36] D.J. Rowan, S. Tomatsu, J.H. Grubb, A.M. Montaño, W.S. Sly, Assessment of bone dysplasia by micro-CT and glycosaminoglycan levels in mouse models for mucopolysaccharidosis type I, IIIA, IVA, and VII, *J. Inherit. Metab. Dis.* 36 (2) (2013) 235–246.
- [37] D.J. Rowan, S. Tomatsu, J.H. Grubb, B. Haupt, A.M. Montaño, H. Oikawa, et al., Long circulating enzyme replacement therapy rescues bone pathology in mucopolysaccharidosis VII murine model, *Mol. Genet. Metab.* 107 (2012) 161–172.
- [38] J. Crow, D.A. Gibbs, W. Cozens, E. Spellacy, R.W. Watts, Biochemical and histopathological studies on patients with mucopolysaccharidoses, two of whom had been treated by fibroblast transplantation, *J. Clin. Pathol.* 36 (4) (1983) 415–430.
- [39] U.N. Wiesmann, M.A. Spycher, C. Meier, I. Liebaers, N. Herschkowitz, Prenatal mucopolysaccharidosis II (Hunter): a pathogenetic study, *Pediatr. Res.* 14 (5) (1980) 749–756.
- [40] M. Beck, S. Braun, W. Coerdts, E. Merz, E. Young, A.C. Sewell, Fetal presentation of Morquio disease type A, *Prenat. Diagn.* 12 (12) (1992) 1019–1029.
- [41] A.C. Crawley, K.H. Niedzielski, E.L. Isaac, R.C. Davey, S. Byers, J.J. Hopwood, Enzyme replacement therapy from birth in a feline model of mucopolysaccharidosis type VI, *J. Clin. Invest.* 99 (4) (1997) 651–662.
- [42] M.H. de Ru, J.J. Boelens, A.M. Das, S.A. Jones, J.H. van der Lee, N. Mahlaoui, et al., Enzyme replacement therapy and/or hematopoietic stem cell transplantation at diagnosis inpatients with mucopolysaccharidosis type I: results of a European consensus procedure, *Orphanet J. Rare Dis.* 6 (2011) 55.
- [43] J.J. Boelens, V. Rocha, M. Aldenhoven, R. Wynn, A. O'Meara, G. Michel, et al., Risk factor analysis of outcomes after unrelated cord blood transplantation in patients with Hurler syndrome, *Biol. Blood Marrow Transplant.* 15 (5) (2009) 618–625.
- [44] V.K. Prasad, J. Kurtzberg, Transplant outcomes in mucopolysaccharidoses, *Semin. Hematol.* 47 (1) (2010) 59–69.
- [45] A. Tanaka, T. Okuyama, Y. Suzuki, N. Sakai, H. Takakura, T. Sawada, et al., Long-term efficacy of hematopoietic stem cell transplantation on brain involvement inpatients with mucopolysaccharidosis type II: a nationwide survey in Japan, *Mol. Genet. Metab.* 107 (3) (2012) 513–520.
- [46] S. Paciotti, E. Persichetti, S. Pagliardini, M. Deganuto, C. Rosano, C. Balducci, et al., First pilot newborn screening for four lysosomal storage diseases in an Italian region: identification and analysis of a putative causative mutation in the GBA gene, *Clin. Chim. Acta* 413 (23–24) (2012) 1827–1831.
- [47] C.R. Scott, S. Elliott, N. Buroker, L.I. Thomas, J. Keutzer, M. Glass, et al., Identification of infants at risk for developing Fabry, Pompe, or mucopolysaccharidosis-I from newborn blood spots by tandem mass spectrometry, *J. Pediatr.* 163 (2) (2013) 498–503.
- [48] S.P. Lin, H.Y. Lin, T.J. Wang, C.Y. Chang, C.H. Lin, S.F. Huang, et al., A pilot newborn screening program for mucopolysaccharidosis type I in Taiwan, *Orphanet J. Rare Dis.* 8 (2013) 147.