

Received: 2016.07.11  
Accepted: 2016.08.12  
Published: 2017.03.28

# Dynamics of Fukuoka Criteria and Patient Management in Pancreatic Intraductal Papillary Mucinous Neoplasms (IPMNs) During Follow-Up

Authors' Contribution:  
Study Design A  
Data Collection B  
Statistical Analysis C  
Data Interpretation D  
Manuscript Preparation E  
Literature Search F  
Funds Collection G

ABCDEF 1 **Barbara Schellhaas**  
B 1 **Francesco Vitali**  
B 1 **Dane Wildner**  
B 1 **Rüdiger S. Görtz**  
B 1 **Lukas Pfeifer**  
E 2 **Peter C. Konturek**  
E 1 **Markus F. Neurath**  
ABDEF 1 **Deike Strobel**

1 Department of Internal Medicine 1, Erlangen University Hospital, Friedrich-Alexander-Universität (FAU) University of Erlangen-Nürnberg, Erlangen, Germany  
2 Department of Internal Medicine II, Thuringia Clinic, Saalfeld, Germany

**Corresponding Author:** Barbara Schellhaas, e-mail: barbara.schellhaas@uk-erlangen.de  
**Source of support:** Departmental sources

**Background:** Pancreatic intraductal papillary mucinous neoplasms (IPMNs) present a clinical challenge. Evidence-based guidelines are lacking. The so-called "Fukuoka criteria" were developed to assess the risk of malignancy in IPMNs upon imaging. However, little is known about their diagnostic value and the natural course of IPMNs. Thus, the aim of this study was the assessment of Fukuoka criteria and patient management in pancreatic IPMNs during follow-up.





**Material/Methods:** IPMNs were identified via retrospective survey of endoscopic ultrasound (EUS) examinations. Fukuoka criteria were assessed on EUS findings and additional imaging (CT, MRI, ultrasound). Patients' symptoms and comorbidities were recorded. Dynamics of Fukuoka criteria and patient management were compared at first presentation and during follow-up.

**Results:** We screened 1324 EUS examinations. Sixty-five patients (male/female, 14/37; mean age, 68.8 years; range, 48–85 years) with IPMNs were identified (57 branch duct (BD)-IPMNs, 3 main duct (MD)-IPMNs, 5 mixed-type (MT)-IPMNs). Seven patients received surgical resection (4 BD-IPMNs, 2 MD-IPMNs, 1 MT-IPMN). Nine BD-IPMNs had neither surgery nor follow-up. Fifty-one patients (44 BD-IPMNs, 2 MD-IPMNs, 5 MT-IPMNs) underwent follow-up (mean duration, 18.7 months; range, 3–139 months). There were 15/51 patients who were initially Fukuoka-positive. One MD-IPMN, 4/5 MT-IPMNs, and 13/44 BD-IPMNs showed progressive changes but were not resected due to patients' refusal or comorbidities. Four BD-IPMNs converted to Fukuoka-positive.

**Conclusions:** Evidence-based guidelines for non-invasive dignity assessment of IPMNs are lacking. In our study, MD-IPMNs displayed greater dynamics than BD-IPMNs and MT-IPMNs concerning Fukuoka criteria. Prospective long-term studies are needed to clarify prognostic significance of the single Fukuoka criteria and sensible duration of follow-up.

**MeSH Keywords:** **Diagnostic Imaging • Endosonography • Pancreas • Pancreatic Cyst • Pancreatic Neoplasms • Patient Care Management**

**Full-text PDF:** <http://www.medscimonit.com/abstract/index/idArt/900535>

 4196  6  2  21



## Background

Intraductal papillary mucinous neoplasms (IPMNs) of the pancreas represent a common finding in unselected patients, with increasing incidence over the last decades and general prevalence increasing with age. Their prevalence on endoscopic ultrasound (EUS) examinations carried out for unrelated indications is estimated as 9.4% [1–3].

To date, evidence-based guidelines for the management of IPMNs are lacking. Our knowledge of the natural history of this heterogeneous entity is limited, and efforts to define reliable imaging criteria for non-invasive assessment of malignancy remain elusive. Efforts to provide guidelines for dealing with IPMNs led to the development of the “Sendai Consensus Guidelines” in 2006 and their revised version, the “Fukuoka Consensus Guidelines”, in 2012 (Table 1). Despite their lack of validation and the fact that they were mostly based on expert opinion and retrospective post-surgical studies, these guidelines were readily adopted worldwide [1,2,4–6]. However, their poor positive predictive value (PPV) for malignancy of 67% for Sendai Consensus Guidelines and 88% for Fukuoka Consensus Guidelines may result in surgical overtreatment [1,2,4].

Therapeutic strategy remains an individual decision taking into account the risk of malignant transformation, as well as a patient’s age, life circumstances, comorbidities, and personal preferences. The potential benefit of surgical resection has to be balanced with morbidity and mortality resulting from pancreatic surgery. Clear concepts or validated guidelines are lacking, especially concerning assessment of malignant potential of a

given lesion by non-invasive means. Furthermore, the duration of follow-up required for a valid dignity assessment of IPMNs remains still unclear. A patient’s potential benefit from longer follow-up has to be considered as well as costs and psychosocial burdens such as anxiety resulting from unnecessary diagnostics.

To date, our understanding of the natural history of IPMNs is insufficient. Also, almost all epidemiological data available is based upon retrospective analysis of post-surgical specimen representing a highly selected patient population of high-risk cases only for whom resection seemed the appropriate option. These patients cannot be seen as representative of the “average patient” with incidentally diagnosed IPMN [7,8]. Thus, the purpose of the present work was to assess the dynamics of Fukuoka criteria and patient management in patients with IPMNs during follow-up.

## Material and Methods

The design of this retrospective longitudinal study is illustrated in Figure 1. Endoscopic ultrasound (EUS) examinations of the pancreas performed between 01.01.1999 and 31.12.2014 were assessed to identify patients with IPMNs. Exclusion criteria were normal pancreas on EUS, solid lesions without cystic parts, as well as cystic lesions of the pancreas other than IPMNs. Patients with a history of acute or chronic pancreatitis (as defined by serum lipase elevated by the factor of  $\geq 3$  and abdominal pain, or criteria typical of chronic pancreatitis on imaging) were excluded. Based on EUS and additional imaging

**Table 1.** Sendai and Fukuoka Consensus Guidelines (adopted from [4]).

Sendai Consensus Guidelines 2006	
MD-IPMN	Major Pancreatic Duct (MPD) $\geq 10$ mm
BD-IPMN	<ul style="list-style-type: none"> <li>• Size <math>&gt;3</math> cm</li> <li>• Size <math>\leq 3</math> cm with                             <ul style="list-style-type: none"> <li>• Symptoms</li> <li>• Mural nodules</li> <li>• MPD dilation (<math>&gt;6</math> mm)</li> <li>• Positive cytology</li> </ul> </li> </ul>
Fukuoka Consensus Guidelines 2012	
High risk features	<ul style="list-style-type: none"> <li>• Proximal lesion with obstructive jaundice</li> <li>• Enhancing nodules</li> <li>• Dilated main duct (<math>\geq 10</math> mm)</li> </ul>
Worrisome risk features	<ul style="list-style-type: none"> <li>• Size <math>\geq 3</math> cm</li> <li>• Pancreatitis</li> <li>• Non-enhancing nodules</li> <li>• Thickened, enhancing walls</li> <li>• Dilated duct (5 to <math>&lt;10</math> mm)</li> <li>• Change in duct caliber with distal atrophy</li> <li>• Lymphadenopathy</li> </ul>

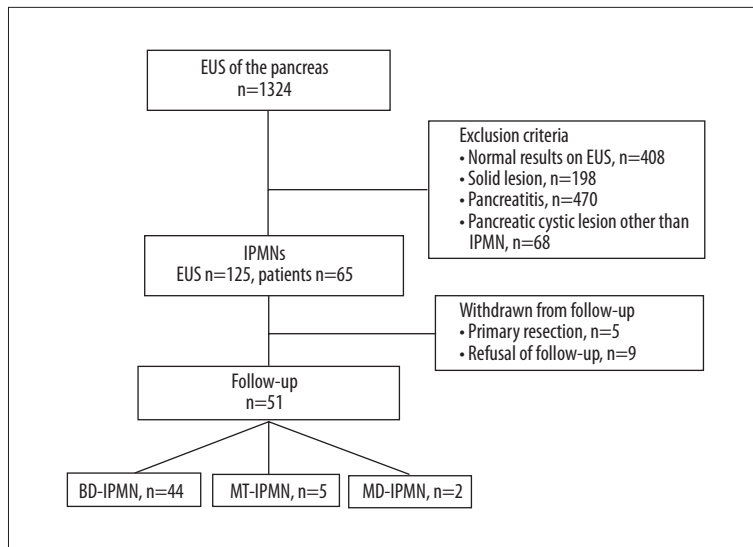


Figure 1. Study design.

(MRI, CT, and ultrasound), IPMNs were categorized according to Fukuoka criteria [1,2,4,7; Table 1] at initial presentation and during follow-up. For follow-up, the minimum interval between 2 separate follow-up-examinations was defined as 3 months. IPMNs were considered “progressive” in case of increase in cyst diameter of  $\geq 20\%$  of the original size or  $\geq 30$  mm in total, or conversion to Fukuoka (F-)positive findings. Also, increases in cyst number were recorded. All patients were assessed for comorbidities and clinical symptoms (icterus, abdominal discomfort, weight loss of  $\geq 10\%/6$  months, or others) at initial presentation and during follow-up. Patient management and histological data were assessed.

Descriptive statistical analysis was performed using Microsoft Excel 2010. Values are expressed as median and range, or absolute sum and proportion in percent, as appropriate.

## Results

### Patient characteristics at first presentation

Sixty-five patients (mean age, 68.6 years; range, 48–85 years) with IPMNs (57 BD-IPMNs, 3 MD-IPMNs, 5 MT-IPMNs) were identified who met the selection criteria. 25 patients (38%) were symptomatic upon first presentation, among them 1/3 MD-IPMNs and 2/5 MT-IPMNs. Most of them (n=21) presented with abdominal discomfort; 3 patients complained about weight loss; 15 had other, unspecific symptoms; and none had jaundice.

Fourteen patients withdrew from follow-up due to primary resection (n=5; 1 MD-IPMN, 1 MT-IPMN, 3 BD-IPMNs), old age  $\geq 75$  years, concurrent malignancies and comorbidities (n=5 BD-IPMNs), or patient’s noncompliance (n=4 BD-IPMNs).

### Patient characteristics at first follow-up

Fifty-one patients, including 44 BD-IPMNs (86.3%), 2 MD-IPMNs (3.9%), and 5 MT-IPMNs (9.8%), were enrolled into follow-up. Of the 2 MD-IPMNs included into follow-up, 1 had had 18 months of follow-up at an external hospital before referral to our institution, where he was resected at first presentation; the other one had metastasized breast cancer and was therefore not qualified for surgery. Of the MT-IPMNs, 1 was primarily resected but afterwards enrolled into follow-up for development of a new cystic lesion later resolved as pseudocyst. Two had unrelated malignancies; one was aged 84 years and refused resection; the fifth one refused biopsy and surgery for personal reasons and decided for follow-up instead.

Patient characteristics upon first follow-up are summarized in Table 2. Mean age was similar for all 3 IPMN subtypes. Sex distribution showed slight differences, with female predominance (79%) for BD-IPMNs and male predominance for MD-IPMNs (66% males) and MT-IPMNs (60% males). Eight patients were symptomatic (15.7%); most of them complained of abdominal discomfort.

### Follow-Up

Mean duration of follow-up was 18.7 months (range, 3–139 months) with a mean interval of 10.4 months (range, 3–65 months) between follow-up examinations.

All patients had at least 1 imaging modality in addition to EUS performed (on average, 1.2–1.8 different imaging modalities per follow-up; range, 1–3).

**Table 2.** Characteristics of IPMN patients enrolled into follow-up.

Total	51 (100%)
BD-IPMN	44 (86.3%)
MD-IPMN	2 (3.9%)
MT-IPMN	5 (9.8%)
Gender male/female (n/%)	14/37 (27%/73%)
Age [Years] (mean; range)	68.6 (48–85)
Symptomatic (n/%)	14 (27.5%)
Cyst size [mm] (mean; range)	16.7 (6–40)
Major pancreatic duct (MPD) diameter [mm] (mean; range)	3.4 (1.2–8)
Fukuoka-positive	15 (29.4%) (2 MD-IPMNs, 5 MT-IPMNs, 8 BD-IPMNs)

**Table 3.** Fukuoka (F-) criteria of IPMNs enrolled into follow-up (n).

	Cyst >30 mm	Thickened walls	Solid component	Mural nodules	MPD 5–9 mm
BD-IPMN (n=44)	1	0	4	1	2
MD-IPMN (n=2)	2	1	1	1	2
MT-IPMN (n=5)	2	1	2	1	2
Total (n=51)	5	2	7	3	6

**Table 4.** Imaging features of IPMNs enrolled into follow-up.

	Cyst size [mm] (mean; range)		Diameter of MPD [mm]		F-positive upon imaging
BD-IPMN (n=44)	15.5	(6–30)	2.7	(1.2–5)	8 (18.2%)
MD-IPMN (n=2)	35	(30; 40)	5.5	(5; 6)	2 (100%)
MT-IPMN (n=5)	23.6	(10–40)	5.3	(3.3–8)	5 (100%)

**Dynamics of IPMNs during follow-up**

Imaging features as well as dynamic changes of IPMNs during follow-up are summarized in Tables 3–5. None of the IPMNs showed a major pancreatic duct (MPD) dilation >10 mm or change in MPD calibre with distal pancreas atrophy.

**BD-IPMNs**

In 15 of the 44 BD-IPMNs (34.1%), dynamic changes could be observed. Two of the 8 initially Fukuoka-positive patients converted to Fukuoka-negative during the course of follow-up, and 13 patients (29.5%) showed some form of progress. Mean time to progression was 13.4 months (range, 5–32 months).

Four patients (9.1%) showed significant increase in cyst size of + ≥20% or up to a total size of ≥30 mm. Two of them remained Fukuoka-negative (increase from 10 to 20 mm and 6 to 9 mm,

respectively; later drop-out from follow-up due to old age and patient’s in compliance). One BD-IPMN with a progressive increase in size from 17 to 32 mm without other risk stigmata was kept within follow-up due to the patient’s preference over biopsy or surgery; findings kept stable during follow-up without further progression for another 44 months. One BD-IPMN (patient no. 6, Table 6) with conversion from Fukuoka-negative to Fukuoka-positive status due to an increase in cyst size from 24 to 35 mm and development of solid components over the course of 19 months of follow-up was referred to surgery (Whipple-procedure). Histological findings revealed non-invasive BD-IPMN with low-grade dysplasia.

One patient developed a new Fukuoka-negative BD-IPMN 27 months after distal pancreatectomy for BD-IPMN without dysplasia. One patient developed solid components after 7 months, but suffering from renal cell cancer, he refused biopsy or surgery. The second patient with development of solid

**Table 5.** Dynamics of IPMNs during follow-up.

	BD-IPMN	MT-IPMN	MD-IPMN
Total N	44	5	2
No changes at all	29	1	0
Significant increase in size (+20%/≥30 mm)	4	3	2
Emergence of solid component	4	2	2
Development of mural nodules	0	2	2
Progressive MPD dilation >5 mm	0	2	2
Emergence of new cysts	6	0	0
Development of new BD-IPMN	1	n.a.	n.a.
Conversion F- → F+	4	n.a.	n.a.
Repeated conversion	2	n.a.	n.a.

components and conversion to Fukuoka-positive status was patient no. 6 mentioned above. Another 2 patients developed solid components and solid components plus new cysts after 7 and 24 months, respectively, which were no longer detectable in subsequent follow-up examinations. These 4 cases (9.1%) were the only ones with conversion from Fukuoka-negative to Fukuoka-positive status.

For 2 patients (4.6%), repeated conversion could be observed. Both patients developed solid components upon EUS (after 5 and 12 months, respectively), which were no longer detectable in subsequent follow-ups with conventional ultrasound (US). In 5 cases (11.4%), emergence of new cysts was observed (mean time to progression, 25.4 months; range, 5–65 months).

#### MT-IPMNs

Four out of the 5 patients with MT-IPMN showed progress during follow-up (Table 5). Only 1 MT-IPMN remained almost unchanged during 2 years of follow-up.

#### MD-IPMNs

Both MD-IPMNs enrolled into follow-up showed progression in terms of increase of cyst size, development of solid components and mural nodules, and progressive MPD dilation.

#### Patients referred to surgery

Surgery was performed in 7/65 patients (10.4%). 5 of them were primarily resected (1 MT-IPMN, 1 MD-IPMN, 1 symptomatic BD-IPMN with recurrent abdominal pain, 2 BD-IPMNs mistakenly assumed to be MT-/MD-IPMNs). 1 BD-IPMN was resected after conversion to Fukuoka-positive status after 19 months of follow-up, being mistaken for a MT-IPMN; and 1 MD-IPMN had had 18 months of follow-up at an external

hospital before referral to our institution, where he was resected at first presentation.

Table 6 shows a comparison of pre- and post-operative diagnoses in surgically resected patients.

Patient no. 1 had a CT scan done for abdominal pain and was pre-operatively diagnosed with mucinous cystic neoplasm (MCN)/DD: MT-IPMN. Results from ultrasound-guided puncture remained inconclusive; MRCP confirmed the tentative diagnosis of MT-IPMN. The patient was thus referred to Whipple's procedure. Histological findings showed a MT-IPMN of borderline dignity with moderate dysplasia, but no signs of invasiveness.

Patient no. 2 also had a CT scan done for abdominal pain, which revealed the incidental finding of a cystic lesion of the pancreas classified as MD-IPMN. Due to multiple collateral vessels, puncture seemed technically impossible. Hence, primary resection (distal pancreatectomy and splenectomy) was performed. Histology revealed a ductal adenocarcinoma (G2) with direct contact to the suspected MD-IPMN with high-grade dysplasia.

Patient no. 3 presented with acute abdominal pain; ultrasound examination showed acute cholecystitis, together with a pancreatic cystic lesion as an incidental finding. Further diagnostic workup (CT, EUS, MRCP) at an external hospital led to the tentative diagnosis of MT-IPMN of 30 mm in size; the MPD was 5 mm. The patient was enrolled in 18 months of follow-up at the external hospital before referral to our institution. EUS confirmed MD-IPMN with a solid component. The patient was referred to Whipple's procedure, which confirmed a MD-IPMN with high-grade dysplasia, but no signs of invasiveness.

Patient no. 4 suffered from multiple food allergies, chronic abdominal pain and meteorism; US was of limited diagnostic value in her. On EUS, a BD-IPMN of 18 mm was suspected; she

**Table 6.** Pre- and post-operative diagnoses in patients undergoing surgical resection.

Patient (sex; age)	Pre-operative diagnosis	Post-operative diagnosis
No. 1 (M; 74) Primary resection	MCN/MT-IPMN	MT-IPMN of borderline dignity (moderate dysplasia, non-invasive)
No. 2 (M; 66) Primary resection	MD-IPMN	MD-IPMN with HGD + PDAC G2 with contact to IPMN lesion
No. 3 (M; 82) Follow-up for 18 months in external hospital; primary resection upon first presentation in our hospital	MD-IPMN	MD-IPMN with HGD; non-invasive
No. 4 (F; 61) Primary resection	MT-IPMN	BD-IPMN of borderline dignity with moderate dysplasia
No. 5 (F; 66) Primary resection	MD-IPMN	BD-IPMN without dysplasia
No. 6 (F; 62) Resection after 19 months of follow-up	MT-IPMN	BD-IPMN with LGD, non-invasive
No. 7 (F; 59) Primary resection	BD-IPMN	BD-IPMN with HGD, non-invasive
Total: n=7		

HGD – high-grade dysplasia; LGD – low-grade dysplasia; PDAC – pancreatic ductal adenocarcinoma.

had a MRCP done, which raised suspicion of a MT-IPMN. She turned to an external hospital for Whipple resection, which revealed a BD-IPMN with moderate dysplasia without malignancy. Further follow-up for 2 years showed no pathological findings.

Patient no. 5 was suspected to have a MD-IPMN. Distal pancreas resection was performed at an external hospital, revealing a BD-IPMN without dysplasia.

Patient no. 6 was diagnosed with BD-IPMN of 24 mm as an incidental finding and was enrolled into follow-up. After 4 months, the lesion had progressed to 35 mm and developed solid components. The patient refused resection at this time, so follow-up was continued. After 19 months, the MPD was dilated (5 mm), so MT-IPMN was suspected and the patient was referred to Whipple resection. Histological findings showed a BD-IPMN with low-grade dysplasia.

Patient no. 7 had been diagnosed with BD-IPMN at an external hospital 1 year prior to referral to our institution. Because of recurrent abdominal pain, she was referred to Whipple resection. Histology showed a non-invasive BD-IPMN with high-grade dysplasia.

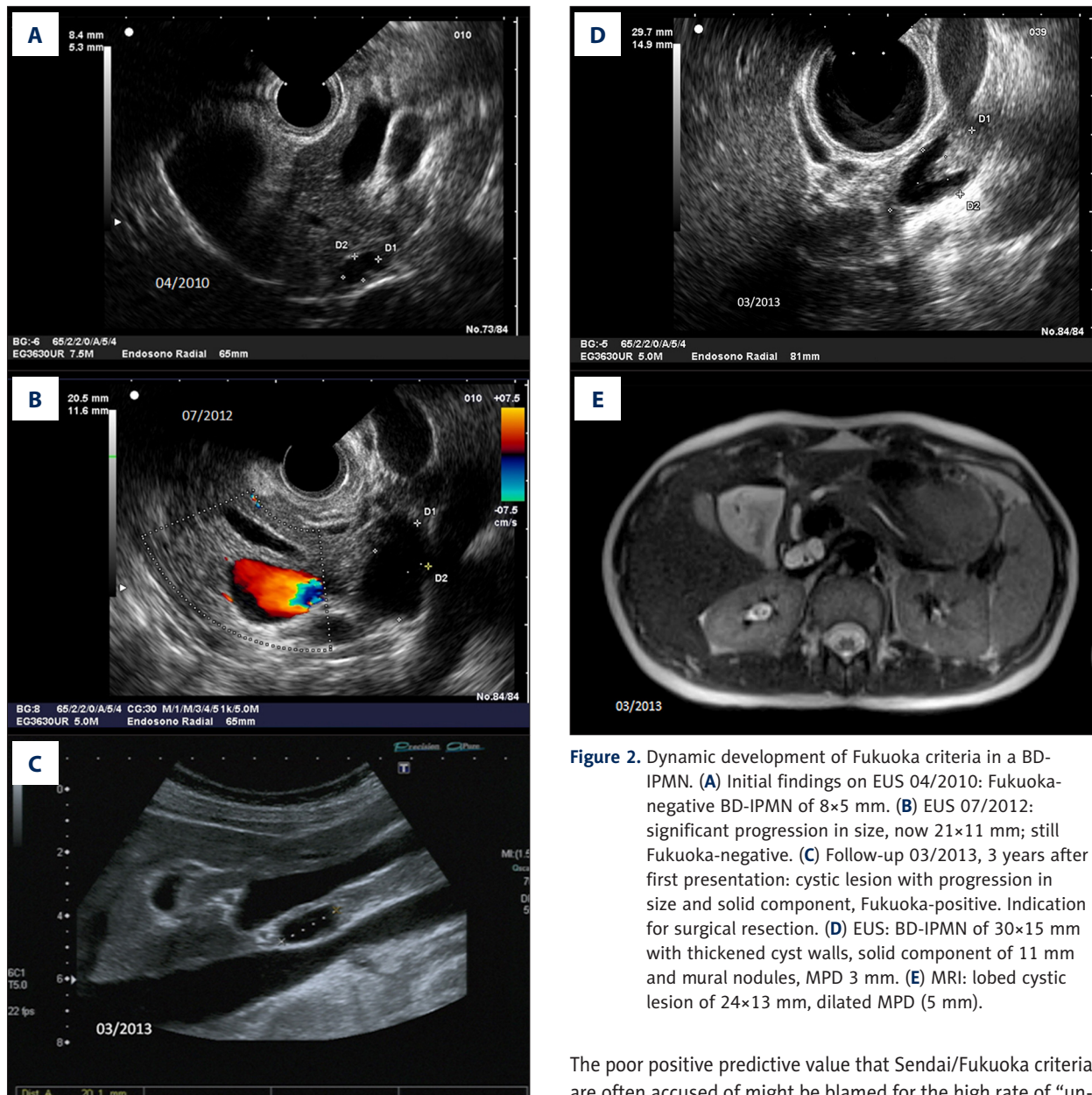
Tentative diagnosis leading to surgery was MD-IPMN in 3 patients, MT-IPMN in 2 patients, BD-IPMN in 1 patient, and MCN versus MT-IPMN in 1 patient. Histological diagnosis confirmed pre-operative findings in 3/7 cases (=42.9%), which means that in 57.1% of resected patients, the initial diagnosis had to

be revised. In one patient resected for suspected MT-IPMN, a pancreatic ductal adenocarcinoma with direct contact to the cystic lesion, and thus probably derived from malignant transformation of the IPMN, was found.

## Discussion

Despite an increasing incidence of IPMNs as incidental findings upon imaging modalities performed for unrelated purpose, management of these lesions remains a clinical challenge. To date, evidence-based guidelines for the management of IPMNs are lacking. Our knowledge of the natural history of this heterogeneous entity is limited, and efforts to define reliable imaging criteria for non-invasive assessment of malignancy remain elusive. A typical example of dynamic development of Fukuoka criteria in a BD-IPMN is shown in Figure 2. The purpose of this work was retrospective assessment of imaging features of IPMNs during follow-up in order to identify patterns of progression.

In our study, histological findings were available for only 7 of the 65 IPMN patients (10.8%) eligible for analysis, thus establishing a definite diagnosis. In the other 89.2%, final diagnosis was based on clinical and imaging features as well as natural history during follow-up, thus finally constituting mainly a tentative diagnosis.



**Figure 2.** Dynamic development of Fukuoka criteria in a BD-IPMN. **(A)** Initial findings on EUS 04/2010: Fukuoka-negative BD-IPMN of 8×5 mm. **(B)** EUS 07/2012: significant progression in size, now 21×11 mm; still Fukuoka-negative. **(C)** Follow-up 03/2013, 3 years after first presentation: cystic lesion with progression in size and solid component, Fukuoka-positive. Indication for surgical resection. **(D)** EUS: BD-IPMN of 30×15 mm with thickened cyst walls, solid component of 11 mm and mural nodules, MPD 3 mm. **(E)** MRI: lobed cystic lesion of 24×13 mm, dilated MPD (5 mm).

Correspondingly, the present data illustrate the pitfalls and limitations of non-invasive diagnostics in IPMNs: In 4 out of 7 patients, histological findings confirmed pre-operative diagnosis. At the same time, this means that in 57.1% of cases, surgery did not confirm the tentative diagnoses. In 1 case, a pancreatic ductal adenocarcinoma was incidentally detected when MD-IPMN was suspected, presenting the only case of “understaging”. In the other 3 cases of wrong pre-operative diagnosis, findings were “overstaged”. These results are consistent with findings from recent literature: According to a large meta-analysis, fractions of invasive pancreatic ductal adenocarcinomas are found in as few as 0–32% (15% on average) of all cystic lesions of the pancreas resected for suspected malignancy [7].

The poor positive predictive value that Sendai/Fukuoka criteria are often accused of might be blamed for the high rate of “unnecessary” resections for alleged malignancies [4]. Moreover, it can be assumed that non-invasive follow-up is also often extended over excessively long periods, resulting in additional burdens for the individual patient and unnecessary costs for the health care system. The question arises of which patients should be enrolled into follow-up, and, in case of constant findings showing no signs of progression, at what point follow-up can be discontinued.

In September 2015, the American Gastroenterological Association (AGA) published for the first time guidelines addressing these questions [8]. However, the level of evidence is low because the guidelines are recommendations mostly based on expert opinion and clinical experience without sufficient validation.

They pertain to asymptomatic pancreatic cystic lesions only; also, IPMNs without branch duct involvement are not included, as they are considered less challenging, with surgical resection being accepted as the appropriate approach in suitable candidates [8]. According to the AGA guidelines, follow-up should be offered only to patients with surgery as a potential option in case of suspected malignancy, thus excluding patients with limited life expectancy, severe comorbidities, or refusal to undergo surgery in case it should be recommended. In asymptomatic pancreatic cystic lesions without any high risk stigmata (defined as cyst size >30 mm, dilated MPD, or presence of a solid component), the AGA suggests performing an MRI scan after 1 year, and thereafter every 2 years for a total period of 5 years. In case of unchanged size and imaging features of cystic lesions, it is then recommended to consider discontinuation of follow-up [8]. These recommendations are based on the assumption that although about 25% of the general population over 70 years of age are asymptomatic carriers of pancreatic cystic lesions, the average risk of malignant transformation is estimated to be as low as 0.24% per year. In contrast, in the presence of high risk stigmata on imaging modalities, the risk of malignant transformation is significantly increased (by a factor of 3 for cysts >30 mm in size, and almost 8-fold for the presence of an associated solid component). In case of IPMNs, a higher risk of malignancy has also been found in association with MPD dilation. In the presence of any of these risk factors, the AGA recommends EUS-guided fine-needle aspiration (FNA). In case of normal cytological findings, an MRI scan should be performed after 1 year and then every 2 years thereafter [8].

In general, surgical resection is widely accepted as the appropriate treatment for MD-IPMNs in suitable candidates. Nevertheless, in the present study, only one out of three MD-IPMN patients was surgically resected on first diagnosis, while the other two patients were enrolled into follow-up. However, this was due to the fact that in one case, the patient was suffering from metastasized breast cancer, so that best supportive care was chosen as the most suitable option for her. The other patient had had a long history of follow-up at an external peripheral hospital before being referred to our clinic; after first presentation here, he was conveyed to surgery.

Therefore, decision-making seems easy in MD-IPMN patients, whereas MT- and BD-IPMN patients present a clinical challenge. Carrying a 57–92% risk of malignant transformation, MD-IPMNs are seen as an indication for surgical resection immediately after first diagnosis [9]. For MT-IPMNs, the risk of malignancy is correlated with the degree of main duct involvement. In our study, both of the MD-IPMN patients and one out of five MT-IPMN patients enrolled into follow-up showed progression. However, as only histological findings can provide information about the presence of high-grade dysplasia or invasiveness, the risk of malignancy for these lesions ultimately remains unclear.

In this context, BD-IPMNs seem to constitute the hardest challenge, representing the most common entity and at the same time the one with the greatest uncertainty as to the appropriate management. They are primarily seen as (pre)malignant lesions, with a risk for malignant transformation of 6–46% [9]. However, there is great interindividual variability. Some studies assume that BD-IPMNs have a 10-year progression risk of 20% [9]. Outcome is excellent in case of resection at an early stage (meaning high-grade-dysplasia, carcinoma-in-situ (CIS), or T1a with <5 mm of stromal invasion). Nonetheless, for advanced stages with invasive parts, prognosis rapidly deteriorates, with outcomes similar to those of pancreatic ductal adenocarcinomas. Thus, some authors recommend early resection [1]. However, as IPMNs are considered as “field defects” based on genome-wide defects, there remains a risk of emerging premalignant and malignant lesions in the residual parenchyma even after R0-resection. Thus, definitive “cure” can only be achieved by complete resection of the pancreas, which, on the other hand, is associated with considerable mortality of 1–3% and post-operative morbidity of 30% [1,2,4,9–12]. BD-IPMNs carry a significantly higher risk of malignancy if already containing high-grade-dysplasia; however, this cannot be confirmed nor ruled out except through histological findings.

Upon first presentation, 17/65 patients (26.2%) showed worrisome or high-risk features on imaging; five of these patients (13.2%) were symptomatic. Upon first follow-up, the percentage of Fukuoka-positive IPMNs remained fairly stable (12/51=23.5%), with three of these patients being symptomatic. However, clinical symptoms do not seem a reliable predictor of the malignant potential of a lesion.

13/51 patients enrolled into follow-up (25.5%) showed progress upon imaging during the course of follow-up. Given the low rate of malignant findings in resected BD-IPMNs, Fukuoka-positivity on imaging does not seem a reliable predictor of malignant development, either. Also, except for surgically resected patients with a definite diagnosis based on histological findings, the present data provides no direct clue as to the risk of malignancy associated with an increase in cyst size or emergence of new cystic lesions during follow-up.

Besides emergence of new cystic lesions in sites separate from the original IPMN, the most common form of progression in the present study was increase in cyst size. The other Fukuoka criteria did not display marked dynamic development.

As IPMNs constitute “field defects” of the pancreas due to genetic alterations, they are found to be multilocular in up to 83% of cases [13]. According to the literature, multilocularity and multiplicity of cysts are not associated with risk of malignancy [14], although high cyst numbers  $\geq 10$  have been associated with high-grade-dysplasia and invasive carcinomas in IPMNs [15].



There is considerable controversy in the literature as to the ranking of cyst size as a risk factor, with some studies reporting higher rates of malignancies for IPMNs  $\geq 30$  mm, and others stating the opposite [1]. However, cyst size alone does not seem to be a reliable predictor of malignancy. As opposed to the original Sendai criteria, a cyst size of  $\geq 30$  mm is classified as a “worrisome” but not “high risk” feature in Fukuoka criteria. Suspected malignancy is confirmed in as few as 13-23% of IPMNs resected due to a cyst size of  $\geq 30$  mm [1]. A meta-analysis by Anand et al. in 2013 [16] identified a cyst size of  $\geq 30$  mm as the main predictor of malignancy, whereas this was contradicted by other studies [17]. Nonetheless, there is evidence in the literature for a higher growth rate of malignant versus benign BD-IPMNs [18]. However, as malignancy can only be confirmed histologically, no reliable conclusions can be drawn from growth rates in our study. Still, the mean duration until first signs of progression in BD-IPMN patients turned out to be 19.6 months (range, 5–65 months), as opposed to 10.5 months in MD-IPMN patients and 77 months in the only MT-IPMN patient showing progression during follow-up. Thus, although cautious interpretation is appropriate given our small sample sizes, it might be concluded that latency time until first onset of progress in IPMNs is shortest for MD-IPMNs and longer for BD-IPMNs, corresponding to their assumed malignant potential. For MT-IPMNs, it seems sensible to assume that dynamic properties are associated with the respective proportion of main duct versus branch duct involvement, thus constituting an entity even more heterogeneous than the other subtypes.

Although there is published evidence for a positive correlation between the number of positive Fukuoka criteria and the malignant potential of IPMNs [19,20], the diagnostic value of the single imaging features such as mural nodules and MPD dilation remains unclear. In a study on BD-IPMN patients in 2015 [21], Malleo et al. observed no risk stigmata during malignant transformation of BD-IPMNs except for a continuous increase in cyst size; until final diagnosis of pancreatic ductal adenocarcinoma, no other risk factors could be identified.

These remarks illustrate the controversy of recent publications; there are few validated criteria allowing for a reliable assessment of malignant potential of IPMNs without referring to histological findings.

Interestingly, in our study, none of the findings of any of the imaging modalities reported a change in MPD calibre with distal pancreas atrophy; this might be because patients with signs of chronic pancreatitis on imaging modalities were excluded from the study. Moreover, attention has to be drawn to the fact that imaging modalities for any individual patients varied between follow-up examinations, thus limiting generalizability. Also, a limitation of our study is the small sample size. However, a strength is the relatively long duration of

follow-up (despite considerable variance in the intervals and total duration of follow-up examinations).

Finally, the question of the optimal duration of follow-up in IPMNs remains unanswered. However, most of the lesions showing progress did so at early stages during follow-up. Still, given the fact that there were also cases of repeated conversion from Fukuoka-negative to Fukuoka-positive and back to Fukuoka-negative status, as well as the considerable range of time intervals between follow-up examinations, the diagnostic significance of these findings seems limited.

Further research is needed, especially prospective studies in larger patient populations, in order to get a better understanding of the natural history and dynamic development of IPMNs, which might then enable assessment of malignant potential by non-invasive means.

In conclusion, IPMNs present a common clinical entity with an increasing incidence. To date, diagnostic certainty is obtained only via histological findings. Evidence-based guidelines as to the management of IPMNs and assessment of their malignant potential are still lacking.

The present work presents results from a retrospective longitudinal assessment of IPMN patients over a period of 15 years. The most common Fukuoka-criterion showing dynamic progress was increase in cyst size, together with emergence of new cystic lesions. MD-IPMNs seemed to progress more rapidly than BD-IPMNs and MT-IPMNs. However, none of the clinical or imaging criteria seemed predictive of malignant potential. Also, diagnostic accuracy of surgically resected patients turned out to be as low as 42.9%. A limitation of the study is the small sample size; a strength is the relatively long duration of follow-up (despite considerable variance in the intervals and total duration of follow-up examinations).

## Conclusions

IPMNs present a common clinical entity with an increasing incidence. To date, diagnostic certainty is obtained via histological findings only. Evidence-based guidelines as to the management of IPMNs and assessment of their malignant potential are still lacking.

The present work presents results from a retrospective longitudinal assessment of IPMN patients over a period of 15 years. The most common Fukuoka-criterion showing dynamic progress was increase in cyst size, together with emergence of new cystic lesions. MD-IPMNs seemed to progress more rapidly than BD-IPMNs and MT-IPMNs. However, none of the clinical or imaging criteria seemed predictive of malignant potential.

Also, diagnostic accuracy of surgically resected patients turned out to be as low as 42.9%.

Our findings illustrate the well-known difficulties in assessment of malignant potential of IPMNs by means of non-invasive diagnostics. Given that almost all epidemiological data is based on retrospective analyses of surgically resected cases

and hence drawn from highly selected patient populations not representative of the standard patient with the incidental finding of an IPMN, further prospective long-term studies in larger patient cohorts are needed for a better understanding of the natural history of these lesions. Also, the diagnostic value of molecular markers remains to be elucidated in order to improve pre-operative diagnostic options.

## References:

1. Tanaka M: International consensus on the management of intraductal papillary mucinous neoplasm of the pancreas. *Ann Transl Med*, 2015; 3(19): 286
2. Tanaka M, Fernández-del Castillo C, Adsay V et al., International Association of Pancreatology: International consensus guidelines 2012 for the management of IPMN and MCN of the pancreas. *Pancreatol*, 2012; 12(3): 183–97
3. Sey MS, Teagarden S, Settles D et al: Prospective cross-sectional study of the prevalence of incidental pancreatic cysts during routine outpatient endoscopic ultrasound. *Pancreas*, 2015; 44: 1130–33
4. Goh BK: International guidelines for the management of pancreatic intraductal papillary mucinous neoplasms. *World J Gastroenterol*, 2015; 21(34): 9833–37
5. Jenssen C, Kahl S: Management of incidental pancreatic cystic lesions. *Viszeralmedizin*, 2015; 31(1): 14–24
6. Lennon AM, Ahuja N, Wolfgang CL: AGA Guidelines for the management of pancreatic cysts. *Gastroenterology*, 2015; 149(3): 825
7. Scheiman JM, Hwang JH, Moayyedi P: American gastroenterological association technical review on the diagnosis and management of asymptomatic neoplastic pancreatic cysts. *Gastroenterology*, 2015; 148(4): 824–48.e22
8. Vege SS, Ziring B, Jain R et al., Clinical Guidelines Committee, American Gastroenterology Association: American gastroenterological association institute guideline on the diagnosis and management of asymptomatic neoplastic pancreatic cysts. *Gastroenterology*, 2015; 148(4): 819–22; quiz e12–23
9. Hartwig W, Werner J: Resektion zystischer pankreastumoren. *Gastroenterologie*, 2014; 9: 31–37 [in German]
10. Kobayashi G, Fujita N, Maguchi H et al, Working Group for the Natural History of IPMN of the Japan Pancreas Society: Natural history of branch duct intraductal papillary mucinous neoplasm with mural nodules: A Japan Pancreas Society multicenter study. *Pancreas*, 2014; 43(4): 532–38
11. Weinberg BM, Spiegel BM, Tomlinson JS et al: Asymptomatic pancreatic cystic neoplasms: Maximizing survival and quality of life using Markov-based clinical nomograms. *Gastroenterology*, 2010; 138(2): 531–40
12. Will U: Zystische raumforderungen im pankreas. *Viszeralmedizin*, 2011; 27: 249–54 [in German]
13. Matthaei H, Norris AL, Tsiatis AC et al: Clinicopathological characteristics and molecular analyses of multifocal intraductal papillary mucinous neoplasms of the pancreas. *Ann Surg*, 2012; 255(2): 326–33
14. Kim KW, Park SH, Pyo J et al: Imaging features to distinguish malignant and benign branch-duct type intraductal papillary mucinous neoplasms of the pancreas: A meta-analysis. *Ann Surg*, 2014; 259: 72–81
15. Raman SP, Kawamoto S, Blackford A et al: Histopathologic findings of multifocal pancreatic intraductal papillary mucinous neoplasms on CT. *Am J Roentgenol*, 2013; 200(3): 563–69
16. Anand N, Sampath K, Wu BU: Cyst features and risk of malignancy in intraductal papillary mucinous neoplasms of the pancreas: A meta-analysis. *Clin Gastroenterol Hepatol*, 2013; 11(8): 913–21; quiz e59–60
17. Jang JY, Park T, Lee S et al: Validation of international consensus guidelines for the resection of branch duct-type intraductal papillary mucinous neoplasms. *Br J Surg*, 2014; 101(6): 686–92
18. Kang MJ, Jang JY, Kim SJ et al: Cyst growth rate predicts malignancy in patients with branch duct intraductal papillary mucinous neoplasms. *Clin Gastroenterol Hepatol*, 2011; 9: 87–93
19. Ohtsuka T, Kono H, Nagayoshi Y et al: An increase in the number of predictive factors augments the likelihood of malignancy in branch duct intraductal papillary mucinous neoplasm of the pancreas. *Surgery*, 2012; 151: 76–83
20. Ohtsuka T, Kono H, Tanabe R et al: Follow-up study after resection of intraductal papillary mucinous neoplasm of the pancreas: Special references to the multifocal lesions and development of ductal carcinoma in the remnant pancreas. *Am J Surg*, 2012; 204: 44–48
21. Malleo G, Marchegiani G, Borin A et al: Observational study of the incidence of pancreatic and extrapancreatic malignancies during surveillance of patients with branch-duct intraductal papillary mucinous neoplasm. *Ann Surg*, 2015; 261(5): 984–90