

Received: 2017.09.27
Accepted: 2018.01.29
Published: 2018.06.28

e-ISSN 1941-5923
© Am J Case Rep, 2018; 19: 757-762
DOI: 10.12659/AJCR.907313

Invasive Thyroglossal Duct Cyst Papillary Carcinoma: A Case Report and Review of the Literature

Authors' Contribution:
Study Design A
Data Collection B
Statistical Analysis C
Data Interpretation D
Manuscript Preparation E
Literature Search F
Funds Collection G

ABCDEF 1 **Michael Alatsakis**
ABCDEF 1 **Maria Drogouti**
ABCDEF 2 **Chrysoula Tsompanidou**
ABCDEF 1 **Anastasios Katsourakis**
ABCDEF 1 **Iosif Chatzis**

1 Department of Surgery, General Hospital of Thessaloniki, Agios Dimitrios, Thessaloniki, Greece
2 Department of Pathology, General Hospital of Thessaloniki, Agios Dimitrios, Thessaloniki, Greece

Corresponding Author: Maria Drogouti, e-mail: drog_maria@hotmail.com
Conflict of interest: None declared

Patient: Female, 27
Final Diagnosis: Invasive thyroglossal duct cyst papillary carcinoma
Symptoms: Painless cervical enlargement
Medication: —
Clinical Procedure: Sistrunk's procedure
Specialty: Surgery

Objective: Rare disease





Background: Thyroglossal duct cyst is a common congenital anomaly of the thyroid gland, usually found centrally. The presence of malignancy occurring in a thyroglossal duct cyst is a rare condition, accounting only for 1% of all cases of thyroglossal duct cyst. This report is of a rare case of papillary carcinoma arising in a thyroglossal duct cyst and includes a review of the literature.

Case Report: A 27-year-old female patient was referred to our department with a painless cystic mass in the neck. After initial physical examination and endocrinology investigations, a fine needle aspiration (FNA) of the cyst was performed. Cytology showed a papillary neoplasm. The patient underwent total thyroidectomy and surgical excision of the thyroglossal duct cyst (the Sistrunk's procedure). Histopathology of the surgical excision specimen showed a thyroglossal duct cyst with a maximum diameter of 7.5 cm containing a primary invasive papillary carcinoma, measuring 1.5 cm in diameter that infiltrated into the cyst wall. The remaining thyroid gland was normal.

Conclusions: Thyroglossal duct carcinoma, most commonly papillary carcinoma, is a rare condition that should be considered in patients presenting with cystic midline neck masses. Surgery and complete excision is the main treatment and the optimal patient management includes multidisciplinary consultation in order to improve survival. The diagnosis of malignancy is made postoperatively, as in the present case.

MeSH Keywords: Carcinoma, Papillary • Thyroglossal Cyst • Thyroidectomy

Full-text PDF: <https://www.amjcaserep.com/abstract/index/idArt/907313>

 2296   4  30



Background

During the third week of fetal life, the thyroid gland arises from a midline endodermal invagination of the foregut, at the level of the foramen caecum [1]. Thyroglossal duct cysts are the most common anomaly in thyroid development [2]. During childhood, 70% of midline masses in the neck, and in adults 7% of midline masses in the neck are thyroglossal duct cysts [3]. Thyroid carcinoma is a rare complication of untreated thyroglossal duct cysts, affecting less than 1% of cysts [4,5]. Initially suspected to be metastases from cancers of the main thyroid gland, these *de novo* tumors can exhibit biological behavior similar to their primary gland counterparts [1].

The most common primary thyroglossal duct cyst carcinoma is papillary carcinoma (75-80%), but other tumor types of primary tumor do occur, such as mixed papillary-follicular carcinomas (7%), squamous cell carcinoma (5%), follicular carcinoma (1.7%); Hürthle cell carcinoma and anaplastic carcinoma (0.9%) have also been reported [6]. In a similar way to thyroglossal duct cysts, thyroglossal duct cyst carcinomas often present as an asymptomatic mass in the midline of the neck, although there are reported cases of these tumors arising in a lateral location [7]. Dysphagia, dysphonia, weight loss, or rapid growth in size, are signs of malignancy [8].

The most common surgical procedure used for a thyroglossal duct cyst is Sistrunk's procedure consisting of excision of the thyroglossal duct cyst, the central portion of the body of the hyoid bone, and a core of tissue around the thyroglossal tract to open into the oral cavity at the foramen cecum [9]. Sistrunk's procedure, is performed as a stand-alone procedure in low-risk patients, and only high-risk patients are likely to undergo an additional total thyroidectomy and postoperative radioactive iodine ablation therapy [10].

This report is of a rare case of papillary carcinoma arising in a thyroglossal duct cyst and includes a review of the literature.

Case Report

A 27-year-old Caucasian woman was referred to our department to investigate and treat a painless anterior midline cervical mass, which had been gradually increasing in the past six months (Figure 1). The patient's medical history included a severe autism spectrum disorder and intellectual disability. Physical examination showed a well-demarcated, mobile, midline cervical tumor of about six centimeters in diameter. Thyroid gland palpation was otherwise normal, and no cervical lymphadenopathy or tongue protrusion were noted.

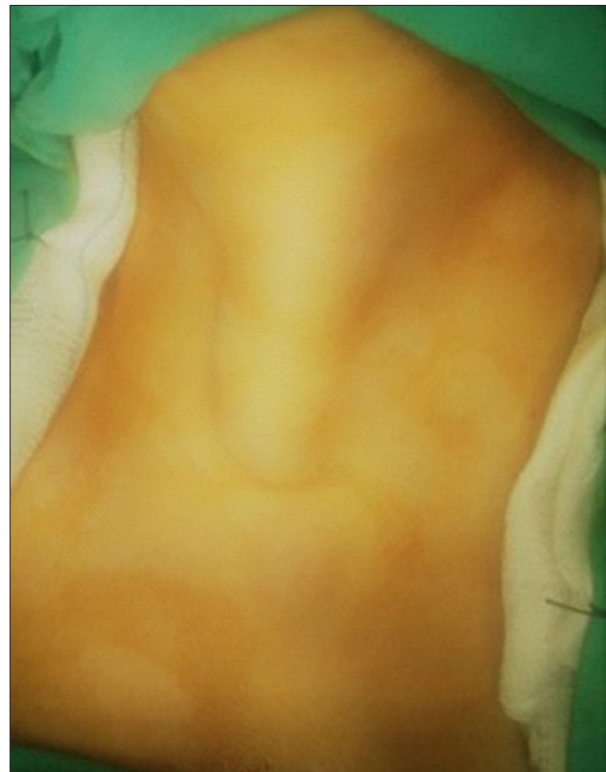

Figure 1. A painless, well-demarcated, anterior midline cervical mass measuring 6 cm in diameter, and gradually increasing in the past six months.

A full imaging workup was performed. Thyroid function and laboratory tests were normal. Ultrasonography identified a 6 cm multilocular midline thyroglossal duct cyst. To further investigate the mass and plan a potential surgical procedure, a computed tomography (CT) imaging scan was undertaken and led to similar findings (Figure 2). Fine-needle aspiration (FNA) and cytology of the cystic lesion showed cells that were suspicious for a papillary neoplasm with that were non-diagnostic for malignancy. A thyroid technetium scan showed a euthyroid multinodular goiter.

Following endocrinology consultation, the patient underwent total thyroidectomy and surgical excision of the thyroglossal duct cyst using the Sistrunk procedure; these surgical procedures were uneventful (Figure 3). After a long hospitalization due to postoperative pulmonary infection and development of respiratory distress, the patient was discharged on postoperative day 19. The histopathology of the surgical excision specimen showed a thyroglossal duct cyst with a maximum diameter of 7.5 cm containing a primary invasive papillary carcinoma. The carcinoma was 1.5 cm in diameter and infiltrated unto the cyst wall (Figure 4). The histology of the remainder of the thyroid gland was normal. The specimen included one parathyroid gland, which was found to contain an incidental parathyroid adenoma.

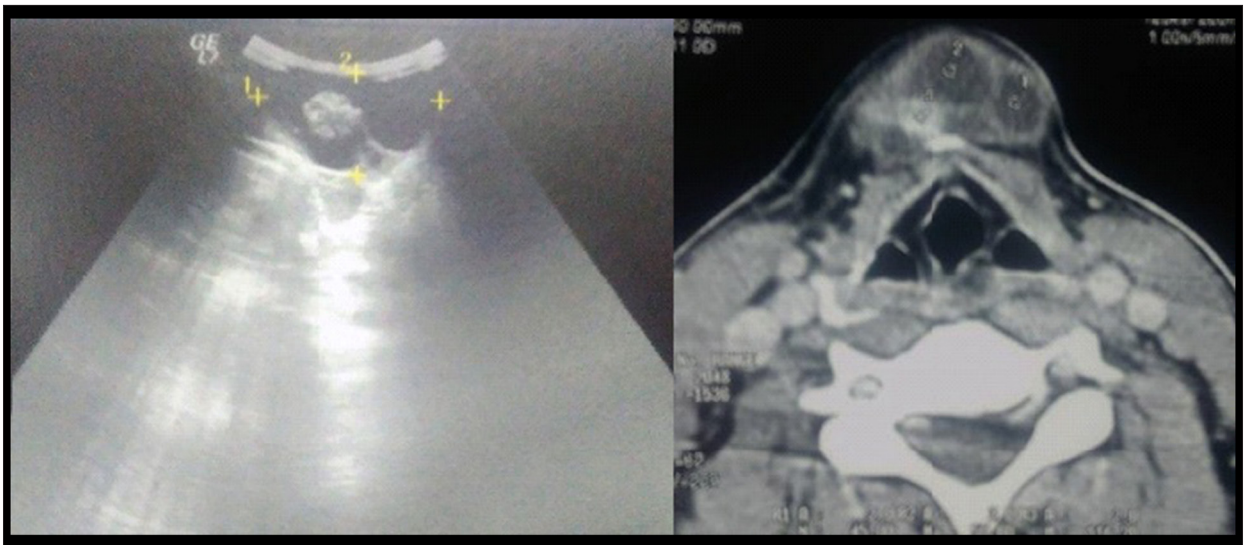


Figure 2. Ultrasound and computed tomography (CT) imaging of the neck confirmed a 6 cm diameter multilocular, midline, thyroglossal duct cyst.

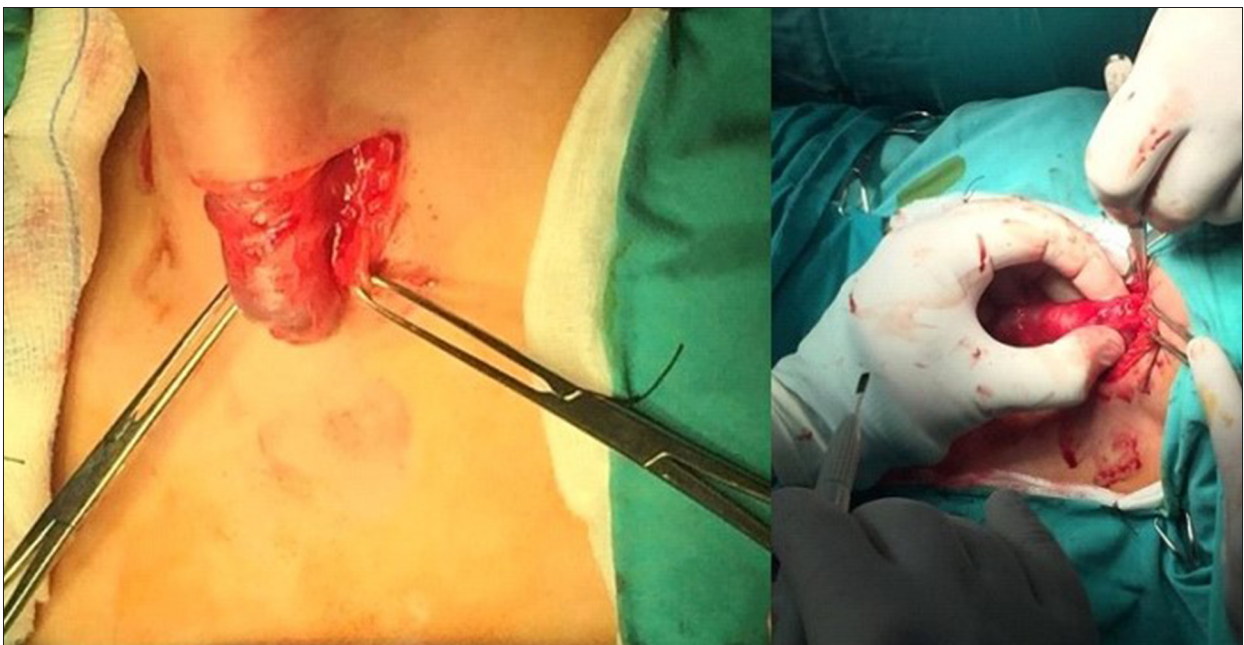

Figure 3. Total thyroidectomy and surgical excision of the thyroglossal duct cyst (Sistrunk's procedure).

The patient was referred to the Nuclear Medicine Department and Endocrinology Department for multidisciplinary further management and follow-up. Due to the patient's neurological background and given the early stage of the disease (tumor size <4.0 cm) no soft tissue invasion, and no distant or lymphatic metastases, no postoperative radioactive iodine ablation therapy was added. Currently, at 12 months of follow-up, the patient remains free from recurrent thyroid tumor.

Discussion

The thyroid gland is the first endocrine gland to develop, with its development commencing in the third week of gestation [1,10]. Embryologically, the thyroid gland arises from the floor of the pharyngeal gut (foramen caecum) and descends as a bilobed diverticulum remaining connected to the gut by a narrow canal, the thyroglossal duct [11]. Normally, the thyroglossal duct obliterates and disappears by the tenth week of gestation [10]. A thyroglossal remnant can remain in the form of a cyst, a tract or duct, or as ectopic thyroid within a cyst or

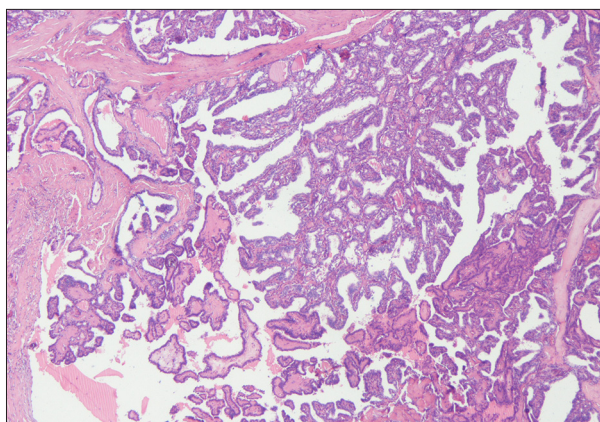


Figure 4. Photomicrograph of the histopathology of the papillary thyroid carcinoma arising in the thyroglossal duct cyst. Hematoxylin and eosin (H&E).

duct. Thyroglossal duct cysts are the most common anomalies in the neck [11].

Since it was first described in 1920, total thyroidectomy and surgical excision of the thyroglossal duct cyst (the Sistrunk procedure) is the gold standard treatment and involves the removal of the entire duct and of a portion of the hyoid bone [12]. Ellis and Van Nostrand demonstrated an intimate connection between the thyroglossal tract and the hyoid bone, rendering Sistrunk's operation the only certain way of completely removing all remnants of the thyroglossal duct and reducing recurrences following surgery for thyroglossal duct cysts and fistulae [13]. The association of recurrence of thyroglossal duct cysts with failure to remove the central portion of the hyoid bone has been well documented [14].

Infection and sinus formation are common complications of thyroglossal duct cysts, but the development of malignancy within a cyst is very rare [15]. The first case of thyroid carcinoma arising in thyroglossal duct remnant was reported in 1911 [16]. Thyroid carcinoma arising in thyroglossal duct cyst is a rare entity, with around 250 cases having been published in the world literature [17]. The cause of thyroglossal duct cyst carcinoma is unclear, although the predominating theories are either metastatic disease from an occult primary or spontaneous development from ectopic thyroid tissue found within the thyroglossal duct cyst wall [18]. Malignancy occurs in about 1% of thyroglossal duct cysts and arises slightly more often in women [19]. The mean age of patients is in the fourth decade of life, and the tumor can be located anywhere along the embryological route of descent of the thyroid gland [16].

In the current case report, the patient was a 27-year-old woman, who was younger than the mean age of presentation for this tumor, and with a midline cervical mass gradually increasing during the previous six months. The majority of thyroid

tumors that arise in thyroglossal duct cysts are papillary tumors, with less than 5% being of squamous cell type [20]. The co-existence of thyroglossal duct cyst and thyroid carcinoma is found to occur at a rate of between 0-25% [21]. The pre-operative evaluation of patients who are discovered to have a thyroglossal duct cyst should include a complete physical examination, accurate head and neck examination, palpation of the thyroid gland, thyroid function tests, and a thyroid scan [22]. In the present case, thorough preoperative evaluation, as well as pathological examination of the thyroid, showed no pathologic findings in the remaining thyroid gland, thyroid function tests were normal, and ultrasonography showed no other thyroid lesions.

The initial symptoms of thyroglossal duct cyst carcinoma are indistinguishable from a benign thyroglossal duct cyst [8]. A rapid increase in growth or the presence of a firm, palpable mass may be signs of malignancy [22]. Thyroglossal duct cyst carcinoma should be suspected when the lesion is hard, fixed, and irregular [23]. Computed tomography (CT) scan, neck nuclear magnetic resonance imaging (MRI) and ultrasound may show a solid mass with invasive features and may play an important role in pre-operative diagnosis and staging of malignancy, and in the planning of primary treatment [22]. In this present case, the clinical presentation was similar to that of a benign cyst, as the lesion was well demarcated and mobile, and no cervical lymphadenopathy was noted. Some authors recommend fine-needle aspiration cytology (FNAC) of core needle biopsy as safe, well-tolerated, and cost-effective procedures for diagnosing thyroglossal duct lesions [23]. Fine needle aspiration and cytology in this case, showed a papillary neoplasm but did not confirm malignancy. There was no clinical suspicion of malignancy and imaging could not show invasion of the capsule or adjacent structures, but confirmed that there were no abnormal findings of the remaining thyroid gland.

The differential diagnosis of thyroglossal duct cyst includes branchial cleft cyst, lipoma, metastatic thyroid carcinoma, dermoid cyst, sebaceous cyst, and an enlarged lymph node [24]. Thyroglossal duct carcinomas should also be distinguished from papillary carcinoma arising from the tip of the pyramidal lobe [5]. The main difficulty encountered with a cancer arising from a thyroglossal duct cyst is that the diagnosis is usually made intraoperatively or from definitive histopathology [9].

According to the Widström et al. criteria, the diagnosis of primary carcinoma of the thyroglossal duct includes the histological identification of thyroglossal duct carcinoma, demonstration of the normal epithelial lining of the thyroglossal duct, normal thyroid follicles within walls of the cyst, normal thyroid tissue adjacent to the tumor, and no findings of primary thyroid carcinoma on histopathological examination of the thyroid gland, all of which were demonstrated in this case [25].

Microscopic examination of the specimen in this present case revealed infiltration of the cystic wall and normal thyroid gland, confirming the diagnosis of primary papillary carcinoma arising in a thyroglossal duct cyst.

The definitive management of thyroglossal duct cyst carcinoma remains controversial, with concern regarding the treatment strategy for the management of the thyroid gland. While some authors consider Sistrunk's procedure to be adequate and curative in most cases, others recommend that total thyroidectomy should be performed in case of thyroglossal duct cyst carcinoma, due to the high incidence of associated papillary or mixed carcinomas in the thyroid gland [22]. According to Balalaa et al., total thyroidectomy is indicated, whether or not the thyroid is involved clinically or radiologically, as it aids staging and can facilitate the detection of metastases, and the risk of injury to the recurrent laryngeal nerve or parathyroid glands in skilled hands is very uncommon, with the greatest risk of injury occurring in redo surgery [3]. The rationale for adding thyroid resection to every patient with a thyroglossal duct cyst carcinoma is based on three main considerations, the presence of concomitant thyroid malignancy in the main thyroid gland, the utilization of radioactive iodine as an adjuvant treatment, and the role of serum thyroglobulin, as a follow-up marker for thyroid cancer [1].

Some authors advocate a surgical approach that is tailored to the patient and is based on risk group stratification. Accordingly, Sistrunk's procedure is performed as a stand-alone procedure in the setting of a clinically and radiologically normal thyroid gland in low-risk patients with low-risk tumors, for patients who are age <45 years, who have no history of radiation exposure, a tumor size <4.0 cm, no soft tissue invasion, no distant or lymphatic metastases, and the absence of aggressive tumor histology. However, selecting a subset of patients free from the risk of concomitant thyroid cancer or free from the need for radioactive iodine ablation therapy, is a difficult task [10]. Tharmabala and colleagues propose a risk staging strategy into three classifications: for low-risk, observe and wait; for moderate risk, total thyroidectomy, hormonal suppressing treatment, and radioactive iodine; for the high-risk group, vertical lymph node dissection in addition to the other treatments [25]. The finding a concomitant primary thyroid cancer, invading into the cyst wall, and finding tumors larger than 1.0 cm in diameter are indications for total thyroidectomy, according to Dan and colleagues [26]. There remains some debate in the management of primary papillary thyroid carcinomas that are less than 1 cm in size, with some suggesting hemi-thyroidectomy alone is enough [26]. As with the controversy over the extent of thyroidectomy, the benefit of radioactive iodine for low-risk

patients remains unclear. Radioactive iodine may be beneficial for patients with larger tumors and metastatic disease, but the increased risk of secondary malignancies in low-risk patients, including children, where the long-term benefit of radioactive iodine is questionable, means that careful patient selection for radioactive iodine ablation therapy is necessary [1].

In this case, the authors chose total thyroidectomy and Sistrunk's procedure as a treatment strategy because of the cyst's size (6 cm), the perioperative finding of contact between the cyst and the thyroid gland, and last but not least, because of the patient's history of autism spectrum disorder, which would render a re-operation, as well as complementary iodine therapy complex. Radical neck dissection might add increased morbidity and was not performed, given the lack of evidence of cervical lymph node involvement.

Metastatic spread is very uncommon, and the prognosis is usually very good [15,27]. In a review by Patel et al., with a median follow-up of 71 months, the 5-year and 10-year Kaplan-Meier overall survival (OS) was 100% and 95.6%, respectively [28].

Regional lymph node metastases of thyroglossal duct cyst carcinoma occur in only 7.7% of reported cases, and local invasion rarely occurs [2]. The risk of metastasis is less than 2% of cases [6]. Careful long-term follow-up is important as papillary carcinoma is usually a low-grade malignancy and recurrences can be successfully treated with careful patient follow-up [29]. All patients must have a neck scan and be re-assessed every six months during the first year and annually after that [7]. Park proposed that follow-up procedures consist of physical examination, ultrasound of the surgical region, and thyroid, and total body scintigraphy [30].

Conclusions

This report adds to the published literature of cases of thyroglossal duct cyst carcinoma, which is a rare tumor, often diagnosed postoperatively as an incidental finding on histopathological examination. Surgery remains the cornerstone of treatment. Currently, there are no evidence-based consensus clinical guidelines that have been established on the optimal surgical approach and further management. A multidisciplinary approach should be considered to safely identify high-risk patients, who will require a more aggressive treatment approach.

Conflict of interest

None.

References:

1. Carter Y, Yeutter N, Mazeh H: Thyroglossal duct remnant carcinoma: Beyond the sistrunk procedure. *Surg Oncol*, 2014; 23(3): 161–66
2. Aghaghazvini L, Mazaher H, Sharifian H et al: Invasive thyroglossal duct cyst papillary carcinoma: A case report. *J Med Case Rep*, 2009; 3: 9308
3. Balalaa N, Megahed M, Ashari MAI, Branicki F: Thyroglossal duct cyst papillary carcinoma. *Case Rep Oncol*, 2011; 4(1): 39–43
4. Branstetter B, Weissman J, Kennedy T, Whitaker M: The CT appearance of thyroglossal duct carcinoma. *Am J Neuroradiol*, 2000; 21(8): 1547–50
5. Chu YC, Han JY, Han HS et al: Primary papillary carcinoma arising in a thyroglossal duct cyst. *Yonsei Med J*, 2002; 43(3): 381–84
6. Kalyani R, Hebbar A, Murthy S: Primary papillary carcinoma arising in thyroglossal duct cyst: A rare case report. *Nat J Lab Med*. 2015;4(3): 27-29.
7. Chala A, Alvarez A, Sanabria A, Gaitan A: Primary papillary carcinoma in thyroglossal ducts. case reports and literature review. *Acta Otorrinolaringol Esp*, 2016; 67(2): 102–6
8. Garcia M, Yanez K, Dominquez A et al: [Carcinoma papilar sobre quiste de conducto tirogloso.] *Acta Otorrinolaringol Esp*, 2001; 52: 75–78 [in Spanish]
9. Kandogan T, Erkan N, Vardar E: Papillary carcinoma arising in a thyroglossal duct cyst with associated microcarcinoma of the thyroid and without cervical lymph node metastasis: A case report. *J Med Case Rep*, 2008; 2: 42
10. Bakkar S, Biricotti M, Stefanini G et al: The extent of surgery in thyroglossal duct carcinoma. *Langenbecks Arch Surg*, 2017; 402(5): 799–804
11. Kennedy T, Whitaker M, Wadih G: Thyroglossal duct carcinoma: A rational approach to management. *Laryngoscope*, 1998; 108: 1154–58
12. Sistrunk WE: The surgical treatment of cysts of the thyroglossal tract. *Ann Surg*, 1920; 71: 121–22
13. Ellis P, Van Nostrand P: The applied anatomy of thyroglossal tract remnants. *Laryngoscope*, 1977; 87(5): 765–70
14. Howard DJ, Lund VJ: Thyroglossal ducts, cysts and sinuses: A recurrent problem. *Ann R Coll Surg Engl*, 1986; 68(3): 137–38
15. Thornton C: Papillary carcinoma arising in a thyroglossal duct. *Ulster Med J*, 1989; 58(1): 111–13
16. Ramirez Plaza CP, Dominguez Lopez M, Carrasco CEG et al: Management of well-differentiated thyroglossal remnant thyroid carcinoma: Time to close the debate? Report of five new cases and proposal of a definitive algorithm for treatment. *Ann Surg Oncol*, 2006; 13(5): 745–52
17. Chrisoulidou A, Iliadou P, Doumala E et al: Thyroglossal duct cyst carcinomas: Is there a need for thyroidectomy? *Hormones*, 2013; 12(4): 522–28
18. Underwood HJ, Williams DM, Kundel A: Papillary thyroid carcinoma within thyroglossal duct cyst: Case report and review of literature. *JSM Head Neck Cancer Cases Rev*, 2016; 1(2): 1006
19. Yang JY, Haghiri S, Wanamaker J, Powers C: Diagnosis of papillary carcinoma in a thyroglossal duct cyst by fine-needle aspiration biopsy. *Arch Pathol Lab Med*, 2000; 124: 139–42
20. Wexler M: Surgical management of thyroglossal duct carcinoma: is an aggressive approach justified? *Can J Surg*, 1996; 39(4): 263–64
21. Tew S, Reeve TS, Poole AG, Delbridge E: Papillary thyroid carcinoma arising in thyroglossal duct cysts: Incidence and management. *Aust N Z J Surg*, 1995; 65(10): 717–18
22. Gebbia V, Di Gregorio C, Attard M: Thyroglossal duct cyst carcinoma with concurrent thyroid carcinoma: A case report. *J Med Case Rep*, 2008; 2: 132
23. Pietruszewska W, Wągrowka-Danilewicz M, Józefowicz-Korczyńska M: Papillary carcinoma in thyroglossal duct cyst with uninvolved thyroid. Case report and review of the literature. *Arch Med Sci*, 2014; 10(5): 1061–65
24. Moorthy NS, Arcot R: Thyroglossal duct cyst – more than just an embryological remnant. *Indian J Surg*, 2011; 73(1): 28–31
25. Tharmabala M, Kanthan R: Incidental thyroid papillary carcinoma in a thyroglossal duct cyst – management dilemmas. *Int J Surg Case Rep*, 2013 4(1): 58–61
26. Dan D, Rambally R, Naraynsingh V et al: A case of malignancy in a thyroglossal duct cyst – recommendations for management. *J Natl Med Assoc*, 2012; 104(3,4): 211–14
27. Chauchan A, Kakkar S, Gupta AK: Papillary carcinoma thyroid in a thyroglossal duct. *Med J Armed Forces India*, 2009; 65(1): 82–83
28. Choi Y, Kim TY, Song DE et al: Papillary thyroid carcinoma arising from a thyroglossal duct cyst: A single institution experience. *Endocrine J*, 2013; 60(5): 665–70
29. Thakar A, Tandon DA, Sharma S: Papillary carcinoma in a thyroglossal duct: Report of a case and review of literature. *Indian J Otolaryngol Head Neck Surg*, 1999; 51(4): 86–88
30. Park MH, Yoon JH, Jegal YJ, Lee JS: Papillary thyroglossal duct cyst carcinoma with synchronous occult papillary thyroid microcarcinoma. *Yonsei Med J*, 2010; 51(4): 609–11