





RESEARCH ARTICLE

A meta-analysis of narrow-band imaging for the diagnosis of primary nasopharyngeal carcinoma [version 1; referees: 2 approved]

David CM Yeung , Alexander C Vlantis, Eddy WY Wong, Michael CF Tong, Jason YK Chan 

Department of Otorhinolaryngology, Head & Neck Surgery, Prince of Wales Hospital, Chinese University of Hong Kong, Shatin, New Territories, Hong Kong

v1 First published: 18 Jun 2018, 7:759 (doi: [10.12688/f1000research.15183.1](https://doi.org/10.12688/f1000research.15183.1))
 Latest published: 18 Jun 2018, 7:759 (doi: [10.12688/f1000research.15183.1](https://doi.org/10.12688/f1000research.15183.1))

Abstract

Background: Narrow band imaging (NBI), an endoscopic technique featuring an augmented definition of microvasculature and mucosal patterns. NBI is increasingly advocated as a tool to characterize neoplasia and intestinal metaplasia in endoscopic standards, such as for colorectal polyps and tumors. Recently NBI has also been studied in the detection of Nasopharyngeal Carcinoma (NPC). Here we aimed to assess the diagnostic utility of NBI for the diagnosis of NPC.

Methods: A meta-analysis of studies comparing narrow-band imaging and white light endoscopy in the diagnosis of primary nasopharyngeal carcinoma was performed. The review process involved two independent investigators. The databases used were MEDLINE, PubMed, the Cochrane library, Embase, and the Web of Science. Statistical analysis was performed with OpenMetaAnalyst, MetaDiSc version 1.4, and Medcalc version 17.9.7.

Results: Five studies including 2480 patients were included. The sensitivity and specificity for narrow-band imaging were 0.90 (0.73-0.97) and 0.95 (0.81-0.99) respectively. The positive likelihood ratio and negative likelihood ratio were 18.82 (0.31-82.1) and 0.08 (0.02-0.31). For white light endoscopy, the sensitivity and specificity were 0.77 (0.58-0.89) and 0.91 (0.79-0.96). The positive likelihood ratio was 7.61 (3.61-16.04), and the negative likelihood ratio was 0.21 (0.11-0.39). The odds ratio for detection rates between narrow-band imaging and white light endoscopy was 4.29 (0.56-33.03, p = 0.16). Area under the curve for narrow-band imaging was 0.98 (SE: 0.02), and for white light it was 0.93 (SE: 0.03). There was no significant difference in the receiver operating characteristic curves between the two modalities (p = 0.14).



Conclusion: Narrow-band imaging showed a higher sensitivity and positive likelihood ratio for the diagnosis of nasopharyngeal carcinoma. However, there was no significant difference in detection rates compared to white light endoscopy. Further investigation with a uniform diagnostic criteria and terminology is needed for narrow-band imaging in the diagnosis of nasopharyngeal carcinoma.



Keywords

Nasopharyngeal carcinoma, narrow-band imaging, endoscopy, meta-analysis

Open Peer Review

Referee Status:  

	Invited Referees	
	1	2
version 1 published 18 Jun 2018	 report	 report

- 1 **Chwee Ming Lim** , National University of Singapore, Singapore
- 2 **Daniel Clayburgh** , Oregon Health and Science University, USA
Jennifer Christenson, Oregon Health and Science University, USA

Discuss this article

Comments (0)

Corresponding author: Jason YK Chan (jasonchan@ent.cuhk.edu.hk)

Author roles: **Yeung DC:** Conceptualization, Data Curation, Formal Analysis, Investigation, Methodology, Project Administration, Resources, Validation, Visualization, Writing – Original Draft Preparation, Writing – Review & Editing; **Vlantis AC:** Conceptualization, Data Curation, Formal Analysis, Investigation, Methodology, Project Administration, Supervision, Writing – Review & Editing; **Wong EW:** Conceptualization, Data Curation, Formal Analysis, Investigation, Methodology, Project Administration, Resources, Supervision, Writing – Review & Editing; **Tong MC:** Conceptualization, Data Curation, Formal Analysis, Investigation, Methodology, Project Administration, Supervision, Validation, Writing – Review & Editing; **Chan JY:** Conceptualization, Data Curation, Formal Analysis, Investigation, Methodology, Project Administration, Supervision, Validation, Writing – Review & Editing

Competing interests: No competing interests were disclosed.

How to cite this article: Yeung DC, Vlantis AC, Wong EW *et al.* **A meta-analysis of narrow-band imaging for the diagnosis of primary nasopharyngeal carcinoma [version 1; referees: 2 approved]** *F1000Research* 2018, 7:759 (doi: [10.12688/f1000research.15183.1](https://doi.org/10.12688/f1000research.15183.1))

Copyright: © 2018 Yeung DC *et al.* This is an open access article distributed under the terms of the [Creative Commons Attribution Licence](https://creativecommons.org/licenses/by/4.0/), which permits unrestricted use, distribution, and reproduction in any medium, provided the original work is properly cited. Data associated with the article are available under the terms of the [Creative Commons Zero "No rights reserved" data waiver](https://creativecommons.org/licenses/by/4.0/) (CC0 1.0 Public domain dedication).

Grant information: The author(s) declared that no grants were involved in supporting this work.

First published: 18 Jun 2018, 7:759 (doi: [10.12688/f1000research.15183.1](https://doi.org/10.12688/f1000research.15183.1))

Introduction

Nasopharyngeal carcinoma (NPC) is a common head and neck cancer in the southeast Asia¹. The age-standardized incidence rate in Hong Kong is 12.6 per 100,000 for males and 3.9 per 100,000 for females². The current standard for NPC diagnosis is histological from a white light endoscopy (WL) directed biopsy³. Large tumors are easy to identify. Early and small tumors might be impossible to differentiate from adenoidal tissue or normal nasopharyngeal mucosa⁴.

Narrow-band imaging (NBI) is an imaging technique that uses two specific wavelengths of light that are strongly absorbed by hemoglobin, allowing improved visualization and delineation of mucosal microvascular patterns⁵. This technique, which has been used for the detection of adenomas in the gastrointestinal tract, has the potential to reduce the false negative rates associated with conventional white light endoscopy⁶. If the sensitivity of abnormal vasculature with the assumed overlying mucosal malignancy seen on NBI was able to surpass that of abnormal morphology of the nasopharynx seen on WL, the false negative findings would be reduced and unnecessary biopsies and their potential complications avoided⁷.

NBI has been described in the early detection of other head and neck cancers, including squamous cell carcinomas (SCC) of the larynx, floor of mouth⁸, oropharynx, and hypopharynx⁹. Among these studies, the finding of brownish spots was the most common descriptive morphology followed by irregular

vascular patterns. Similar NBI abnormalities have been adapted to identify primary NPC. The aim of this study was to use a meta-analysis to evaluate the diagnostic utility of NBI compared to conventional WL for the detection and diagnosis of NPC.

Methods

Eligibility and data extraction

We included all prospective studies detecting NPC by using NBI compared with standard WL. Excluded studies were reviews, data reported only as abstracts, non-diagnostic studies, those that did not include histological confirmation or extractable raw data, and retrospective studies. The publications, their relevance, and eligibility were determined independently by DCMY and JYKC. Application of the inclusion and exclusion criteria was undertaken independently by both reviewers, and any difference of opinion was resolved by discussion between the reviewers. Data extraction was done by DCMY and JYKC. Included studies were assessed for quality. The PRISMA diagram is shown in Figure 1. The study was exempt from Institutional Review Board approval as no patient identifiable data was utilized.

Search strategy

MEDLINE, PubMed, the Cochrane library, Embase, and the Web of Science were searched to identify studies in which narrow band imaging endoscopy was used to look for nasopharyngeal carcinoma compared with white light endoscopy. We

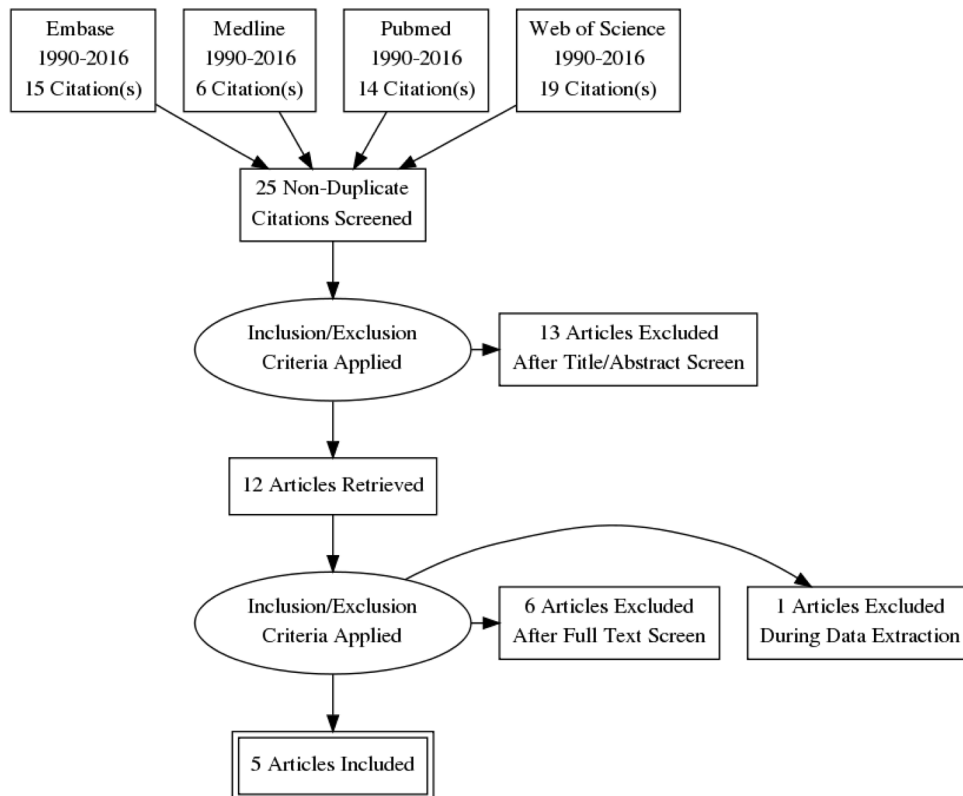


Figure 1. This PRISMA Chart was constructed to illustrate the workflow of the review process.

used the search terms ‘narrow band imaging,’ ‘narrow band imaging vs white light imaging,’ and ‘nasopharyngeal carcinoma’. As an example, for MEDLINE, we searched the terms “Narrow Band Imaging” and “Nasopharyngeal Neoplasms” separately. We subsequently combined them as an “AND” search, yielding six articles for that specific database. We only included prospective trials of NBI versus standard WL. Only articles in English were included. Reviewers were not blinded to the names of authors, institutions, or journals. The reference lists of these articles were searched for additional relevant articles.

Statistical analysis

A DerSimonian-Laird diagnostic random effects model was adopted for statistical analysis of sensitivity, specificity, positive and negative likelihood ratios for NBI and WL respectively. Detection rates, defined by true positives divided by sample size, were analyzed and compared between NBI and WL using a binary random effects model. Receiver operating characteristic (ROC) curves were constructed and compared with the Hanley and McNeil approach. Funnel plots were not constructed as the relatively small number of primary studies available for this meta-analysis would make it difficult to interpret¹⁰. Statistical analysis was performed with OpenMetaAnalyst version 12.11.14; ROC curves and meta-regression were performed using MetaDiSc version 1.4; ROC curve comparison analysis was performed with Medcalc version 17.9.7.

Results

A total of 2480 patients, 61% male and 39% female, were included in our meta-analysis. The mean patient age was 49.5 years. No range was calculated for age and sex as not all studies had included them. Basic demographics are listed in [Table 1](#). The indications for nasoendoscopy in the studies are shown in [Table 2](#). Details of endoscopic examination specifics of the included studies are listed in [Table 2](#). A total of 191 patients were diagnosed with NPC. NBI and WL successfully detected 191 and 163 of these cases respectively.

The pooled sensitivity and specificity for NBI was 0.90 (0.73–0.97) and 0.95 (0.81–0.99) respectively as shown in [Figure 2](#). The ROC curve is shown in [Figure 4](#) and has a calculated area under the curve (AUC) of 0.98 (SE: 0.02). The pooled positive likelihood ratio and negative likelihood ratio was 18.82 (4.31–82.06) and 0.08 (0.02–0.31). The pooled diagnostic odds ratio for NBI was 200.13 (32.56–1230.33, $p < 0.001$) with τ^2 3.34, $Q(df=4)$ 23.90, heterogeneity p -value < 0.001 , and I^2 being 83.26.

For WL, the pooled sensitivity and specificity was 0.77 (0.58–0.89) and 0.91 (0.79–0.96) as shown in [Figure 3](#) respectively. The ROC curve is shown in [Figure 5](#), and the AUC calculated as 0.93 (SE: 0.03) The pooled positive likelihood ratio is 7.61 (3.61–16.04) and the negative likelihood ratio is 0.21 (0.11–0.39). The pooled diagnostic odds ratio is 34.00

Table 1. Demographics of included studies.

Study	Country	Patients	Male (%)	Female (%)	Mean age
Vlantis 2016	Hong Kong	156	90 (58%)	66 (42%)	49.5
Wang 2011	Taiwan	79	58 (73%)	21 (27%)	52.9
Wang 2012	Taiwan	106	80 (75%)	26 (25%)	55.6
Wen 2012	Guangzhou, China	285	133 (47%)	152 (53%)	38
Yang 2012	Guangzhou, China	1854	1153 (62%)	701 (38%)	53.1

Table 2. Endoscope examination characteristics.

Study	Endoscopic examination purpose	Endoscope (Olympus medical system)	Light source (Olympus medical system)	Video system (Olympus medical system)	NBI abnormality
Vlantis 2016	Screening	ENF-VQ	CLV-S40 PRO	Visera OTV-S7 PRO	Vascular tufts, dilated, and enlarged vessels
Wang 2011	Screening or surveillance for recurrence	ENF-V2 or VQ	CLV- 160B	CV-160B	Irregular microvascular pattern and side differences including Light crests
Wang 2012	Surveillance for recurrence	ENF-V2 or VQ	CLV- 160B	CV-160B	Well demarcated brown spots and scattered brown spots
Wen 2012	Screening	A500	CLV-S40	CV-160B	Well demarcated brown spots, vessel Irregularity
Yang 2012	Screening	ENF-VT2	CLV-S40Pro	CV 160B	Well demarcated brownish area and scattered brown spots, irregularity of vessels

NBI – Narrow-band imaging

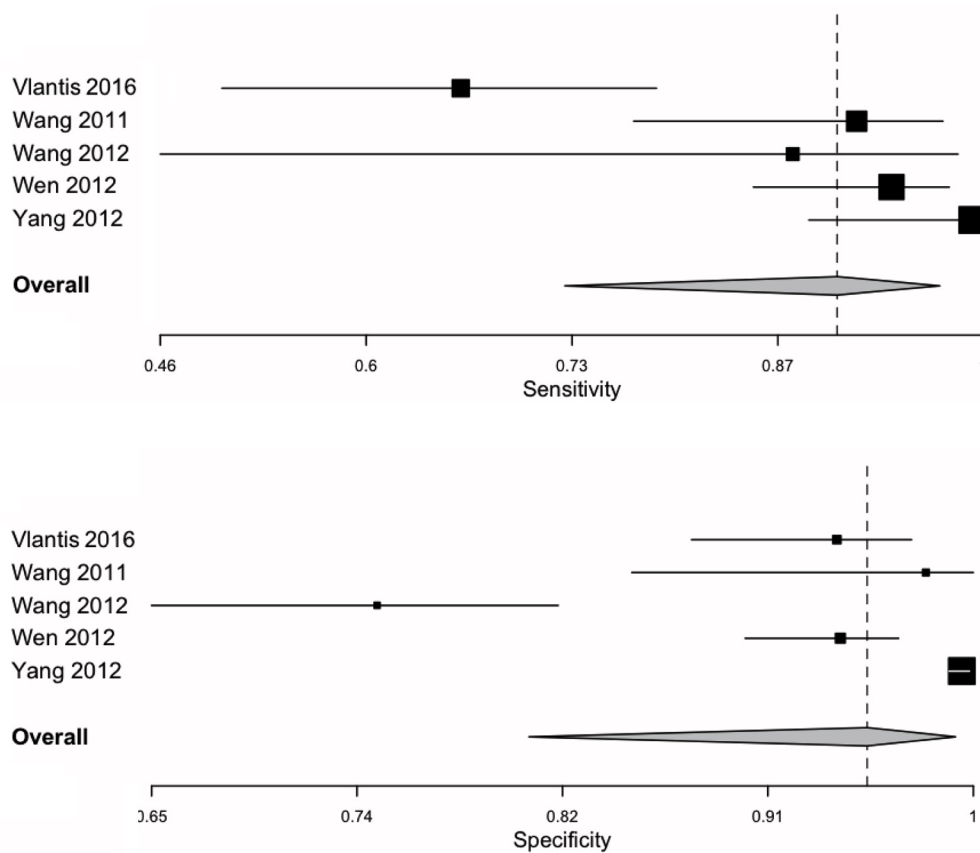


Figure 2. Narrow-band imaging sensitivity and specificity forest plots summarized the individual as well as the pooled sensitivities and specificities for nasendoscopy with narrow band imaging settings.

(15.58–74.21, $p < 0.001$) for WL, with τ^2 0.45, $Q(df=4)$ 9.67, heterogeneity p -value: 0.046, I^2 being 58.63. A summary of pooled statistics and analyses is depicted in Table 3.

For heterogeneity analysis, meta-regression was performed to identify the source of heterogeneity for the following factors: number of patients, percentage of males or females and mean age. However, none of them accounted for heterogeneity in either group.

In the analysis of detection rates between NBI and WL, the odds ratio was 4.29 (0.56–33.03, $p = 0.16$), the τ^2 was 4.35, $Q(df=4)$ was 25.39, heterogeneity p value was <0.001 , and I^2 was 84.24. There was no significant difference between detection rates of NBI and WL. Comparing the ROC curve between and NBI and WL, there was no significant difference ($p = 0.14$).

Dataset 1. OpenMetaAnalyst file contain data analysis performed in this study
<http://dx.doi.org/10.5256/f1000research.15183.d206977>

Discussion

In this meta-analysis comparing NBI to WL for the detection and diagnosis of primary nasopharyngeal carcinoma, our

study found that NBI had a higher specificity, sensitivity, and positive likelihood ratio. However contrary to previous studies, there were no significant differences between NBI and WL for sensitivity analyses and detection rates. Both tests had similar accuracies as indicated by an AUC approaching the value of 1. This likely reflects the fact that WL is an established examination to evaluate the nasopharynx, and that there are no significant advantages of using current otolaryngological NBI systems to detect NPC, perhaps also indicative of the lack of magnification that is available with larger diameter gastrointestinal endoscopes but not with the smaller nasopharyngeal endoscopes.

Early detection of NPC is important given the differences in treatment regimens and prognoses for early versus late NPC. Modalities useful in the screening, diagnosis and staging of primary NPC that supplement nasoendoscopy including MRI, CT, PET-CT, and plasma Epstein-Barr virus (EBV) DNA¹¹. However, one or more of these may not always be readily available, may be time consuming, and may be costly in the routine diagnosis of NPC. Plasma EBV DNA has recently been shown to be a highly sensitive and specific screening tool for NPC¹, but again the technology to assess plasma EBV DNA has not been standardized to make this a definitively useful investigation. For these reasons, NBI has the potential to be useful by improving the endoscopic detection of primary NPC.

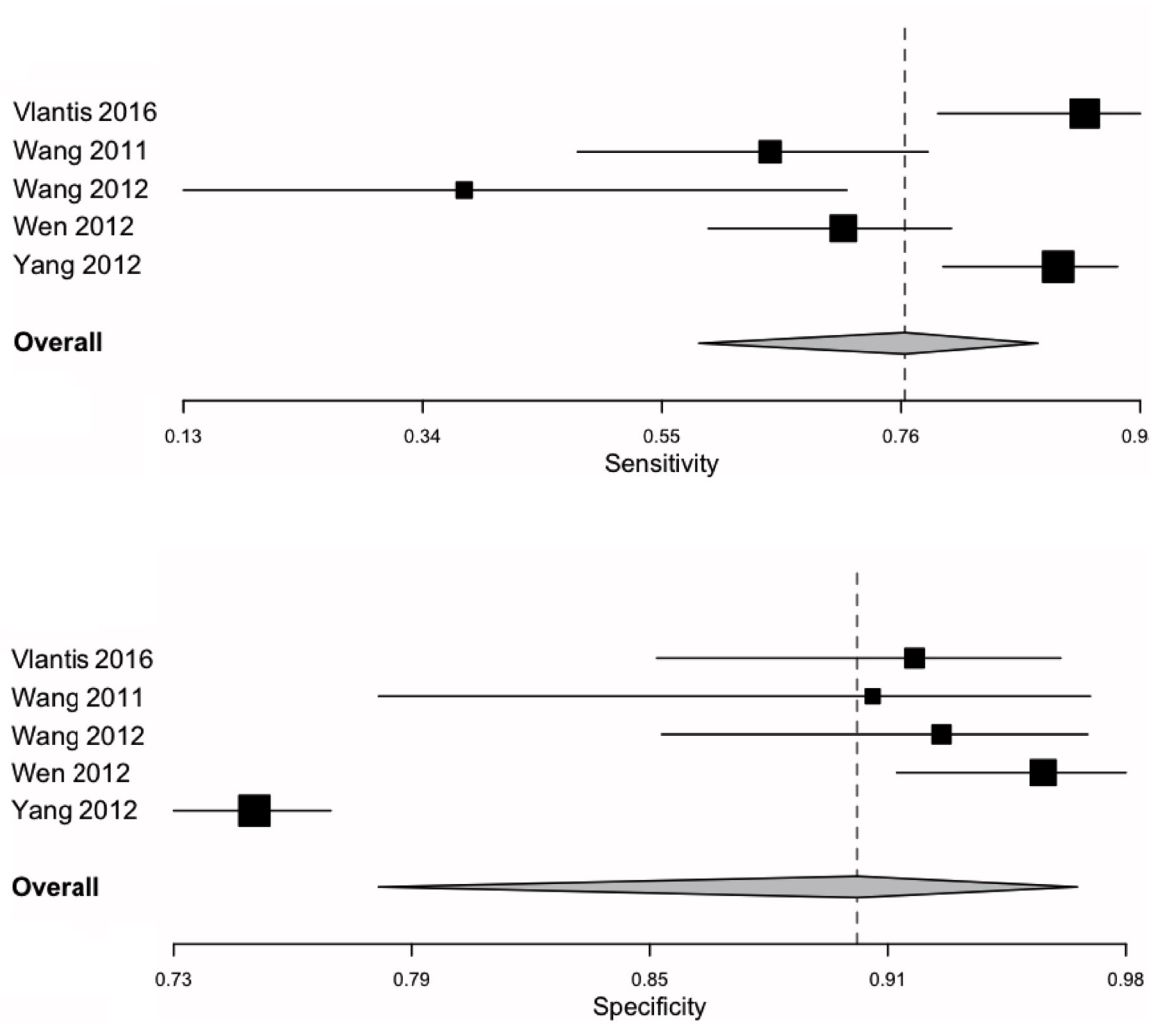


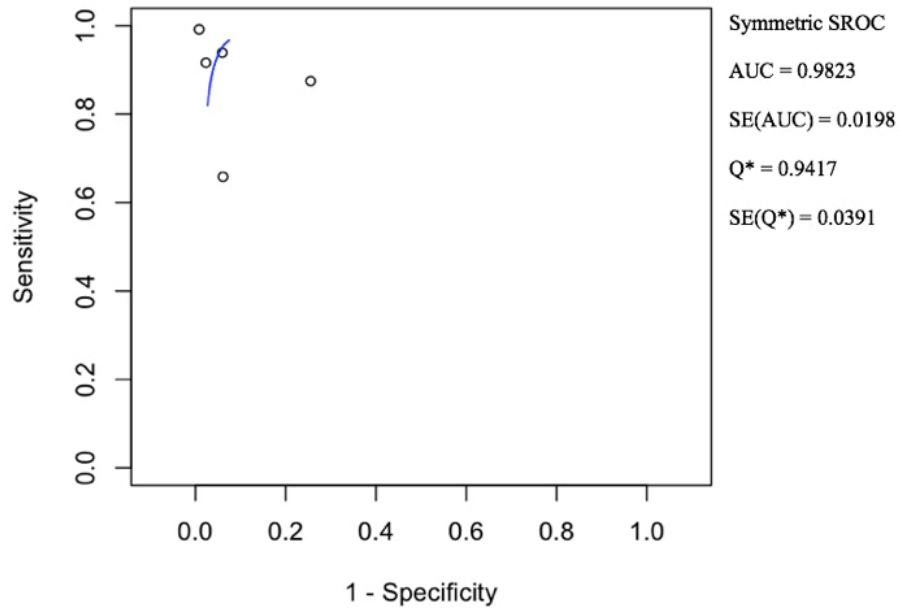
Figure 3. White light endoscopy sensitivity and specificity forest plots summarized the individual as well as the pooled sensitivities and specificities for nasoendoscopy with conventional white light settings.

Endoscopes used in the examination of the nasopharynx are usually 4mm in diameter, unlike gastrointestinal endoscopes which are 9 to 12mm in diameter. As current NBI endoscopes are distal sensing endoscopes, the smaller diameter limits the size of the distal sensing chip at the tip of the endoscope, thus limiting the pixel density and resolution and thus the ability to detect smaller lesions¹². The endoscopes used in this study might not have had sufficient magnification to observe the microvascular patterns of the nasopharynx in sufficient detail when compared to gastrointestinal endoscopy¹³. With the advance of ultra-high definition distal chips now offering a resolution of up to 4k, and with 8k resolution under development¹⁴, the utility of NBI in the detection and diagnosis of primary NPC may improve significantly.

A further potential issue with NBI being used as a screening tool for the detection of NPC is that NBI endoscopy requires specific training and there is a learning curve. NBI

images are initially exceptionally difficult to interpret, and without uniform diagnostic criteria, are not particularly helpful. The interpretation of abnormal features such as vascular tufts or tortuous vessels could theoretically affect accuracy. One concern is that NBI might lead to an increased number of unjustified biopsies due to false positive findings of NBI abnormalities¹⁵. NBI was however shown to have a high specificity of 0.95 in our study. This could be either due to the fact that the endoscopists included in this study were already well trained and experienced, or that the learning curve was less of a problem than was postulated.

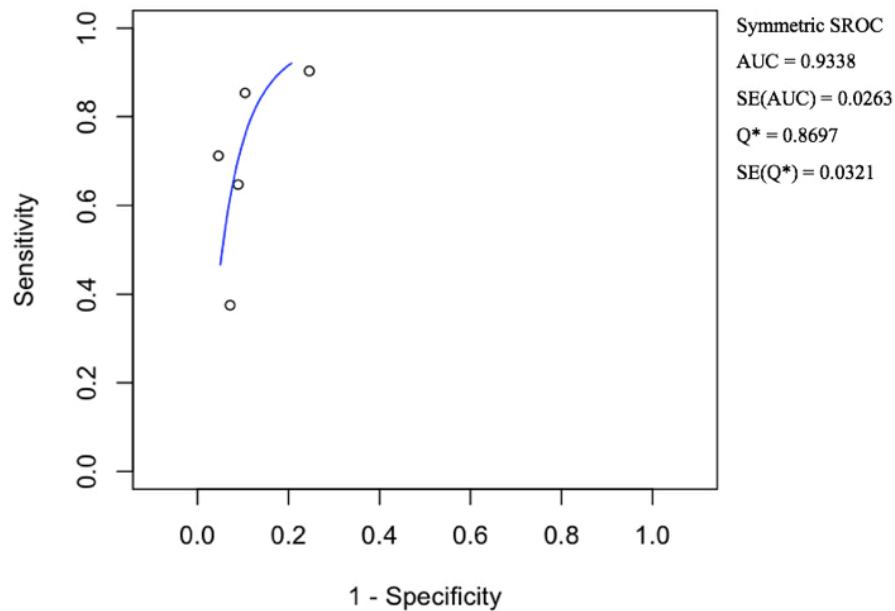
Most of the papers included in this study primarily focused on what they termed brownish spots as the predominant NBI detected abnormality, which was felt to represent a macroscopic focal increase in subepithelial microvascular architectural density¹⁶⁻¹⁸. Terms of vascular patterns such as vessel tortuosity, dilation, and irregularity followed. The utilization



SROC - summary receiver operating characteristic. SE - standard error.

AUC - area under the curve

Figure 4. Narrow-band imaging summary receiver operating characteristic curve illustrated the accuracy of nasoendoscopy with narrow-band imaging settings. Area under the curve and standard error was calculated.



SROC - summary receiver operating characteristic. SE - standard error.

AUC - area under the curve

Figure 5. White light summary receiver operating characteristic curve illustrates the accuracy of nasoendoscopy with conventional white light settings. Area under the curve and standard error was calculated.

Table 3. Narrow-band imaging and white light endoscopy pooled data and analysis.

	NBI	WL
Sensitivity	0.90 (0.73–0.97)	0.77 (0.58–0.89)
Specificity	0.95 (0.81–0.99)	0.91 (0.79–0.96)
Positive Likelihood Ratio	18.82 (4.31–82.06)	7.61 (3.61–16.04)
Negative Likelihood Ratio	0.076 (0.018–0.31)	0.21 (0.11–0.39)
Diagnostic Odds Ratio	200.13 (32.56–1230.33)	34.00 (15.58–74.21)
AUC	0.98 (SE: 0.02)	0.93 (SE: 0.03)

NBI - Narrow-band imaging. WL - white light endoscopy. AUC – area under the curve. SE – standard error.

of other mucosal surface structural abnormalities in the epithelial layer was only mentioned in one study which included light crests and side morphological differences detected by NBI¹⁹. In our colorectal counterparts, a universal NBI magnifying endoscopic classification of colorectal tumors based on objective grounds using a modified Delphi method, followed a proposal by the Japanese NBI Expert Team. They classified abnormal NBI findings into four categories based on the vascular pattern. Mucosal surface patterns were included in this classification: dark or white spots; tubular, branched, and papillary; irregular or obscure; and amorphous areas²⁰. Mucosal surface patterns of oval, tubular, papillary, and destructive were described in histological confirmed gastric carcinomas²¹. One example of the utilization of mucosa surface structural abnormalities in the head and neck region was in a study of NBI on laryngeal squamous cell carcinoma⁹. The sensitivity and specificity of NBI was described to be both 0.91 respectively. Mucosal abnormalities detected with NBI were demarcated brownish areas with scattered brown spots in the lesion on the epiglottis. In the nasopharynx, the most common type of epithelial malignancy is a non-keratinizing undifferentiated carcinoma. Although the sensitivity and specificity was 0.90 and 0.95 in our meta-analysis, adopting a uniform epithelial abnormality classification similar to colorectal and upper gastrointestinal diagnostics might be a suitable step in optimizing NBI for the detection of NPC.

Furthermore, solely using vascular patterns to differentiate malignant from benign lesions may be difficult in practice. In a paper investigating the difference between benign basal cell hyperplasia (BCH) and head and neck SCC, BCH was described as having a regular distribution of capillary loops and preserved intervascular transparency compared to SCC. However, no significant differences were detected in the sharpness of the lesion border, nor in the dilatation and tortuosity of the capillary loops²². If every lesion showing dilatation and tortuosity of capillary loops were to be biopsied, it would defeat one aim of NBI and that is to decrease the number of unjustified biopsies.

Limitations of the current analysis include the heterogeneity between primary studies that limit the accuracy of this meta-analysis. These variations include inclusion and exclusion criteria, indications for nasoendoscopy, operator experience, interpretation of endoscopic findings, and diagnostic thresholds. Convenience samples of available examiners and power calculations were not included in any of the studies to calculate the number of examiners needed to detect significant differences. Only studies written in English were included in this meta-analysis. Other languages may offer primary studies with larger sample sizes. Finally, the inclusion of examiners with high baseline detection rates but with little potential to improve may also have limited the effect sizes.

Conclusion

For the detection of primary nasopharyngeal carcinoma, narrow-band imaging has not been shown to have significant advantage over white light endoscopy in this meta-analysis, which may be related to the heterogeneity of studies analyzed. Detection may be improved with uniform diagnostic criteria and the inclusion of additional definitions and patterns of mucosal microstructures and submucosal microvascular abnormalities.

This work was previously presented at the IFOS World Congress of Otorhinolaryngology and Head and Neck Surgery on 28 June 2017, Paris, France.

Data availability

Dataset 1: OpenMetaAnalyst file contain data analysis performed in this study. [10.5256/f1000research.15183.d206977](https://doi.org/10.5256/f1000research.15183.d206977)²³

Competing interests

No competing interests were disclosed.

Grant information

The author(s) declared that no grants were involved in supporting this work.

Supplementary material

Supplementary File 1 – Completed PRISMA checklist.

[Click here to access the data.](#)

References

1. Lin YC, Wang WH, Tsai WC, *et al.*: **Predicting the early invasiveness of nasopharyngeal mucosal neoplasia after radiotherapy by narrow-band imaging: a pilot study.** *Head Neck.* 2013; **35**(1): 46–51.
[PubMed Abstract](#) | [Publisher Full Text](#)
2. Centre for Health Protection: **Nasopharyngeal cancer.** 2017; January 5, 2018.
[Reference Source](#)
3. Tay JK, Lim MY, Kanagalingam J: **Screening in nasopharyngeal carcinoma: current strategies and future directions.** *Curr Otorhinolaryngol Rep.* 2014; **2**(1): 1–7.
[Publisher Full Text](#)
4. Thong JF, Loke D, Karumathil Sivasankarannair R, *et al.*: **Use of narrow-band imaging in detection of nasopharyngeal carcinoma.** *J Laryngol Otol.* 2013; **127**(2): 163–169.
[PubMed Abstract](#) | [Publisher Full Text](#)
5. Piazza C, Dessouky O, Peretti G, *et al.*: **Narrow-band imaging: a new tool for evaluation of head and neck squamous cell carcinomas. Review of the literature.** *Acta Otorhinolaryngol Ital.* 2008; **28**(2): 49–54.
[PubMed Abstract](#) | [Free Full Text](#)
6. Dinesen L, Chua TJ, Kaffes AJ: **Meta-analysis of narrow-band imaging versus conventional colonoscopy for adenoma detection.** *Gastrointest Endosc.* 2012; **75**(3): 604–611.
[PubMed Abstract](#) | [Publisher Full Text](#)
7. Viantis AC, Woo JK, Tong MC, *et al.*: **Narrow band imaging endoscopy of the nasopharynx is not more useful than white light endoscopy for suspected nasopharyngeal carcinoma.** *Eur Arch Otorhinolaryngol.* 2016; **273**(10): 3363–3369.
[PubMed Abstract](#) | [Publisher Full Text](#)
8. Gono K, Yamazaki K, Doguchi N, *et al.*: **Endoscopic observation of tissue by narrowband illumination.** *Opt Rev.* 2003; **10**(4): 211–215.
[Publisher Full Text](#)
9. Watanabe A, Taniguchi M, Tsujie H, *et al.*: **The value of narrow band imaging for early detection of laryngeal cancer.** *Eur Arch Otorhinolaryngol.* 2009; **266**(7): 1017–1023.
[PubMed Abstract](#) | [Publisher Full Text](#)
10. Song F, Khan KS, Dinnes J, *et al.*: **Asymmetric funnel plots and publication bias in meta-analyses of diagnostic accuracy.** *Int J Epidemiol.* 2002; **31**(1): 88–95.
[PubMed Abstract](#) | [Publisher Full Text](#)
11. Raab-Traub N: **Epstein-Barr virus in the pathogenesis of NPC.** *Semin Cancer Biol.* 2002; **12**(6): 431–441.
[PubMed Abstract](#) | [Publisher Full Text](#)
12. Bruno MJ: **Magnification endoscopy, high resolution endoscopy, and chromoscopy; towards a better optical diagnosis.** *Gut.* 2003; **52**(suppl 4): iv7.
[PubMed Abstract](#) | [Publisher Full Text](#) | [Free Full Text](#)
13. Ni XG, Wang GQ: **The Role of Narrow Band Imaging in Head and Neck Cancers.** *Curr Oncol Rep.* 2016; **18**(2): 10.
[PubMed Abstract](#) | [Publisher Full Text](#)
14. Yamashita H, Aoki H, Tanioka K, *et al.*: **Ultra-high definition (8K UHD) endoscope: our first clinical success.** *Springerplus.* 2016; **5**(1): 1445.
[PubMed Abstract](#) | [Publisher Full Text](#) | [Free Full Text](#)
15. Piazza C, Del Bon F, Peretti G, *et al.*: **Narrow band imaging in endoscopic evaluation of the larynx.** *Curr Opin Otolaryngol Head Neck Surg.* 2012; **20**(6): 472–476.
[PubMed Abstract](#) | [Publisher Full Text](#)
16. Wang WH, Lin YC, Chen WC, *et al.*: **Detection of mucosal recurrent nasopharyngeal carcinomas after radiotherapy with narrow-band imaging endoscopy.** *Int J Radiat Oncol Biol Phys.* 2012; **83**(4): 1213–1219.
[PubMed Abstract](#) | [Publisher Full Text](#)
17. Wen YH, Zhu XL, Lei WB, *et al.*: **Narrow-band imaging: a novel screening tool for early nasopharyngeal carcinoma.** *Arch Otolaryngol Head Neck Surg.* 2012; **138**(2): 183–188.
[PubMed Abstract](#) | [Publisher Full Text](#)
18. Yang H, Zheng Y, Chen Q, *et al.*: **The diagnostic value of narrow-band imaging for the detection of nasopharyngeal carcinoma.** *ORL J Otorhinolaryngol Relat Spec.* 2012; **74**(5): 235–239.
[PubMed Abstract](#) | [Publisher Full Text](#)
19. Wang WH, Lin YC, Lee KF, *et al.*: **Nasopharyngeal carcinoma detected by narrow-band imaging endoscopy.** *Oral Oncol.* 2011; **47**(8): 736–741.
[PubMed Abstract](#) | [Publisher Full Text](#)
20. Sano Y, Tanaka S, Kudo SE, *et al.*: **Narrow-band imaging (NBI) magnifying endoscopic classification of colorectal tumors proposed by the Japan NBI Expert Team.** *Dig Endosc.* 2016; **28**(5): 526–533.
[PubMed Abstract](#) | [Publisher Full Text](#)
21. Ok KS, Kim GH, Park do Y, *et al.*: **Magnifying Endoscopy with Narrow Band Imaging of Early Gastric Cancer: Correlation with Histopathology and Mucin Phenotype.** *Gut Liver.* 2016; **10**(4): 532–541.
[PubMed Abstract](#) | [Publisher Full Text](#) | [Free Full Text](#)
22. Yagishita A, Fujii S, Yano T, *et al.*: **Endoscopic findings using narrow-band imaging to distinguish between basal cell hyperplasia and carcinoma of the pharynx.** *Cancer Sci.* 2014; **105**(7): 857–861.
[PubMed Abstract](#) | [Publisher Full Text](#) | [Free Full Text](#)
23. Yeung DC, Viantis AC, Wong EW, *et al.*: **Dataset 1 in: A meta-analysis of narrow-band imaging for the diagnosis of primary nasopharyngeal carcinoma.** *F1000Research.* 2018.
[Data Source](#)

Open Peer Review

Current Referee Status:  

Version 1

Referee Report 10 July 2018

doi:10.5256/f1000research.16541.r35278



Daniel Clayburgh , **Jennifer Christenson**

Department of Otolaryngology/Head and Neck Surgery, Oregon Health and Science University, Portland, OR, USA

In this manuscript, Yeung *et al* perform a meta-analysis of narrow band imaging versus white light endoscopy for the diagnosis nasopharyngeal carcinoma. A few areas that could be improved in this report:

Introduction

Explain more about how narrow band imaging works and detects mucosal change.

Methods

Included studies inclusion criteria are very loosely explained (discussed between DCMY and JYKC), No specific criteria other than prospective studies that compare NBI to WL. Please provide more detail on study protocols that were used.

Provide additional detail on imaging characteristics that were concerning for neoplastic change and warranted biopsy.

Results:

Table 1 and 2 could easily be combined in to a "study characteristics" table.

Discussion

One confounding factor would be in the indications for imaging and/or biopsy. Mucosal appearance of screening patients and surveillance patients are likely very different aka post-treatment/ radiated mucosa.

Is the work clearly and accurately presented and does it cite the current literature?

Yes

Is the study design appropriate and is the work technically sound?

Yes

Are sufficient details of methods and analysis provided to allow replication by others?

Partly

If applicable, is the statistical analysis and its interpretation appropriate?

I cannot comment. A qualified statistician is required.

Are all the source data underlying the results available to ensure full reproducibility?

Yes

Are the conclusions drawn adequately supported by the results?

Yes

Competing Interests: No competing interests were disclosed.

We have read this submission. We believe that we have an appropriate level of expertise to confirm that it is of an acceptable scientific standard.

Referee Report 09 July 2018

doi:10.5256/f1000research.16541.r35284



Chwee Ming Lim 

Department of Otolaryngology, Head and Neck Surgery,, National University of Singapore, Singapore, Singapore

A comprehensive review/meta-analysis on the topic of NBI in diagnosis of NPC. Several comments that i have are

1) PRISMA chart - Figure 1

The authors should expand on the reasons of the exclusion of the papers. Having 13 papers excluded after title screen, one paper excluded after data collection without clarification may leave the readers wondering on the nature of the exclusion.

2) The heterogeneity analysis is an inherent weakness of this study which the authors have addressed in the discussion. Having NBI in separate clinical context (ie screening and if so, in specific high risk cohorts versus general population; and surveillance cohort should be explored). Can a separate robust analysis be performed on the use of NBI in these specific clinical scenarios with the existing dataset?

3) A recent meta-analysis published in Otolaryngology-Head and Neck Surgery on this subject yielded similar conclusions. The authors may want to highlight some similarities or differences in their analysis and approach.

Overall, an informative article on the subject matter and reviewing the existing evidence of NBI in diagnosis of NPC.

Is the work clearly and accurately presented and does it cite the current literature?

Yes

Is the study design appropriate and is the work technically sound?

Yes

Are sufficient details of methods and analysis provided to allow replication by others?

Yes

If applicable, is the statistical analysis and its interpretation appropriate?

I cannot comment. A qualified statistician is required.

Are all the source data underlying the results available to ensure full reproducibility?

Yes

Are the conclusions drawn adequately supported by the results?

Yes

Competing Interests: No competing interests were disclosed.

Referee Expertise: head and neck cancer, onco-immunology, robotic surgery

I have read this submission. I believe that I have an appropriate level of expertise to confirm that it is of an acceptable scientific standard.

The benefits of publishing with F1000Research:

- Your article is published within days, with no editorial bias
- You can publish traditional articles, null/negative results, case reports, data notes and more
- The peer review process is transparent and collaborative
- Your article is indexed in PubMed after passing peer review
- Dedicated customer support at every stage

For pre-submission enquiries, contact research@f1000.com

F1000Research