

This is an Open Access article licensed under the terms of the Creative Commons Attribution-NonCommercial-NoDerivs 3.0 License (www.karger.com/OA-license), applicable to the online version of the article only. Distribution for non-commercial purposes only.

Serous Retinal Detachments Complicating Interferon- α and Ribavirin Treatment in Patients with Hepatitis C

Giulio Modorati Federico Di Matteo Elisabetta Miserocchi
Annalisa Colucci Francesco Bandello

Department of Ophthalmology, University Vita-Salute, Scientific Institute San Raffaele, Milan, Italy

Key Words

Serous retinal detachment · Vogt-Koyanagi-Harada · Hepatitis C · Interferon · Uveitis

Abstract

Purpose: To report the cases of two patients with chronic hepatitis C infection showing serous retinal detachments similar to Vogt-Koyanagi-Harada (VKH) disease.

Methods: We reviewed the clinical records of two patients who were diagnosed with VKH-like disease during combined interferon- α (IFN α) and ribavirin treatment.

Results: Interruption of IFN α and ribavirin treatment in association with oral corticosteroids resulted in a favorable visual outcome in the case of diffuse retinal detachment (case 1). On the contrary, visual acuity did not improve when late cicatricial stage disease was already present (case 2).

Conclusion: There is increasing evidence of a link between hepatitis C virus infection treated with pegylated IFN α -2b and the development of VKH-like disease. Knowing the potential side effects of IFN α and ribavirin administration is fundamentally important, as is the need to closely follow up those patients that need to undergo this treatment.

Introduction

Vogt-Koyanagi-Harada (VKH) disease, also known as uveomeningitic syndrome, is a rare idiopathic multisystem autoimmune granulomatous disorder affecting the eyes, meninges, auditory system and skin. The disease is thought to be due to an autoimmune Th1-mediated response to a melanocyte-associated antigen [1], but the initiation mechanism and development of the exact process remain poorly understood.

Recent reports suggest a link between hepatitis C virus (HCV) infection and/or its treatment and the development of bilateral uveitis that is virtually identical to VKH

disease. We present two cases of VKH-like disease in patients treated with pegylated interferon- α (IFN α) and ribavirin for chronic hepatitis C.

Case Report

Case 1

A 61-year-old woman contracted HCV in 2006 following a blood transfusion performed during a colectomy for adenocarcinoma. The patient's past medical history was relevant only for type I diabetes mellitus controlled with insulin therapy. Because of histological damage at liver biopsy, she was prescribed pegylated IFN α and ribavirin treatment from October 2006. After 3 months, the patient was referred to a hepatologist because of sudden vision loss in both eyes. The physician suspected an interferon-related side effect and immediately interrupted the treatment. Upon presentation at our Ocular Immunology and Uveitis Service, the patient's best-corrected visual acuity was hand motion in the right eye and 20/400 in the left eye. The anterior segment examination was normal and intraocular pressure was 10 mm Hg in both eyes. The fundus examination showed diffuse bilateral serous retinal detachment ([fig. 1](#)). No auditory or neurological symptoms were noted, nor vitiligo, alopecia, or poliosis. Based on the revised diagnostic criteria for VKH we diagnosed 'probable' VKH disease and prescribed treatment with oral prednisone 25 mg/die; the patient recovered to 20/25 in the right eye and to 20/20 in the left eye.

Case 2

A 36-year-old man with HCV since 2004 was taking pegylated IFN α and ribavirin during the same period. He also suffered from celiac disease. After 6 months of treatment, he referred bilateral sudden vision loss to his ophthalmologist and was treated with 12.5 mg oral prednisone per day without visual improvement. The patient was referred to our Ocular Immunology and Uveitis Service 15 months after the onset of initial symptoms for a second diagnostic and therapeutic opinion. At presentation, best-corrected visual acuity was 20/200 in the right eye and 20/40 in the left eye. No neurological or auditory signs were noted, nor were vitiligo, poliosis or alopecia. The anterior segment revealed a marked posterior cortical cataract in the right eye and an initial posterior subcapsular cataract in the left eye. We noted bilateral nummular chorioretinal depigmented scars and retinal pigment epithelium clumping and migration compatible with late cicatricial stage probable VKH disease ([fig. 2](#)). Previous fluorescein angiograms showed multiple pinpoint hyperfluorescence at the level of the pigment epithelium and diffuse exudative retinal detachments in both eyes. Despite discontinuation of IFN α and ribavirin visual acuity did not improve.

Discussion

A causal effect between IFN α treatment for HCV infection and VKH disease has not yet been proven. The exact etiology of VKH itself remains unclear. VKH syndrome is possibly caused by a T cell-mediated autoimmune reaction against proteins related with choroidal melanocytes. The fact that the disease prevalence varies considerably among populations and that it commonly affects people with more pigmented skin and a certain HLA (human leukocyte antigen) predisposition highlights the importance of individual genetic predisposition for the development of VKH disease. However, the autoimmune reaction needs to be initiated by a triggering agent. Epstein-Barr or cytomegalovirus infections have been proposed as initiating factors. The infection may lead to the production of autoreactive antibodies through a process of molecular mimicry between viral and melanocyte-related antigens [1].

The immunogenicity of IFN α in ocular tissue has been known since 1997 when a possible role in the development of Behçet's disease, another autoimmune disorder in which T cell-mediated activation is thought to play a major role, was suggested. Furthermore, interferon and ribavirin can induce a Th1 response and modify the expression of MHC class II antigens, both of which are associated with the development of VKH disease. Therefore, despite the lack of evidence of a causal effect, IFN α and ribavirin might be involved in both the initiation of the autoimmune process and the induction of a higher susceptibility in developing VKH syndrome. The association between VKH-like syndrome and interferon treatment for hepatitis C was first suggested in 2003 [2]. Since then, seven other cases of HCV-positive patients presenting a VKH-like disease after IFN α treatment have been reported in the literature [3–5]. Most of the reported cases ([table 1](#)) show signs of systemic involvement such as skin lesions, auditory or neurologic symptoms in association with serous retinal detachment, which is one of the hallmarks of VKH disease. Nevertheless, our cases highlight the importance of including serous retinal detachment without systemic signs in suspecting VKH-like disease in patients under IFN α and ribavirin treatment for hepatitis C.

Despite the widespread use of interferon and ribavirin for the treatment of hepatitis C, the small number of published cases of VKH-like disease following IFN α treatment shows that ocular immunological side effects are rare. However, IFN α may cause other more common significant side effects, including retinal vascular disorders, ischemic optic neuropathies, neovascular glaucoma and 'specific IFN α -related retinopathy,' i.e. retinopathy characterized by retinal hemorrhages, microaneurysms, and cotton-wool spots.

The presented cases emphasize the importance of early recognition and prompt adequate ophthalmological therapy in the presence of a VKH-like disease associated with IFN treatment. Discontinuation of IFN and ribavirin treatment in association with oral corticosteroids might result in a favorable visual outcome in the case of diffuse retinal detachment (case 1). Conversely, visual recovery is usually poor when late cicatricial stage disease is already present (case 2). If not promptly recognized, IFN α -related effects may lead to chronic bilateral severe vision loss. Therefore, it is of fundamental importance to recognize the potential side effects of IFN α and ribavirin administration, and to closely follow up patients if treatment needs to be continued.

Acknowledgement

The authors wish to thank Michael John, Professor of Applied English at the Vita-Salute San Raffaele University, for the English language editing of this manuscript.

Disclosure Statement

None of the authors has any financial interests concerning procedures nor drugs cited in this manuscript.

Table 1. Comparison with previously reported cases of VKH-like disease associated with IFN treatment

Case No. [ref.]	Origin	Age	Sex	VA at presentation	Anterior segment	Posterior segment	Systemic involvement	VA at follow-up
1 [2]	Latino	52	F	<20/200	posterior synechiae	vitritis, choroidal and scleral thickening (echography)	AL, AU	HM
2 [3]	Asian	36	M	NR	NR	serous retinal detachment, optic disk swelling	HE	20/20
3 [4]	Mediterranean	38	F	20/80 OD, 20/200 OS	mild anterior chamber reaction	serous retinal detachment, optic disk swelling	HE, AU, ME	20/20 and 20/20
4 [5]	Northern Europe	42	M	20/25 OD, 20/40 OS	normal	serous retinal detachment, choroidal folds, hyperemic optic disk	VI, HE, PL	20/20 both eyes
5 [5]	Northern Europe	43	F	20/200 OD, 20/40 OS	bilateral keratic precipitates; 1+ cells and flare	serous retinal detachment	PO, VI, HE	20/20 both eyes
6 [5]	Mediterranean	37	M	20/200 OD, HM OS	normal	serous retinal detachment, optic disk swelling, vitritis	PO, HE, AU, PL	20/20 OD, 20/400 OS
7 [5]	Northern Europe	52	F	20/200 OD, 20/40 OS	normal	serous retinal detachment, hyperemic optic disk	AL, AU	20/20 both eyes
8	Mediterranean	61	F	HM OD, 20/400 OS	normal	serous retinal detachment	none	20/25 OD, 20/20 OS
9	Mediterranean	36	M	20/200 OD, 20/40 OS	posterior cortical cataract (OD), posterior subcapsular cataract (OS)	chorioretinal scars and retinal pigment epithelium clumping	none	20/200 OD, 20/40 OS

Cases 8 and 9 are from the present paper. VA = Visual acuity; NR = not reported; VI = vitiligo; PO = poliosis; AL = alopecia; HE = headache; ME = meningism; AU = auditory symptoms; PL = pleoxytosis; HM = hand motion; OD = right eye; OS = left eye.

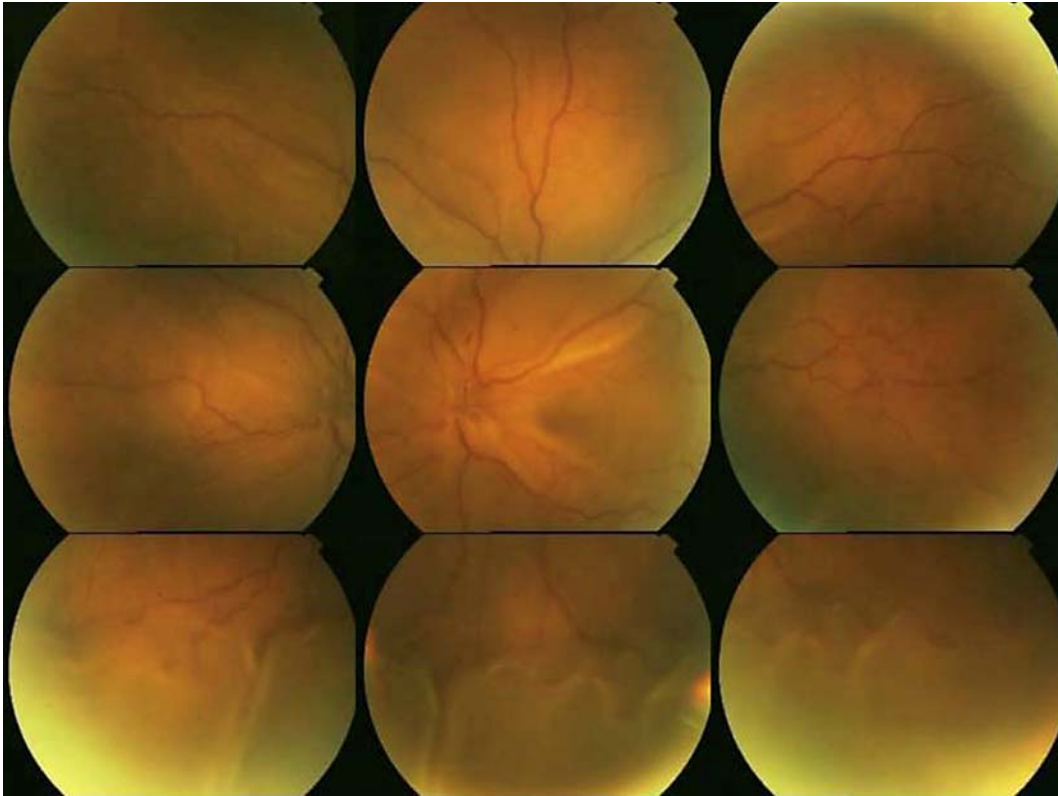


Fig. 1. Fundus photography evidencing diffuse serous retinal detachment (left eye).

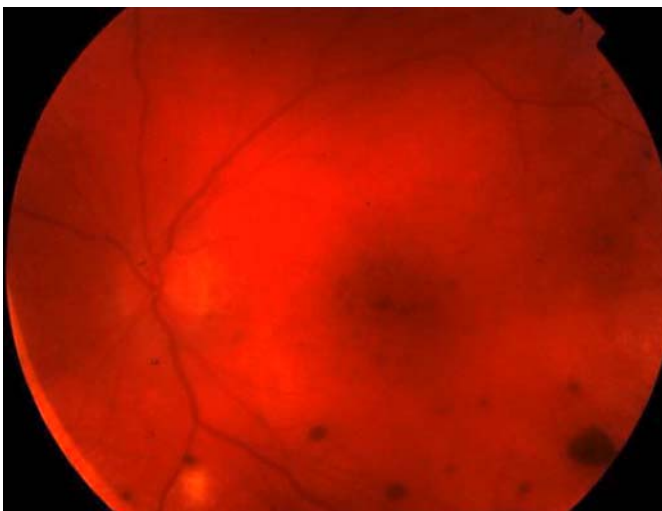


Fig. 2. Posterior pole photography evidencing depigmented scars and retinal pigment epithelium clumping (left eye).

References

- 1 Fang W, Yang P: Vogt-Koyanagi-Harada syndrome. *Curr Eye Res* 2008;33:517–523.
- 2 Sylvestre DL, Disston AR, Bui DP: Vogt-Koyanagi-Harada disease associated with interferon alpha-2b/ribavirin combination therapy. *J Viral Hepat* 2003;10:467–470.
- 3 Kasahara A, Hiraide A, Tomita N, et al: Vogt-Koyanagi-Harada disease occurring during interferon alpha therapy for chronic hepatitis C. *J Gastroenterol* 2004;39:1106–1109.
- 4 Papastathopoulos K, Bouzas E, Naoum G, Vergados I, Tsiodras S: Vogt-Koyanagi-Harada disease associated with interferon-A and ribavirin therapy for chronic hepatitis C infection. *J Infect* 2006;52:59–61.
- 5 Touitou V, Bodaghi B, Cassoux N, et al: Vogt-Koyanagi-Harada disease in patients with chronic hepatitis C. *Am J Ophthalmol* 2005;140:949–952.