

A five-year follow-up of *ABCA4* carriers showing deterioration of retinal function and increased structural changes

Ulrika Kjellström, Sten Andréasson

Lund University, Skane University Hospital, Department of Clinical Sciences Lund, Ophthalmology, Lund, Sweden

Purpose: To investigate whether the reduced retinal function and morphological retinal changes previously demonstrated in *ABCA4* carriers had remained stationary or had deteriorated over time at 5-year follow-up to further explore if carriers of an autosomal recessive trait also express a weak phenotype, although this is not expected for an autosomal recessive disorder.

Methods: Thirteen *ABCA4* carriers from a previous study that included parents to patients with well known genetically verified *ABCA4*-associated retinal degenerations were reexamined 5 years after the initial examination. As novel genes and new variants in already established genes are continuously reported, all subjects underwent renewed genetic testing with a next-generation sequencing (NGS) panel that included 288 genes associated with retinal dystrophies and an analysis of deep intronic mutations and copy number variations in the *ABCA4* gene. Moreover, to evaluate any changes in retinal function and/or structure over time, clinical reassessment with Goldmann perimetry, visual acuity testing, fundus photography, fundus autofluorescence (FAF) imaging, optical coherence tomography (OCT), full-field electroretinography (ffERG), and multifocal ERG (mfERG) were performed 5 years after the initial investigation. The values of the ffERG parameters were compared between the two time points (the measurements obtained in the initial study versus the measurements at 5-year follow-up) and with the controls. The mfERG results of the carriers were compared with those of the controls.

Results: The renewed genetic testing confirmed the previously established *ABCA4* mutations but also revealed the hypomorph *ABCA4* variant c.5603A>T in five *ABCA4* carriers. In three of them, the variant was found to be associated with known disease-causing alleles that always carry the c.5603A>T in cis. According to recent publications, the subjects could still be considered *ABCA4* carriers because both variants are on the same allele. In the remaining two subjects, c.5603A>T could be in trans with the previously known *ABCA4* variant, and the subjects were therefore excluded from the study since they could no longer be considered as carriers only. Statistical comparison of ffERG parameters showed significant reduction of the isolated rod, -as well as the combined rod-cone amplitudes over the five years of follow-up, but not compared with the controls. Concerning macular function, mfERG amplitudes were reduced for all rings in the carriers compared with the controls. Fundus photographs demonstrated morphological changes in 64% of the carriers, and 36% of them had further changes at follow-up. FAF images showed alterations in 55% of the carriers, with increased changes in 36% of them. Abnormalities on OCT were observed in 82% of the carriers, of whom 9% had newly found abnormalities at follow-up.

Conclusions: At 5-year follow-up, the *ABCA4* carriers, who previously demonstrated reduced macular function, presented with deterioration of general retinal function, including reduced isolated rod and mixed rod-cone ffERG responses combined with a slight increase in morphological changes in some subjects. This indicates that carriership of at least some *ABCA4* variants may cause a condition similar to a subgroup of dry age-related macular degeneration (AMD). In the long run, this might be of importance concerning the possibilities to also treat this subgroup of AMD patients with future gene-based and pharmacological drugs targeting *ABCA4*-associated disorders.

Compound heterozygous or homozygous mutations in the *ABCA4* gene (Gene ID: 24, OMIM 601691) are known to cause a spectrum of *ABCA4*-associated retinal degenerations from the mildest form; Stargardt disease (STGD), mostly reducing macular function [1-5], to the more severe entities, including cone-rod dystrophy (CRD) [6-9] and autosomal recessive retinitis pigmentosa (arRP) [3,7,10], which lead to a more widespread reduction of retinal function.

STGD is usually associated with typical fundus changes, including deep yellow-orange flecks in the posterior pole and symmetric and bilateral atrophies of the retinal pigment epithelium (RPE) in the macular region [1,2,4]. In CRD, fundus changes are less typical, with unspecific pigmentations and atrophies in the macula and midperiphery. Very severe cases can demonstrate pale optic discs and attenuated vessels [3,9,11]. Typically, patients with retinitis pigmentosa (RP) have peripheral bone corpuscle pigmentations, pale optic discs, and attenuated retinal vessels [3,7,10], but in *ABCA4*-associated arRP, retinal pigmentations can be less specific.

The *ABCA4* gene is located on chromosome 1 (OMIM; 1p22.1). It encodes the ABCA4 protein, a

Correspondence to: Ulrika Kjellström, Ögonkliniken Skånes Universitetssjukhus Lund, Kioskg 1, S 221 85 Lund, Sweden, Phone: +46-70-566 52 54, FAX: +46-46-13 90 45, email: ulrika.kjellstrom@med.lu.se

membrane-associated protein in the rim of the photoreceptor discs [12-14]. ABCA4 is a transport protein belonging to the ATP-binding cassette (ABC) superfamily. It plays an important role in photoreceptors by removing the toxic retinoid compounds, *N*-retinylidene-phosphatidylethanolamine and phosphatidylethanolamine, from the inside of the outer segment discs to the cytosol during the phototransduction cascade [15-17]. Defective or missing ABCA4 protein results in a build-up of lipofuscin fluorophores such as *N*-retinylidene-*N*-retinylethanolamine in RPE cells [17-19], eventually leading to RPE cell death and probable secondary loss of photoreceptors [17,20]. Some surveys have also suggested that photoreceptor cell death is the primary process [21-25].

Previous studies have found indications of a potential role for heterozygous *ABCA4* mutations in age-related macular degeneration (AMD) [4,26-29], although carriers of recessive traits are not supposed to express the phenotype. The carrier-ship of pathological *ABCA4* mutations is quite common, with an incidence of approximately 1 in 20 persons, in different populations [30,31]. Therefore, the role of the *ABCA4* gene in AMD could be of interest to explain the cause of dry AMD, at least, in some subgroups of this widely prevalent disorder. Moreover, if an association with the *ABCA4* gene can be confirmed, novel future gene-based and pharmacological treatments especially developed for *ABCA4*-associated disorders might also be of interest for this subgroup of patients with dry AMD who lack treatment options today.

The present study was a 5-year follow-up of *ABCA4* carriers who, in the initial survey [27], presented with reduced macular function measured with multifocal electroretinography (mfERG) and, in some cases, morphological retinal changes on optical coherence tomography (OCT), fundus autofluorescence (FAF), and fundus photographs, although they carry only one pathological *ABCA4* variant. These subjects were reexamined to evaluate whether the changes in retinal function and morphology were stationary or progressive to further explore the possibility of an association with AMD.

METHODS

Subjects and controls: In this survey, *ABCA4* carriers from a previous study [27] were reinvestigated 5 years after the initial examination. They were originally recruited as the parents to young patients with *ABCA4*-associated retinal dystrophies carrying two documented pathogenic *ABCA4* variants that were followed up regularly in our department during the previous study period. None of the *ABCA4* carriers had been examined in our clinic before the original study started, and only two of them, subjects 1 and 14, had had

any subjective problems with their eyes or vision previously. Subject 1 underwent surgery for cataract in her right eye (in another hospital) and still had a mild cortical cataract in her left eye. Patient 14 had not had his right eye checked, although he had noticed some blurriness. Thus, the inclusion criterion for the subjects was the presence of a pathogenic *ABCA4* variant on one allele. The exclusion criteria were the presence of pathogenic *ABCA4* variants on both alleles, previous retinal surgery or serious eye trauma, and previous diagnosis of chronic eye disorders.

The initial study [27] originally recruited 18 Swedish parents. Sixteen of them were found to be carriers of a single heterozygous pathological *ABCA4* variant and were thus included in the study, while two of them were compound heterozygous for two pathological *ABCA4* mutations and were thus excluded. In the initial study, the *ABCA4* carriers demonstrated reduced macular function and morphological changes in the posterior pole. In the present survey, the *ABCA4* carriers were reexamined to evaluate whether the reduced retinal function and structural changes had been stationary over 5 years or if further deterioration could be detected. Moreover, because novel genes and new variants in already established genes are continuously reported, renewed genetic testing was also performed. Unfortunately, not all the original 16 *ABCA4* carriers could participate in the 5-year follow-up survey. Two of them could not be reached, and a third subject declined to participate because of health problems in a close relative. Thus, 13 *ABCA4* carriers aged 49–66 years (mean, 58 years) at the time of the reassessment were included. The subjects' demographic, genetic, and clinical data are described in Table 1.

In the present study, two control groups were included, one for comparison of mfERG parameters, consisting of 15 healthy subjects aged 49–64 years (mean, 55 years), and another for comparison of the full-field ERG (ffERG) parameters, including 20 healthy subjects aged 45–73 years (mean, 59 years). The inclusion criteria for the control subjects were the absence of retinal disorders or former retinal surgery, no history of serious eye trauma, and a best-corrected visual acuity (BCVA) of ≥ 0.9 on the letter chart. The exclusion criteria included a diagnosis of a chronic eye disorder, previous eye trauma or retinal surgery, and a BCVA of ≤ 0.8 on the letter chart. The study was conducted in accordance with the tenets of the Declaration of Helsinki and was approved by the Ethical Committee for Medical Research at Lund University. All subjects received a thorough written and oral explanation of the nature and possible consequences of the study and thereafter provided their written consent to participate.

TABLE 1. DEMOGRAPHIC AND GENETIC DATA. SUBJECTS HIGHLIGHTED IN BOLD WERE EXCLUDED FROM THE STUDY DUE TO THE NEWLY DETECTED PATHOGENIC *ABCA4* VARIANTS THAT COULD BE IN TRANS WITH THE ONE PREVIOUSLY FOUND.

Subject/ Gender	Age	Mutations found initially	Mutations found on follow-up	BCVA (RE, LE)
1/F	65	c.768 G>T	c.768 G>T	1.0, 0.4 <i>0.8, 0.4*</i>
2/M	66	c.768 G>T	c.768 G>T	1.0, 0.9 <i>1.0, 1.0</i>
3/M	50	c.768 G>T	c.768 G>T	1.0, 1.0 <i>1.0, 1.0</i>
4/F	64	c.5461–10T>C	c.5461–10T>C, c.5603 A>T (<i>in cis</i>)	1.0, 1.0 <i>1.0, 0.9</i>
5/M	66	c.319 C>T	c.319 C>T, c.5603 A>T (<i>in cis</i>)	0.9, 0.8 <i>1.0, 1.0</i>
6/F	49	c.5917delG	c.5917delG	0.7, 1.0 <i>0.7, 1.0</i>
7/F	62	c.2894 A>G	c.2894 A>G	0.8, 1.0 <i>1.0, 1.0</i>
8/M excluded	66	c.768 G>T	c.768 G>T, c.5603 A>T	0.9, 0.9 <i>1.0, 1.0</i>
10/M excluded	56	c.1804 C>T	c.1804 C>T, c.5603 A>T	1.0, 1.0 <i>1.0, 1.0</i>
11/F	54	c.4469 G>A	c.4469 G>A, c.5603 A>T (<i>in cis</i>)	1.0, 1.0 <i>1.0, 1.0</i>
12/M	56	c.6079 C>T	c.6079 C>T	0.9, 0.9 <i>1.0, 1.0</i>
13/F	52	c.2894 A>G	c.2894 A>G	1.0, 1.0 <i>1.0, 1.0</i>
14/M	58	c.2894 A>G	c.2894 A>G	0.5, 1.0 <i>0.8, 1.0</i>

BCVA=best corrected visual acuity (Snellen), RE=right eye, LE=left eye, F=female, * numbers in italics are BCVA from the initial examination, M=male

Ophthalmological examination: BCVA was tested monocularly at 5 m on a letter chart, and Goldmann perimetry was performed, likewise monocularly, to map the visual fields using standardized objects V4e, I4e, 03e, and 02e. In eight subjects, the 01e object was also used. Fundus photographs, including color photographs, red-free photographs, and FAF images, were captured with a Topcon TRC 50DX fundus camera (Topcon, Inc., Oakland, NJ). The field of view for the FAF images was 50° × 50°, and Spaide filters with an excitation wavelength of 530–580 nm and barrier filters with a wavelength of 600–720 nm were used. In three subjects, careful slit-lamp and fundus examinations were performed.

Genetic analysis: In the initial study [27], DNA was extracted from a venous blood sample drawn from the precubital vein in all subjects. The sequence analysis of the entire coding region of the *ABCA4* gene was performed at Asper Biotech (Asper Ophthalmics, Tartu, Estonia). Positive results were

verified by Sanger sequencing. On follow-up, DNA was reanalyzed with an eye disease next-generation sequencing (NGS) panel that included 288 genes, with the addition of analyses for deep intronic mutations, copy number variations (CNVs), and hypomorph alleles in the *ABCA4* gene.

Full-field electroretinography: ffERGs were recorded with an Espion E² analysis system (Diagnosys, Lowell, MA) in accordance with the standardized guidelines for clinical ERG recommended by the International Society for Clinical Electrophysiology of Vision (ISCEV) [32,33], with the exception that the dark-adapted 10 ERG result was not recorded and that the 30-Hz flicker recordings were obtained during both dark- and light-adapted conditions, as our laboratory has used those settings for many years. Measurements were obtained after 40 min of dark adaptation with a bipolar Burian Allen corneal contact lens electrode. The ground electrode was placed on the forehead. The pupils were maximally dilated using

cyclopentolate 1% and 10% phenylephrine hydrochloride, and the cornea was anesthetized with oxybuprocaine 0.4%. To ensure reproducibility, stimulations were repeated for each stimulus intensity until two sequential identical curves were registered.

Multifocal electroretinography: Multifocal ERGs (mfERGs) were registered with a Visual Evoked Response Imaging System (VERIS Science 6; EDI, San Mateo, CA), with settings adhering to the ISCEV standards [32,33]. A Burian Allen bipolar ERG contact lens electrode was placed on the anesthetized (oxybuprocaine 0.4%) cornea, with the ground electrode on the forehead. The pupils were maximally dilated with cyclopentolate 1% and 10% phenylephrine. Fixation was monitored using an infrared eye camera mounted in the equipment. The stimulus matrix consisted of 103 hexagonal elements, scaled with eccentricity to elicit approximately equal amplitude responses at all locations. Each hexagon independently alternated between black and white according to a pseudorandom binary m-sequence at 75 Hz. The first-order component of the mfERG was analyzed for amplitudes (A) and implicit times (ITs) of P1 (first positive peak) within the six concentric rings (A 1–5 and IT 1–5) around the fovea. Ring 1, the innermost ring, included the summed responses from the central hexagon and the surrounding first ring of stimulus elements.

Optical coherence tomography: OCT images were captured, and the macular thickness was measured with a Topcon 3D OCT-1000 (Topcon, Inc., Paramus, NJ), as previously described [11,27].

Statistical analyses: Statistical analyses were performed using SPSS 26.0 (IBM SPSS Statistics, IBM Corporation, Chicago, IL). Statistical significance was defined as a p value <0.05. Owing to the small sample size, non-parametric statistical tests were used. To compare the ffERG results at the first investigation and those at 5-year follow-up, the Wilcoxon signed-rank test was used. For comparison of the values of the ffERG and mfERG parameters between the subjects and control groups, the Mann–Whitney *U* test was used. The limits of normality of the ERG parameters were defined by the mean \pm two standard deviations (2SD). The lower limits of normality were used for amplitudes; and the upper limits of normality, for ITs.

RESULTS

Genotype in ABCA4 carriers: The updated genetic analysis using NGS confirmed the ABCA4 mutations described previously [27] (Table 1) and revealed the hypomorphic ABCA4 variant c.5603 A>T in five subjects (subjects 4, 5, 8, 10, and 11). c.5603 A>T has been considered benign owing to its high

minor allele frequency (approximately 7%; 34) in the general population but was recently confirmed to be associated with late-onset ABCA4-associated retinal degenerations [34,35]. In three subjects (subjects 4, 5, and 11), the c.5603A>T variant was found in association with the pathogenic alleles, c.5461–10T>C, c.319 C>T, and c.4469 G>A, which are known to always carry c.5603A>T in cis [34,35]. Hence, the subjects could still be considered ABCA4 carriers. The remaining two subjects (subjects 8 and 10) were carrying mutations (c.768 G>T and c.1804 C>T) that can be in trans with c.5603A>T [34,35]. Accordingly, the subjects might be compound heterozygous and were therefore excluded from the study. No deep intronic mutations or CNVs were found. Neither did any of the subjects carry pathogenic variants in other genes associated with retinal dystrophies.

The genetic reanalysis using NGS revealed that c.5603 A>T was the most common mutation, followed by c.768 G>T (four cases) and then c.2894 A>G (three cases).

Phenotype in ABCA4 carriers:

Visual acuity and visual fields—Visual acuity data, both at the initial and follow-up examinations, are presented in Table 1. Of the 11 ABCA4 carriers, four (36%) had a BCVA of 1.0 in both eyes, and two (18%) had a BCVA of <1.0 bilaterally. The BVCA had deteriorated at the time of follow-up in five (45%) of the 11 ABCA4 carriers but improved in two (18%). Only two subjects (1 LE and 14 RE) had noticed reduced vision in daily life. The reduced visual acuity was caused by moderate cortical cataract in Subject 1 and scarring in the macula in Subject 14 (Figure 1).

All subjects completed Goldmann visual field testing in both eyes. Short descriptions of the visual field results are presented in Table 2. In four (36%; subjects 1, 2, 5, and 7) of the 11 ABCA4 carriers, the result had deteriorated slightly at follow-up compared with the initial examination (Table 2). On the other hand, two (18%) of the 11 ABCA4 carriers had slightly wider isopters for 03e and 02e on follow-up.

Retinal structure—The fundus photographs and examination results showed morphological retinal alterations in seven (64%) of the 11 ABCA4 carriers. Descriptions of the retinal morphologies are presented in Table 3. The most common findings were subtle pigmentary changes in the macula (Figure 2), but in one subject (Subject 1), drusen were scattered outside and just inside the vascular arcades (Figure 3A, B). In four (36%; subjects 1, 2, 6, and 12) of the 11 ABCA4 carriers, a slight aggravation of retinal changes was found at follow-up, whereas no remarkable features were found in the fundus photos of subjects 3, 4, 11, and 13 (36%).

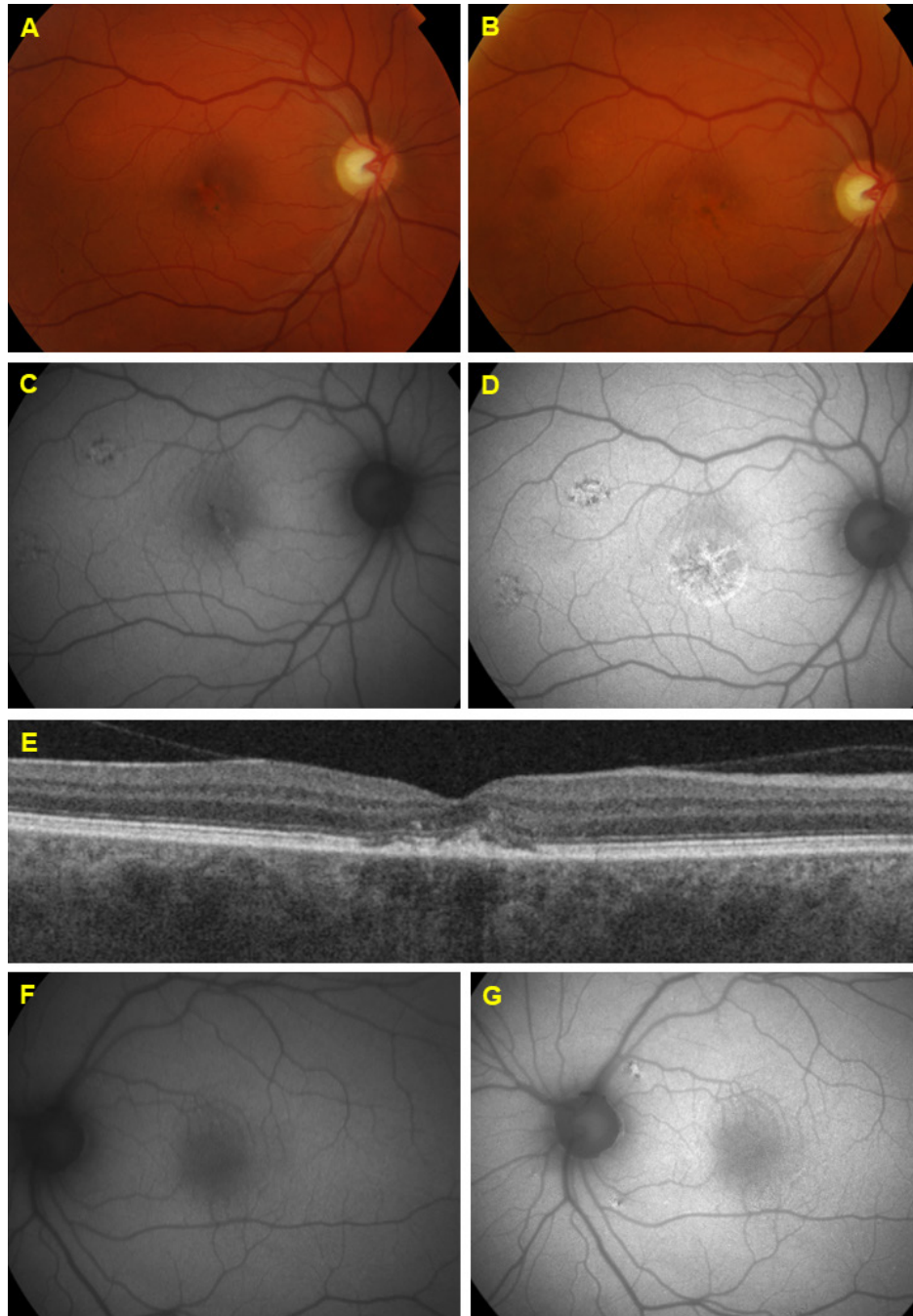


Figure 1. Fundus images in subject 14. The fundus photographs of the right eye show quite mild macular pigmentary changes both at the **A**: initial and **B**: follow-up examinations. The FAF images show more widespread changes with several foci of increased and reduced AF both at the **C**: initial and **D**: follow-up examinations, and the changes worsened during the 5-year period. **E**: The macular OCT images confirm the changes with scarring in the RPE and interruption of the ellipsoid zone. The left eye shows newly found structural alterations with small foci of increased and reduced AF along the vascular arcades on the FAF image **F**: at the initial examination compared with **G**: the follow-up examination.

TABLE 2. DESCRIPTION OF GOLDMANN VISUAL FIELDS IN *ABCA4* CARRIERS.

Subject/ Gender	Goldmann visual field; initial examination	Goldmann visual field; follow-up
1/F	RE small scotoma 03e inf temp between 10 and 20° ^a , LE normal	RE: same LE: 02e reduced from 12°–7°. 03e reduced sup from 20°–12°.
2/M	N	OA 02e reduced from 15° sup, nas, inf and 22° temp to 10° all around.
3/M	N	N
4/F	OA 03e, 02e, 01e constricted mostly 03e sup and more in LE	N
5/M	N	OA: cannot see 01e which was 5° in the initial study.
6/F	N	N
7/F	N	OA: cannot see 01e which was 5° in the initial study.
11/F	N	N
12/M	N	N: 03e slightly enlarged from 10 to 20° RE and 10–25° LE and 02e from 5 to 10° RE and 5–7 LE° compared to the initial study.
13/F	N	N
14/M	N	N: 03e slightly enlarged from 17 to 25° RE and 15–25° LE and 02e from 5 to 10° OA compared to the initial study.

F=female, M=male, RE=right eye, LE=left eye, inf=inferior, temp=temporal, n=normal, sup=superior, OA=both eyes^a The patient has myelinated nerve fibers corresponding to the scotoma

In subject 8, numerous orange-yellow retinal flecks (Figure 3C, D), which are quite typical for STGD, were found in the posterior pole both on the initial and follow-up examinations. These could be explained by the results of the renewed DNA analysis revealing the hypomorph variant c.5603A>T in addition to the previously known c.768 G>T variant. Thus, subject 8 now has both a phenotype and a genotype that agrees with late-onset STGD [34,35].

FAF images were captured in all subjects and showed alterations in six (55%) of the 11 *ABCA4* carriers. The changes were subtle, with small foci of increased and/or reduced autofluorescence in the posterior pole (Table 3 and Figure 2). The FAF images of subject 8 showed more widespread changes with multiple pisciform foci of high and low autofluorescence (AF) scattered in the entire posterior pole and outside the vascular arcades (Figure 3), confirming the late-onset STGD phenotype in line with genetics. Four (subjects 5, 7, 12, and 14) of the 11 (36%) *ABCA4* carriers had developed slightly more FAF changes in one eye at the time of follow-up (Figure 2).

OCT images were captured in both eyes of all *ABCA4* carriers (22 eyes). Nine eyes showed normal layering and overall morphology on OCT b-scans, whereas 12 eyes demonstrated subtle attenuation of the ellipsoid zone. The

right eye of Subject 14 showed more widespread morphological changes on OCT b-scans (Figure 1). Descriptions of the OCT findings are shown in Table 4 and examples of OCT images can be viewed in Figure 1 and Figure 4. Two carriers (subjects 4 and 11) had normal OCT images in both eyes, whereas four subjects (subjects 1, 6, 13, and 14) demonstrated morphological changes on OCT bilaterally. At follow-up, nine (82%) of the 11 *ABCA4* carriers showed some degree of abnormality on OCT, and one carrier (6 LE) had developed new subtle alterations in an eye that was normal at the initial examination.

General retinal function—All *ABCA4* carriers completed ffERG assessments using the same equipment both at the initial and follow-up examinations. The statistical comparison of the ffERG parameters for the right eye was made between the two time points (Wilcoxon signed-rank test) and showed significantly reduced amplitudes for the isolated dark-adapted rod response ($p=0.013$) and the b-wave amplitudes of the dark-adapted combined rod and cone response ($p=0.013$) at follow-up. The a-wave amplitudes for the combined rod and cone responses were also reduced with borderline significance ($p=0.050$). Box plots illustrating the results are shown in Figure 5. The amplitudes for the isolated 30-Hz flicker cone responses were not significantly altered. Table 5 shows the mean values of the ffERG parameters for

TABLE 3. DESCRIPTION OF FUNDUS PHOTOS AND FAF IMAGES. SUBJECTS HIGHLIGHTED IN BOLD WERE EXCLUDED FROM THE STUDY DUE TO THE NEWLY DETECTED PATHOGENIC *ABCA4* VARIANTS THAT COULD BE IN TRANS WITH THE ONE PREVIOUSLY FOUND.

Subject	Fundus photos; initial examination	Fundus photos; follow-up	FAF; initial examination	FAF; follow-up
1	normal	↑ OA; small drusen outside the vascular arcades and in the posterior pole along the vessels.	not tested	normal
2	normal	↑ OA; discrete pigmentary changes in the maculae and minimal localized yellowish spots close to the upper vascular arcade RE.	not tested	OA; small foci of reduced AF within the vascular arcades
3	normal	normal	normal	normal
4	normal	normal	normal	normal
5	LE; pigmentary changes in the macula	LE; unchanged pigmentary changes in the macula	LE; hyper-fluorescences in the macula	↑ LE; slightly enlarged area of increased AF in the macula RE; Small spots of reduced AF temporal to and above the macula.
6	normal	↑ LE; subtle pigmentary changes in the macula	not tested	LE; Reduced AF in the macula and small spots of hypofluorescence between the optic disc and macula
7	OA; subtle pigmentary changes in the maculae and along the vascular arcades	OA; unchanged subtle pigmentary changes in the maculae and along the vascular arcades	LE; small spots of increased and reduced AF around the vascular arcades	↑ OA; hyper - and hypo fluorescences around the vascular arcades and in the posterior pole
8 excluded	OA; pigmentary changes in the maculae and deep yellow spots in the posterior pole and mid-periphery	↑ OA; pigmentary changes in the maculae and a bit more wide- spread deep yellow spots in the posterior pole and midperiphery	OA; multiple foci of high and low AF signals	OA; unchanged multiple foci of high and low AF signals
10 excluded	OA; subtle pigmentary changes in the maculae	OA; unchanged subtle pigmentary changes in the maculae	normal	normal
11	normal	normal	normal	normal
12	OA; pigmentary changes in the maculae	↑ OA; pigmentary changes in the maculae, slight progress in the RE	normal	↑ OA; subtle small hypofluorescences in the posterior pole and nasal to the optic disc
13	normal	normal	normal	normal
14	RE; pigmentary changes in the macula	RE; pigmentary changes in the macula	RE; high AF signals in the macula and the temporal midperiphery	↑ RE; More pronounced FAF changes with foci of both increased and reduced AF signals in the macula and the temporal midperiphery LE; small foci of both high and low AF along the vascular arcade close to the optic nerve head

FAF=fundus autofluorescence, RE=right eye, LE=left eye, ↑ marks eyes with more changes at follow-up, OA=both eyes

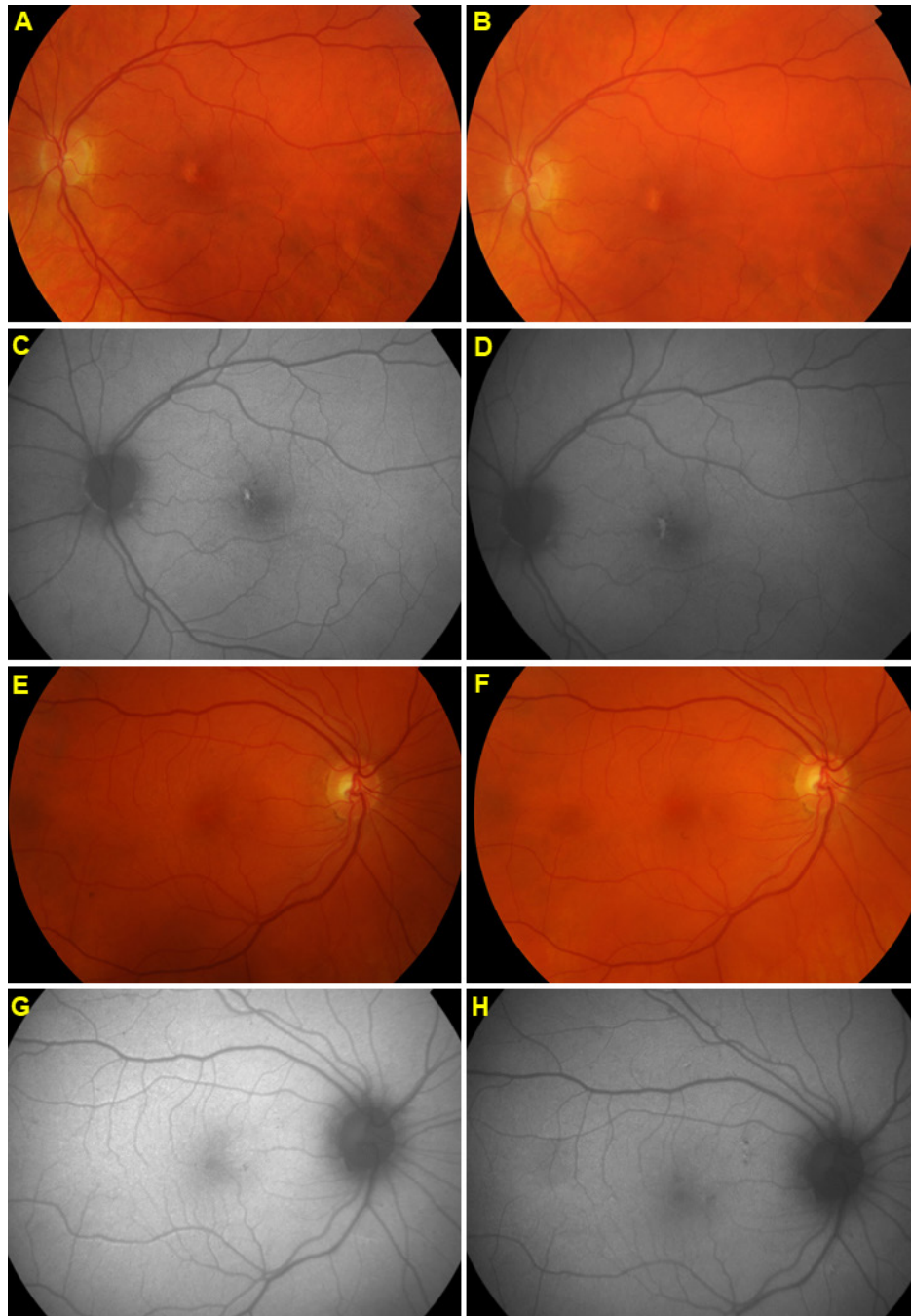


Figure 2. Fundus images in subject 5. **A:** Initial and **B:** follow-up examination show subtle pigmentary macular changes that were quite stable over the 5-year period. The central fundus autofluorescence (FAF) image **C:** at the initial examination shows a small central hyperfluorescence, which **D:** had slightly increased in size at the follow-up examination. The fundus photos from the **E:** initial and **F:** follow-up examinations of the right eye of Subject 7 also demonstrate stable mild pigmentary changes in the macula, whereas the FAF images show a discrete progress of the small spots of hyperfluorescence and hypofluorescence around the vascular arcades and in the posterior pole from **G:** the initial to **H:** the follow-up examinations.

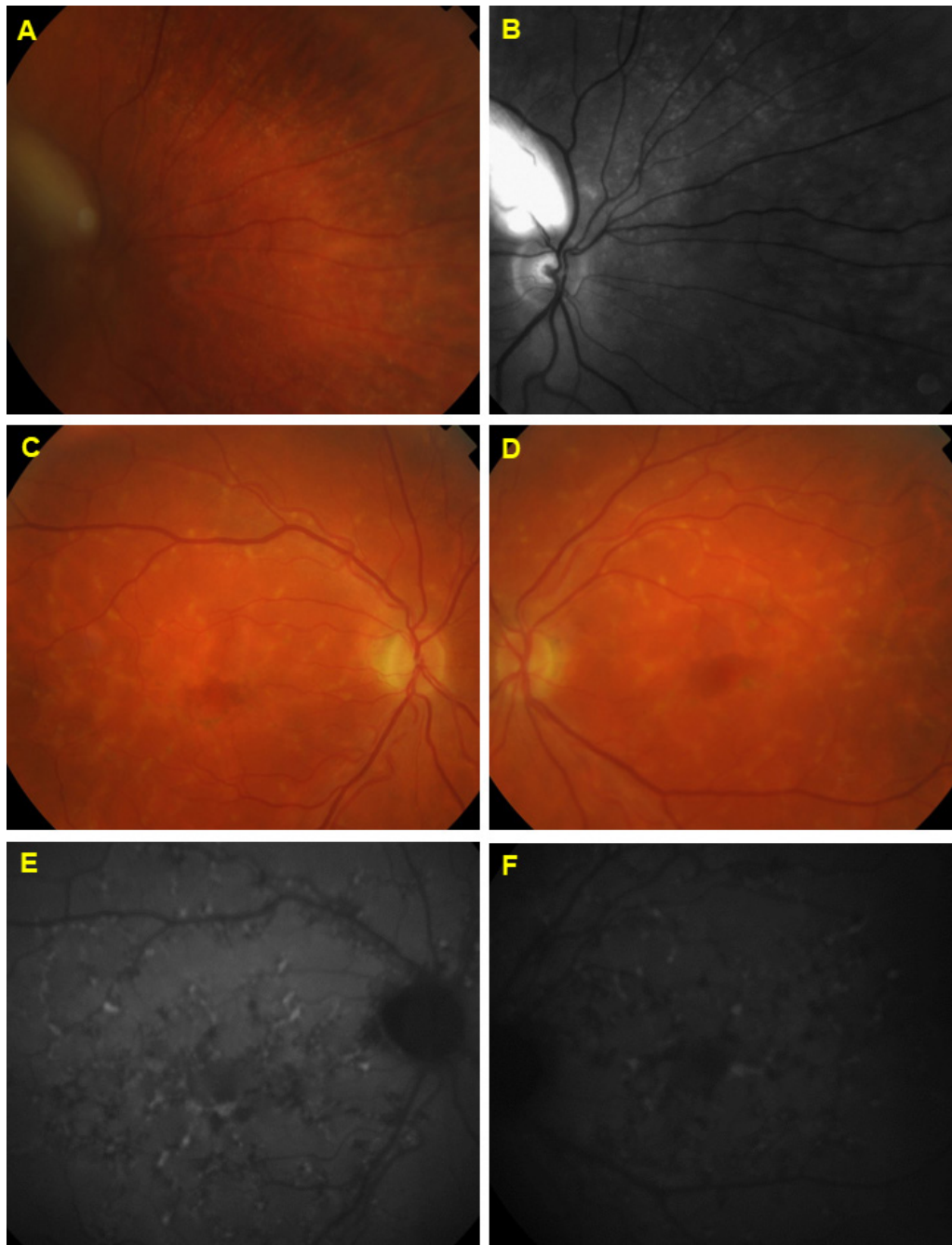


Figure 3. Fundus images. **A–D**: Fundus photographs. **E** and **F**: Fundus autofluorescence (FAF) images. The fundus photographs of Subject 1, both **A**: color and **B**: red-free, demonstrate small drusen scattered outside and inside the vascular arcades. The images also show myelinated retinal nerve fibers along the superior vascular arcade. **C** and **D**: Color fundus photographs of Subject 8, in whom the renewed genetic testing revealed an additional *ABCA4* mutation explaining the widespread deep orange-yellow retinal flecks around the macula and in the posterior pole, typical of Stargardt disease. **E** and **F**: The structural changes are even more evident on the FAF images, showing multiple foci of increased and reduced autofluorescence scattered in the entire posterior pole and outside the vascular arcades.

TABLE 4. DESCRIPTION OF OCT IMAGES IN THE *ABCA4* CARRIERS.

Subject	OCT findings RE initial examination	OCT findings LE initial examination	OCT findings RE at follow-up	OCT findings LE at follow-up
1	very subtle attenuation of the central EZ	not tested	very subtle attenuation of the central EZ	very subtle attenuation of the central EZ
2	very subtle attenuation of the central EZ	not tested	very subtle attenuation of the central EZ	N
3	very subtle attenuation of the central EZ	N	very subtle attenuation of the central EZ	N
4	N	N	N	N
5	N	subtle outer retinal disruption	N	subtle outer retinal disruption
6	subtle attenuation of the central EZ	N	subtle attenuation of the central EZ	↑very subtle attenuation of the central EZ
7	very subtle attenuation of the central EZ	N	very subtle attenuation of the central EZ	N
11	N	N	N	N
12	subtle disturbances in the central RPE	N	subtle disturbances in the central RPE	N
13	very subtle attenuation of the central EZ	very subtle attenuation of the central EZ	very subtle attenuation of the central EZ	very subtle attenuation of the central EZ
14	interruption of the EZ centrally and subretinal fluid	very subtle attenuation of the central EZ	scarring in the RPE centrally and interruption of the EZ	very subtle attenuation of the central EZ

RE=right eye, EZ=ellipsoid zone, LE=left eye, n=normal, ↑ marks eyes with new-found morphological changes, RPE=retinal pigment epithelium.

the subjects at the initial and follow-up examinations and the p values for the Wilcoxon signed-rank test results.

The comparison of right-eye fERG parameters between the *ABCA4* carriers and the controls (Mann–Whitney *U* test) did not show any significant differences. Nevertheless, five (45%; subjects 1, 2, 5, 6, and 12) of the eleven *ABCA4* carriers had at least one significantly reduced fERG parameter (Table 6) compared with the controls.

Macular function: mfERGs were recorded in all subjects both at the initial and follow-up examinations. Unfortunately, the mfERG VERIS equipment was updated during the 5-year follow-up, making the comparison between the two time points ambiguous. Therefore, the statistical comparison between the two time points was omitted, and the values of the mfERG parameters were only compared between the *ABCA4* carriers and the control group (Mann–Whitney *U* test), demonstrating reduced P1 amplitudes for all rings of the mfERG (A1–A5: A1, $p=0.024$; A2, $p=0.017$; A3, $p=0.002$; A4, $p=0.001$; and A5, $p=0.006$) and delayed P1 ITs for IT4 and IT5 (IT4: $p=0.039$; IT5: $p=0.003$) in *ABCA4* carriers compared with the controls. Table 7 shows the means and SDs of the mfERG amplitudes in the right eye of the *ABCA4* carriers

and controls, and the p values of the Mann–Whitney *U* test results.

DISCUSSION

In autosomal recessive monogenic disorders, carriers of a single heterozygous mutation are expected not to experience any symptoms or signs of the disease, nor are they supposed to present with reduced function in any organ system. Despite this, heterozygous mutations in the *ABCA4* gene have been suggested as a risk factor of AMD because the prevalence of certain *ABCA4* mutations are overrepresented in patients with AMD, up to fivefold for some mutations [26,36]. Likewise, Fritsche et al. [37] described a certain subtype of AMD presenting with a fine granular pattern and peripheral punctate spots that are significantly associated with heterozygous *ABCA4* mutations. Moreover, the prevalence of AMD has been shown to be significantly higher in the relatives of patients with STGD than in the general population, pointing toward a common genetic background [38,39]. Regarding retinal function, Maia-Lopes et al. [28] showed that the non-affected relatives of patients with STGD who were carrying a heterozygous *ABCA4* mutation presented with reduced

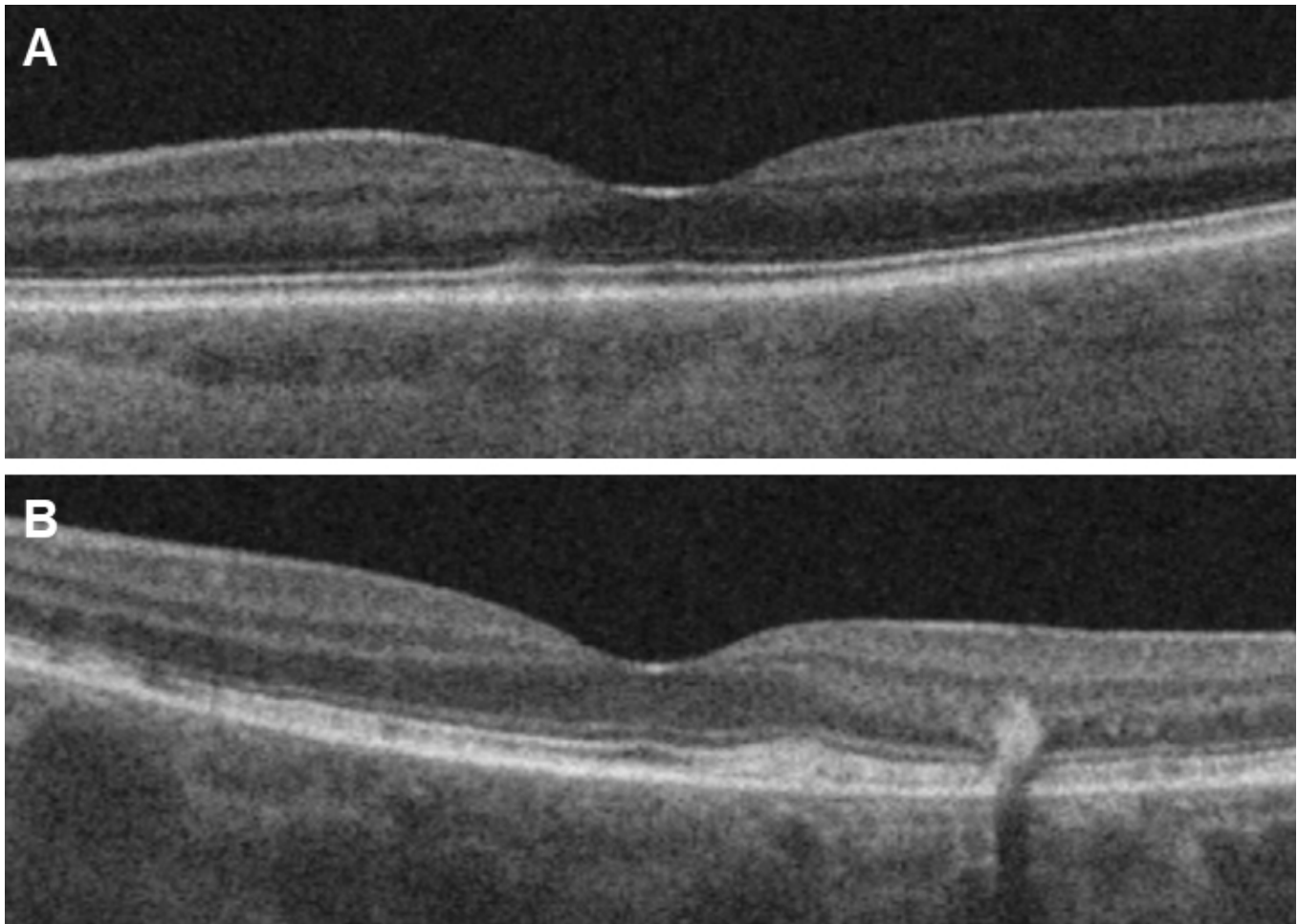


Figure 4. Optical coherence tomography. B-scans showing examples of **A**: mild changes with subtle outer retinal disruption (left eye of Subject 5) and **B**: alterations with more widespread outer retinal disruption (left eye of Subject 8) explained by the newly found additional *ABCA4* mutation.

parameters concerning both electrophysiological measurements (mfERG) and tests using psychophysical approaches. Likewise, in a previous survey [27] conducted to study the effects of single specific *ABCA4* mutations on retinal function and/or morphology, we investigated *ABCA4* carriers and, surprisingly, found reduced macular function measured by mfERG. *ABCA4* carriers were also found to have subtle and, in a few cases, more extensive morphological retinal changes on fundus photographs, fundus examinations, FAF and OCT. The aim of the present study was to conduct a 5-year follow-up of the same group of subjects to evaluate any changes of retinal status over time. As mentioned, the mfERG equipment, unfortunately, was updated during the 5-year follow-up. Therefore, no reliable comparison of the mfERG parameters could be made between the initial and follow-up measurement. When compared with the control group, the mfERG P1 amplitudes in the *ABCA4* carriers were

still reduced, and P1 implicit times were delayed in line with the results of the study of Maia-Lopes et al. [28]. Statistical analysis of the ffERG parameters, which reflect total retinal function and were recorded with exactly the same equipment on the follow-up and initial examinations, revealed a deterioration of the isolated rod function and combined rod and cone functions when responses at follow-up were compared with those at the initial assessment. Moreover, five subjects had reduced ffERG responses compared with the control group. Thus, over time, middle-aged *ABCA4* carriers appeared to also experience a more general reduction of photoreceptor function, including rods, although they did not seem to notice it subjectively. A similar phenomenon with reduced general rod function has been demonstrated in patients with early AMD showing both delayed rod-mediated dark adaptation [40-43] and reduced rod function on ffERG [41,44]. In one study [42], visual acuity, low luminance acuity, macular

TABLE 5. MEANS AND STANDARD DEVIATIONS FOR ffERG PARAMETERS IN THE RIGHT EYE ON INITIAL EXAMINATION AND ON FOLLOW-UP IN *ABCA4* CARRIERS. P VALUES FOR WILCOXON SIGNED RANKS TEST ARE ALSO GIVEN.

Various	Isolated rod response b-wave Ampl (μV)	Combined rod-cone response a-wave Ampl (μV)	Combined rod-cone response b-wave Ampl (μV)	30 Hz flicker cone response Ampl (μV)
Initial examination mean ± 1SD	252±59	202±52	380±88	52±12
Follow-up mean ± 1SD	207±42	167±39	322±69	50±14
P value Wilcoxon Signed Ranks Test	<i>0.013</i>	0.050	<i>0.013</i>	0.424

Ampl=amplitude, SD=standard deviation. Statistically significant p values are in italics.

light sensitivity, and spatial contrast sensitivity were normal, corresponding to the fact that all but two of our subjects did not notice any visual problems in daily life, although slight reduction in visual acuity was encountered in five of the 11 *ABCA4* carriers. This reflects that electrophysiological

measurement is more sensitive to incipient deterioration of retinal function than visual acuity testing. Forshaw et al. [45] also reported an association between macular dysfunction and reduced rod function in patients with AMD.

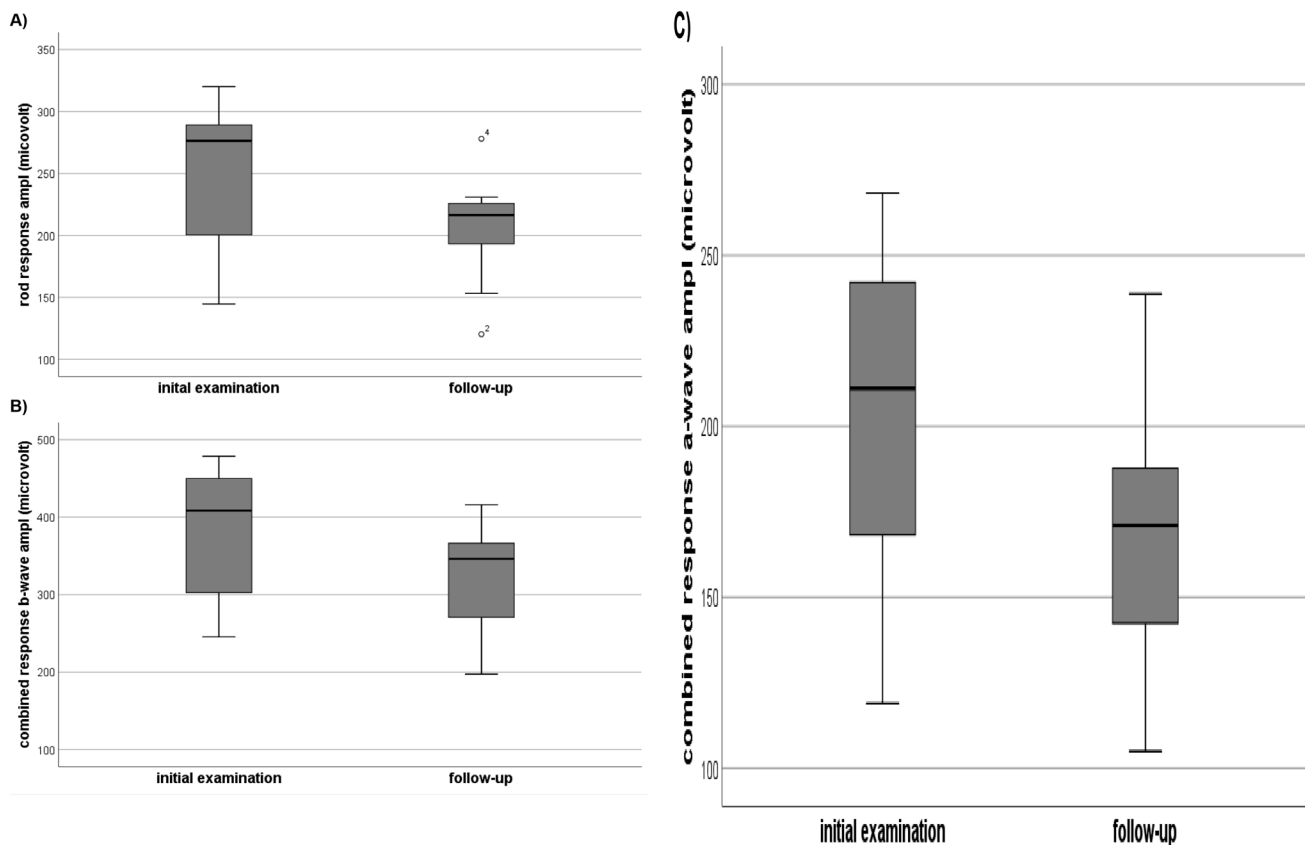


Figure 5. Box plots. Box plots showing **A**: isolated rod amplitudes (μV) on full-field electroretinography (ffERG) at the initial and follow-up examinations, **B**: combined rod and cone b-wave amplitudes (μV) on ffERG at the initial and follow-up examinations, and **C**: combined rod and cone a-wave amplitudes (μV) on ffERG at the initial and follow-up examinations. Boxes show the median and interquartile range. Bars illustrate the ranges. Circles and asterisks indicate outliers. Sample size: n=11 subjects. The statistical comparison of the ffERG parameters between the initial and follow-up examinations was made using the Wilcoxon signed-rank test.

TABLE 6. FFERG PARAMETERS IN *ABCA4* CARRIERS ON FOLLOW-UP AND THE MEANS ± 2SD FOR THE 20 CONTROL SUBJECTS.

Subject	Mutation/mutations	Isolated rod response b-wave Ampl (µV)	Combined rod-cone response a-wave Ampl (µV)	Combined rod-cone response a-wave Ampl (µV)	30 Hz flicker cone response Ampl (µV)	30 Hz flicker cone response IT (ms)
1	c.768 G>T	181	138	263	44	30.0
2	c.768 G>T	120	105	197	36	28.5
3	c.768 G>T	227	192	350	41	27.0
4	c.5461-10T>C +c.5603A>(cis)	278	183	406	78	31.5
5	c.319 C>T c.5603A>T (cis)	153	147	248	38	35.0
6	c.5917delG	216	148	279	52	29.0
7	c.2894 A>G	215	175	311	34	30.5
11	c.4469 G>A c.5603A>T (cis)	225	171	383	48	27.5
12	c.6079 C>T	206	129	347	45	31.0
13	c.2894 A>G	231	239	416	61	28.5
14	c.2894 A>G	220	213	346	70	29.5
Mean of controls ±2SD		302±120	228±94	443±162	63±38	30.0±3.0
Limits of normality		182	134	281	25	33.0

Ampl=amplitude, µV=micro volts, IT=implicit time, ms=milliseconds, SD=standard deviation Amplitudes lower than the mean -2 SD are considered pathologically reduced and are highlighted in bold and italics. Implicit times delayed more than the mean + 2SD are also considered pathological and highlighted in bold and italics.

In the present study, 64% of the *ABCA4* carriers showed morphological retinal alterations. The most prevalent findings were subtle pigmentary changes, quite similar to the pigmentary changes with hypopigmentations and hyperpigmentations observed in age-related maculopathy (ARM) and early dry AMD [46-48]. One subject also presented with drusen, which likewise can be associated with ARM and dry AMD [46-48]. When compared with those observed in the fundus photographs from the initial examination, retinal morphological changes at 5-year follow-up showed a subtle increase in 36% of the subjects. A similar slight increase in pathological alterations was also found in the FAF images.

The most pronounced changes were found in Subject 8, who demonstrated widespread deep yellow flecks in the posterior pole, typical of STGD. The changes could now be explained by the fact that the subject was carrying the c.5603A>T variant in addition to the previously found c.768 G>T variant. c.5603A>T was not reported as pathogenic at the initial genetic workup and has been shown quite recently to be the missing *ABCA4* variant in quite a few cases of late-onset *ABCA4*-associated retinal degeneration [34,35]. Subject 10, who might also be compound heterozygous for c.5603A>T and another *ABCA4* variant (c.1804 C>T), (although we could not be entirely sure that they are in trans because

TABLE 7. MEANS AND STANDARD DEVIATIONS FOR mfERG AMPLITUDES IN THE RIGHT EYE OF THE *ABCA4* CARRIERS AND THE CONTROLS, AS WELL AS P VALUES FOR THE MANN-WHITNEY U-TEST.

Various	mfERG ring 1 Ampl (µV/deg2)	mfERG ring 2 Ampl (µV/deg2)	mfERG ring 3 Ampl (µV/deg2)	mfERG ring 4 Ampl (µV/deg2)	mfERG ring 5 Ampl (µV/deg2)
<i>ABCA4</i> carriers mean ± 1SD	31±11	22±7	17±4	15±4	16±4
Controls mean ± 1SD	42±8	29±5	24±5	20±3	20±4
P value, Mann-Whitney U-test	<i>0.024</i>	<i>0.017</i>	<i>0.002</i>	<i>0.001</i>	<i>0.006</i>

Ampl=amplitude, SD=standard deviation. Statistically significant p values are in italics.

no co-segregation analysis could be performed), had a less typical phenotype with only subtle pigmentary changes in the maculae and a few reduced electrophysiological parameters. Similar findings with weak penetrance and variable expression of *ABCA4*-associated retinal degeneration in patients with the c.5603A>T variant were reported by Runhart et al. [35]. Identification of missing alleles is of great importance in the management of patients with a phenotype that fits with *ABCA4*-associated retinal degeneration, but in whom previous genetic analysis failed to confirm the genotype. Our study further supports the significance of the c.5603A>T variant as disease causing, thus hopefully helping more patients to receive a reliable diagnosis, which is important for both genetic counseling and accessing future novel gene-based therapies.

A widely used explanation of the broad variation of the severity of the different forms of retinal degenerations associated with *ABCA4* mutations (STGD, CRD, and arRP) is a model correlating the residual function of the ABCA4 protein to the extent of reduced retinal function [7,31,49-53]. In this model, on the basis of the calculated effect of the individual mutation on gene transcription and protein translation, null mutations, with no residual ABCA4 protein activity, are thought to be associated with the most severe forms of retinal dystrophies, and milder mutations only resulting in a defect protein are thought to cause milder entities. In line with this, carriership of a severe heterozygous *ABCA4* mutation causing absent or extremely reduced residual ABCA4 protein transport function could lead to extremely poor clearance of toxic retinoid metabolites, resulting over time in reduced retinal function also in *ABCA4* carriers, although carriers of autosomal recessive traits are not supposed to express the phenotype.

In the initial study [27], the c.768 G>T variant was considered a severe mutation associated with morphological retinal changes, marked macular dysfunction, and in one subject, also altered ffERG parameters. At follow-up, this pattern remained, still supporting previous studies classifying c.768 G>T as a rather serious mutation [3,54,55]. Concerning the c.2894 A>G, it seemed a bit milder in the initial study with normal ffERGs but still with moderate macular dysfunction in addition to OCT – and FAF alterations. The findings were similar at follow-up and in agreement with other studies describing c.2894 A>G as a quite serious mutation [54,56,57]. The remaining mutations were found in only one subject each; therefore, a thorough evaluation gets more uncertain. Nevertheless, c.319 C>T was still associated with a severe phenotype, and the subject with the c.4469 G>A variant still had a mild phenotype.

An important future perspective of a probable association between *ABCA4* carriership and, at least, some AMD subgroups could be the search for novel treatment options for the dry form of the disorder, as there are ongoing studies on gene therapy for *ABCA4*-associated retinal degenerations [58-60] and pharmacological approaches [61]. One shortcoming of our study is that we failed to include a control group followed up for >5 years in the same way as the *ABCA4* carriers. Thus, we cannot be entirely sure that aging is not a contributing factor to the reduced ffERG parameters over time.

Moreover, a larger number of subjects would have been advantageous, and finally, a comparison of mfERG parameters between the two time points would have been most interesting. Concerning the small number of subjects, the use of non-parametric statistical tests, to some extent, compensated for this. For the statistical analysis of mfERG results, we found it better to use a control group than to compare values obtained under non-equivalent conditions.

In conclusion, the 5-year follow-up of *ABCA4* carriers, previously presenting with reduced macular function, revealed deterioration also of general retinal function with reduced rod, - as well as combined rod-cone amplitudes measured by ffERG in combination with slight increase of morphological changes in some subjects over time, which suggests that carriership of pathological *ABCA4* mutations, may lead to a condition similar to a subgroup of AMD making this subgroup of AMD patients eligible for novel future gene-based – or pharmacological treatments. Moreover, we could confirm that in some cases of *ABCA4*-associated retinal degeneration with a missing allele, c.5603A>t testing could be useful for correct diagnosis; thereby, more patients can have access to optimized care.

ACKNOWLEDGMENTS

We would like to thank Ing-Marie Holst and Boel Nilsson for skillful technical assistance. Funding: The work was supported by the Medical Faculty, Lund University, and grants from; The Armec Lindbergs Stiftelse; Stiftelsen för synskadade i f.d. Malmöhus län; Stiftelsen Synfrämjandets Forskningsfond/Ögonfonden. Availability of data and material: The authors have full control of all primary data and agree to allow the journal to review the data on request. Authors' contributions: Both authors made substantial contributions to the design of the work, the acquisition, analysis and interpretation of data as well as drafting and revising of the content of the manuscript. Both authors also approve the version to be published and take responsibility for all aspects of the work. Ethical approvals: The study was conducted in

accordance with the Tenets of the Declaration of Helsinki and it was approved by the Ethical Committee for Medical Research at Lund University. Consent to participate: All subjects got a thorough written and oral explanation of the nature and possible consequences of the study and after that gave their written consent to participate. Consent for publication: All subjects gave their written consent to the publication of study results.

REFERENCES

- Allikmets R. Simple and complex *ABCR*: genetic predisposition to retinal disease. *Am J Hum Genet* 2000; 67:793-9. [PMID: 10970771].
- Allikmets R, Singh N, Sun H, Shroyer NF, Hutchinson A, Chidambaram A, Gerrard B, Baird L, Stauffer D, Peiffer A, Rattner A, Smallwood P, Li Y, Anderson KL, Lewis RA, Nathans J, Leppert M, Dean M, Lupski JR. A photoreceptor cell-specific ATP-binding transporter gene (*ABCR*) is mutated in recessive Stargardt macular dystrophy. *Nat Genet* 1997; 15:236-46. [PMID: 9054934].
- Klevering BJ, Deutman AF, Maugeri A, Cremers FP, Hoyng CB. The spectrum of retinal phenotypes caused by mutations in the *ABCA4* gene. *Graefes Arch Clin Exp Ophthalmol* 2005; 243:90-100. [PMID: 15614537].
- Lewis RA, Shroyer NF, Singh N, Allikmets R, Hutchinson A, Li Y, Lupski JR, Leppert M, Dean M. Genotype/Phenotype analysis of a photoreceptor-specific ATP-binding cassette transporter gene, *ABCR*, in Stargardt disease. *Am J Hum Genet* 1999; 64:422-34. [PMID: 9973280].
- Michaelides M, Hunt DM, Moore AT. The genetics of inherited macular dystrophies. *J Med Genet* 2003; 40:641-50. [PMID: 12960208].
- Birch DG, Peters AY, Locke KL, Spencer R, Megarity CF, Travis GH. Visual function in patients with cone-rod dystrophy (CRD) associated with mutations in the *ABCA4*(*ABCR*) gene. *Exp Eye Res* 2001; 73:877-86. [PMID: 11846518].
- Cremers FP, van de Pol DJ, van Driel M, den Hollander AI, van Haren FJ, Knoers NV, Tijmes N, Bergen AA, Rohrschneider K, Blankenagel A, Pinckers AJ, Deutman AF, Hoyng CB. Autosomal recessive retinitis pigmentosa and cone-rod dystrophy caused by splice site mutations in the Stargardt's disease gene *ABCR*. *Hum Mol Genet* 1998; 7:355-62. [PMID: 9466990].
- Fishman GA, Stone EM, Eliason DA, Taylor CM, Lindeman M, Derlacki DJ. *ABCA4* gene sequence variations in patients with autosomal recessive cone-rod dystrophy. *Arch Ophthalmol* 2003; 121:851-5. [PMID: 12796258].
- Klevering BJ, Blankenagel A, Maugeri A, Cremers FP, Hoyng CB, Rohrschneider K. Phenotypic spectrum of autosomal recessive cone-rod dystrophies caused by mutations in the *ABCA4* (*ABCR*) gene. *Invest Ophthalmol Vis Sci* 2002; 43:1980-5. [PMID: 12037008].
- Martinez-Mir A, Paloma E, Allikmets R, Ayuso C, del Rio T, Dean M, Vilageliu L, Gonzalez-Duarte R, Balcells S. Retinitis pigmentosa caused by a homozygous mutation in the Stargardt disease gene *ABCR*. *Nat Genet* 1998; 18:11-2. [PMID: 9425888].
- Schroeder M, Kjellstrom U. Full-field ERG as a predictor of the natural course of *ABCA4*-associated retinal degenerations. *Mol Vis* 2018; 24:1-16. [PMID: 29386879].
- Azarian SM, Travis GH. The photoreceptor rim protein is an ABC transporter encoded by the gene for recessive Stargardt's disease (*ABCR*). *FEBS Lett* 1997; 409:247-52. [PMID: 9202155].
- Molday LL, Rabin AR, Molday RS. *ABCR* expression in foveal cone photoreceptors and its role in Stargardt macular dystrophy. *Nat Genet* 2000; 25:257-8. [PMID: 10888868].
- Sun H, Nathans J. Stargardt's *ABCR* is localized to the disc membrane of retinal rod outer segments. *Nat Genet* 1997; 17:15-6. [PMID: 9288089].
- Quazi F, Lenevich S, Molday RS. *ABCA4* is an N-retinylidene-phosphatidylethanolamine and phosphatidylethanolamine importer. *Nat Commun* 2012; 3:925-[PMID: 22735453].
- Tsybovsky Y, Molday RS, Palczewski K. The ATP-binding cassette transporter *ABCA4*: structural and functional properties and role in retinal disease. *Adv Exp Med Biol* 2010; 703:105-25. [PMID: 20711710].
- Weng J, Mata NL, Azarian SM, Tzekov RT, Birch DG, Travis GH. Insights into the function of Rim protein in photoreceptors and etiology of Stargardt's disease from the phenotype in *abcr* knockout mice. *Cell* 1999; 98:13-23. [PMID: 10412977].
- Kim SR, Jang YP, Jockusch S, Fishkin NE, Turro NJ, Sparrow JR. The all-trans-retinal dimer series of lipofuscin pigments in retinal pigment epithelial cells in a recessive Stargardt disease model. *Proc Natl Acad Sci USA* 2007; 104:19273-8. [PMID: 18048333].
- Yamamoto K, Yoon KD, Ueda K, Hashimoto M, Sparrow JR. A novel bisretinoid of retina is an adduct on glycerophosphoethanolamine. *Invest Ophthalmol Vis Sci* 2011; 52:9084-90. [PMID: 22039245].
- Mata NL, Weng J, Travis GH. Biosynthesis of a major lipofuscin fluorophore in mice and humans with *ABCR*-mediated retinal and macular degeneration. *Proc Natl Acad Sci USA* 2000; 97:7154-9. [PMID: 10852960].
- Conley SM, Cai X, Makkia R, Wu Y, Sparrow JR, Naash MI. Increased cone sensitivity to *ABCA4* deficiency provides insight into macular vision loss in Stargardt's dystrophy. *Biochim Biophys Acta* 2012; 1822:1169-79. [PMID: 22033104].
- Fakin A, Robson AG, Fujinami K, Moore AT, Michaelides M, Pei-Wen Chiang J, Holder GE, Webster AR. Phenotype and Progression of Retinal Degeneration Associated With Nullizigosity of *ABCA4*. *Invest Ophthalmol Vis Sci* 2016; 57:4668-78. [PMID: 27583828].
- Gomes NL, Greenstein VC, Carlson JN, Tsang SH, Smith RT, Carr RE, Hood DC, Chang S. A comparison of fundus

- autofluorescence and retinal structure in patients with Stargardt disease. *Invest Ophthalmol Vis Sci* 2009; 50:3953-9. [PMID: 19324865].
24. Khan KN, Kasilian M, Mahroo OAR, Tanna P, Kalitzeos A, Robson AG, Tsunoda K, Iwata T, Moore AT, Fujimani K, Michaelides M. Early Patterns of Macular Degeneration in *ABCA4*-Associated Retinopathy. *Ophthalmology* 2018; 125:735-46. [PMID: 29310964].
 25. Mullins RF, Kuehn MH, Radu RA, Enriquez GS, East JS, Schindler EI, Travis GH, Stone EM. Autosomal recessive retinitis pigmentosa due to *ABCA4* mutations: clinical, pathologic, and molecular characterization. *Invest Ophthalmol Vis Sci* 2012; 53:1883-94. [PMID: 22395892].
 26. Allikmets R. Further evidence for an association of *ABCR* alleles with age-related macular degeneration. The International ABCR Screening Consortium. *Am J Hum Genet* 2000; 67:487-91. [PMID: 10880298].
 27. Kjellstrom U. Reduced macular function in *ABCA4* carriers. *Mol Vis* 2015; 21:767-82. [PMID: 26261413].
 28. Maia-Lopes S, Silva ED, Silva MF, Reis A, Faria P, Castelo-Branco M. Evidence of widespread retinal dysfunction in patients with stargardt disease and morphologically unaffected carrier relatives. *Invest Ophthalmol Vis Sci* 2008; 49:1191-9. [PMID: 18326749].
 29. Shroyer NF, Lewis RA, Yatsenko AN, Wensel TG, Lupski JR. Cosegregation and functional analysis of mutant *ABCR* (*ABCA4*) alleles in families that manifest both Stargardt disease and age-related macular degeneration. *Hum Mol Genet* 2001; 10:2671-8. [PMID: 11726554].
 30. Jaakson K, Zernant J, Kulm M, Hutchinson A, Tonisson N, Glavac D, Ravnik-Glavac M, Hawlina M, Meltzer MR, Caruso RC, Testa F, Maugeri A, Hoyng CB, Gouras P, Simonelli F, Lewis RA, Lupski JR, Cremers FP, Allikmets R. Genotyping microarray (gene chip) for the *ABCR* (*ABCA4*) gene. *Hum Mutat* 2003; 22:395-403. [PMID: 14517951].
 31. Yatsenko AN, Shroyer NF, Lewis RA, Lupski JR. Late-onset Stargardt disease is associated with missense mutations that map outside known functional regions of *ABCR* (*ABCA4*). *Hum Genet* 2001; 108:346-55. [PMID: 11379881].
 32. Marmor MF, Fulton AB, Holder GE, Miyake Y, Brigell M, Bach M. ISCEV Standard for full-field clinical electroretinography (2008 update). *Doc Ophthalmol* 2009; 118:69-77. [PMID: 19030905].
 33. Robson AG, Nilsson J, Li S, Jalali S, Fulton AB, Tormene AP, Holder GE, Brodie SE. ISCEV guide to visual electrodiagnostic procedures. *Doc Ophthalmol* 2018; 136:1-26. [PMID: 29397523].
 34. Zernant J, Lee W, Collison FT, Fishman GA, Sergeev YV, Schuerch K, Sparrow JR, Tsang SH, Allikmets R. Frequent hypomorphic alleles account for a significant fraction of *ABCA4* disease and distinguish it from age-related macular degeneration. *J Med Genet* 2017; 54:404-412. [PMID: 28446513].
 35. Runhart EH, Sangermano R, Cornelis SS, Verheij J, Plomp AS, Boon CJF, Lugtenberg D, Bax NM, Blokland EAW, Jacobs-Camps MHM, van der Velde-Visser SD, Pott JWR, Rohrschneider K, Thiadens AAH, Klaver CWC, van den Born LI, Hoyng CB, Cremers FPM. The Common *ABCA4* Variant p.Asn1868Ile Shows Nonpenetrance and Variable Expression of Stargardt Disease When Present in trans With Severe Variants. *Invest Ophthalmol Vis Sci* 2018; 59:3220-31. [PMID: 29971439].
 36. Allikmets R, Shroyer NF, Singh N, Seddon JM, Lewis RA, Bernstein PS, Peiffer A, Zabriskie NA, Li Y, Hutchinson A, Dean M, Lupski JR, Leppert M. Mutation of the Stargardt disease gene (*ABCR*) in age-related macular degeneration. *Science* 1997; 277:1805-7. [PMID: 9295268].
 37. Fritsche LG, Fleckenstein M, Fiebig BS, Schmitz-Valckenberg S, Bindewald-Wittich A, Keilhauer CN, Renner AB, Mackensen F, Mossner A, Pauleikhoff D, Adrion C, Mansmann U, Scholl HP, Holz FG, Weber BH. A subgroup of age-related macular degeneration is associated with mono-allelic sequence variants in the *ABCA4* gene. *Invest Ophthalmol Vis Sci* 2012; 53:2112-8. [PMID: 22427542].
 38. Hyman LG, Lilienfeld AM, Ferris FL 3rd, Fine SL. Senile macular degeneration: a case-control study. *Am J Epidemiol* 1983; 118:213-27. [PMID: 6881127].
 39. Seddon JM, Ajani UA, Mitchell BD. Familial aggregation of age-related maculopathy. *Am J Ophthalmol* 1997; 123:199-206. [PMID: 9186125].
 40. Dimitrov PN, Robman LD, Varsamidis M, Aung KZ, Makeyeva G, Busija L, Vingrys AJ, Guymer RH. Relationship between clinical macular changes and retinal function in age-related macular degeneration. *Invest Ophthalmol Vis Sci* 2012; 53:5213-20. [PMID: 22714893].
 41. Dimopoulos IS, Tennant M, Johnson A, Fisher S, Freund PR, Sauve Y. Subjects with unilateral neovascular AMD have bilateral delays in rod-mediated phototransduction activation kinetics and in dark adaptation recovery. *Invest Ophthalmol Vis Sci* 2013; 54:5186-95. [PMID: 23821195].
 42. Owsley C, Huisingh C, Clark ME, Jackson GR, McGwin G Jr. Comparison of Visual Function in Older Eyes in the Earliest Stages of Age-related Macular Degeneration to Those in Normal Macular Health. *Curr Eye Res* 2016; 41:266-72. [PMID: 25802989].
 43. Tahir HJ, Rodrigo-Diaz E, Parry NRA, Kelly JMF, Carden D, Aslam TM, Murray IJ. Slowed Dark Adaptation in Early AMD: Dual Stimulus Reveals Scotopic and Photopic Abnormalities. *Invest Ophthalmol Vis Sci* 2018; 59:AMD202-10. [PMID: 30398565].
 44. Walter P, Widder RA, Luke C, Konigsfeld P, Brunner R. Electrophysiological abnormalities in age-related macular degeneration. *Graefes Arch Clin Exp Ophthalmol* 1999; 237:962-8. [PMID: 10654164].
 45. Forshaw TRJ, Ahmed HJ, Kjaer TW, Andreasson S, Sorensen TL. Full-field Electroretinography in Age-related Macular Degeneration: can retinal electrophysiology predict the

- subjective visual outcome of cataract surgery? *Acta ophthalmologica*. 2020; 98:693-700. [PMID: 32275357].
46. Bandello F, Sacconi R, Querques L, Corbelli E, Cicinelli MV, Querques G. Recent advances in the management of dry age-related macular degeneration: A review. *F1000 Res* 2017; 6:245-[PMID: 28529701].
 47. Bird AC, Bressler NM, Bressler SB, Chisholm IH, Coscas G, Davis MD, de Jong PT, Klaver CC, Klein BE, Klein R. An international classification and grading system for age-related maculopathy and age-related macular degeneration. The International ARM Epidemiological Study Group. *Surv Ophthalmol* 1995; 39:367-74. [PMID: 7604360].
 48. Neelam K, Nolan J, Chakravarthy U, Beatty S. Psychophysical function in age-related maculopathy. *Surv Ophthalmol* 2009; 54:167-210. [PMID: 19298899].
 49. Burke TR, Tsang SH. Allelic and phenotypic heterogeneity in *ABCA4* mutations. *Ophthalmic Genet* 2011; 32:165-74. [PMID: 21510770].
 50. Gerth C, Andrassi-Darida M, Bock M, Preising MN, Weber BH, Lorenz B. Phenotypes of 16 Stargardt macular dystrophy/fundus flavimaculatus patients with known *ABCA4* mutations and evaluation of genotype-phenotype correlation. *Graefes Arch Clin Exp Ophthalmol* 2002; 240:628-38. [PMID: 12192456].
 51. Maugeri A, Flothmann K, Hemmrich N, Ingvast S, Jorge P, Paloma E, Patel R, Rozet JM, Tammur J, Testa F, Balcells S, Bird AC, Brunner HG, Hoyng CB, Metspalu A, Simonelli F, Allikmets R, Bhattacharya SS, D'Urso M, González-Duarte R, Kaplan J, te Meerman GJ, Santos R, Schwartz M, Van Camp G, Wadelius C, Weber BHF, Cremers FPM. The *ABCA4* 2588G>C Stargardt mutation: single origin and increasing frequency from South-West to North-East Europe. *European journal of human genetics Eur J Hum Genet* 2002; 10:197-203. [PMID: 11973624].
 52. Shroyer NF, Lewis RA, Allikmets R, Singh N, Dean M, Leppert M, Lupski JR. The rod photoreceptor ATP-binding cassette transporter gene, *ABCR*, and retinal disease: from monogenic to multifactorial. *Vision Res* 1999; 39:2537-44. [PMID: 10396622].
 53. van Driel MA, Maugeri A, Klevering BJ, Hoyng CB, Cremers FP. *ABCR* unites what ophthalmologists divide(s). *Ophthalmic Genet* 1998; 19:117-22. [PMID: 9810566].
 54. Kjellstrom U. Association between genotype and phenotype in families with mutations in the *ABCA4* gene. *Mol Vis* 2014; 20:89-104. [PMID: 24453473].
 55. Westeneng-van Haften SC, Boon CJ, Cremers FP, Hoefsloot LH, den Hollander AI, Hoyng CB. Clinical and genetic characteristics of late-onset Stargardt's disease. *Ophthalmology* 2012; 119:1199-210. [PMID: 22449572].
 56. Rosenberg T, Klie F, Garred P, Schwartz M. N965S is a common *ABCA4* variant in Stargardt-related retinopathies in the Danish population. *Mol Vis* 2007; 13:1962-9. [PMID: 17982420].
 57. Testa F, Rossi S, Sodi A, Passerini I, Di Iorio V, Della Corte M, Banfi S, Surace EM, Menchini U, Auricchio A, Simonelli F. Correlation between photoreceptor layer integrity and visual function in patients with Stargardt disease: implications for gene therapy. *Invest Ophthalmol Vis Sci* 2012; 53:4409-15. [PMID: 22661472].
 58. Auricchio A, Trapani I, Allikmets R. Gene Therapy of *ABCA4*-Associated Diseases. *Cold Spring Harb Perspect Med* 2015; 5:a017301-[PMID: 25573774].
 59. Han Z, Conley SM, Naash MI. Gene therapy for Stargardt disease associated with *ABCA4* gene. *Adv Exp Med Biol* 2014; 801:719-24. [PMID: 24664763].
 60. Takahashi VKL, Takiuti JT, Jauregui R, Tsang SH. Gene therapy in inherited retinal degenerative diseases, a review. *Ophthalmic Genet* 2018; 39:560-8. [PMID: 30040511].
 61. Sears AE, Bernstein PS, Cideciyan AV, Hoyng C, Charbel Issa P, Palczewski K, Rosenfeld PJ, Sadda S, Schraermeyer U, Sparrow JR, Washington I, Scholl HPN. Towards Treatment of Stargardt Disease: Workshop Organized and Sponsored by the Foundation Fighting Blindness. *Transl Vis Sci Technol* 2017; 6:6-[PMID: 28920007].

Articles are provided courtesy of Emory University and the Zhongshan Ophthalmic Center, Sun Yat-sen University, P.R. China. The print version of this article was created on 1 October 2022. This reflects all typographical corrections and errata to the article through that date. Details of any changes may be found in the online version of the article.