

Bronchoscopic Ethanolamine Injection Therapy in Patients with Persistent Air Leak from Chest Tube Drainage

Ah Leum Lim, M.D.¹, Cheol-Hong Kim, M.D.¹, Yong Il Hwang, M.D.¹, Chang Youl Lee, M.D.¹, Jeong-Hee Choi, M.D.¹, Taerim Shin, M.D.¹, Yong-Bum Park, M.D.¹, Seung-Hun Jang, M.D.¹, Sang Myeon Park, M.D.¹, Dong-Gyu Kim, M.D.¹, Myung Goo Lee, M.D.¹, In-Gyu Hyun, M.D.¹, Ki-Suck Jung, M.D.¹, Ho-Seung Shin, M.D.²

Departments of ¹Internal Medicine and ²Thoracic and Cardiovascular Surgery, Hallym University College of Medicine, Seoul, Korea

Background: Chest tube drainage (CTD) is an indication for the treatment of pneumothorax, hemothorax and is used after a thoracic surgery. But, in the case of incomplete lung expansion, and/or persistent air leak from CTD, medical or surgical thoracoscopy or, if that is unavailable, limited thoracotomy, should be considered. We evaluate the efficacy of bronchoscopic injection of ethanolamine to control the persistent air leak in patients with CTD.

Methods: Patients who had persistent or prolonged air leak from CTD were included, consecutively. We directly injected 1.0 mL solution of 5% ethanolamine oleate into a subsegmental or its distal bronchus, where it is a probable air leakage site, 1 to 21 times using an injection needle through a fiberoptic bronchoscope.

Results: A total of 15 patients were enrolled; 14 cases of spontaneous pneumothorax [idiopathic 9, chronic obstructive pulmonary disease (COPD) 3, post-tuberculosis 2] and one case of empyema associated with broncho-pleural fistula. Of these, five were patients with persistent air leak from CTD, just after a surgical therapy, wedge resection with plication for blebs or bullae. With an ethanolamine injection therapy, 12 were successful but three (idiopathic, COPD and post-tuberculosis) failed, and were followed by a surgery (2 cases) or pleurodesis (1 case). Some adverse reactions, such as fever, chest pain and increased radiographic opacities occurred transiently, but resolved without any further events. With success, the time from the procedure to discharge was about 3 days (median).

Conclusion: Bronchoscopic ethanolamine injection therapy may be partially useful in controlling air leakage, and reducing the hospital stay in patients with persistent air leak from CTD.

Key Words: Bronchoscopy; Chest Tubes; Ethanolamine; Pneumothorax

Introduction

If there is a communication between alveoli and pleura, the air in the pleural space is observed on chest radiography. It is also seen in the cases with direct communication between atmosphere and pleural space, or the presence of gas-producing organisms in the pleural

space. It includes pneumothorax and bronchopleural fistula. They are caused by idiopathic and may also occur after traumatic, invasive interventions or pulmonary resection. The goal of the treatment is to remove the air present in the pleural space and to prevent secondary recurrence. Chest tube drainage is the most commonly used treatment method. If thoracoscopy is selected, transient chest tube drainage may also be required.

During the treatment of chest tube drainage, air leak may be persistent from the tube. It is mainly attributable to the presence of bronchopleural fistula or air leak through the bronchiole, which requires medical or surgical treatment. If a surgical treatment is difficult to per-

Address for correspondence: **Cheol-Hong Kim, M.D.**

Department of Internal Medicine, Hallym University
Hangang Sacred Heart Hospital, 94-200, Yeongdeungpo-dong,
Yeongdeungpo-gu, Seoul 150-719, Korea
Phone: 82-2-2639-5787, Fax: 82-2-2677-9756
E-mail: kimch2002@hallym.or.kr

Received: Jan. 19, 2012

Revised: Feb. 6, 2012

Accepted: Apr. 14, 2012

form due to underlying illness, medical treatments should be selected. The flexible bronchoscopy has allowed us to close the fistula using tissue glues, fibrin glues, sealants or sclerong agents¹⁻⁴.

We hypothesized that there were certain communications between alveoli (or bronchioles) and pleural space in patients with persistent air leak from the chest tube. Thus, we instilled ethanolamine solution into the target bronchus bronchoscopically and evaluate the clinical outcomes after this therapy. This procedure may reduce medical costs and the duration of hospitalization.

Materials and Methods

1. Subjects

During chest tube drainage for pneumothorax or empyema, the patients who had persistent air leak and incomplete expansion of the lung due to the air in the pleural space were included. All patients provided written informed consent, and they agreed to be treated with bronchoscopic ethanolamine injection. But, in the cases of bronchopleural fistula formation after pulmonary resection, they were excluded in this study because surgical correction needed to be inevitable.

2. Methods

For bronchoscopic preparations, meperidine 25~50 mg and atropine sulfate 0.5 mg were injected intramuscularly 15~30 minutes before the bronchoscopy. If necessary, midazolam 1.0~2.0 mg was injected intravenously for further sedation. Before beginning the procedure, the patients were nebulized by 2% lidocaine hydrochloride 10 mL for the local anesthetic effect of the oropharynx.

Bronchoscopy was conducted to identify the presence of endobronchial lesions by conventional methods. If bronchopleural fistula was seen grossly during bronchoscopy, 5% ethanolamine oleate 1.0 mL was instilled to the surrounding mucosa of the orifice repeatedly via the injection needle inserted through the bronchoscopic biopsy channel.

If no lesion was found, the bronchoscope was fixed

to the lobar bronchus that was most likely to have the air leak sites. In consideration of radiologic and post-operative findings, we select segmental or subsegmental bronchus and wedge the target bronchus with the bronchoscope. Then, the patients were asked to cough to see if air bubbles from the chest tube were significantly reduced or halted. If so, it was concluded that air leak occurred through the segmental (or subsegmental) bronchus. The injection catheter was placed in the target bronchus for passing through bronchoscopic channel and catheter tip out from the distal end. The aliquots of 5% ethanolamine oleate 1.0 mL were injected through the catheter repeatedly. If the patients complained of discomfort or pain during the procedure, the therapy was discontinued.

If air leak from the chest tube was halted by ethanolamine injection therapy and the chest tube was removed from the patients after the complete expansion of the lung, the treatment was considered to be successful. If other treatments such as surgery were required, however, the treatment was considered to be unsuccessful.

Results

1. Basal clinical characteristics

A total of 15 patients were enrolled in the study. They were all male patients aged 16~75 years. The clinical manifestations of the patients consisted of 14 cases (primary 7 cases, recurrent 7 cases) of pneumothorax and one case of hydro-pneumothorax. Underlying lung diseases included 9 cases of idiopathic (60%), 3 cases of chronic obstructive pulmonary disease (COPD, 20%), 2 cases of tuberculosis or past history of tuberculosis (13.3%), and once case of empyema associated with bronchopleural fistula (6.7%). Among the seven patients with recurrent pneumothorax, five patients had a previous history of surgical treatments (Table 1).

Five patients had incomplete lung expansions due to persistent air leak despite a surgical treatment for apical bleb during the admission (Table 2). A chest computed tomography (CT) was done in 13 patients, among

Table 1. Patients characteristics

No.	Age (yr)	Gender	Clinical manifestation	Underlying causes	Past history of surgical treatment
1	75	Male	Spontaneous pneumothorax, recurrent	Post-TBc	Wedge resection with bullae plication
2	21	Male	Spontaneous pneumothorax, 1st	Idiopathic	-
3	22	Male	Spontaneous pneumothorax, recurrent	Idiopathic	-
4	63	Male	Spontaneous pneumothorax, recurrent	COPD	-
5	20	Male	Spontaneous pneumothorax, recurrent	Idiopathic	Wedge resection with bullae plication
6	20	Male	Spontaneous pneumothorax, recurrent	Idiopathic	Wedge resection with bullae plication
7	17	Male	Spontaneous pneumothorax, 1st	Idiopathic	-
8	27	Male	Spontaneous pneumothorax, 1st	Idiopathic	-
9	56	Male	Broncho-pleural fistula	Empyema	-
10	16	Male	Spontaneous pneumothorax, recurrent	Idiopathic	Wedge resection with bullae plication
11	20	Male	Spontaneous pneumothorax, 1st	Idiopathic	-
12	57	Male	Spontaneous pneumothorax, 1st	COPD	-
13	28	Male	Spontaneous pneumothorax, 1st	Post-TBc	-
14	16	Male	Spontaneous pneumothorax, 1st	Idiopathic	-
15	72	Male	Spontaneous pneumothorax, recurrent	COPD	Wedge resection with bullae plication

TBc: tuberculosis; COPD: chronic obstructive pulmonary disease.

Table 2. Treatment outcome

No.	Initial treatment	Bronchoscopic ETOH Tx	Frequency of ETOH injection	Outcome	Time from CTD to initial ETOH (day)	Time from last ETOH to CTD removal (day)	Time from last ETOH to discharge (day)
1	CTD	3 times	21	Success	7	2	2
2	Wedge resection+CTD	Once	10	Success	1	5	6
3	CTD	Once	10	Success	3	4	5
4	CTD	Once	5	Success	3	1	1
5	CTD	Once	5	Success	2	3	3
6	CTD	Once	10	Success	2	2	2
7	Wedge resection+CTD	Once	5	Success	10	2	2
8	Wedge resection+CTD	Once	5	Success	4	3	3
9	CTD	Once	10	Success	18	11	13
10	CTD	Once	10	Success	1	3	3
11	CTD	Twice	20	Fail*	3	9	9
12	CTD	Once	10	Fail [†]	12	4	4
13	CTD	Twice	15	Fail*	2	7	7
14	Wedge resection+CTD	Once	10	Success	5	3	3
15	Wedge resection+CTD	Once	10	Success	7	5	6

*Wedge resection with bullae plication done, [†]Autologous blood patch pleurodesis done.
ETOH: ethanolamine; Tx: treatment; CTD: chest tube drainage.

whom blebs or bullae were observed in 12 patients and pleural effusion was observed in one patient.

2. Treatment outcomes

Ethanolamine injection therapy was conducted 1~3 times: once in 12 patients (80%), twice in two patients

(13.3%), and three times in one patient (6.7%). The total injection amount of ethanolamine was between 5 mL (minimum) and 21 mL (maximum). An Ethanolamine injection therapy was initiated 1~18 days (median, 3.5 days) after the initiation of chest tube drainage. In the cases of pneumothorax with surgical therapy (5 cases),

an ethanolamine was injected 0~8 days (median, 2 days) after the operation. Successful outcomes were shown in 12 patients (80%). Meanwhile, the treatment was considered unsuccessful in the three patients (20%), followed by additional surgery in two patients and an autologous blood patch pleurodesis in one patient. In the cases of successful treatment, 1~11 days (median, 3 days) were needed for the removal of the chest tube and 1~13 days (median, 3 days) were taken to discharge from the hospital (Table 2).

3. Complication

After an ethanolamine injection therapy, the patients experienced any of the following adverse reactions: fever (4 cases, 26.7%), chest pain (2 cases, 13.3%), fever and chest pain (4 cases, 26.7%). Radiographic findings after ethanolamine therapy showed no significant changes (6 cases, 40%), patchy pulmonary infiltrations (8 cases, 83.3%), and hydropneumothorax (1 case, 6.7%). All of them showed transient courses and were gradually resolved clinically and radiographically as time passed by.

Discussion

An ethanolamine injection therapy was initially introduced to control gastrointestinal bleeding⁵. It is also used for the extracting an intraluminal polypoid tumor that is protruding into the airway in respiratory area⁶. An ethanolamine injection therapy is effective in inducing rapid dehydration and scar formation of the tissue. These effects are also applied to the treatment of early gastric cancer as regional edema, necrosis and ulcer for-

mation are anticipated with local injection of ethanolamine solution^{5,7}. Histologically, fibroblast proliferation and tissue reconstruction by fibrous scar can be observed within three weeks^{2,7}. The authors focused on the regional edema and chemical inflammatory reaction of an ethanolamine on tissues. Accordingly, this study was conducted to investigate the effect of ethanolamine injection therapy in patients with pneumothorax, particularly, those who were unable to remove the chest tube quickly due to persistent air leak from chest tube drainage.

An ethanolamine injection therapy was conducted in 15 patients (pneumothorax 14 cases, empyema one case caused by bronchopleural fistula). The catheter was fixed to the segmental bronchus that was suspected to have air leak, and the aliquots of 5% ethanolamine oleate 1.0 mL were slowly injected 5~21 times through the catheter. Because the rapid injection of high dose has been reported to cause deep ulcer and tissue toxicity, leading to necrosis in the tissue^{5,6}, an ethanolamine solution was slowly injected at a low dose in this study. As a result, the chest tube was successfully removed from 12 patients (88%).

In Figure 1 (case 1), a recurrent large pneumothorax in left side occurred in a 75-year-old male patient who had been on the outpatient department for post-tuberculous bronchiectasis and emphysematous lung. Despite chest tube drainage, the lung was not expanded fully and a large amount of air leak via the chest tube was persistent until 7 days later. Thus, a surgical treatment was required. However, as his sputum acid-fast bacillus smear and post-bronchodilator forced expiratory volume in one second was shown to be pos-

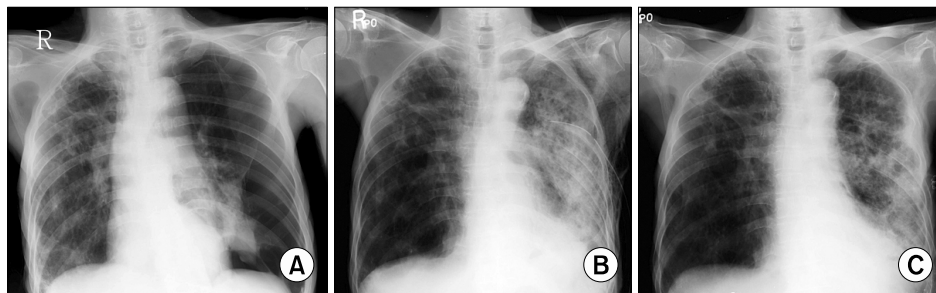


Figure 1. Case 1. A 75-year-old male patient who had past history of tuberculosis. Spontaneous pneumothorax, recurrent (A), 2 and 3 days after ethanolamine injection therapy (B, C).

itive and only 630 mL (27% of predicted value) respectively, he had a high risk for surgical treatment. Thus, the patient underwent bronchoscopic ethanolamine injection therapy total three times. Thereafter, air leak was halted and the lung was fully expanded, and so the chest tube was successfully removed. The patient was discharged from the hospital with anti-tuberculous medications (Figure 1). It has been known that air leak from spontaneous pneumothorax that occurs in the case of emphysema-like changes caused by tuberculous destroyed lung and COPD is resulted from the rupture of bulla⁸. Thus, air leak site or any abnormalities resulting probably into air leak should be corrected to prevent further recurrences. Currently, thoracoscopic treatment for emphysema-like changes (blebs or bullae) and pleurodesis have been commonly used^{9,10}. In some cases, wedge resection with bullae placcation is preferred depending on thoracic surgeons. If the air leak persist more than 4 days even in the first episode of spontaneous pneumothorax, a surgical treatment should be considered¹¹. However, if the patient had a high risk of anesthesia or surgery due to underlying illness or poor pulmonary function, other therapeutic modalities should be alternatively selected, but there are no effective treatments until now.

Although the injection of sclerosing agents (tetracycline, minocyclin, doxycyclin or talc slurry) via the chest tube can be used, the recurrence rate of pneumothorax has been reported to be 15~25%¹²⁻¹⁴. Thus, an ethanolamine injection therapy can be considered as an alternative treatment option.

In Figure 2 (case 9), a 56-year-old male patient who had no specific underlying lung disease visited the hos-

pital due to fever and chest pain. After right hydro-pneumothorax was observed on radiography, the patient immediately underwent chest tube drainage. As a bronchopleural fistula was suspected on a chest CT, bronchoscopy was conducted prior to the surgical treatment. As a result, a small fistula was observed in the orifice of right middle lobe bronchus, from which pus-like foamy secretion was discharged. The patient was diagnosed with empyema caused by a bronchopleural fistula, and the air leak from the chest tube was expected to be halted if this fistula was closed. Luckily, the air leak was halted after ethanolamine injection therapy, and subsequently, the chest tube was removed from the patient. Takaoka et al.¹⁵ reproted that local injection of an ethanolamine was effective in occluding central bronchopleural fistula with a diameter of 1 mm or less because the swollen mucosa epithelium due to regional edema induced the mechanical occlusion of the fistula. That is, if an ethanolamine is injected to the mucosa around the fistula orifice, increased blood flow, fibrin disintegration and tissue granulation are formed as the time went by, and 2 months later, connective tissue and fibrin were completely covered over with epithelial tissue^{2,5}. Subsequently, the fistula was covered with fibrous scarring. However, in the case of fistula with a diameter of 3 mm or more, it is difficult to close because the patient would expectorate the fibrin plug by local injection of ethanolamine solution during coughing even if it closes the fistula initially. It has been reported that the mortality is high due to aspiration pneumonia, pyothorax, and sepsis if a surgical treatment is conducted in patients with bronchopleural fistula. Hollaus et al.¹⁶ reported that postoperative mor-

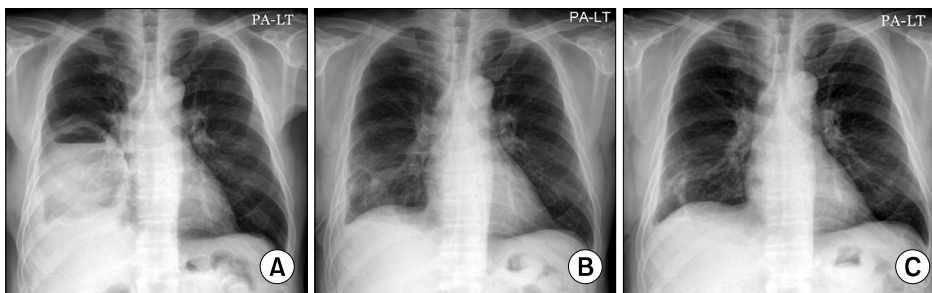


Figure 2. Case 9. A 56-year-old male patient who had empyema due to broncho-pleural fistula. Hydro-pneumothorax (A), 10 and 13 days after ethanolamine injection therapy (B, C).

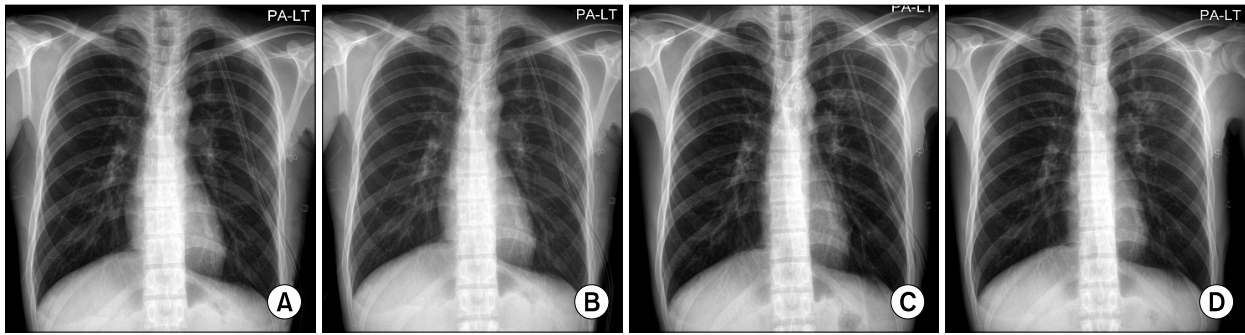


Figure 3. Case 8. A 27-year-old male patient who had spontaneous pneumothorax, first episode. High resolution computed tomography showed multiple bullae and blebs in left apex (not shown). Two days after wedge resection with bullae and blebs plication (A), 1, 2, and 5 days after ethanolamine injection therapy (B~D).

tality was 31%. Therefore, in the treatment of bronchopleural fistula, a bronchoscopic treatment may be an alternative prior to the determination of surgical treatment.

As bronchoscopic ethanolamine injection therapy can be conducted under local anesthesia, light anesthesia or analgesics, it can avert risks associated with general anesthesia. Small amounts of over-flowed ethanol induced coughing, chest discomfort, and fever, but no serious respiratory complications such as hypoxia occurred during ethanolamine injection therapy. As radiologic opacities were shown in 8 patients (53.3%), ethanolamine-induced pneumonia was suspected. However, they were spontaneously resolved within 2~3 days (case 10) (Figure 3B~D). This was likely to be attributable to the regional edema due to ethanolamine injection^{5,7}.

In addition, ethanolamine injection therapy has cost-effective benefits. If this treatment is successful, invasive procedures such as surgery are not required and in-hospital stays can also be reduced. In this study, 1~13 days (median, 3 days) were taken from the last injection of ethanolamine to hospital discharge in 12 patients.

In conclusion, an bronchoscopic ethanolamine injection therapy can avoid surgical treatments and reduce the duration of hospitalization in patients with persistent air leak from chest tube drainage and incomplete lung expansion. However, a further study is required to investigate the appropriate inclusion criteria for the treat-

ment, treatment frequency, and safety. In this study, unsatisfactory results were obtained from three patients (20%) (Table 2). In the cases of idiopathic and spontaneous pneumothorax associated with post-tuberculous scar, lung expansion did not get fully even after two times of ethanolamine injection therapy, and a surgical treatment was required. In the patient with COPD, multiple bullae were seen on the chest CT and so, a surgical treatment was recommended for the prevention of recurrence instead of repeated ethanolamine therapy, but the patient wanted non-surgical therapy and received autologous blood patch pleurodesis to halt air leak¹⁷. It is unclear when ethanolamine injection therapy should be conducted in patients with persistent air leak from chest tube drainage. In this study, an ethanolamine injection therapy was first conducted on 1~18 days (median, 3.5 days) after introduction of chest tube drainage. It was initially planned to be conducted 4 days after chest tube drainage. However, it was conducted earlier when the patients showed persistent air leak and incomplete lung expansion despite chest tube drainage or thoracic surgeons needed the therapy after operation, whereas it was often delayed up to 10 days than the initial schedule in the cases of underlying illness, bronchopleural fistula and surgical candidates.

References

1. Baumann MH, Strange C. The clinician's perspective on

- pneumothorax management. *Chest* 1997;112:822-8.
2. Baumann WR, Ulmer JL, Ambrose PG, Garvey MJ, Jones DT. Closure of a bronchopleural fistula using decalcified human spongiosa and a fibrin sealant. *Ann Thorac Surg* 1997;64:230-3.
 3. Jessen C, Sharma P. Use of fibrin glue in thoracic surgery. *Ann Thorac Surg* 1985;39:521-4.
 4. Roksvaag H, Skalleberg L, Nordberg C, Solheim K, Hoivik B. Endoscopic closure of bronchial fistula. *Thorax* 1983;38:696-7.
 5. Asaki S. Tissue solidification in coping with digestive tract bleeding: hemostatic effect of local injection of 99.5% ethanol. *Tohoku J Exp Med* 1981;134:223-7.
 6. Fujisawa T, Hongo H, Yamaguchi Y, Shiba M, Kadoyama C, Kawano Y, et al. Intratumoral ethanol injection for malignant tracheobronchial lesions: a new bronchofiberscopic procedure. *Endoscopy* 1986;18:188-91.
 7. Otani T, Tatsuka T, Kanamaru K, Okuda S. Intramural injection of ethanol under direct vision for the treatment of protuberant lesions of the stomach. *Gastroenterology* 1975;69:123-9.
 8. Light RW. Management of spontaneous pneumothorax. *Am Rev Respir Dis* 1993;148:245-8.
 9. Noppen M, Alexander P, Driesen P, Slabbynck H, Verstraeten A. Manual aspiration versus chest tube drainage in first episodes of primary spontaneous pneumothorax: a multicenter, prospective, randomized pilot study. *Am J Respir Crit Care Med* 2002;165:1240-4.
 10. van de Brekel JA, Duurkens VA, Vanderschueren RG. Pneumothorax: results of thoracoscopy and pleurodesis with talc poudrage and thoracotomy. *Chest* 1993;103:345-7.
 11. Baumann MH, Strange C, Heffner JE, Light R, Kirby TJ, Klein J, et al. Management of spontaneous pneumothorax: an American College of Chest Physicians Delphi consensus statement. *Chest* 2001;119:590-602.
 12. Berger R. Pleurodesis for spontaneous pneumothorax. Will the procedure of choice please stand up? *Chest* 1994;106:992-4.
 13. Colt HG, Russack V, Chiu Y, Konopka RG, Chiles PG, Pedersen CA, et al. A comparison of thoracoscopic talc insufflation, slurry, and mechanical abrasion pleurodesis. *Chest* 1997;111:442-8.
 14. Light RW, O'Hara VS, Moritz TE, McElhinney AJ, Butz R, Haakenson CM, et al. Intrapleural tetracycline for the prevention of recurrent spontaneous pneumothorax: results of a Department of Veterans Affairs cooperative study. *JAMA* 1990;264:2224-30.
 15. Takaoka K, Inoue S, Ohira S. Central bronchopleural fistulas closed by bronchoscopic injection of absolute ethanol. *Chest* 2002;122:374-8.
 16. Hollaus PH, Lax F, el-Nashef BB, Hauck HH, Lucciarini P, Pridun NS. Natural history of bronchopleural fistula after pneumonectomy: a review of 96 cases. *Ann Thorac Surg* 1997;63:1391-6.
 17. Ando M, Yamamoto M, Kitagawa C, Kumazawa A, Sato M, Shima K, et al. Autologous blood-patch pleurodesis for secondary spontaneous pneumothorax with persistent air leak. *Respir Med* 1999;93:432-4.