



## Case report

# Repeated unconsciousness due to chronic carbon monoxide poisoning in an older patient: a case report

Syuichi Tetsuka<sup>1</sup>, Tomohiro Suzuki<sup>1</sup>, Tomoko Ogawa<sup>1</sup>, Ritsuo Hashimoto<sup>1</sup>, and Hiroyuki Kato<sup>1</sup>

<sup>1</sup>Department of Neurology, International University of Health and Welfare Hospital, Japan

### Abstract

**Objective:** Although much is known about acute carbon monoxide (CO) poisoning, little is known about chronic CO poisoning. Chronic CO poisoning is often diagnosed based on the patient's living environment and medical history. Herein, we report the case of an older patient who presented with repeated unconsciousness due to chronic CO poisoning.

**Case presentation:** A 90-year-old man was brought to the emergency department after being found at home with a disturbance of consciousness. Arterial blood gas measurements in room air revealed a carboxyhemoglobin level of 18.0%. Impaired consciousness was caused by chronic CO poisoning. The patient received high-flow oxygen therapy, which promptly improved his condition. According to his family, briquette kotatsu was the cause of chronic CO poisoning.

**Conclusion:** Although high-flow oxygen therapy has been said to be less effective than hyperbaric oxygen therapy in CO poisoning treatment, recent studies have demonstrated that high-flow oxygen has similar effects and benefits. Thus, in institutions that do not have hyperbaric oxygen, high-flow oxygen may be sufficient to treat patients with CO poisoning, as seen in the present case. It should be noted that briquette kotatsu can lead to CO poisoning. This case highlights the need for clinicians to consider patients' living conditions.

**Key words:** chronic CO poisoning, high-flow oxygen therapy, briquette kotatsu

(J Rural Med 2021; 16(4): 289–292)

## Introduction

Carbon monoxide (CO) poisoning is common in winter, and chronic CO poisoning is often diagnosed according to the patient's living environment and medical history. Although much is known about acute CO poisoning, less is known about chronic CO poisoning. Exposure to low levels of CO is highly likely responsible for a wide range of serious conditions. Such clinical syndromes are often overlooked because of the variety of symptoms, obscurity, and lack of awareness of the problem<sup>1</sup>. Clinicians should remember chronic CO poisoning in the differential diagnosis of im-

paired consciousness, headache, and vomiting, especially in winter. Herein, we report the case of an older man with repeated disturbance of consciousness caused by chronic CO poisoning, who recovered with high-flow oxygen therapy through a non-rebreather mask.

## Case Report

A 90-year-old man was brought to the emergency department after being found at home with a disturbance of consciousness. The patient lived in a rural area. He had received treatment for Parkinson's disease for >10 years. He did not smoke. With regard to his activities of daily living (ADLs), he rarely went out of his house but was able to walk with support in his house. For several years, he has often looked as if he was in a daze in the winter. Two weeks earlier, he began showing repeated signs of disturbed consciousness daily during the daytime, which manifested as unconsciousness that lasted 10–15 min. Upon arrival at our institution, his Glasgow Coma Scale score was E3V4M5, and he was able to reply when called and managed to move his limbs. Blood glucose level was 83 mg/dL. His vital signs were as follows: blood pressure, 182/96 mmHg; pulse rate,

Received: June 7, 2021

Accepted: July 19, 2021

Correspondence: Syuichi Tetsuka, Department of Neurology, International University of Health and Welfare Hospital, 537-3 Iguchi, Nasushiobara, Tochigi 329-2763, Japan

E-mail: syuichi@ijichi.ac.jp

This is an open-access article distributed under the terms of the Creative Commons Attribution Non-Commercial No Derivatives

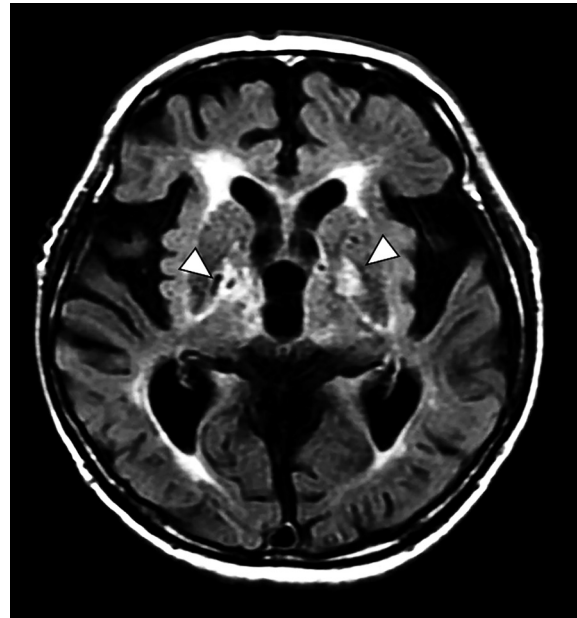
(by-nc-nd) License <<http://creativecommons.org/licenses/by-nc-nd/4.0/>>.



61 beats per minute; respiratory rate, 20 breaths per minute; temperature, 35.7°C; oxygen saturation by pulse oximetry, 98% on room air. Emergency computed tomography of the brain revealed normal findings. His initial arterial blood gases (ABGs) on room air shortly after arrival revealed a pH of 7.440 (normal range, 7.35–7.45), partial pressure of carbon dioxide of 41.2 mm Hg (normal range, 35–45 mmHg), partial pressure of oxygen of 99.6 mmHg (normal range, 75–100 mmHg), and carboxyhemoglobin (COHb) level of 18.0% (normal range, 0–2%). An electrocardiogram (ECG) showed no evidence of ischemic changes, and the levels of cardiac enzymes were normal.

We diagnosed the patient with impaired consciousness due to CO poisoning. Immediately after the ABG results were known, high-flow oxygen therapy through a non-rebreather mask was started at 10 L/min. After 5 h of this therapy, his ABGs revealed a decrease in COHb to 5.5%; therefore, the oxygen flow rate was reduced to 5 L/min. The next day, he was able to eat, and his level of consciousness improved to the point at which he could say his name. On ABG reexamination, his COHb level was 1.1%, and oxygen administration was discontinued. During the rest of his hospital stay, he received rehabilitation treatment for Parkinson's disease and disuse syndrome, and his ADLs gradually improved. Fluid-attenuated inversion recovery sequences on brain magnetic resonance imaging (MRI) showed bilateral high-intensity lesions in the globus pallidus (Figure 1), which is a typical finding of CO poisoning on MRI<sup>2</sup>. His family then informed us that he had spent the daytime in his

living room, where he had a kotatsu with briquettes (Figure 2). One month after his hospitalization, he became more talkative, and episodes of unconsciousness did not recur. The patient was then transferred to a long-term care facility.



**Figure 1** Fluid-attenuated inversion recovery image shows bilateral high-intensity lesions in the globus pallidus (arrowheads). This brain magnetic resonance imaging (MRI) finding is typical of carbon monoxide poisoning on MRI.



**Figure 2** Kotatsu with briquettes (left) and briquette braziers (right). The kotatsu is a Japanese traditional heating table covered with a blanket. The kotatsu dates to the Japanese era over 500 years ago. Charcoal or briquettes were used as a heat source before electricity was introduced. Permission to use the pictures has been granted by the photolibrary (<https://www.photolibrary.jp/>).

## Discussion

“Chronic CO poisoning” refers to multiple exposures to CO, usually at relatively low concentrations. The most common symptoms of acute CO poisoning are headache, nausea, dizziness, vomiting, malaise ataxia, seizures, and loss of consciousness<sup>3</sup>. Acute CO poisoning and chronic CO poisoning are generally defined as follows: 1) “acute CO poisoning” is an acute clinical condition that usually occurs after a single, massive exposure to CO, and most current medical and scientific knowledge is based on acute poisoning; and 2) “Chronic CO poisoning” is a condition in which there is repeated exposure to relatively low concentrations of CO<sup>4</sup>. Each time a patient is exposed to CO, if the concentration and duration of exposure are high enough, they will repeatedly develop symptoms associated with exposure to the poison. However, because chronic CO poisoning often presents nonspecific symptoms, it is difficult to recognize and frequently mistaken for a flu-like disease<sup>5</sup>. Symptoms of chronic CO poisoning include chronic fatigue, memory problems, work difficulties, sleep disorders, dizziness, neurological disorders, paresthesia, recurrent infections, abdominal pain, and diarrhea. In addition, prolonged exposure to low-level CO has also been associated with cardiac hypertrophy and polycythemia, which may be an effect of chronic hypoxia<sup>6</sup>. These symptoms occur if the patients are exposed to the poison at a sufficiently high concentration and duration, with presentations that can be delayed up to several months or 2–3 years<sup>7</sup>. Because CO does not accumulate inside the body, it does not cause chronic poisoning in pathophysiology. However, if mild acute poisoning is repeated (chronic CO poisoning), central nervous system damage accumulates, causing symptoms such as fatigue, headache, dizziness, and repeated transient loss of consciousness attacks. Clinical effects, such as loss of consciousness, are related to a combination of the level of exposure and duration. Thus, after multiple exposures, attention from medical professionals is needed because of hypoxemia, which results in symptoms such as headache and impaired consciousness, as in the present case<sup>8</sup>. Levels of COHb are approximately 1% in normal adults and approximately 6% or more in people who smoke 20 cigarettes per day, and increase physiologically in pregnant women and fetuses<sup>3,9</sup>. In general, >3% of cases of CO poisoning are diagnosed in nonsmokers and 10–15% in smokers<sup>3</sup>. In this case, despite being a nonsmoker, the blood COHb level was elevated at 18%, and the patient was in a state of CO poisoning. Indications of hyperbaric oxygen therapy (HBOT) include CO level >25%, CO level >20% in pregnant patients, loss of consciousness, severe metabolic acidosis (pH <7.1), and evidence of end-organ ischemia (ECG changes, chest pain, or altered mental status)<sup>10</sup>. In the present case, the patient also had a disturbance of consciousness. Thus,

HBOT could be considered in this type of patient, especially for the prevention of delayed neuropsychiatric syndrome regardless of the COHb level. However, facilities that can use HBOT to treat CO poisoning are limited in rural areas. HBOT should be administered early in severe cases to improve neurological prognosis<sup>11</sup>. Although high-flow oxygen therapy has been suggested as less effective than HBOT in preventing cognitive sequelae<sup>12</sup>, some recent studies have reported that high-flow oxygen therapy is appropriate and recommended first until the COHb level normalizes<sup>13</sup>. Additionally, high-flow oxygen therapy can be considered a reasonable alternative treatment because of its cost-effectiveness and affordability<sup>14</sup>. Furthermore, a recent nationwide population-based cohort study revealed that the risk of developing neuropsychological sequelae in patients receiving HBOT was 1.87 times ( $P < 0.001$ ) greater than that of high-flow oxygen therapy<sup>15</sup>. Although HBOT is not available at our facility, which is located in a rural area, based on the results of recent clinical studies, we were able to provide appropriate oxygen therapy in this case, and the patient recovered.

Briquettes were once used regularly as a heat source for daily cooking in ordinary households and heating, as in Japanese kotatsu. At present, they are often used for keeping warm outdoors for a long time, as in leisure activities such as fishing, cooking, and heating devices at food stalls and restaurants. In addition, briquette kotatsu and briquette braziers (Figure 2) are still used in some rural households. According to an epidemiological survey on housing performance centered on the heating environment in Miyagi Prefecture, the ownership rate of briquette kotatsu in households was reported to be 43% in rural areas and 3% in urban areas<sup>16</sup>. Because briquettes generate a large amount of smoke and CO for a while after ignition, they should be ignited outdoors and left in a well-ventilated outdoor environment for approximately an hour after ignition. Even if the combustion is stable indoors, users must have plenty of ventilation; for example, windows should be opened three times in an hour. In situations such as the current case, as the amount of oxygen in the room decreases, a large amount of CO is generated in inverse proportion to the amount of oxygen. The current patient was probably familiar with the use of briquette kotatsu; however, with age, he may have been unable to manage the briquettes as a result of executive dysfunction caused by dementia associated with Parkinson’s disease. In community medicine, this case serves as a reminder that while performing daily medical care, clinicians must consider patients’ living conditions.

**Data availability:** The data used to support the findings of this study are available from the corresponding author upon request.

**Consent for publication:** Written informed consent was obtained from the patient and the patient's family for publication of this case report.

**Conflicts of interest:** The authors declare that they have no conflicts of interest.

## References

1. Myers RA, DeFazio A, Kelly MP. Chronic carbon monoxide exposure: a clinical syndrome detected by neuropsychological tests. *J Clin Psychol* 1998; 54: 555–567. [[Medline](#)] [[CrossRef](#)]
2. Varrassi M, Di Sibio A, Gianneramo C, *et al.* Advanced neuroimaging of carbon monoxide poisoning. *Neuroradiol J* 2017; 30: 461–469. [[Medline](#)] [[CrossRef](#)]
3. Ernst A, Zibrak JD. Carbon monoxide poisoning. *N Engl J Med* 1998; 339: 1603–1608. [[Medline](#)] [[CrossRef](#)]
4. Wright J. Chronic and occult carbon monoxide poisoning: we don't know what we're missing. *Emerg Med J* 2002; 19: 386–390. [[Medline](#)] [[CrossRef](#)]
5. Goldstein M. Carbon monoxide poisoning. *J Emerg Nurs* 2008; 34: 538–542. [[Medline](#)] [[CrossRef](#)]
6. Kao LW, Nañagas KA. Carbon monoxide poisoning. *Emerg Med Clin North Am* 2004; 22: 985–1018. [[Medline](#)] [[CrossRef](#)]
7. Ruth-Sahd LA, Zulkosky K, Fetter ME. Carbon monoxide poisoning: case studies and review. *Dimens Crit Care Nurs* 2011; 30: 303–314. [[Medline](#)] [[CrossRef](#)]
8. Harper A, Croft-Baker J. Carbon monoxide poisoning: undetected by both patients and their doctors. *Age Ageing* 2004; 33: 105–109. [[Medline](#)] [[CrossRef](#)]
9. Fazekas AS, Wewalka M, Zauner C, *et al.* Carboxyhemoglobin levels in medical intensive care patients: a retrospective, observational study. *Crit Care* 2012; 16: R6. [[Medline](#)] [[CrossRef](#)]
10. Huang CC, Ho CH, Chen YC, *et al.* Hyperbaric oxygen therapy is associated with lower short- and long-term mortality in patients with carbon monoxide poisoning. *Chest* 2017; 152: 943–953. [[Medline](#)] [[CrossRef](#)]
11. Casillas S, Galindo A, Camarillo-Reyes LA, *et al.* Effectiveness of hyperbaric oxygenation versus normobaric oxygenation therapy in carbon monoxide poisoning: a systematic review. *Cureus* 2019; 11: e5916. [[Medline](#)]
12. Jurič DM, Finderle Ž, Šuput D, *et al.* The effectiveness of oxygen therapy in carbon monoxide poisoning is pressure- and time-dependent: a study on cultured astrocytes. *Toxicol Lett* 2015; 233: 16–23. [[Medline](#)] [[CrossRef](#)]
13. Sen S, Peltz C, Beard J, *et al.* Recurrent carbon monoxide poisoning from cigarette smoking. *Am J Med Sci* 2010; 340: 427–428. [[Medline](#)] [[CrossRef](#)]
14. Weaver LK. Clinical practice. Carbon monoxide poisoning. *N Engl J Med* 2009; 360: 1217–1225. [[Medline](#)] [[CrossRef](#)]
15. Yang CC, Chuang YF, Chen PE, *et al.* The occurrence of delayed neuropsychologic sequelae in acute carbon monoxide poisoning patients after treatment with hyperbaric or normobaric oxygen therapy. *Medicine (Baltimore)* 2021; 100: e24183. [[Medline](#)] [[CrossRef](#)]
16. Yoshino H, Momiyama M, Sato T, *et al.* The effect of social and economical factors and climatic conditions on regional difference of death rate due to cerebral apoplexy: especially, in correlation to thermal indoor environment of houses. *Jutaku kenchiku kenkyujohou* 1988; 14: 405–422 (in Japanese, Abstract in English).