

## LETTER TO THE EDITOR

## Cutaneous adverse reactions following SARS-CoV-2 vaccine booster dose: a real-life multicentre experience

### Editor

A fourth pandemic wave of COVID-19 recently spread across the globe. In June 2021, a resurgence of infections raised concerns about waning immunity of the vaccine, and a time-dependent reduction in COVID-19 neutralizing antibody

was later confirmed. Accordingly, the recommendation for a booster dose was issued in Europe<sup>1,2</sup> and is still ongoing. From the beginning of mass vaccination campaign, several people sought dermatological attention due to cutaneous adverse reactions after the first two doses, as recently described.<sup>3</sup> However, data on cutaneous toxicities after homologous boosters (same as the primary vaccine) and heterologous boosters (different from the primary vaccine) are lacking. Herein, we report the experience of four Italian tertiary referral dermatology units. Standard informed consents were obtained for recording images in all patients. Adverse reactions following SARS-CoV-2

**Table 1** Demographics, vaccine type, clinicopathological features and onset time of cutaneous adverse reaction in the study population

N	Sex (M/F) and Age (years)	Vaccine Type (1st and 2nd dose)	Vaccine Type (3rd dose)	Onset	Clinical features	Histopathological features	Diagnosis
1	24 M	BNT162b2	BNT162b2	3 days	Erythematous, confluent urticarial wheals of trunk, face and lower limbs	Biopsy not performed	Urticaria
2	58 M	BNT162b2	BNT162b2	10 days	Mildly pruritic erythematous maculopapular morbilliform eruption of the trunk (Fig. 1a)	Mild spongiosis, apoptotic keratinocytes and interface change. Moderate perivascular lymphocytic infiltrate and dermal papillary oedema (Fig. 1b)	Maculopapular rash
3	68 F	BNT162b2	mRNA-1273	7 days	Mildly pruritic erythematous papules on the upper and lower limbs	Hyperkeratosis, hypergranulosis, irregular acanthosis, interface change and a dense band-like lichenoid lymphocytic infiltrate with some scattered eosinophils in the dermis	Lichenoid drug eruption
4	70 F	BNT162b2	BNT162b2	5 days	Erythematous-violaceous patches and swelling on the fingers, toes and feet accompanied by itching and burning sensation.† (Fig. 1c)	Vacuolar interface changes with occasional necrotic keratinocytes and smudging of the basement membrane. Papillary dermal oedema, extravasated erythrocytes and mainly perivascular lymphomonocytic infiltrates (Fig. 1d)	Chilblain-like
5	69 F	BNT162b2	BNT162b2	30 days	Violaceous and erythematous patches on several toes and heels.†	Parakeratosis with serum exudate and apoptotic keratinocytes in the epidermis, vacuolar degeneration of the dermal-epidermal junction with thickening of the basement membrane, papillary oedema and a mainly lymphocytic vasculitis with swollen endothelium and fibrin deposits in the dilated vessels; focal mucin deposition in the dermis (Fig. 1h)	Chilblain-like
6	30 F	BNT162b2	BNT162b2	2 days	Well-defined circular erythematous patches with central blisters on the interdigital folds of both hands (Fig. 1e)	Apoptotic keratinocytes with confluent necrosis and detachment of the overlying epidermal layers, vacuolar interface changes and mild superficial dermal perivascular lymphocytic infiltrate with vessel ectasia and some pigment incontinence (Fig. 1f)	Erythema multiforme-like

Table 1 Continued

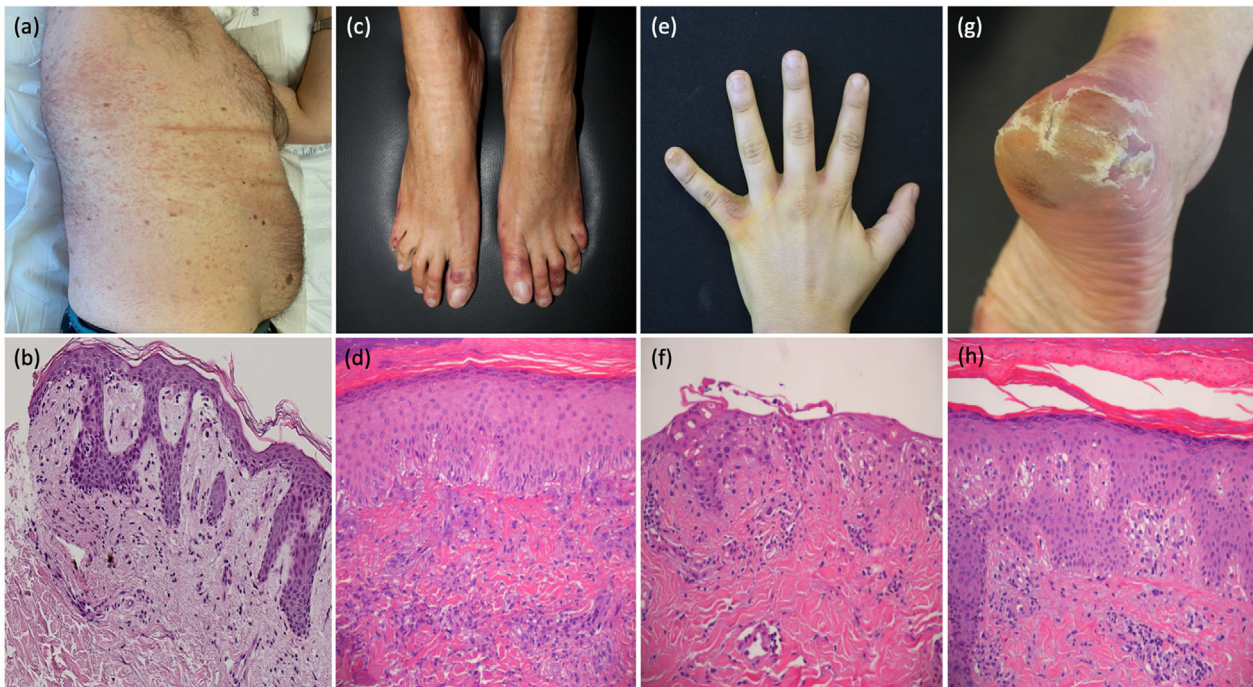
N	Sex (M/F) and Age (years)	Vaccine Type (1st and 2nd dose)	Vaccine Type (3rd dose)	Onset	Clinical features	Histopathological features	Diagnosis
7	35 M	BNT162b2	BNT162b2	5 days	Large erythematous plaque with collarette scales and numerous smaller, confluent, scaleless, infiltrated, pink-coloured papules and plaques on the trunk chest and upper limbs	Epidermal spongiosis with mounds of parakeratosis, exocytosis and some necrotic keratinocytes; in the dermis, a superficial and perivascular lymphomonocytic infiltrate with interface changes, extravasated red blood cells and scattered eosinophils	Pityriasis rosea-like eruptions
8	80 M	ChAdOx1 nCoV-19	mRNA-1273	3 days	Erythematous, oedematous, papular, vesicular and crusted	Psoriasiform-like acanthosis with diffuse spongiosis, orthokeratosis. Initial full-thickness dermal blistering, mild oedema with dilated vessels and scattered perivascular lymphocytic infiltration and interstitial eosinophils.	Eczematous drug eruption
9	65 M	BNT162b2	mRNA-1273	6 days	Erythematous, confluent urticarial wheals of trunk and lower upper limbs	Biopsy not performed	Urticaria
10	72 M	BNT162b2	mRNA-1273	20 days	Tense blisters on urticarial base, predominantly over trunk and lower limbs	Subepidermal blister with eosinophils and underlying dermis demonstrating oedema, lymphohistiocytic and eosinophilic infiltrates. Direct immunofluorescence: immunoglobulin G and complement C3 linear deposits along the dermo-epidermal junction	Bullous pemphigoid
11	39 M	BNT162b2	BNT162b2	5 days	Erythematous plaque with mild peripheral scaling and herald patch on the trunk	Biopsy not performed	Pityriasis rosea-like eruption
12	52 F	BNT162b2	BNT162b2	14 days	Vesicles and erythematous patches in clusters on the right thigh that followed approximately L3-L4 dermatomes	Biopsy not performed	Herpes zoster
13	16 M	BNT162b2	mRNA-1273	3 days	Maculo-papular rash with purpuric aspect located on the lower limbs and forearms.†	Superficial and deep dermal small vessels with lymphocytic perivascular infiltrate, wall aggression and endothelial cell swelling, in absence of thrombosis or fibrinoid necrosis	Cutaneous lymphocytic vasculitis

†Previous hot/cold exposure, pemphigus and any vascular or autoimmune disease were all ruled out.

F = female; M = male.

vaccine booster dose between September 2021 and February 2022 were gathered. For each patient, a comprehensive medical history was collected to exclude predisposing factors. Any cutaneous reactions occurring within 30 days after SARS-CoV-2 vaccine booster dose were considered as potentially related to anti-COVID-19 vaccines. All patients denied any adverse reaction after the first two doses of vaccination and, at the time of the rash, no patient presented with symptoms of COVID-19 nor tested positive for Sars-Cov-2 nor had been in contact with a symptomatic subject. Demographics, vaccine type, clinicopathological features and onset time of cutaneous reaction have all been assessed and are summarized in Table 1. A total of 13 patients have been described (two urticaria, two chilblain-like, two pityriasis rosea-like eruptions, one bullous pemphigoid,

one herpes zoster, one maculo-papular rash, one eczematous drug eruption, one lichenoid drug eruption, one erythema multiforme-like, one cutaneous vasculitis) (Fig. 1a–h). Eight patients (61.5%) were males, and the mean age was 50.7 (standard deviation: 21.2). Skin biopsies were performed in nine patients. The mean onset time was 7.8 days. As for vaccine type, eight patients received BNT162b2 homologous booster, four patients received BNT/1273 heterologous booster and one patient underwent ChAd/1273. In this regard, a study conducted on health-care workers (HCWs) showed that reactivity in infection-naïve HCWs and those without pre-existing cellular immunity was greater after the second dose of BNT162b2 vaccine. At the same time, it was predominant after the first dose in HCWs with pre-existing cellular immunity



**Figure 1** (a) erythematous macules and papules on the back, right flank and abdomen (b) Mild spongiosis, apoptotic keratinocytes and interface change. Moderate perivascular lymphocytic infiltrate and dermal papillary oedema consistent with maculopapular rash. (H&E, magnification 20 $\times$ ) (c) erythematous-violaceous patches of the toes (d) histopathological findings diagnostic for chilblain-like lesions: vacuolar interface changes with occasional necrotic keratinocytes and smudging of the basement membrane. Papillary dermal oedema, extravasated erythrocytes and mainly perivascular lymphomonocytic infiltrates. (H&E, magnification 200 $\times$ ) (e) Erythematous patches with central blisters in the interdigital folds of the hand. (f) Histology revealing erythema multiforme-like changes: apoptotic keratinocytes with confluent necrosis and detachment of the overlying epidermal layers, vacuolar interface changes and mild superficial dermal perivascular lymphocytic infiltrate with vessel ectasia and some pigment incontinence (H&E, magnification 200 $\times$ ) (g) erythematous-violaceous hyperkeratotic patch of the heel (h) histopathological findings diagnostic for chilblain-like lesions: parakeratosis with serum exudate and apoptotic keratinocytes in the epidermis, vacuolar degeneration of the dermal–epidermal junction with thickening of the basement membrane, papillary oedema and a mainly lymphocytic vasculitis with swollen endothelium and fibrin deposits in the dilated vessels (H&E, magnification 200 $\times$ ).

secondary to past infection or cross-reactivity. These findings suggest a connection between a pre-existing cellular response and reactogenicity.<sup>4</sup> From this perspective, the booster dose could represent an additional trigger to the reactogenicity since it further stimulates the immune response. This could explain why a cutaneous skin reaction to the homologous booster may occur after an asymptomatic priming cycle with the same anti-Covid vaccine.

On the other hand, preliminary results from the Com-COV2 trial suggest that the heterologous BNT/1273 prime-boost regimen is more reactogenic than the BNT/BNT homologous regimen. The mix of two different mRNA vaccines and the more reactogenic nature of mRNA1273, consistent with higher mRNA dosage, has been addressed as the possible underlying causes of this phenomenon.<sup>5</sup> This evidence could shed light on why some patients do not experience skin reactions to the first two doses of

the vaccine, yet they do after the heterologous booster. However, study limitations should be noted: our selection of patients does not relate to the total number of subjects accessing the four tertiary referral hospitals in the time range selected. Also, some minor reactions might have been overlooked as not linked to the booster dose at the time. In conclusion, this multicentric experience lays the groundwork for furtherly investigating the mechanisms underlying any adverse skin reactions following booster doses. Studies on a larger scale are needed to thoroughly clarify this preliminary evidence.

#### Conflicts of interest

The authors have no conflict of interest to declare.

#### Funding sources

None declared.

### Informed consent

The patients in this manuscript have given written informed consent to publication of their case details.

### Data availability statement

The data that support the findings of this study are available on request from the corresponding author.

G. Avallone,<sup>1,\*</sup>  F. Cavallo,<sup>1,†</sup>  C. Aструa,<sup>1</sup>  
 G. Caldarola,<sup>2</sup>  C. Conforti,<sup>3</sup>  C. De Simone,<sup>2,4</sup>  
 N. di Meo,<sup>3</sup> A. di Stefani,<sup>2</sup> G. Genovese,<sup>5,6</sup>   
 C.A. Maronese,<sup>5,6</sup>  A.V. Marzano,<sup>5,6</sup>  R. Parente,<sup>7</sup>  
 P. Quaglino,<sup>1</sup>  G. Rocuzzo,<sup>1</sup> F. Tassone,<sup>2</sup> I. Zalaudek,<sup>3</sup>  
 R. Senetta,<sup>8,‡</sup> S. Ribero<sup>1,‡</sup> 

<sup>1</sup>Dermatology Clinic, Department of Medical Sciences, University of Turin, Turin, Italy, <sup>2</sup>UOC Dermatologia, Dipartimento di scienze Mediche e Chirurgiche, Fondazione Policlinico Universitario 'A. Gemelli' IRCCS, Rome, Italy, <sup>3</sup>Dermatology Clinic, Maggiore Hospital, Trieste, Italy, <sup>4</sup>Sezione di Dermatologia, Dipartimento di Medicina e Chirurgia Traslazionale, Università Cattolica del S. Cuore, Rome, Italy, <sup>5</sup>Dermatology Unit, Fondazione IRCCS Ca' Granda Ospedale Maggiore Policlinico, Milan, Italy, <sup>6</sup>Department of Pathophysiology and Transplantation, Università degli Studi di Milano, Milan, Italy, <sup>7</sup>Department of Pathology, Humanitas-Gradenigo Hospital, Turin, Italy, <sup>8</sup>Department of Oncology, Pathology Unit, University of Turin, Turin, Italy

\*Correspondence: G. Avallone. E-mail: gianluca.avallone2@gmail.com

†These authors contributed equally to this article and shared first authorship

‡These authors contributed equally to this article and shared senior authorship

### References

- 1 Callaway E. COVID vaccine boosters: the most important questions. *Nature* 2021; **596**: 178–180.
- 2 Spitzer A, Angel Y, Marudi O *et al.* Association of a Third Dose of BNT162b2 vaccine with incidence of SARS-CoV-2 infection among health Care Workers in Israel. *JAMA* 2022; **327**: 341–349.
- 3 Avallone G, Quaglino P, Cavallo F *et al.* SARS-CoV-2 vaccine-related cutaneous manifestations: a systematic review [published online ahead of print, 2022 Feb 9]. *Int J Dermatol* 2022. <https://doi.org/10.1111/ijd.16063>
- 4 Vizcarra P, Haemmerle J, Velasco H *et al.* BNT162b2 mRNA COVID-19 vaccine reactogenicity: the key role of immunity. *Vaccine* 2021; **39**: 7367–7374.
- 5 Stuart ASV, Shaw RH, Liu X *et al.* Immunogenicity, safety, and reactogenicity of heterologous COVID-19 primary vaccination incorporating mRNA, viral-vector, and protein-adjuvant vaccines in the UK (com-COV2): a single-blind, randomised, phase 2, non-inferiority trial. *Lancet* 2022; **399**: 36–49.

DOI: 10.1111/jdv.18386