

Recurrent and recalcitrant upper lid cicatricial entropion following combined chemotherapy: Clinical and pathology correlation

Alicia Galindo-Ferreiro¹, Diego S. de Prado Otero², Pilar I.G. Marquez³, Silvana Schellini⁴

Access this article online
Quick Response Code:

Website: www.saudijophthalmol.org
DOI: 10.4103/1319-4534.347308

Abstract:

We report a case of recalcitrant bilateral upper eyelid cicatricial entropion associated with distichiasis/trichiasis which followed an adjuvant systemic chemotherapy. The chemotherapy, administered for treatment of breast cancer, consisted of docetaxel, carboplatin, and herceptin. Shortly following the combined chemotherapy treatment, epiphora and eyelash abnormalities commenced. The patient presented with a swollen eyelid margin and tarsal conjunctival inflammation associated with cicatricial entropion and diffused distichiasis/trichiasis affecting the upper lids, with greater severity observed in the medial portion. Despite manual epilation and multiple argon laser sessions, no improvement was noted. Surgical treatment was performed using a lid split, distichiasis excision of the right upper lid, and homolateral tarsoconjunctival graft. The biopsy examination showed chronic inflammation, dermal fibrosis with squamous metaplasia process, and an abnormal epithelial differentiation. After 6 months, entropion recurred. Tarsal marginal rotation associated with posterior lamella advancement was performed. However, cicatricial entropion and distichiasis/trichiasis recurred. The patient was prescribed bandage contact lenses and topical lubrication to relieve symptoms.

Keywords:

Chemotherapy, eyelid disease, eyelid malposition

INTRODUCTION

It is possible to observe distichiasis/trichiasis, entropion, and madarosis after any chemotherapy treatment.^[1,2]

We present a case where the patient developed recurrent and recalcitrant bilateral upper eyelid cicatricial entropion and structural eyelash abnormalities, including distichiasis/trichiasis after receiving adjuvant systemic chemotherapy, which was administered in the treatment of breast cancer.

To our knowledge, eyelash abnormalities, with lid changes, have been documented in three patients after docetaxel^[3] and in one other patient after trastuzumab.^[2] However, this is the first reported case where surgical treatment has been performed and clinical–pathologic correlation presented.

This is an open access journal, and articles are distributed under the terms of the Creative Commons Attribution-NonCommercial-ShareAlike 4.0 License, which allows others to remix, tweak, and build upon the work non-commercially, as long as appropriate credit is given and the new creations are licensed under the identical terms.

For reprints contact: WKHLRPMedknow_reprints@wolterskluwer.com

The study adhered to the tenets of the Declaration of Helsinki, and patient consent to publish photographs was obtained and archived in the file.

CASE REPORT

A 75-year-old woman was referred complaining of epiphora and an intense inflammatory reaction on her upper eyelids in addition to distorted eyelashes which were touching her cornea. She had been experiencing these symptoms for 16 months.

The patient had breast cancer. After a mastectomy, she received adjuvant systemic chemotherapy which adhered to the TCH schedule: Taxotere® (Docetaxel, Hospira National code 667214) 75 mg/ml, Carboplatin® (Carboplatin AUC6, Pfizer RxPathways, US) administered every 3 weeks with a total of six cycles, and

How to cite this article: Galindo-Ferreiro A, de Prado Otero DS, Marquez PI, Schellini S. Recurrent and recalcitrant upper lid cicatricial entropion following combined chemotherapy: Clinical and pathology correlation. Saudi J Ophthalmol 2021;35:347-9.

¹Department of Ophthalmology, Rio Hortega University Hospital,

²Department of Medical Oncology, Clinic University Hospital,

³Department of Pathology, Rio Hortega University Hospital, Valladolid, Spain,

⁴Department of Ophthalmology, Faculdade de Medicina de Botucatu - UNESP, São Paulo, Brasil

Address for correspondence:

Dr. Alicia Galindo-Ferreiro, Department of Ophthalmology, Rio Hortega University Hospital, Dulzaina St. 2, 47012, Valladolid, Spain. E-mail: ali_galindo@yahoo.es

Submitted: 10-Apr-2020

Revised: 26-Jun-2020

Accepted: 09-Dec-2020

Published: 13-Jun-2022

Herceptin® (Trastuzumab, Roche Products Limited, UK) 6 mg/kg/12 months. Following the first cycle, she developed relevant signs of toxicity, such as conjunctival, vaginal, and anal grade 2 mucositis.^[1] This development of symptoms forced the chemotherapy dose to be decreased to 75%, resulting in an improvement of the referred symptoms. Ever since treatment, she has suffered from severe changes to her nail beds, palms, toes, and eyelids. She was diagnosed with cilia touching her eyes which were subsequently epilated on multiple occasions. She denied any previous history of blepharitis/meibomitis, trauma, exposure to chemicals, topical ophthalmic medications, recent eye infections, or pre-existing history of chronic infection in the adnexa such as trachoma before the chemotherapy.

Hyperemia, swelling, crust adhered to the lashes and meibomian glands containing thick secretion were detected on the upper lid. Combined with the distichiasis, the upper eyelids were turned inward, mainly in the medial portion of superior eyelids. On eversion of the tarsal plate, the mucosa showed inflammation without papillae [Figure 1]. Schirmer test I was 5/6 mm and Schirmer II was 3/4 mm. The lacrimal meniscus was almost absent. The cornea was normal. The punctum was patent and well positioned. The lacrimal system was normal.

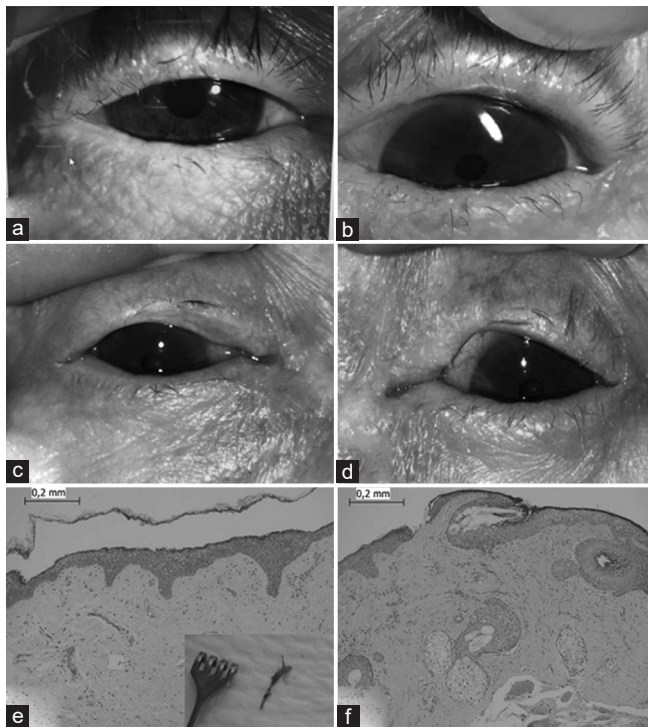


Figure 1: Composition (a and b) right and left upper eyelid of the patient with misdirected eyelashes involving the lateral half of the upper eyelid, (c and d) postoperative appearance of both upper eyelids. At 1-year visit follow-up, significant inflammatory and cicatricial changes within the temporal palpebral conjunctiva that corresponds to the area of eyelash abnormalities. (e and f) Pathology slides. (e) Conjunctival mucosa with squamous metaplasia and subepithelial fibrosis. (f) Cutaneous portion of the eyelid with pilosebaceous follicles. Dermal fibrosis and few scattered chronic inflammatory cells can be seen

Clinical findings of ocular pemphigoid as subconjunctival fibrosis, fornix foreshortening, and symblepharon formation were absent, and no systemic pemphigoid signs were found as subconjunctival fibrosis, fornix foreshortening, and symblepharon formation were absent, and no systemic pemphigoid signs were found.

The diagnosis was cicatricial entropion with distichiasis/trichiasis of the upper eyelids associated with bilateral severe blepharitis/meibomitis and dry eye, as a secondary effect due to the combined chemotherapeutic agents.

Blepharitis/meibomitis were medically treated. She had manual epilation and multiple argon laser sessions (Integre Pro™ Ellex) using 1000 KW, 0.2 s, 100 μ in the upper eyelids to treat the misdirected lashes. No improvement was noted from these procedures. We then proceeded to surgical treatment, which was performed using a lid split and segmental distichiasis excision of the right upper lid with a tarsoconjunctival graft taken from a healthy location on the same side.^[4]

The histological examination of the excised portion of the affected lid revealed chronic inflammation, dermal fibrosis with squamous metaplasia process, and abnormal epithelial differentiation [Figure 1]. Immunofluorescence was negative, as no linear deposition of antibodies were found on the basal membrane. Ocular pemphigoid (OCP), Steven–Johnson disease, infections, rosacea blepharoconjunctivitis, atopic keratoconjunctivitis, conjunctival lichen planus, or topical medication toxicity were all ruled out.

Six months after the surgery, the entropion recurred and the lashes returned misdirected, once again touching the cornea. On eversion, the tarsus was thin and deformed and cicatricial scars in the upper tarsal conjunctiva were worse. The decision was to undergo tarsal marginal rotation combined with posterior lamella advancement in both upper lids.^[5] Nevertheless, after 6 months of the second surgery, the cicatricial entropion and distichiasis/trichiasis recurred. At this time, the patient refused further surgical procedure. She was prescribed bandage contact lenses (Bausch + Lomb, Purevision 2) and topical lubrication to relieve the symptoms and to protect the cornea.

DISCUSSION

We describe a case of chronic inflammation of the upper eyelids evolving with cicatricial entropion and associated with acquired distichiasis/trichiasis, which developed after combined chemotherapy given in the treatment of breast cancer. The process was recalcitrant regardless of the provided treatment.

The oncological treatment of the patient's breast cancer was performed using the two chemotherapeutic agents: docetaxel and carboplatin, in combination with trastuzumab. Docetaxel is a taxane-class antineoplastic agent used in extensive breast cancer with the possible side effect of eyelid alterations, resulting in cicatricial entropion^[3] or canalicular obstruction.^[6] Carboplatin has been associated with rare reported cases of

optic nerve edema with hemorrhages and macular edema, irreversible vision loss, and optic atrophy.^[7] On the other hand, trastuzumab is a humanized monoclonal antibody specifically targeted against the extracellular domain of the human epidermal growth factor receptor 2. It can result in itchy eyes with increased tear production, swelling of the eyelids, conjunctivitis, discharge, crusty eyelids,^[8] lacrimal canalicular stenosis,^[9] and corneal epithelium changes.^[10] Our patient had no visual alterations, ruling out the carboplatin side effect; however, she presented with lashes malpositioned which could be related to docetaxel and/or to trastuzumab.

She developed upper eyelids chronic cicatricial inflammation and severe dryness soon after the first cycle of the treatment. The chronic inflammatory process resulted in meibomian glands metaplasia, evolving with acquired distichiasis/trichiasis and cicatricial entropion. Three other cases of similar eyelid inflammation associated to the use of docetaxel^[3] have previously been reported, starting 5 days to 7 years, and 8 months after trastuzumab,^[2] or even after cessation of treatment,^[2,3] similar to our case.

The pathology biopsy of our patient confirmed chronic inflammation, fibrosis, and squamous metaplasia. A theoretic pathogenesis for the severe dryness can be the reduction of number of conjunctival goblet cells caused by the drugs. Conversely, squamous metaplasia is a continuous, dynamic process of abnormal epithelial differentiation and is related to the pathologic transition from a nonkeratinized stratified epithelium to a nonsecretory keratinized epithelium.

It is reported that both docetaxel^[6] and trastuzumab^[9] can induce significant inflammation and stromal fibrosis in the mucosal lining of the lacrimal drainage apparatus. However, our patient did not developed stenosis in the lacrimal apparatus.

The side effect known of docetaxel is that it may affect both upper and lower eyelids^[3] and it is reported that trastuzumab can affect the lower lids.^[2] The reason to have cicatricial entropion affecting the lower or upper eyelids is unknown.

Cicatricial entropion is usually known to occur as a result from trauma, chemical burns, Stevens–Johnson syndrome, OCP, infections (trachoma and others), or local toxicity to topical medications. None of those conditions was proven in the histopathological examination in our case. It is known that OCP diagnosis is not ruled out by negative direct or indirect immunofluorescence;^[11] however, our patient neither presented with clinical ocular nor systemic OCP signs. Although a direct cause–effect relationship was not demonstrated, based on the previous findings of ophthalmic side effects following antineoplastic agents^[3] and excluding other etiologies, we report that docetaxel and/or trastuzumab can be a cause of recalcitrant cicatricial entropion associated with distichiasis/trichiasis, inducing irreversible chronic inflammatory and cicatricial process, resulting in dryness.

Despite the surgical and laser treatment performed on our patient, distichiasis/trichiasis and cicatricial entropion recurred, due to the chronic inflammatory process.^[3] The super advancement^[5] technique and the tarsal graft^[4] are effective to treat recalcitrant cicatricial entropion and distichiasis, with great efficacy.^[5] Nevertheless, recently, a conjunctival-sparing technique associated to infraciliary rotation was suggested to treat active OCP patients, with good results.^[12] Perhaps we should have used a similar conjunctival sparing technique to treat our case, it is even possible we should not have performed surgery.

Both oncologists and ophthalmologists need to work together for early management of such cases. In these cases, maybe we should be more conservative in our approach, opting only for medical treatment from the onset, until we are sure that the inflammatory process is over.

Financial support and sponsorship

Nil.

Conflicts of interest

There are no conflicts of interest.

REFERENCES

- Freites-Martinez A, Santana N, Arias-Santiago S, Viera A. Using the Common Terminology Criteria for Adverse Events (CTCAE-Version 5.0) to evaluate the severity of adverse events of anticancer therapies. *Actas Dermosifiliogr (Engl Ed)* 2021;112:90-2.
- Tas F, Ozturker C. Distichiasis in association with entropion in metastatic HER2-positive breast cancer treated by pertuzumab, trastuzumab, and docetaxel combination chemotherapy. *Breast J* 2020;26:1004-6.
- Cetinkaya A, Hudak D, Kulwin D. Cicatricial entropion following docetaxel (Taxotere) therapy. *Ophthalmic Plast Reconstr Surg* 2011;27:e113-6.
- Galindo-Ferreiro A, Alkatan H, Maktabi A, Gálvez-Ruiz A, Schellini S. A new surgical technique for congenital distichiasis. *Orbit* 2018;37:87-90.
- Russell DJ, Seiff SR. Long-term results for entropion repair by tarsal margin rotation with posterior lamella superadvancement. *Ophthalmic Plast Reconstr Surg* 2017;33:434-9.
- Esmali B, Burnstine MA, Ahmadi MA, Prieto VG. Docetaxel-induced histologic changes in the lacrimal sac and the nasal mucosa. *Ophthalmic Plast Reconstr Surg* 2003;19:305-8.
- Rankin EM, Pitts JF. Ophthalmic toxicity during carboplatin therapy. *Ann Oncol* 1993;4:337-8.
- R Laboratory. Product Monograph Pr HERCEPTIN®. 2019; v. 2019.
- Kim CY, Kim N, Choung HK, In Khwarg S. Lacrimal drainage system stenosis associated with Trastuzumab emtansine (Kadcyla®, T-DM1) administration: A case report. *BMC Cancer* 2019;19:774.
- Deklerck E, Denys H, Kreps EO. Corneal features in trastuzumab emtansine treatment: Not a rare occurrence. *Breast Cancer Res Treat* 2019;175:525-30.
- Anesi SD, Eggenschwiler L, Ferrara M, Artornsombudh P, Walsh M, Foster CS. Reliability of conjunctival biopsy for diagnosis of ocular mucous membrane pemphigoid: Redetermination of the standard for diagnosis and outcomes of previously biopsy-negative patients. *Ocul Immunol Inflamm* 2020;???:1-8.
- Choung H, Reshef ER, Tanking T, Freitag SK. A conjunctival-sparing surgical technique for lower eyelid cicatricial entropion repair in ocular cicatricial pemphigoid. *Orbit* 2020;39:23-30.