



Giant Dorsalis Pedis Pseudoaneurysm Following Cannulation for Arterial Line in a Patient with Systemic Lupus Erythematosus

Christiana Anastasiadou¹, Sotiris Giannakakis¹, George Galyfos¹, Livieris Livieratos², George Kastrisios¹, Anastasios Papapetrou¹, and Chrisostomos Maltezos¹

¹Vascular Surgery Department, KAT General Hospital, Athens, ²Department of Radiology, KAT General Hospital, Athens, Greece

Dorsalis pedis artery (DPA) aneurysms are very rare and fewer than 60 cases have been reported in the literature. Most affected patients present with false aneurysms after orthopedic surgery or trauma. Here we report an unusual case of a giant DPA pseudoaneurysm after cannulation for arterial line placement in a patient newly diagnosed with systemic lupus erythematosus (SLE). A diagnostic delay resulted in necrosis of the overlying skin. Excision of the pseudoaneurysm, ligation of the DPA, and debridement of the foot dorsum were performed, followed by a second flap coverage surgery. Although a DPA false aneurysm is rare after arterial line removal, it can cause the serious complications of skin necrosis, rupture and toe necrosis. Arterial puncture sites should be carefully monitored, especially in patients with SLE or other vasculitis.

Key Words: Delayed diagnosis, False aneurysm, Systemic lupus erythematosus, Vascular access devices, Flap

Received April 2, 2019
Revised May 16, 2019
Accepted May 31, 2019

Corresponding author:
Christiana Anastasiadou

Vascular Surgery Department, KAT
General Hospital, Nikis 2, Kifisia, Athens,
P.O. 14561, Greece
Tel: 30-2132086069
Fax: 30-2132086455
E-mail: an.xristiana@hotmail.com
<https://orcid.org/0000-0001-7260-9534>

Copyright © 2019, The Korean Society for Vascular Surgery

This is an Open Access article distributed under the terms of the Creative Commons Attribution Non-Commercial License (<http://creativecommons.org/licenses/by-nc/4.0>) which permits unrestricted non-commercial use, distribution, and reproduction in any medium, provided the original work is properly cited.

Vasc Specialist Int 2019;35(2):114-117 • <https://doi.org/10.5758/vsi.2019.35.2.114>

INTRODUCTION

Dorsalis pedis artery (DPA) aneurysms represent a small proportion of peripheral artery aneurysms, with an estimated incidence of 0.5% [1]. An extensive literature review revealed fewer than 60 cases published to date [2]. However, its actual incidence may be underestimated because smaller aneurysms treated conservatively are rarely reported. The causes of pseudoaneurysms are usually iatrogenic or community trauma. However, in some perplexing cases, connective tissue disease or vasculitis can cause peripheral pseudoaneurysms. A detailed recording of the patient's medical history and a careful physical examination are needed to reveal the underlying cause. Marfan syndrome and Ehlers–Danlos syndrome frequently accompany arterial aneurysms, especially those within the

aorta [3]. In some studies, one third of these patients also present with peripheral artery aneurysms [3,4]. An association between peripheral artery aneurysm and vasculitis has also been suggested although data regarding systemic lupus erythematosus (SLE) remain sparse [5]. The treatment of foot pseudoaneurysms traditionally includes observation or open surgery since there is an adequate collateral network in most cases. Thrombin injection and endovascular procedures have been added to the panel of therapeutic approaches during the past few decades [1,5,6].

Aims of this report are to investigate the proper management of a giant pseudoaneurysm and evaluate a possible correlation between SLE and peripheral artery aneurysm formation.

CASE

A 51-year-old female patient was admitted to the neurology department with ischemic stroke. The primary cause, a spontaneous left vertebral artery dissection, was the first clinical manifestation of SLE in this patient. She presented with a gradually enlarging mass on the dorsum of her left foot, which was detected 1 week after the removal of an arterial line (A-line). She had a history of bilateral mastectomy and radiotherapy for breast cancer 4 years prior. To treat the dissection, she was administered aspirin 100 mg daily and bempiparin sodium 3,500 IU/0.2 mL daily. A physical examination revealed a large pulsatile mass with necrosis of the overlying skin (Fig. 1), but no signs of infection, peripheral ischemia (normal Doppler signals in all digital arteries), or palpable thrill. The color duplex scan showed the typical “yin-yang” sign (bi-directional flow due to the swirling of blood within the collection, confirming the diagnosis of a false aneurysm (4.0×4.0×8.0 cm) with a wide neck (6 mm)

originating from the left DPA (Fig. 2). The posterior tibial and plantar arteries were patent with normal velocities (60–80 cm/sec), without any sign of atherosclerosis.

Open surgical repair was selected as the most appropriate approach due to the skin necrosis. Under local anesthesia, a longitudinal incision was made over the proximal DPA. After proximal control, the aneurysm was exposed and the clots were removed. An anterior wall defect of the DPA was confirmed as the cause of the pseudoaneurysm. Because the back-bleeding from the distal DPA was active, ligation of the proximal and distal DPA was performed safely, followed by debridement of the necrotic foot dorsum (Fig. 3). A second operation was performed a few days later by plastic surgeons to cover the skin defect with a cutaneous flap. The postoperative course was uneventful, and no complications such as flap inflammation or toe gangrene were noted. After the 6-month follow-up, she recovered well with no signs of forefoot ischemia. Informed consent was obtained from the patient for publication of this case

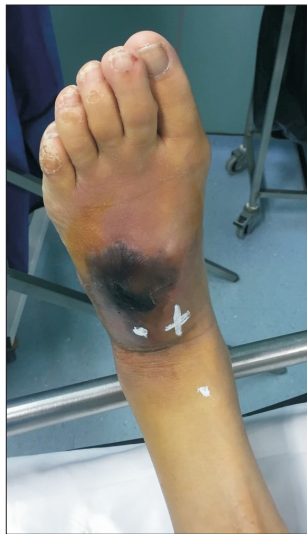

Fig. 1. Preoperative clinical evaluation revealed a giant mass on the dorsum with skin necrosis.

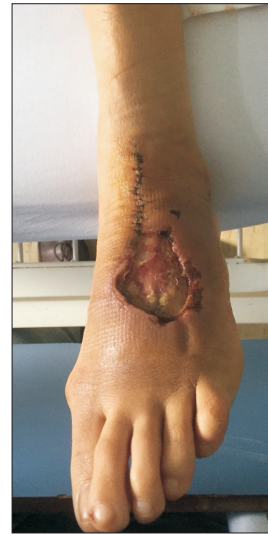

Fig. 3. Postoperative image shows the skin deficit after ligation of the dorsalis pedis artery and debridement of the dorsum.

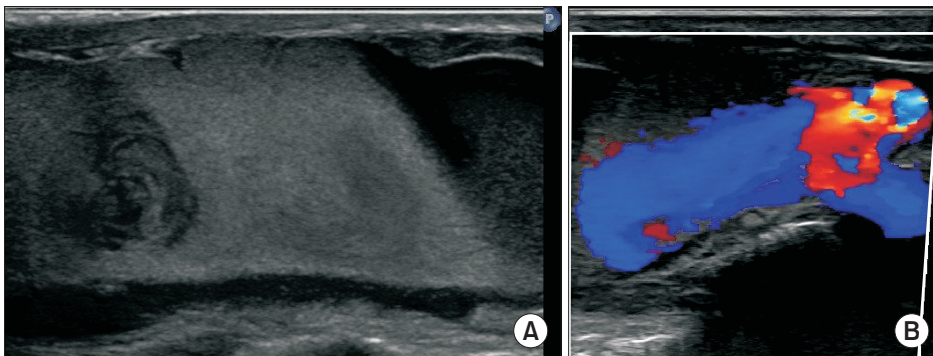


Fig. 2. Duplex ultrasonography performed with a Philips Afiniti 30. (A) B-mode image shows an anechoic, longitudinal mass with blood elements flowing and swirling within a collection. (B) Color Doppler image shows blood spreading from the dorsalis pedis artery to the surrounding tissue with a wide neck.

report and accompanying images.

DISCUSSION

A DPA aneurysm remains a rare condition, even in patients suffering from autoimmune diseases such as SLE or systemic vasculitis [6]. Clinical manifestations include a painful mass, acute foot ischemia, edema or rupture [7]. In cases of arteriovenous fistula formation, subcutaneous venous dilation may be evident. The differential diagnosis includes other vascular (e.g., arteriovenous malformations) or orthopedic (e.g., ganglion cyst) abnormalities [8,9]. In the present case, the mass was initially considered a hematoma by the treating physicians, and the pseudoaneurysm was neglected until it reached a very large size and caused a skin necrosis.

For the diagnosis, clinical suspicion is important for a growing pulsating mass after A-line removal. A duplex ultrasound scan, computed tomography angiography (CTA), magnetic resonance angiography (MRA) and digital subtraction angiography can confirm the diagnosis and evaluate the collateral circulation [9]. Duplex ultrasonography is a cost-effective and time-saving diagnostic modality with high accuracy provided the operator is experienced [10,11] and it is the recommended first-line approach. The typical ultrasound appearance is a swirling flow pattern within an echolucent sac (yin-yang sign). CTA and MRA are less invasive techniques that facilitate accurate aneurysm localization and provide accurate dimensions before the planning of a definite treatment. Another advantage of CT/magnetic resonance imaging is that it is not operator-dependent. Digital subtraction angiography is not recommended due to its invasive nature; thus, it is only considered for therapeutic purposes.

Concerning treatment, several strategies have been reported such as ligation, resection and end-to-end anastomosis, reconstruction with venous graft, compression, percutaneous embolization and thrombin injection [1,9]. To determine the proper treatment strategy, perfusion of the distal foot, the presence of underlying peripheral artery, and pseudoaneurysm size and location (possible nerve compression) should be considered [12]. Simple ligation can be performed in cases of good distal perfusion, while patients with inadequate distal perfusion should be treated with arterial reconstruction [6,13]. Small aneurysms could be treated with compression or thrombin injection whereas large aneurysms should be resected to prevent the compression of an adjacent nerve and further neuropathia [14]. An endovascular strategy was recently introduced in small aneurysms without the risk of compression symptoms [15]. The treatment should be performed without delay to

minimize the risk of complications such as rupture or distal embolism.

While the cause of true DPA aneurysms could be related to atherosclerosis, infection, or connective tissue disease, pseudoaneurysms usually occur secondary to trauma [9,16]. Penetrating injuries, fractures, sprains, iatrogenic injuries (ankle arthroscopy, A-line cannulation or endovascular procedures) and infection can cause false aneurysms [12]. In SLE patients, ruptured aneurysms and pseudoaneurysms were mainly reported in splanchnic arteries [17,18]. SLE is an autoimmune disease that can affect any vessel throughout the body, resulting in vessel wall weakening and vasculitis, in up to 56% of the cases [17]. Appel et al. reported a classification of SLE vasculopathy that included non-complicated vascular deposits of immune complexes, non-inflammatory necrotic vasculopathy, thrombotic microangiopathy and true lupus vasculitis [19]. Thus, the assumption that SLE is correlated with true/false aneurysm development has been discussed but not yet elucidated.

In the present case, the primary mechanism of injury was DPA cannulation (with a 22-gauge needle) despite the fact that A-line placement in our hospital is performed only by highly experienced anesthesiologists or intensivists. Moreover, compression of the puncture site for 24 hours after removal is the routine protocol, and false aneurysm formation due to arterial line placement is rarely observed. Given that the possibility of an improper technique or inadequate hemostasis is excluded, we suspect that SLE could have played an important role in this case. A histologic examination may reveal hidden vasculitis in the affected artery; unfortunately, we did not perform a pathologic examination. Therefore, we suggest routine histologic examinations of rare lesions in unusual locations, particularly in patients with autoimmune diseases.

CONCLUSION

A DPA false aneurysm after A-line placement is very rare. However, hidden vasculitis in SLE patients may contribute to the development of pseudoaneurysm. Therefore, physicians should be careful to place an A-line in SLE patients, and the compression after removal should be performed carefully, and serial follow-up is mandatory. In the case of a growing pulsating mass, duplex ultrasonography should be performed to rule out pseudoaneurysm. Prompt surgical treatment is mandatory to prevent serious complications including skin necrosis, distal ischemia, or rupture.

CONFLICTS OF INTEREST

The authors have nothing to disclose.

ORCID

Christiana Anastasiadou
<https://orcid.org/0000-0001-7260-9534>

George Galyfos
<https://orcid.org/0000-0002-6077-007X>

REFERENCES

- 1) Alhaizaey A, Hussain MA, Aljabri B, Al-Omran M. Aneurysms of the foot arteries. *Vascular* 2016;24:109-112.
- 2) Grzela T, Piotrowicz R, Leksowski K. Should the histological examination be used in the diagnosis of aneurysms of the dorsalis pedis artery? A case report and review of the literature. *Ann Vasc Surg* 2019;54:336.e1-e336.e4.
- 3) Yetman AT, Roosevelt GE, Veit N, Everitt MD. Distal aortic and peripheral arterial aneurysms in patients with Marfan syndrome. *J Am Coll Cardiol* 2011;58:2544-2545.
- 4) Gaertner S, Alembik Y, Cordeanu EM, Dollfus H, Lejay A, Chakfe N, et al. Should we systematically screen for peripheral arterial aneurysms in all patients with Marfan syndrome? *Int J Cardiol* 2014;172:e94-e95.
- 5) Stratton R, Bryce K, Beynon H, Tibballs J, Watkinson A, Davidson B. Systemic vasculitis with multiple aneurysms complicating systemic lupus erythematosus. *J R Soc Med* 1999;92: 636-637.
- 6) Yu JL, Ho E, Wines AP. Pseudoaneurysms around the foot and ankle: case report and literature review. *Foot Ankle Surg* 2013;19:194-198.
- 7) Hiromatsu S, Hosokawa Y, Egawa N, Aoyagi S. Spontaneous rupture of the dorsalis pedis artery: report of a case. *Ann Thorac Cardiovasc Surg* 2007;13: 290-292.
- 8) Lee Y, Ryu HY, Kim YJ, Ku GW. Unusual pseudoaneurysm of the dorsalis pedis artery after an iatrogenic injury. *Korean J Thorac Cardiovasc Surg* 2018;51:213-215.
- 9) Vlachovsky R, Staffa R, Novotny T. Pseudoaneurysm of the dorsalis pedis artery: case report and literature review. *J Foot Ankle Surg* 2017;56:398-400.
- 10) Maydew MS. Dorsalis pedis aneurysm: ultrasound diagnosis. *Emerg Radiol* 2007;13:277-280.
- 11) Ozdemir H, Mahmutyazicioğlu K, Özkökeli M, Savranlar A, Ozer T, Demirel F. Pseudoaneurysm of the dorsalis pedis artery: color Doppler sonographic and angiographic findings. *J Clin Ultrasound* 2003;31:283-287.
- 12) Nishi H, Miyamoto S, Minamimura H, Ishikawa T, Katoh Y, Shimizu Y. Pseudoaneurysm of the dorsalis pedis artery causing neurological deficit. *Ann Vasc Surg* 2004;18:487-489.
- 13) Christoforou P, Asaloumidis N, Katseni K, Kotsis T. Dorsalis pedis artery aneurysm: a case report and review of the literature. *Ann Vasc Surg* 2016;34:271.e5-e8.
- 14) Malghem J, Abdalkader M, Lecouvet F, Goffette P, Hammer F, Vande Berg B. Pseudoaneurysms after ankle sprain: report of three cases successfully cured by nonsurgical treatment. *Ann Vasc Surg* 2017;40:296.e5-e296.e13.
- 15) Kolber MK, Shukla PA, Kumar A, Berkowitz E. Endovascular treatment of a dorsalis pedis artery pseudoaneurysm. *Vasc Endovascular Surg* 2016; 50:283-285.
- 16) Yamaguchi S, Mii S, Yonemitsu Y, Orita H, Sakata H. A traumatic pseudoaneurysm of the dorsalis pedis artery: report of a case. *Surg Today* 2002;32: 756-757.
- 17) Hoorn EJ, Flink HJ, Kuipers EJ, Poley JW, Mensink PB, Dolhain RJ. Complicated systemic lupus erythematosus pancreatitis: pseudocyst, pseudoaneurysm, but real bleeding. *Lupus* 2011; 20:305-307.
- 18) Koga T, Miyashita T, Koga M, Izumi Y, Onizuka S, Fujioka H, et al. A case of lupus-associated pancreatitis with ruptured pseudoaneurysms. *Mod Rheumatol* 2011;21:428-431.
- 19) Radic M, Martinovic Kaliterna D, Radic J. Vascular manifestations of systemic lupus erythematosus. *Neth J Med* 2013;71:10-16.