

Risk factors for early redislocation after primary treatment of developmental dysplasia of the hip

Is there a protective influence of the ossific nucleus?

Atul Bhaskar^{1,2,3}, Hardik Desai^{1,4}, Gaurav Jain⁵

ABSTRACT

Background: Re-dislocation after primary treatment of developmental dysplasia of the hip is a serious complication. We analyzed the various risk factors that contribute to re-dislocation, and whether the bony ossific nucleus (ON) confers increased stability against re-dislocation.

Materials and Methods: Fifty-five children (60 hips) were classified into three treatment groups: Closed reduction (CR) in 15 children (17 hips), open reduction (OR) in 26 children (28 hips), and OR with bony surgery (ORB) in 14 children (15 hips). The mean age at initial treatment was 16 months (range 6–36 months). Fifty-one hips and 9 hips were Tonnis Grade 4 and 3, respectively. The mean preoperative acetabular index (AI) was 44.82° (range 32°–56°) for the study group. At initial treatment, bony ON was absent in 8 hips and present in 52 hips.

Results: No hip developed stiffness and pain after primary treatment. Although the AI index, Tonnis grade, and absence of ossific nucleus were higher in the re-dislocated groups, this was not statistically significant. Excluding the re-dislocations, four children had a fair outcome, 11 had good outcome, and 36 had excellent outcome as per McKay’s criteria. In the CR group (17 hips), two children (2 hips) with absent ON had re-dislocation. In the OR group (28 hips), three re-dislocations were seen (three children) at 3, 5, and 7 months, respectively. Two of these had an absent bony ON. In the ORB group (15 hips), one late sub-luxation occurred in a child with absent ON. The mean preoperative AI for the re-dislocated and located group was 44.66° (range 42°–48°) and 44.53° (range 39°–56°), respectively. The postoperative AI was 34.53.

Conclusion: The experience of the treating surgeon and technical factors play an overwhelming role in preventing early dislocation. The absence of ON should perhaps alert the surgeon for enhanced spica care, postoperative splinting, and meticulous intra-operative management.

Key words: Developmental dysplasia of the hip, ossific nucleus, redislocation

MeSH terms: Risk factors, hip, congenital anomalies, magnetic resonance imaging, dysplasia, congenital

INTRODUCTION

Early redislocation after initial closed or open reduction (OR) of developmental dysplasia of the hip (DDH) is a known complication. If left untreated,

it can lead to poor long term outcomes.^{1,2} The reported incidence of redislocation varies from about 8% to 20%.³⁻⁵

Failure to obtain concentric and stable reduction, by closed or open surgery, can occur due to several factors: Sub-optimal initial treatment, learning curve of the treating surgeon, postreduction spica care, and factors inherent to dysplastic hip.⁶⁻⁸ The adequacy of hip stability after closed or OR is predominantly surgeon-dependent because it is based on perception of “feel of reduction” of the cartilaginous femoral head.

¹Children Orthopaedic Clinic, MHADA, Oshiwara, Andheri West, ²Department of Orthopaedics, Bombay Hospital Institute of Medical Sciences, New Marine Lines, ³Department of Orthopaedics - Dr. R N Cooper Hospital, ⁴Department of Orthopaedics, MW Desai Municipal Hospital, ⁵Department of Orthopaedics, Bombay Port Trust Hospital, Mumbai, Maharashtra, India

Address for correspondence: Dr. Atul Bhaskar, Children Orthopaedic Clinic, Flat 3, Building No. 18, Mhada Complex, Oshiwara Link Road, Andheri West, Mumbai - 400 053, Maharashtra, India.
E-mail: arb_25@yahoo.com

Access this article online	
Quick Response Code:	Website: www.ijoonline.com
	DOI: 10.4103/0019-5413.189610

This is an open access article distributed under the terms of the Creative Commons Attribution-NonCommercial-ShareAlike 3.0 License, which allows others to remix, tweak, and build upon the work non-commercially, as long as the author is credited and the new creations are licensed under the identical terms.

For reprints contact: reprints@medknow.com

How to cite this article: Bhaskar A, Desai H, Jain G. Risk factors for early redislocation after primary treatment of developmental dysplasia of the hip: Is there a protective influence of the ossific nucleus?. Indian J Orthop 2016;50:479-85.

Despite meticulous surgical and cast application techniques, some hips do dislocate. Postreduction computed tomography (CT) or magnetic resonance imaging (MRI) scans are recommended to visualize the position of the ossific nucleus (ON) and grade the quality of reduction.^{9,10} The normal capital epiphysis begins to ossify by 4–6 months of age due to physiological and mechanical forces between femoral head and acetabular cartilage.¹¹ These forces become abnormal in DDH causing delay in ossification. Experimental studies in porcine models have shown that the bony ON offers structural stiffness and also resistance to compression, thus offering protection from avascular necrosis (AVN).¹² Some authors have recommended treatment of DDH after the appearance of this ON to prevent late AVN.^{13,14}

Although authors have looked at the relationship between ON and AVN, its presence or absence during primary closed or OR has not been elucidated. Bolland *et al.* commented that the width and height of the ON in untreated was less as compared to the contralateral side, and following reduction, the width increased but the height never caught up with the contralateral side and remained less at long term followup.⁸ Only one study to date has looked at the ossification of femoral head at closed reduction (CR) and its influence on the long term results.¹⁵

The purpose of this study was to assess the role of various factors that lead to early hip redislocations, and specifically the role of bony ON in imparting stability, after closed or OR.

MATERIALS AND METHODS

55 children (60 hips), with idiopathic DDH underwent treatment with CR or primary OR between January 2003 and December 2012. Children with suspected or proven history of hip infection, and neuromuscular causes were excluded. The mean age at treatment was 16 months (range 6–36 months). Only children with a minimal followup period of 2 years were included. Preoperative clinical assessment revealed that all children had painless range of motion (ROM) of the dislocated hip whereas ambulatory children demonstrated Trendelenburg gait. Children with bilateral hip dislocations presented with waddling gait and restriction of hip abduction. Preoperative evaluation included anteroposterior radiograph of the pelvis to assess Tonnis grade,¹⁶ acetabular slope, and presence or absence of bony ON [Table 1].

The treatment received by the children was classified into three groups: 15 children (17 hips) underwent CR, 26 children (28 hips) underwent OR through either medial or anterolateral approach, and 14 children (15 hips) had combined open reduction and bony surgery. All children

had spica cast immobilization for 12 weeks with an interval cast change at 6 weeks.

Postoperative followup was done every 4 months interval after hip spica removal. At each followup, children were assessed for pain, limp, ROM, and limb length discrepancy. Postoperative radiographs were also evaluated for Tonnis grade, break in Shenton’s line, presence of bony ON, and hip subluxation or dislocation. The AVN was graded using the Bucholz and Ogden criteria.¹⁷ Functional assessment was done using the modified McKay score.¹⁸

RESULTS

There were 40 girls and 15 boys in the study. Of the 60 hip dislocations, 28 were left-sided, 22 were right-sided, and five were with bilateral hip dislocation. Fifty-one hips (four bilateral) were Tonnis Grade 4 and nine hips were Tonnis Grade 3 (one bilateral). The mean followup period after hip spica removal was 28 months (range 24–36 months) for all children. The mean preoperative acetabular index (AI) for all 60 hips was 44.82° (range 32°–56°), and postoperative AI for the stable hips was 34.71° (range 26°–44°) [Table 2].

Table 1: Clinical details of the patients

Number of children	Unilateral	Bilateral
Boys	13	2
Girls	37	3
Side (60 hips)	50	10
Number of children (55)		
Left	28	5
Right	22	
Mean age at treatment (months)	16 (6-36)	
Tonnis grade (60 hips)		
Grade 4	43	8
Grade 3	7	2
Mean prereluction AI (°) (range)	44.82 (32-56)	
Ossific nucleus		
Present	43	8
Absent	7	2

AI=Acetabular index

Table 2: Details of the three treatment groups in the study

Details of Children	CR	OR	ORB
Number of hips (bilateral)	17 (2)	28 (2)	15 (1)
Mean age (months)	9.5 (6-16)	16 (12-24)	22 (18-36)
Radiological indices			
Tonnis grade			
Grade 3	5	4	0
Grade 4	12	24	15
Ossific nucleus			
Present	15	23	14
Absent	2	5	1
Mean preoperative AI (°)	43.17	42.57	48.86
Range	32-56	36-52	44-56

AI=Acetabular index, CR=Closed reduction, OR=Open reduction, ORB=Open reduction with bony surgery

Closed reduction

Fifteen children (17 hips) were treated with CR under general anesthesia (GA). The mean age of children in this group was 9.5 months (range 6–16 months). Two children had bilateral hip dislocation. Five hips were Tonnis Grade 3 and 12 hips were Tonnis Grade 4. Percutaneous adductor tenotomy under GA was done in 8 children (9 hips). Intra-operative arthrogram was performed to confirm concentric reduction under an image intensifier (image intensifier television). A double leg spica cast was applied with the hip held reduced in the position of maximum stability (flexion 90–95° and abduction of 70–80°). Postreduction radiographs were done the next day, and an MRI scan was done within a week. MRI scans when available were done for 8 children (9 hips).

The mean pre and postoperative AI was 43.17° (range 32°–56°) and 34.58° (range 26°–40°), respectively. There were two children with bilateral DDH (4 hips) and 13 children with unilateral DDH (13 hips). The ON was present in 15 hips ($n = 13$) and absent in two hips ($n = 2$). One child who had bilateral DDH had absent bony ON on the left-side (one hip) and the other child had with absent bony ON unilateral DDH (one hip). Redislocation was observed in these two children (2 hips): One child with bilateral DDH had redislocation on the left side 4 weeks after spica removal and the other child presented with redislocation at 6 weeks. MRI scan done postreduction revealed that the cartilaginous ON was located in dysplastic acetabulum in both cases. Thirteen children, one bilateral DDH (2 hips) and 12 unilateral DDH (12 hips) who had the bony ON at the time of primary CR did not dislocate. One child with bilateral DDH that had the ON on the right side also did not redislocate (one hip).

Thus, no child with a bony ON redislocated in this group.

Open reduction

Twenty six children (28 hips) required an OR and hip spica (OR-Group II) as concentric reduction was not possible by closed technique. Four hips were Tonnis Grade 3 and 24 hips were Tonnis Grade 4. The mean age at the time of surgery was 16 months (range 12–24 months). Four children (4 hips) underwent medial open reduction (MOR) through the Ferguson approach and 22 children (24 hips) had conventional anterior OR through the modified Smith–Peterson approach. Two children underwent staged OR for bilateral DDH.

The hips were immobilized in bilateral hip spica cast in position of maximum stability (human position) for 12 weeks. An interval cast change was done at 6 weeks to assess wound status and changed any soiled cast. Trans-articular pins (TAPs) were not used in any case.

Postreduction radiographs were done in all cases to confirm the stability of reduction and 7 children had postoperative CT and 4 had MRI scans.

The mean preoperative AI angle was 42.57° (range 36°–52°). The ON was present in 23 hips (22 children) and absent in five hips (four children). Redislocation was seen in three hips (three children), two with absent bony ON at a mean interval of 3 months (1–5 months) after spica removal. One hip, where the ON was present, dislocated 3 months after the spica removal.

Open reduction with femoral or pelvic osteotomy

Fourteen children (15 hips) underwent OR, bony surgery, and spica (OR with bony surgery [ORB]-Group III). All 15 hips were Tonnis Grade 4, and the mean age in this group was 22 months (range 18–36 months). One child had bilateral hip dislocation. An open hip reduction was done through the modified Smith–Peterson approach. In addition, nine children (10 hips) required a femur derotation osteotomy to decrease the excessive anteversion and five children (five hips) underwent a pelvic osteotomy to obtain stable reduction. The decision to perform a pelvic or femoral osteotomy was based on intra-operative stability after OR. Femoral shortening was added where excessive force was required to reduce the femoral head. A double hip spica was applied in “walking position” with 10°–15° abduction, neutral rotation, and 10°–15° of hip flexion to relax the hamstrings. The spica was continued for 12 weeks with an interval cast change at 6 weeks.

In the ORB group, ON was present in all but one hip at the onset of treatment. The mean preoperative AI angle was 48.86° (range 34°–56°). One late subluxation was seen in the child without an ON after 6 months of spica removal. Thus, 8 hips ($n = 8$) out of 60 hips ($n = 55$) showed absence of ON at initial treatment. Five of these developed redislocation at a mean interval of 2 months (range 1–6 months) after the index procedure and spica removal [Figures 1-3]. Two redislocations occurred within 6 weeks of hip spica removal and three were late redislocations. In the remaining 52 hips ($n = 47$), where the ON was present, there was one redislocation seen after 3 months of spica removal.

Given the limitations of numbers available, no statistical conclusion could be drawn, implicating only the lack of ON as the cause of redislocation [Table 3]. The Tonnis grade was higher in the redislocation group and the acetabulum was more dysplastic (high mean AI), but there was no statistical difference in mean preoperative AI index between stable hips and the redislocated hips [Tables 4 and 5].

The hip spica cast application was applied by the treating surgeon and the mean duration of the hip spica was

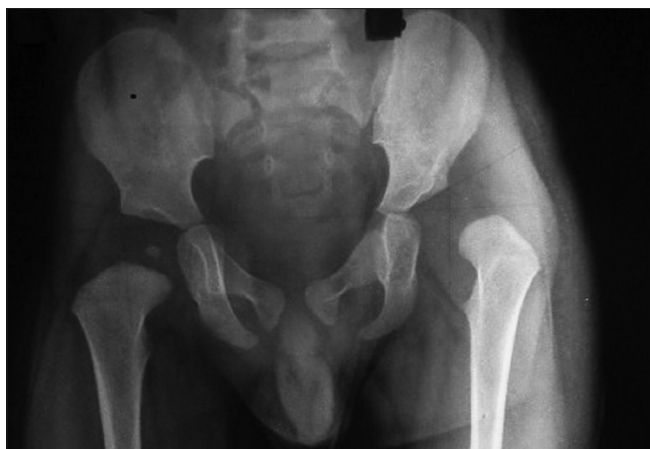

Figure 1: X-ray anteroposterior view of pelvis showing both hips in a 16-month-old infant showing unilateral developmental dysplasia of the hip on the left side with absence of ossific nucleus at the time of open reduction

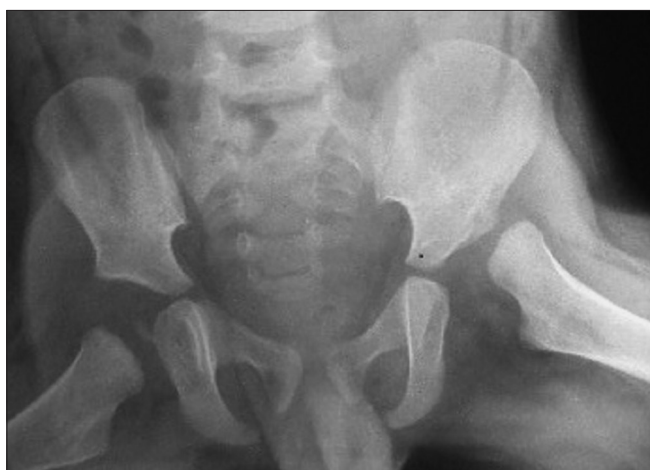

Figure 2: Frog leg lateral view of the same child showing dislocation (L) hip

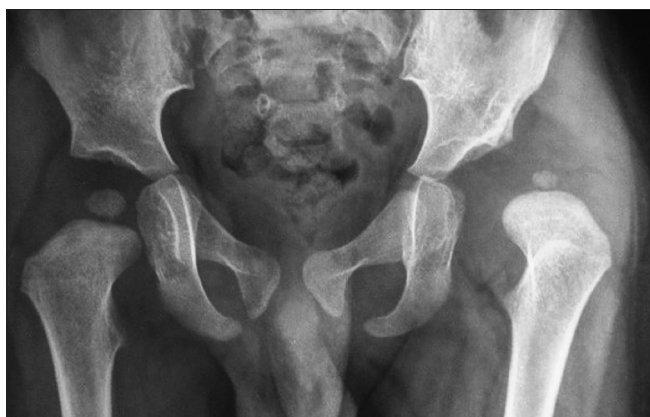

Figure 3: The child underwent open reduction and spica application. X-ray pelvis with both hip joints anteroposterior view showing redislocation of the hip 6 months after spica removal

12 weeks (range 8–14 weeks). Postspica care involved night time abduction brace for all children for 6 months.

Table 3: Comparison of ossific nucleus between three groups

Ossific nucleus	Closed reduction (n=17) n (%)	Open reduction (n=28) n (%)	Open reduction and bony surgery (n=15) n (%)
-----------------	-------------------------------	-----------------------------	--

Present	13 (86.7)	22 (84.6)	13 (92.9)
Absent	02 (13.3)	04 (15.4)	01 (07.1)

By Chi-square test $P=0.755$, not significant. 92.9% of the cases showed ossific nucleus among the open reduction and bony surgery group which was more as compared to 86.7% and 84.6% among the closed reduction group and open reduction group, respectively, but difference was not significant

Table 4: Tonnis grade in the three treatment groups
Comparison of mean preoperative Tonnis score between three groups

Groups	Mean preoperative Tonnis score ($\bar{x}\pm SD$)
--------	--

Closed reduction (n=17)	03.60±00.51*
Open reduction (n=28)	03.85±00.37 (NS)
Open reduction and bony surgery (n=15)	04.00±00.00

By Student's t-test *Significant. From this study, mean preoperative Tonnis score was 04.00 among the open reduction and bony surgery group which was significantly more as compared to 03.60 among the closed reduction group and was comparable with 03.85 among the open reduction group. NS=Not significant, SD=Standard deviation, n=Number of hips in the study group

Table 5: Comparison of mean preoperative acetabular index between three groups

Groups	Mean preoperative acetabular index ($\bar{x}\pm SD$)
--------	--

Closed reduction (n=17)	43.47±06.61*
Open reduction (n=28)	42.85±04.09
Open reduction and bony surgery (n=15)	48.86±03.82

By Student's t-test $P<0.05$ *Significant. In this data, mean preoperative AI was 48.86 among the open reduction and bony surgery group which was significantly more as compared to 43.47 and 42.85 among the closed reduction group and open reduction group, respectively. SD=Standard deviation, AI=Acetabular index

The mean preoperative AI was 44.82° in the located group and 44.4° in the redislocations group.

All six patients with redislocation underwent further treatment. An OR was performed in all children, and in two cases, a femoral derotation osteotomy was added to achieve stable reduction. In 2 children, an intraarticular supplementary “K” wire fixation was used to stabilize the hip. The spica cast was kept for 12 weeks with wire removal done at 4 weeks.

The Bucholz and Ogden classification was used to grade any AVN observed: One child had Grade 1 and one had Grade 2. However, this did not compromise the final result.

The McKay criteria were used to assess functional outcome: Thirty-six children had excellent outcome, 11 had good, two had a fair outcome, and six that redislocated had poor outcome after their primary index procedure for DDH [Table 6].

DISCUSSION

Failure to obtain CR, infection, hip stiffness, and redislocation are some of the early reported complications

Table 6: Results of intervention in three groups

Final Outcome for the study group	CR	OR	ORB
AVN	1	1	0
Functional score (McKay criteria)			
Excellent	10	18	8
Good	2	4	5
Fair	1	1	
Poor	2	3	1

CR=Closed reduction, OR=Open reduction, ORB=Open reduction with bony surgery, AVN=Avascular necrosis

likely to occur in the management of DDH in young children.¹⁹

There is scant data on early redislocation which is a serious complication, and if not addressed in time will compromise the ultimate outcome. Several factors can lead to redislocation after primary treatment of DDH; experience of the treating surgeon being the foremost. Most reports concern retrospective series and look at long term results wherein redislocation (Severin Grade 6) has been mentioned as one of the complications.^{8,20-22}

Salvage of a redislocated hip after index procedure is also one of the most challenging surgeries in pediatric orthopedics. Results of revision surgery are suboptimal and unpredictable due to altered bony and soft tissue anatomy.^{5,23,24}

The bony ON usually appears by 6 months. The normal physiological joint and muscle forces present in a located joint are absent in an untreated DDH. The delay in appearance of the bony ON may be due to lack of this growth stimulus to the cartilaginous nucleus, which may remain unossified for several months. An increased incidence of AVN has been reported when surgery for DDH is done before ossification of the nucleus. The bony ON is supposed to have some protective influence for AVN. It may be that this protective influence may also be preventing early redislocation by offering better resilience and joint stability.

In this study, we looked at 55 children in three treatment groups and this reflects the initial presentation of DDH in the developing world. In the absence of any formal screening program, most children present during infancy or even later, and thus the treatment was tailored to an individual child.

We also used only plain radiographs to image the hip, and the initial AI index was comparable both in the located and redislocated hips. Since improvement in AI index would not have occurred in the early redislocated hips, technical factors seem more likely as the cause of failure of the procedure.

Sankar *et al.* (2011) looked at some predictors for redislocation after a technically proficient OR procedure. The authors identified that right-sided (or bilateral) hip involvement, greater pelvic width, and decreased abduction in the spica cast were associated with high risk for redislocation. Although they looked at the size of the ON, this was overlooked in the final analysis.²⁵ In our CR group, 2 children had early redislocation: One child with bilateral DDH redislocated on one side and one child with unilateral DDH. This may be well due to poor technique and represents a learning curve of the treating surgeon, but both these children had absent bony ON [Figure 4].

In our OR group, the three redislocations occurred with 6 months of the surgery precluding acetabular remodeling as a causative factor to prevent this complication in such a short span. Two hips had absent bony ON and in one case, the bony ON was present. Neither the surgical approach nor the preoperative AI index was attributed as a causative factor for redislocation. Again, possibly, poor appreciation of intra-operative stability may have led to this outcome. Now, we routinely use a TAP for 3 weeks to enhance stability in these cases under the interval of spica change.

The mean age in our open reduction with bony surgery group was higher and only one lateral subluxation was seen at 6 months. All children with the exception of the above child had a bony ON present at the time of surgery. Bony surgery perhaps facilitates the correction of high AI and thus prevents a redislocation. In our child with redislocation, failure to achieve the initial stable reduction or poor postspica removal care could have caused the dislocation. We now routinely use an abduction brace for 3 months following spica removal: 4 weeks of full time brace wear and then 8 weeks of night time bracing.

Bolland *et al.* (2010) have reported that late OR after development of the bony ON had the lowest need for a secondary procedure.⁸ Whether to delay open surgical procedure until the bony ON appears remains moot as most studies focus on the acetabular development and grade of dislocation.

Bhuyan (2012) reviewed the results of one-stage triple procedure (OR, femoral shortening, and Salter's osteotomy) for older children, mean age 3.9 years, in 30 hips and reported one redislocation.²⁶

Some authors recommend trans-articular or trans-trochanteric "K" wire fixation for unstable hips after closed or OR. Alsiddiky *et al.* (2012) described a hip instability test after CR in 124 cases of DDH. Twenty-one cases out of 27 with a positive test had "K" wire inserted

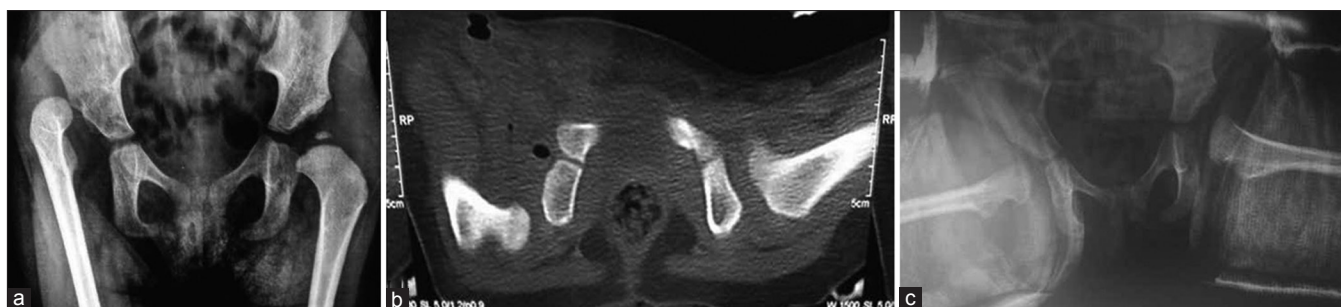


Figure 4: (a) X-ray pelvis with both hip joints anteroposterior view in a 15-month-old infant showing unilateral right developmental dysplasia of the hip with absence of ossific nucleus at the time of closed reduction (b) Computed tomography scan in spica showing that the hip is dislocated. The child was treated with adductor tenotomy and spica cast application (c) X-ray frog leg lateral view of same child who underwent remanipulation showing hip is well reduced

from the trochanter to the pelvic bone.²⁷ Three of the six children with a positive test redislocated at first cast change. They attributed this to posterior acetabular deficiency and excessive femoral anteversion.

The Shriners groups in Mexico have reported the routine use of TAP after open surgery for DDH.²⁸ They reviewed 645 hips (578 children), 621 with TAP, and 24 without TAP. Redislocation was seen in 27 hips out of 621 (4.1%) at a mean interval of 62.2 days and three out of 24 in the non-TAP group (12.5%) at a mean interval of 58.7 days. No child developed premature fusion or injury to the tri-radiate cartilage. They did not look at the size of the ON, but found that TAP was an effective measure in maintaining reduction.

Biçimoglu *et al.* (2003) reported two redislocations out of 137 hip cases at three and 11 months, respectively, after arthrographic-assisted MOR.²⁹ Hip spica was applied for 3 months and the authors found no correlation between redislocation and preoperative Tonnis grade, age of operation, gender, or laterality. Although the illustrated case in their published paper shows a radiograph without the bony ON, this was not specifically looked at in this series.

Surgery for DDH remains technically demanding. The “feel” of reduction either by closed or open procedure is purely subjective and needs additional imaging to confirm concentricity. The technique and interpretation of arthrogram also demands the knowledge of anatomy of the dysplastic hip.³⁰⁻³² The choice of osteotomy depends on intra-operative stability of the femoral head after OR and is difficult to predict.³³ The application of hip spica in DDH is also a precise procedure, and a well molded spica around the trochanter with minimum dead space offer adequate stability in an unstable hip. Hips can redislocate due to malposition in a poorly applied spica cast.

In this study, all five redislocations occurred in cases where the bony ON was absent, and only in one case where it

was present, for both closed and OR. In our series, the observed dislocation rate of 8.33%, albeit higher, could well represent a learning curve in the management of DDH. The positive impact of the ON on the treatment outcome of DDH may well have provided stability in cases which did not redislocate; only a larger study can confirm this correlation.

There are several limitations in the study. Since children presented at various ages, no direct comparison can be made for the three treatment groups. This is an observational, retrospective cases series with a single surgeon experience, potential for selection bias as also the learning curve, could get reflected in the high dislocation rate seen in this series. Advanced imaging studies to assess acetabular dysplasia were not under-taken in this study.

CONCLUSION

Early redislocation of hip after a technically sound open or CR remains an enigma. Although surgeon-controlled factors play an overwhelming role, the dysplastic hip may itself hold untold clues about its instability. Postreduction MRI scan offers the best modality of understanding the anatomical pathology, but its role during surgery is limited. May be in the future, real-time imaging will improve the outcome in this difficult yet common condition seen in the developing world. Referral to dedicated hip centers with enhanced surgical experience will give better outcomes.

Further, perhaps, experimental studies or direct comparison of two groups of DDH, one with and the other without ON may elucidate the predictable management of DDH.

Financial support and sponsorship

Nil.

Conflicts of interest

There are no conflicts of interest.

REFERENCES

- Weinstein SL. Natural history of congenital hip dislocation (CDH) and hip dysplasia. *Clin Orthop Relat Res* 1987;225:62-76.
- Holman J, Carroll KL, Murray KA, Macleod LM, Roach JW. Long term followup of open reduction surgery for developmental dislocation of the hip. *J Pediatr Orthop* 2012;32:121-4.
- Chmielewski J, Albiñana J. Failures of open reduction in developmental dislocation of the hip. *J Pediatr Orthop* 2002;11:284-9.
- McCluskey WP, Bassett GS, Mora-Garcia G, MacEwen GD. Treatment of failed open reduction for congenital dislocation of the hip. *J Pediatr Orthop* 1989;9:633-9.
- Kershaw CJ, Ware HE, Pattinson R, Fixsen JA. Revision of failed open reduction of congenital dislocation of the hip. *J Bone Joint Surg Br* 1993;75:744-9.
- Wedge JH, Kelley SP. Strategies to improve outcomes from operative childhood management of DDH. *Orthop Clin North Am* 2012;43:291-9.
- Malvitz TA, Weinstein SL. Closed reduction for congenital dysplasia of the hip. Functional and radiographic results after an average of thirty years. *J Bone Joint Surg Am* 1994;76:1777-92.
- Bolland BJ, Wahed A, Al-Hallao S, Culliford DJ, Clarke NM. Late reduction in congenital dislocation of the hip and the need for secondary surgery: Radiologic predictors and confounding variables. *J Pediatr Orthop* 2010;30:676-82.
- Chin MS, Betz BW, Halanski MA. Comparison of hip reduction using magnetic resonance imaging or computed tomography in hip dysplasia. *J Pediatr Orthop* 2011;31:525-9.
- MacDonald J, Barrow S, Carty HM, Taylor JF. Imaging strategies in the first 12 months after reduction of developmental dislocation of the hip. *J Pediatr Orthop B* 1995;4:95-9.
- Harris NH. Acetabular growth potential in congenital dislocation of the hip and some factors upon which it may depend. *Clin Orthop Relat Res* 1976;119:99-106.
- Segal LS, Schneider DJ, Berlin JM, Bruno A, Davis BR, Jacobs CR. The contribution of the ossific nucleus to the structural stiffness of the capital femoral epiphysis: A porcine model for DDH. *J Pediatr Orthop* 1999;19:433-7.
- Clarke NM, Jowett AJ, Parker L. The surgical treatment of established CDH: Result of surgery after planned delayed intervention following the appearance of capital femoral ossific nucleus. *J Pediatr Orthop* 2005;25:434039.
- Brougham DI, Broughton NS, Cole WG, Menelaus MB. Avascular necrosis following closed reduction of congenital dislocation of the hip. Review of influencing factors and long term followup. *J Bone Joint Surg Br* 1990;72:557-62.
- Cooke SJ, Rees R, Edwards DL, Kiely NT, Evans GA. Ossification of the femoral head at closed reduction for developmental dysplasia of the hip and its influence on the long term outcome. *J Pediatr Orthop B* 2010;19:22-6.
- Tonnis D. *Congenital Dysplasia and Dislocation of Hip in Children and Adults*. Berlin, Heidelberg: Springer-Verlag; 1987.
- Bucholz RW, Ogden JA. Patterns of ischemic necrosis of the proximal femur in nonoperatively treated congenital hip disease. St. Louis MO: CV Mosby Co.; 1978. p. 43-63.
- McKay DW. A comparison of the innominate and the pericapsular osteotomy in the treatment of congenital dislocation of the hip. *Clin Orthop Relat Res* 1974;98:124-32.
- Bos CF, Slooff TJ. Treatment of failed open reduction for congenital dislocation of the hip. A 10-year followup of 14 patients. *Acta Orthop Scand* 1984;55:531-5.
- Severin E. Contribution to knowledge of congenital dislocation of hip joint. Late results of closed reduction and arthrographic studies of recent cases. *Acta Chir Scand* 1941; 84 Suppl 63:1-142.
- Fixsen JA. Anterior and posterior subluxation of the hip following innominate osteotomy. *J Bone Joint Surg Br* 1987;69-B: 361-4.
- Morel G. The treatment of congenital dislocation and subluxation of the hip in the older child. *Acta Orthop Scand* 1975;46:364-99.
- Vitale MG, Skaggs DL. Developmental dysplasia of the hip from six months to four years of age. *J Am Acad Orthop Surg* 2001;9:401-11.
- Ponseti IV. Causes of failure in the treatment of congenital dislocation of the hip. *J Bone Joint Surg* 1944;26:775-92.
- Sankar WN, Young CR, Lin AG, Crow SA, Baldwin KD, Moseley CF. Risk factors for failure after open reduction for DDH: A matched cohort analysis. *J Pediatr Orthop* 2011;31:232-9.
- Bhuyan BK. Outcome of one-stage treatment of developmental dysplasia of hip in older children. *Indian J Orthop* 2012;46:548-55.
- Alsiddiky AM, Bakarman KA, Alzain KO, Aljassir FF, Al-Ahaideb AS, Kremli MK, *et al.* The early detection and management of unstable concentric closed reduction of DDH with percutaneous K-wire fixation in infants 6 to 12 months of age. *J Pediatr Orthop* 2012;32:64-9.
- Castañeda P, Tejerina P, Nualart L, Cassis N. The safety and efficacy of a transarticular pin for maintaining reduction in patients with developmental dislocation of the hip undergoing an open reduction. *J Pediatr Orthop* 2015;35:358-62.
- Biçimoglu A, Agus H, Omeroglu H, Tümer Y. Six years of experience with a new surgical algorithm in developmental dysplasia of the hip in children under 18 months of age. *J Pediatr Orthop* 2003;23:693-8.
- van Douveren FQ, Pruijs HE, Sakkars RJ, Nievelstein RA, Beek FJ. Ultrasound in the management of the position of the femoral head during treatment in a spica cast after reduction of hip dislocation in developmental dysplasia of the hip. *J Bone Joint Surg Br* 2003;85:117-20.
- Khoshhal KI, Kremli MK, Zamzam MM, Akod OM, Elofi OA. The role of arthrography-guided closed reduction in minimizing the incidence of avascular necrosis in developmental dysplasia of the hip. *J Pediatr Orthop B* 2005;14:256-61.
- Konigsberg DE, Karol LA, Colby S, O'Brien S. Results of medial open reduction of the hip in infants with developmental dislocation of the hip. *J Pediatr Orthop* 2003;23:1-9.
- Zadeh HG, Catterall A, Hashemi-Nejad A, Perry RE. Test of stability as an aid to decide the need for osteotomy in association with open reduction in developmental dysplasia of the hip. *J Bone Joint Surg Br* 2000;82:17-27.