

# Anti-vascular endothelial growth factor in the treatment of macular edema in epidemic retinitis

Ankush A Kawali, Ashwin Mohan<sup>1</sup>, Ruchir Mehta<sup>1</sup>, Padmamalini Mahendradas, Sanjay Srinivasan, Bhujang Shetty<sup>2</sup>

**Purpose:** To study efficacy of anti-vascular endothelial growth factor (anti-VEGF) in resolution of macular edema in epidemic retinitis (ER). **Methods:** In this retrospective, comparative study, patients diagnosed as ER with central macular thickness (CMT)  $\geq 600$   $\mu\text{m}$  on SD-OCT at presentation were studied. Eyes which did not receive intravitreal anti-VEGF formed group A and eyes receiving additional anti-VEGF formed group B. Eyes receiving anti-VEGF monotherapy were studied separately. Cases with subsequent OCT scans with interval of more than 20 days and cases without OCT scan at the resolution were excluded. Treatment details, visual outcome, and days to resolution of macular edema were studied. **Results:** Mean CMT in group A ( $n = 8$ ) was 820.1  $\mu\text{m}$  (range 607-1004  $\mu\text{m}$ ) and in Group B ( $n = 4$ ) was 756.0  $\mu\text{m}$  (range 603-1000  $\mu\text{m}$ ). Macular edema resolved in 34.8 days (range: 16-65) and 39.0 days (range: 21-45) in group A and B, respectively. Two eyes with anti-VEGF monotherapy recovered in 45 and 18 days, respectively. Mean corrected distance visual acuity (CDVA) at presentation in group A was 19.1 (range: 0-61) ETDRS letters and in group B was 14.3 (range: 0-35) ETDRS letters. Mean CDVA improved to 65.7 (range: 0-85) and 50.8 (range: 20-76) ETDRS letters in group A and B, respectively. Anti-VEGF monotherapy eyes improved from 35 and 46 ETDRS letters to 70 and 85 ETDRS letters, respectively. **Conclusion:** Additional anti-VEGF therapy has no added advantage in speed of resolution of macular edema due to ER. A randomized controlled trial with steroids sparing “anti-VEGF monotherapy” may verify our observations.

**Key words:** Anti-VEGF, cystoid macular edema, epidemic retinitis, macular edema, retinitis post febrile illness

Retinitis post-febrile illness (RpFI) or epidemic retinitis (ER) is an acute posterior or panuveitis, commonly seen in tropical countries during epidemics like dengue, chikungunya, West Nile virus, and Rickettsia.<sup>[1]</sup> Regardless of the etiology, the course of the disease and prognosis remains same.<sup>[2,3]</sup> Almost 50% of patients can have macular edema leading to severe vision loss and the disease may last for 3-4 months.<sup>[1]</sup>

To hasten the recovery and to minimize irreversible retinal damage various treatment modalities have been tried to treat the macular edema in ER: intravenous methylprednisolone, oral steroids, posterior subtenon's, and intravitreal triamcinolone acetonide injections. In recent years, anti-vascular endothelial growth factors (VEGFs) gained popularity in the treatment of macular edema of various etiologies including diabetic macular edema, vascular occlusive diseases, postoperative cystoid macular edema, and uveitic macular edema.<sup>[4-7]</sup>

Chawla *et al.* have already reported usefulness of anti-VEGF in the treatment of macular edema of RpFI of unknown etiology in a case report with two patients.<sup>[8]</sup> To our knowledge there are no other case series or drug trials that evaluate the efficacy of anti-VEGF injections in macular edema due to ER. We aimed to study the role of intravitreal anti-VEGF therapy for the treatment of macular edema in ER.

Department of Uveitis and Ocular Immunology, <sup>1</sup>Retina, <sup>2</sup>General Ophthalmology, Narayana Nethralaya, Bengaluru, Karnataka, India

**Correspondence to:** Dr. Ankush A Kawali, Narayana Nethralaya, Chord Road, Rajajinagar, Bengaluru - 560 010, Karnataka, India. E-mail: akawali332@gmail.com

Received: 02-Mar-2020

Revision: 04-May-2020

Accepted: 09-May-2020

Published: 20-Aug-2020

## Access this article online

### Website:

www.ijo.in

### DOI:

10.4103/ijo.IJO\_439\_20

## Quick Response Code:



## Methods

In this retrospective, observational, comparative chart review, cases diagnosed as ER with macular edema presented between July 2012 and May 2018 to a tertiary eye care institute were studied. The study was approved by internal review board and adhered to the tenets of the Declaration of Helsinki. The diagnosis of ER was made based on previously published criteria: Presence of focal or multifocal cotton wool spot-like retinitis lesions around the disc or in the posterior pole with presence of vitritis in a patient with history of a recent fever and where other differentials are ruled out.<sup>[1,2]</sup>

Patients with ER who underwent Spectral Domain Optical Coherence Tomography (SD-OCT) scan using Spectralis™ (Heidelberg Engineering GmbH, Heidelberg, Germany) and showed central macular thickness (CMT)  $\geq 600$   $\mu\text{m}$  at presentation and had follow-up till complete resolution of the macular edema on SD-OCT scan were included. Cases which received identical systemic medications for treatment of ER were included. Cases which received only anti-VEGF monotherapy were also included. Cases with associated

This is an open access journal, and articles are distributed under the terms of the Creative Commons Attribution-NonCommercial-ShareAlike 4.0 License, which allows others to remix, tweak, and build upon the work non-commercially, as long as appropriate credit is given and the new creations are licensed under the identical terms.

**For reprints contact:** WKHLRPMedknow\_reprints@wolterskluwer.com

**Cite this article as:** Kawali AA, Mohan A, Mehta R, Mahendradas P, Srinivasan S, Shetty B. Anti-vascular endothelial growth factor in the treatment of macular edema in epidemic retinitis. Indian J Ophthalmol 2020;68:1912-5.

clinically evident vasculitis, patients with pre-existing uveitis or retinal disease, patients with recent history of intraocular ocular surgery (<3 months) or trauma just before developing ER and patients with media haze where good quality OCT scan was not available were excluded. Cases which received prior intravitreal or periocular steroid therapy were excluded. Cases with subsequent OCT scans with interval of more than 20 days were also excluded.

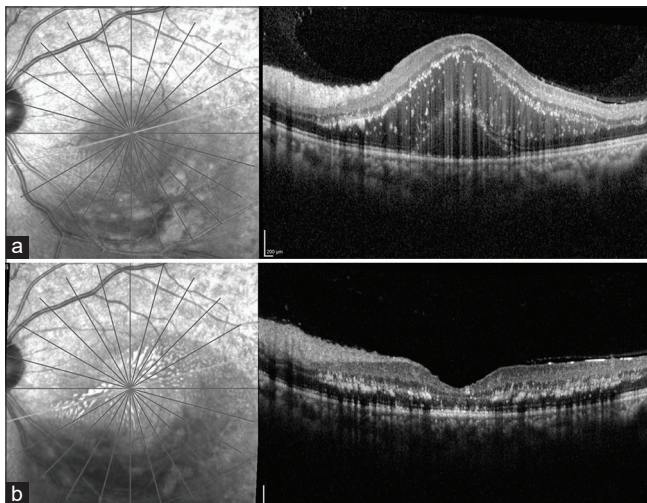
Patient's corrected distance visual acuity (CDVA), findings of clinical examination, and CMT on SD-OCT scan was noted for all visits. The CDVA was recorded on the Snellen's chart and then converted to ETDRS letters. The CMT on the thickness map of the macular volume scan at the presentation was noted for each effected eye.

Patients were treated with oral doxycycline (100 mg BD for 2-3 weeks) and oral steroid (doses were adjusted to the patient's body weight) and started within 5 days of presentation. Ten eyes received topical steroids (prednisolone 1% 6 times/day in tapering doses) along with cycloplegics (homatropine twice a day) for mild-moderate anterior uveitis and rest were treated with topical nepafenac. Eyes which did not receive anti-VEGFs were included in Group A and eyes receiving anti-VEGF formed Group B. Two patients who opted for anti-VEGF monotherapy and were analyzed separately. On follow-up a complete ophthalmic examination was carried out and SD-OCT repeated every 14-20 days. Absence of subretinal and intra-retinal fluid on SD-OCT was defined as resolution of macular edema [Fig. 1]. Number of days taken for complete resolution of macular edema on the OCT scan was documented.

We also studied relationship between severity of macular edema and days to resolution by creating another 2 groups. Eyes with CMT less than 900  $\mu\text{m}$ , group X and eyes with CMT greater than 900  $\mu\text{m}$ , group Y.

## Results

Fourteen eyes of 13 patients were studied: Group A ( $n = 8$  eyes), group B ( $n = 4$  eyes), and 2 eyes with anti-VEGF monotherapy.



**Figure 1:** A 32-year-old man received intravitreal “ranibizumab only treatment” for his epidemic retinitis with macular edema. CMT at the presentation was 901  $\mu\text{m}$  (a). Macular edema resolved completely in 18 days with residual hard exudates in the layer of Henle. (b)

Mean age in group A was 38.9 years (range: 17-56 years) and 39.5 years (range 25-61 years) in group B. Male-female ratio was 1:1 and 4:0, respectively in group A and B. All patients were immunocompetent. The patients in Group B and the two patients on anti-VEGF monotherapy, received the injection within 1 week of baseline OCT (mean: 3.3 days). All patients in anti-VEGF group received single injection only. Two eyes received bevacizumab (1.25 mg in 0.05 ml) and four eyes received ranibizumab (0.5 mg in 0.05 ml).

Mean CDVA at presentation in group A was 19.1 (range: 0-61) ETDRS letters and was comparable to group B which was 14.3 (range: 0-35) ETDRS letters. Mean CDVA in group A improved to 65.7 (range: 0-85) ETDRS letters and was comparable to group B which improved to 50.8 (range: 20-76) ETDRS letters. In two eyes which received anti-VEGF monotherapy, BCVA improved from 35 and 46 ETDRS letters at presentation to 70 and 85 ETDRS letters, respectively, at final visit. The common clinical features for all the patients included mild-moderate anterior chamber reaction, vitritis, cotton wool spot-like retinitis lesions at the posterior pole and around the disc and macular edema as described previously.<sup>[1,2]</sup>

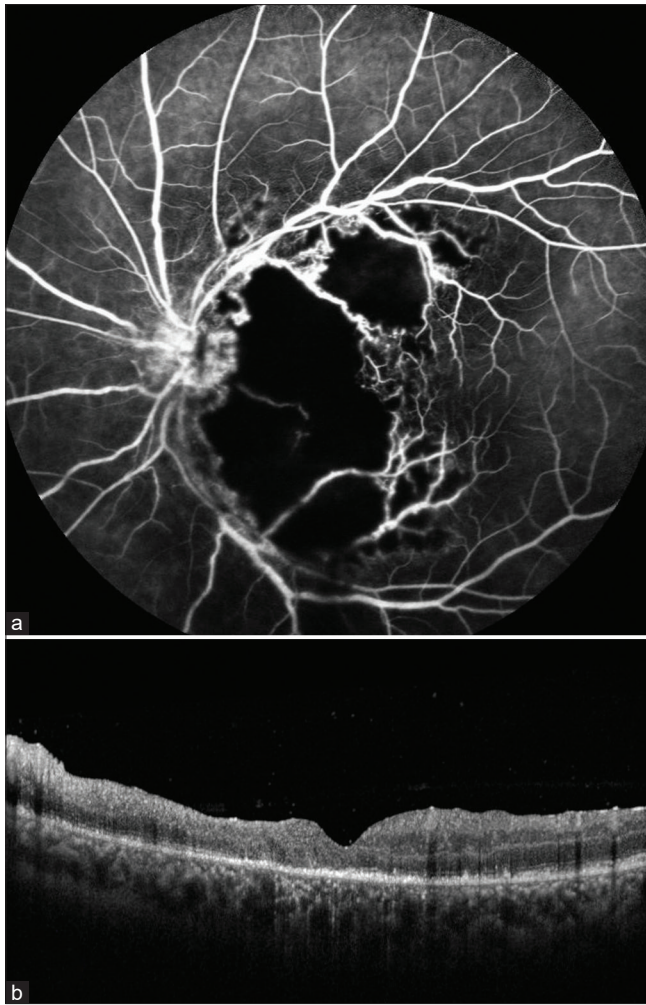
Mean CMT at the presentation was comparable between groups, 820.1  $\mu\text{m}$  (range 607-1004  $\mu\text{m}$ ) in group A and 756.0 (range 603-1,000  $\mu\text{m}$ ) in Group B [Table 1]. This improved to 255.1  $\mu\text{m}$  in Group A and 227.3  $\mu\text{m}$  in group B. In group A macular edema resolved within 34.8 days on average, whereas in group B the edema resolved in 39.0 days. Two eyes which received “anti-VEGF monotherapy” showed resolution in 45 and 18 days, respectively. If added those 2 cases to group B, mean days taken for resolution of macular edema decreased to 34 days. Overall (considering all cases) the macular edema resolved at 35.5 days. Mean follow-up was 5 months (range 1.5-9 months). No recurrence of inflammation or macular edema was noted in all groups. None of the patients had epiretinal membrane greater than grade 1.

Considering groups X and Y, mean CMT at the presentation was 714.2  $\mu\text{m}$  (range 603-873  $\mu\text{m}$ ) in group X and 1010.6 (range 901-1292  $\mu\text{m}$ ) in Group Y [Table 2]. This improved to 248.3  $\mu\text{m}$  in Group X and 236.3  $\mu\text{m}$  in group Y. In group X macular edema resolved within 36.3 days on average and in group Y the edema resolved in 34.3 days.

## Discussion

In the present study we noted no significant difference in resolution of macular edema after adding intravitreal anti-VEGF. We also had two eyes which received only anti-VEGF treatment and observed variable results. This suggested that addition of anti-VEGF to conventional systemic therapy does not significantly change the time taken for resolution of macular edema in ER. Overall vision improvement was satisfactory in all eyes except one (eye 12 - Group B) which had a large macular ischemia (superior to 0.32  $\text{mm}^2$ ) at presentation leading to retinal thinning and significant ellipsoid zone loss after resolution of macular edema [Fig. 2a, b].

In eyes with anti-VEGF monotherapy, the edema resolved relatively faster in one case while the other took 45 days. We could not find exact explanation for this variation. Both the patients were comparable in terms of age, gender, and etiology remained uncertain in both the cases. Slight



**Figure 2:** Fluorescein angiography of a 36-year-old gentleman at presentation shows severe macular ischemia, mild vascular and disc leakage in the left eye (a). Patient received oral doxycycline, steroids and intravitreal ranibizumab. Macular edema resolved after 45 days with ellipsoid zone loss, retinal thinning and indistinct retinal layers (b)

difference in CMT before the injection and use of different anti-VEGF (ranibizumab and bevacizumab) could possibly one of the contributing factors but comparing other cases this explanation appears unlikely [Table 1]. No adverse effects were noted in any eye post-injection during follow-up. Unlike other retinal diseases only single injection was adequate even in patients who received anti-VEGF monotherapy.

Anti-inflammatory property of anti-VEGF agents has recently been studied in experimental study of inflammatory CNVM and macular edema,<sup>[7]</sup> and a similar mechanism can play a role in ER as well. Worsening or migration of retinitis lesions after use of steroids has been reported previously,<sup>[1,9,10]</sup> and hence use of a non-steroidal agent for treatment of macular edema becomes particularly important in cases of retinitis of infective etiology.

Although “studying the relationship between severity of macular edema and days to resolution” was not the primary objective of our study, ignoring the minor treatment bias, we observe that severity of macular edema had no significant relation with days taken to resolution. This observation may instigate further larger studies to consolidate our findings.

Limitations of our study were small sample size due to relative rarity of the condition and seasonal presentation, retrospective nature and use of 2 different anti-VEGFs. Variable etiology of ER is also a confounding factor, but explainable with similar morphological pattern and course of the disease. Exact etiology may remain unknown, as also reported by Chawla *et al.*,<sup>[8]</sup> moreover, serological investigations may show false positive results attributed to cross reacting antigens.<sup>[11]</sup> Intraocular fluid analysis to confirm the etiology was also not possible due to non-availability of the test for suspected organisms or due to financial constraints. Due to all these factors isolating the causative organism in ER cases remains a challenge. Thus, grouping together morphologically similar conditions of ER to study resolution of macular edema may not be discouraged. Following were merits of our study: comparison of near identical groups in terms of clinical presentation and systemic therapy; inclusion of patients who underwent multiple OCT scan so that we can calculate

**Table 1: Comparing resolution of macular edema in Group A and Group B and Anti-VEGF-monotherapy**

Group	Age/Sex	CMT at presentation	CMT at resolution	Days to resolution
A	17/F	607	241	20
	49/M	739	245	49
	20/F	671	310	65
	49/M	1004	278	44
	30/M	965	216	24
	56/F	902	200	30
	51/F	873	235	16
	39/M	800	316	30
B	61/M <sup>†</sup>	687	221	45
	25/M <sup>*</sup>	734	208	21
	36/M <sup>†</sup>	603	211	45
Anti-VEGF monotherapy	36/M <sup>†</sup>	1000	269	45
	27/M <sup>*</sup>	1292	226	45
	32/M <sup>†</sup>	901	229	18

\*Intravitreal bevacizumab, <sup>†</sup>Intravitreal ranibizumab. CMT: Central macular thickness at presentation

**Table 2: Comparing resolution of macular edema in Group X and Group Y**

Group	Age/ Sex	CMT at presentation	CMT at resolution	Days to resolution
X	17/F	607	241	20
	49/M	739	245	49
	20/F	671	310	65
	25/M*	734	208	21
	61/M†	687	221	45
	51/F	873	235	16
	36/M	603	211	45
	39/M	800	316	30
Y	30/M	965	216	24
	49/M	1004	278	44
	56/F	902	200	30
	36/M†	1000	269	45
	27/M*	1292	226	45
	32/M†	901	229	18

\*Intravitreal bevacizumab, †Intravitreal ranibizumab

the exact duration of resolution of macular edema, we also studied relation between severity of macular edema and days to resolution and found no significant co-relation and lastly we also included 2 patients who received Anti-VEGF monotherapy who surprisingly showed variable response to the treatment.

## Conclusion

Although limited by small numbers, our study has shown that the macular edema in ER resolves at 35 days. Use of anti-VEGFs in addition to conventional treatment for ER showed no added advantage in terms of speed of resolution in macular edema. A recently published study has also reported that the macular edema of ER can resolve even without use of corticosteroids.<sup>[2]</sup> We are of opinion that the risk of invasive procedure and the additional costs incurred by administration of Anti-VEGF can be avoided in the treatment of macular edema of ER. A larger randomized controlled trial

with steroids sparing “Anti-VEGF monotherapy” may verify our observations.

## Financial support and sponsorship

Nil.

## Conflicts of interest

There are no conflicts of interest.

## References

- Kawali A, Mahendradas P, Mohan A, Mallavarapu M, Shetty B. Epidemic retinitis. *Ocul Immunol Inflamm* 2018;25:1-7.
- Kawali A, Srinivasan S, Mohan A, Bavaharan B, Mahendradas P, Shetty B. Epidemic retinitis with macular edema -treatment outcome with and without steroids. *Ocul Immunol Inflamm* 2020;21:1-5.
- Panchal B. Commentary: Post fever retinitis and vasculitis: A morphological conundrum. *Indian J Ophthalmol* 2018;66:1844.
- Weiss K, Steinbrugger I, Weger M, Ardjomand N, Maier R, Wegscheider BJ, *et al.* Intravitreal VEGF levels in uveitis patients and treatment of uveitic macular oedema with intravitreal bevacizumab. *Eye (Lond)* 2009;23:1812-8.
- Cervantes-Castaneda RA, Giuliari GP, Gallagher MJ, Yilmaz T, MacDonell RE, Quinones K, *et al.* Intravitreal bevacizumab in refractory uveitic macular edema: One-year follow-up. *Eur. J. Ophthalmol* 2009;19:622-9.
- Lott MN, Schiffman JC, Davis JL. Bevacizumab in inflammatory eye disease. *Am J Ophthalmol* 2009;148:711-7.
- Agrawal R, Tun SBB, Balne PK, Zhu HY, Khandelwal N, Barathi VA. Fluorescein labeled leukocytes for *in vivo* imaging of retinal vascular inflammation and infiltrating leukocytes in laser-induced choroidal neovascularization model. *Ocul Immunol Inflamm* 2018;22:1-7.
- Chawla R, Sundar DM, Gupta P, Mittal K. Intravitreal bevacizumab for post viral fever retinitis: A novel approach for early resolution of macular oedema. *BMJ Case Rep* 2018;18:2018.
- Ayachit A, Ayachit G, Joshi S, Sameera VV. Commentary: Rickettsial retinitis – Direct bacterial infection or an immune-mediated response? *Indian J Ophthalmol* 2017;65:1041-3.
- Kawali A, Mahendradas P, Srinivasan P, Yadav NK, Avadhani K, Gupta K, *et al.* Rickettsial retinitis-an Indian perspective. *J Ophthalmic Inflamm Infect* 2015;5:37.