

Clinical outcome following multisegmental cervical spinal fixation in patients who recovered partially following injury

ABSTRACT

Objective: The clinical outcome following multilevel stabilization in patients who suffered cervical spinal injury and developed severe neurological deficits and then gradually partially recovered is evaluated. The basis of the surgical concept was that cervical spinal degeneration is a result of single or multilevel spinal instability and that spinal trauma exaggerates the instability.

Materials and Methods: During the period 2015–2020, 14 patients who suffered severe cervical spinal injury and could be included in the classification of spinal cord injury without computed tomography evidence of trauma were surgically treated. There were 11 males and 3 females. The ages ranged from 45 to 67 years, average being 53 years. Cervical canal stenoses related to degenerative spinal changes were observed in all patients. All patients suffered severe neurological deficits and within few days or weeks had shown significant but incomplete neurological recovery. The identification of the levels of unstable spinal segments was done on the basis of radiological and clinical parameters and direct observation of spinal instability in adjoining spinal segments. Transarticular fixation was done by Camille's transarticular fixation technique. Using ASIA score, modified JOA score, and Goel Clinical Grading Scale, the clinical course of the patients was monitored.

Results: All patients showed recovery in the neurological status. Recovery started in the immediate postoperative period and the improvement progressed during the period of follow-up.

Conclusions: Surgery for spinal stabilization can be indicated even in cases that improve in the neurological function.

Keywords: Spinal cord injury without computed tomography evidence of trauma, spinal injury, spinal stabilization, transarticular fixation

INTRODUCTION

Spinal cord injury and moderate-to-severe neurological deficits without any evidence of spinal vertebral fractures, dislocation, or instability is a known clinical entity. Such entity was identified by Pang and Wilberger in children as SCIWORA (spinal cord injury without radiological abnormality).^[1] Several authors subsequently discussed similar clinical entity in adults and labeled it as spinal cord injury without computed tomography evidence of trauma (SCIWOCTET).^[2-7] Evidences of spinal degeneration and presence of “stenotic” cervical spinal canal differentiated imaging in adults from that in children.^[2-7] There was no evidence of acute disc herniation or focal neural compression that can be attributed to trauma. General observation is that the ultimate clinical outcome of neurological deficits is

better in patients having SCIWORA or SCIWOCTET than in those wherein there are evidences of bone or ligamentous disruption that leads to fracture and or dislocation of vertebral segments.

ATUL GOEL, ADITYA LUNAWAT, ABHIDHA SHAH, SASWAT DANDPAT, AKSHAY HAWALDAR, HARDIK DARJI, NISHIT TRIVEDI

Department of Neurosurgery, K. E. M. Hospital and Seth G. S. Medical College, Mumbai, Maharashtra, India

Address for correspondence: Prof. Atul Goel, Department of Neurosurgery, K. E. M. Hospital and Seth G. S. Medical College, Parel, Mumbai - 400 012, Maharashtra, India. E-mail: atulgoel62@hotmail.com

Submitted: 06-Aug-21


Accepted: 09-Aug-21

Published: 08-Sep-21

This is an open access journal, and articles are distributed under the terms of the Creative Commons Attribution-NonCommercial-ShareAlike 4.0 License, which allows others to remix, tweak, and build upon the work non-commercially, as long as appropriate credit is given and the new creations are licensed under the identical terms.

For reprints contact: WKHLRPMedknow_reprints@wolterskluwer.com

How to cite this article: Goel A, Lunawat A, Shah A, Dandpat S, Hawaldar A, Darji H, *et al.* Clinical outcome following multisegmental cervical spinal fixation in patients who recovered partially following injury. *J Craniovert Jun Spine* 2021;12:216-22.

Access this article online	
Website: www.jcvjs.com	Quick Response Code 
DOI: 10.4103/jcvjs.jcvjs_110_21	

We report our experience with 14 adult patients who suffered “severe” neck injury and could essentially be included in the category of SCIWOCTET. All patients developed significant neurological deficits and over the period of few days or weeks showed partial neurological recovery. There were evidences of spinal degeneration-related cord compression and intrinsic spinal cord changes in the form of focal segmental “edema.” There was no evidence of bone or ligamentous soft-tissue injury and spinal instability on dynamic imaging. All patients underwent multisegmental spinal fixation without any kind of decompression. Remarkable clinical improvement that started in the immediate postoperative period was observed in all patients. A retrospective analysis of the clinical progression from the time of spinal injury, surgery, and at follow-up is discussed.

MATERIALS AND METHODS

This is a retrospective analysis of 14 adult patients who presented with spinal cord injury to our department during the period January 2015 to January 2020. Only patients with no radiological evidences of bone injury, acute disc herniation, bone fractures, subluxation, or any evidences of spinal instability on dynamic radiological imaging were included in the analysis. The patients could be grouped under the term SCIWOCTET. All patients provided written informed consent, and all clinical tests and surgical procedures were conducted according to the principles of the declaration of Helsinki. Patients with severe traumatic brain injury, upper cervical (C1-C2), thoracic and lumbar injury were excluded from the analysis. All patients underwent plain radiographs, magnetic resonance imaging (MRI), and dynamic computed tomography (CT) of the cervical spine. The plain radiographs and CT scan in all the patients were normal except for age-related degenerative changes. MRI of the cervical spine within 72 h of the initial injury was available in all the patients. All the patients developed “severe” neurological deficits immediately after sustaining the injury and improved incompletely in their neurological deficits over a period of few days to few weeks following the injury, but continued to remain significantly disabled. The neurological status of the patients at the time of admission for surgery was documented. Two independent neurosurgeons who were not part of the study performed the clinical and radiological assessments. The neurological assessments were performed using ASIA score, modified JOA score, and Goel clinical grading just before surgery, 4 days after surgery and at a follow up of 3 months and after about 1 year of surgery. The clinical details are presented in Tables 1 and 2. Data regarding neurological function included the ambulatory status of the patients and bladder

and bowel function. Urinary tract function included status of bladder emptying (voluntary control and indwelling catheter) or reflex micturition. Motor activity status included the need for personal assistance for the activities of daily living or the need for hospital care. The CT scans were reviewed to look for any fracture, facet dislocation, subluxation, or any instability. MRI was assessed to look for cord signal changes, cord swelling or hematoma, extramedullary hematoma, ligament or muscle injury, and presence of spondylotic degenerative changes. The radiological findings are tabulated in Table 1. After establishing the diagnosis of SCIWOCTET, the patients were treated surgically.

Surgery

The patients underwent surgery in the prone position with the head placed in Gardner Wells traction. The head end of the operation table was elevated to provide counter-traction. Transarticular screw fixation technique as described by Camille and Saillant in 1972 was used [Figures 1 and 2]. The screws measured 2.6 mm in diameter and were 12–14 mm in length. C2-3 articulation was included in all cases. The spinal segments fixated are shown in Table 1. After the screw fixation, all the muscles and ligaments attached to the spinous process and laminae were sharply sectioned, exposed posterior element bones were drilled to make them suitable host for bone graft. Bone graft was harvested from the iliac crest and stabilized.

RESULTS

The clinical details, mode of injury, and time of presentation to the hospital of the patients are detailed in Table 1. There were 11 males and 3 females. The ages of the patients ranged from 45 to 67 years (mean 53 years). All patients presented with a history of injury. The mechanism of injury included: Road traffic accident (6 patients), fall from height (1 patient), and fall at home or at work place (7 patients). The duration after injury at which the patients presented for surgery ranged from 4 to 45 days with a mean of 12.5 days. All the patients had improved to varying degrees following the injury but continued to have significant neurological morbidity. Nine patients had some degree of bladder involvement. The radiological findings are detailed in Table 1 and are summarized here. There was no evidence of any bone injury, subluxation, muscle, or ligament injury in any of the patients. There was no evidence of any instability on dynamic imaging. All patients had telltale evidences of cervical degeneration. The radiological levels depicting evidences of cervical degeneration were C3-4 in one patient, C3-C5 in 6 patients, C4-C6 in one patient, C3-C6 in 4 patients, and C3-C7 in 2 patients. T2 hyperintense signal was seen in MRI

Table 1: The epidemiology, mode of injury, and radiological findings of the patients

Case number	Age/sex	Mode of trauma	Time duration between injury and presentation to hospital (days)	Radiological levels of spinal degeneration	Levels of cord edema	Levels fixed
1	Female/57	Fall	4	C3-C7	C3-C6	C2-C7
2	Male/60	Motor vehicle collision	45	C3-C7	C3-C6	C2-C7
3	Male/46	Motor vehicle collision	5	C3-C5	C3-C5	C2-C5
4	Male/67	Fall	30	C3-C5	C4-5	C2-C6
5	Male/46	Motor vehicle collision	7	C3-C4	C3-4	C2-C6
6	Male/48	Fall	20	C3-C6	C3-6	C2-C5
7	Male/45	Fall	21	C3-C5	C3-4	C2-C5
8	Male/53	Fall	9	C3-C5	C4-5	C2-C5
9	Male/56	Fall	6	C3-C6	C3-4, C4-5	C2-C7
10	Female/61	Fall	5	C3-C5	C3-5	C2- C6
11	Male/50	Motor vehicle collision	8	C4-C6	C4-5	C2- C6
12	Female/47	Motor vehicle collision	5	C3-C5	C3-4	C2-C5
13	Male/51	Motor vehicle collision	6	C3-C6	C3-5	C2-C6
14	Male/57	Fall	5	C3-C6	C4-5	C2-C6

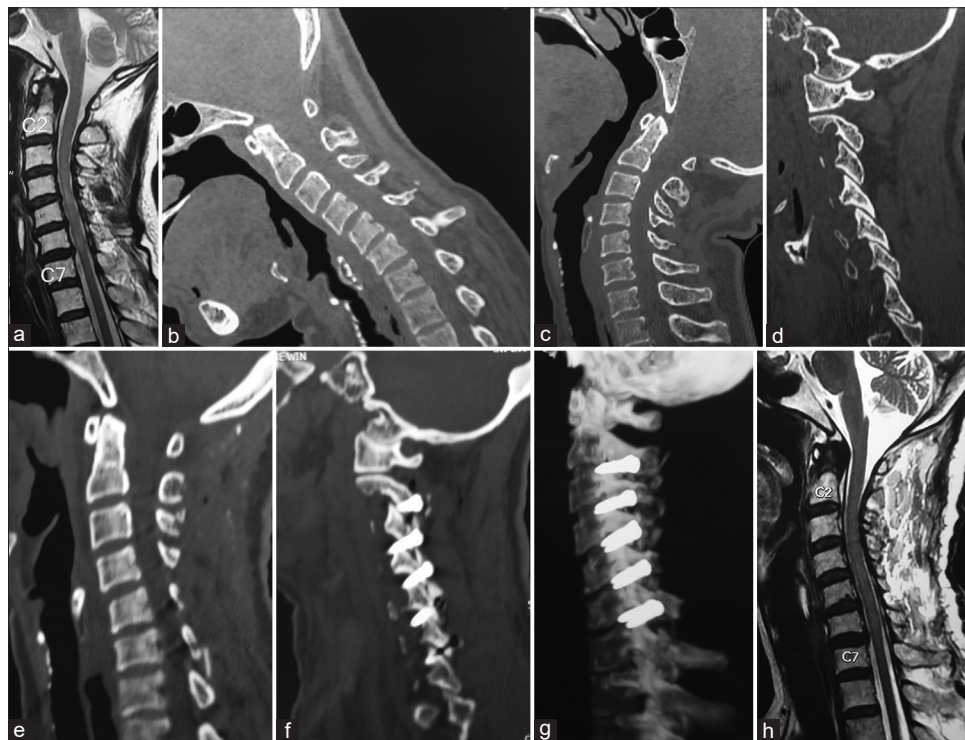

Figure 1: Images of a 57-year-old female patient [Table 1- Case 1]. (a) T2-weighted magnetic resonance imaging showing moderate cervical spinal degenerative changes in the form of bulging disc spaces and ligamentum flavum. Intra-axial cord signals are seen at C4-5 and C6-7 levels. (b) Computed tomography scan with the head in flexed position does not show any evidence of bone injury or instability. (c) Computed tomography scan with the head in the extended position. (d) Computed tomography scan cut passing through the facets showing no significant abnormality or instability. (e) Postoperative computed tomography scan showing the cervical spine alignment. No posterior decompression has been done. (f) Computed tomography scan cut through the facets showing transarticular fixation. (g) Computed tomography scan showing the fixation construct. (h) Delayed magnetic resonance imaging (after 3 months of surgery) showing regression of the osteophyte and resolution of intra-axial spinal cord changes

in all 14 patients. The most frequent levels showing cord signal changes were C3-4 and C4-5. There was no evidence of cord hemorrhage in any of the patients. There was loss of cervical lordosis in 12 out of 14 patients. All patients had incomplete spinal cord injury at the time of presentation. All the presented patients had improved to varying degrees following the initial insult but still had significant neurological

deficits at the time of presentation. Steroids were not used either before or after surgery in any case. All patients underwent multi-level spinal stabilization using the Camille's transarticular fixation technique.^[8] No bone or soft-tissue decompression was performed. The number of levels fixed included five levels in three patients, four levels in six patients, and three levels in five patients. The C2-3 joint was

Table 2: The neurological status of the patients

Case number	Neurological status	At time of injury	At time of presentation (preoperative)	Immediate postoperative	At 3 months follow-up	Delayed follow-up
1	ASIA score	C	D	D	D	E
	Goel clinical grade	5	4	3	2	2
	JOA score	9	11	13	14	14
2	ASIA score	B	C	C	D	D
	Goel clinical grade	5	5	4	3	2
	JOA score	5	7	9	12	14
3	ASIA score	B	C	D	D	D
	Goel clinical grade	5	5	5	3	2
	JOA score	5	8	10	13	16
4	ASIA score	C	D	D	D	E
	Goel clinical grade	4	3	3	2	2
	JOA score	6	11	13	15	16
5	ASIA score	C	C	D	D	E
	Goel clinical grade	5	4	3	3	2
	JOA score	8	11	12	14	15
6	ASIA score	B	C	D	D	D
	Goel clinical grade	5	4	4	3	2
	JOA score	4	11	12	14	16
7	ASIA score	B	C	D	D	D
	Goel clinical grade	5	4	3	2	2
	JOA score	7	9	12	14	15
8	ASIA score	C	D	D	D	E
	Goel clinical grade	4	3	3	2	2
	JOA score	9	11	12	15	16
9	ASIA score	C	C	D	D	E
	Goel clinical grade	5	4	3	2	2
	JOA score	8	11	12	14	15
10	ASIA score	B	C	C	C	D
	Goel clinical grade	5	5	4	3	2
	JOA score	5	6	9	12	14
11	ASIA score	C	D	D	D	D
	Goel clinical grade	4	3	2	2	2
	JOA score	9	12	14	14	16
12	ASIA score	C	D	D	D	E
	Goel clinical grade	5	4	3	2	2
	JOA score	9	11	13	16	16
13	ASIA score	C	C	C	D	E
	Goel clinical grade	5	4	3	2	2
	JOA score	8	11	12	14	15
14	ASIA score	B	C	C	D	E
	Goel clinical grade	5	5	5	2	2
	JOA score	5	5	10	13	16

ASIA - American spinal injury association; JOA - Japanese Orthopedic Association

included in all the patients. The period of follow-up ranged from 6 to 73 months (average 26 months). All patients started showing varying degrees of improvement. Six patients had an improvement in their ASIA score and 11 patients had an improvement in their Goel clinical grade in the immediate postoperative period. All patients improved in their bladder function. At a follow-up of 3 months, four patients were independently functioning and six patients required assistance in daily activities. At delayed follow-up of more

than 1 year, all patients were able to carry out most activities of daily living with minimal assistance. None of the patients showed any worsening of neurological function at early and delayed follow up. In all cases, delayed postoperative CT scan (more than 6 months after surgery) imaging was possible and available for review. All screws at all the treated levels remained stationary or did not dislocate, dislodge, break or fail. Solid bone fusion in all the treated surgical levels was radiologically demonstrated. No re-exploration of the

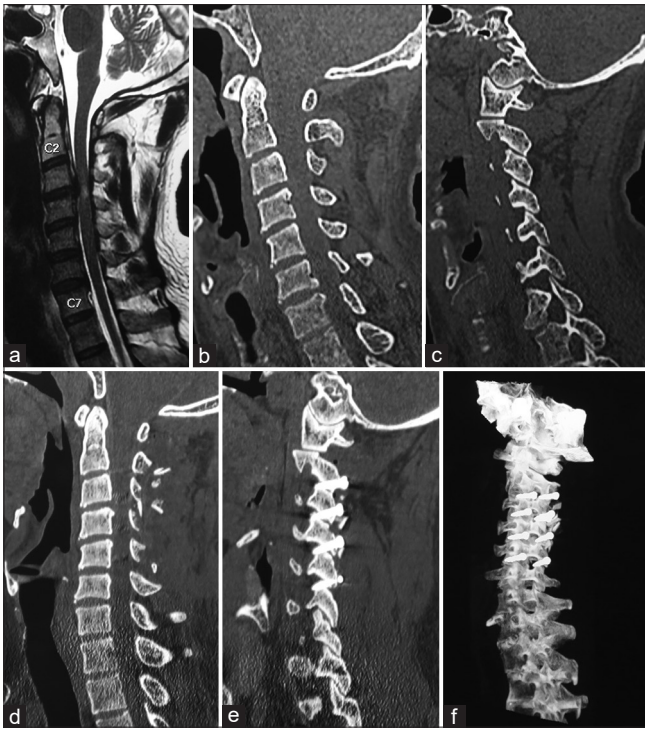


Figure 2: Images of a 46-year-old male patient [Table 1- Case 5]. (a) T2-weighted magnetic resonance imaging showing degenerative spinal changes at C3-4 spinal segment. Intrinsic cord changes are seen opposite the disc bulge at this level. (b) Sagittal image of computed tomography scan showing no evidence of bone injury or instability. (c) Sagittal image of computed tomography scan with the cut passing through the facets. No significant facetal instability is observed. (d) Postoperative computed tomography scan. There is no posterior decompression. (e) Postoperative computed tomography scan showing transarticular fixation at 4 spinal segments. (f) Computed tomography scan showing the screws

wound to address a failed fusion was done. Delayed MRI was available in nine patients. There was resolution of cord edema in five patients who had cord signal changes at the time of presentation. Some degree of cord-changes' on MRI persisted even on delayed imaging.

DISCUSSION

Spinal cord injuries are a frequent cause of severe physical disability more often encountered in relatively young population. The incidence of spinal cord injury has been identified to be 700 per million population.^[6] With the relentlessly increasing motor vehicular speed, the incidence and the severity of injury seem to be on the rise. Considering the clinical implications and financial burden to the patient and family and its impact to the society, continued clinical research on the subject is mandatory.

General understanding of the clinical effects of spinal cord injury includes both primary and secondary mechanisms. Primary injury is a result of acute neural compression resulting in cord contusion, distraction, or ischemia that initiates a

cascade of secondary events that include spinal cord edema and hemorrhage.^[9-11] Patients with spinal cord injury without any radiological evidence of spinal instability or dislocation form a discrete group. The patient subgroup discussed fits in the description of SCIWOCTET.^[1-7] Considering the aging population, spinal injury in a stenotic cervical spinal has become a more frequent clinical event.

Surgical decision-making is relatively straightforward in cases with spinal injury where there is a demonstrated bone fracture, clear evidence of spinal instability, or acute disc herniation. The debatable issue in such cases is if early or delayed surgery is better.^[5,6] Surgery involves the decompression with or without stabilization.

Literature does not clarify the treatment strategy in cases with SCIWORA or SCIWOCTET. Scanning through the literature gives an impression that majority of groups advocate a conservative nonsurgical treatment.^[1-7] The mechanism of injury to the spinal cord in the absence of modern computer-based imaging showing any type of bone, ligament, or even neural injury continues to be a debated subject. Cord changes that suggest acute injury or cord effects were identified in all patients in this series. The injury to the neural structures in SCIWOCTET cases can be a result of primary injury and initial insult to the spinal cord in the presence of pre-existing stenotic spinal canal. Sudden abnormal hyperextension as a result of injury in a "stenotic" spinal canal has been identified to be a possible factor in such cases.^[2-4] Delayed secondary events are speculated to be related to various factors that include edema, ischemia, and apoplectic cell death.^[9-12] Neurological recovery within few days or weeks from severe neurological deficits following cervical spinal injury and with no demonstrated spinal instability usually forms a case for conservative neurological observation. Few authors have advocated surgery even in an improving patient, particularly in those where recovery is partial and neurological deficits continue to be disabling.^[7,9]

None of the patients had bone injury, dislocation, or radiological evidences of ligamentous disruption and fit into the classification of SCIWOCTET. It has not been clarified in the literature if spinal instability is present in such cases. Essentially, in the absence of radiological demonstration, and as per criteria of instability laid down by White and Panjabi, the spine in these patients is considered to be "stable."^[13] As instability is not identified to be an issue, the surgical treatment, if at-all, is focused on decompression of the neural structures.

All patients analyzed had moderate-to-severe evidences of spinal degeneration and even suggestion of cord changes. Although comparative studies were not done, it was apparent that the degenerative changes in the presented group of patients were “significantly” more than a parallel age-matched cohort of general population. Spinal degeneration in the form of prominent osteophytes or ligamentum flavum bulges was identified at one (1 patient), two (7 patients) or more (6 patients) levels. Focal (7 patients) or more than one segment intrinsic cord changes on MRI were identified in all patients. In all our patients, the motor involvement was disproportionately more severe in the upper limbs than in the lower limbs and urinary and bowel functions were affected. The sensory loss was variable. From definition, the patients had “central” cord involvement.^[7]

The usefulness of high dose of steroids has been advocated and widely practiced but has continued to be a subject of debate. Schneider *et al.* concluded from their study that recovery occurs spontaneously in most cases with spinal injury presenting with central cord affection and that any kind of dural decompression can be detrimental.^[14,15] They also identified that decompressive laminectomy or laminoplasty is futile as there is no subarachnoid space block. Essentially several authors have proposed the effectiveness of conservative nonsurgical observation. Some authors have identified the usefulness of “decompression” of the neural structures. Proponents of early decompressive surgery rationalize early resection of the compressive structures and normalizing the neural environment. On the other hand, some surgeons identify that early surgery in the presence of cord edema may worsen the effects of surgery. Fehlings observed effectiveness of early (within 24 h of injury) neural decompression.^[6] In the presence of moderate-to-severe degenerative cervical spinal changes, some authors have recommended laminectomy or laminoplasty with the aim of spinal decompression. The indication for stabilization of one or more spinal segments has been debated. Some authors have identified satisfactory clinical outcome following anterior decompression with or without stabilization surgery.^[5] Such surgery has been identified to be relatively simple, provides satisfactory decompression, maintains physiological spinal curvatures, and provides an opportunity for firm stabilization.^[5]

In the year 2010, we proposed that the nodal point of initiation of spinal degeneration is muscle weakness-associated “vertical” spinal instability.^[16-18] Instability is first manifested at the facets and there is retrolisthesis of the facet of rostral vertebra over the facet of caudal vertebra.^[18] Disc space reduction, osteophyte formation, ligamentum flavum bulging and eventual reduction in spinal canal or neural

foraminal girth are secondary and more obvious radiological observations and are indicative of potential or manifest spinal instability.^[18-21] Despite the fact that instability is the cause, the lateral profile of the facets and location away from neurological structures makes radiological identification of instability difficult or impossible. The identification of unstable spinal segments is done on the basis of clinical and radiological indicators. It appears that the patients with SCIWOCTET already had subtle or subclinical spinal instability before injury that was exacerbated by trauma.

In five patients three level, in six patients four level and in three patients five level spinal fixation was done. In all cases, C2-3 articulation was included in the fixation construct. Our earlier studies have suggested that atlantoaxial joint is frequently involved in multi-level cervical spinal degeneration, particularly in those patients having “severe” neurological deficits.^[22,23] We identified that sectioning of the muscles attached to the C2 spinous process and C2-3 transarticular fixation stabilizes the C2-3 joint and prevents anteroposterior movements of the odontoid process, whilst permitting rotatory movements executed by the muscles attached to the transverse process of atlas.^[24] In the presented series, C2-3 articulation was fixated in all patients and this resulted in strategic stabilization of the atlantoaxial joint. Qi *et al.* from their study identified C3-4 and C5-6 as most vulnerable segments to be involved in SCIWOCTET.^[5]

Transarticular fixation technique described by Camille was found to stabilize the point of fulcrum of spinal movements and the screw traverse was through the strongest part of the spinal vertebra.^[8,25] The technique was quick, safe, and relatively “easy.”

Our gratifying clinical outcome following stabilization of the spinal segments relays several messages. It suggests that progressive and partial improvement in middle or older age group in the presence of clinical or radiological evidences of spinal degeneration indicates the presence of instability and its acute exaggeration following injury. Even in the absence of clear radiological indicators, stabilization of the spinal segments results in clinical recovery. The clinical recovery in the immediate postoperative period is suggestive of the fact that instability is a major causal factor in the clinical and neurological worsening. Our earlier studies have identified reduction in the size of osteophytes following stabilization of the spine.^[26] The validity of decompression by resection of bones and soft tissues needs to be re-evaluated.

The relatively small patient numbers is a drawback of the study. As no comparative studies were done, it is unclear

if the extent of neurological recovery observed after the stabilization treatment could have been obtained with conservative observation. However, the very fact that neurological recovery was observed in the immediate postoperative period whose recovery had slowed down or stopped following an initial period of incomplete improvement, suggests the positive clinical impact of surgery that involved stabilization.

Declaration of patient consent

The authors certify that they have obtained all appropriate patient consent forms. In the form, the legal guardian has given his consent for images and other clinical information to be reported in the journal. The guardian understands that names and initials will not be published and due efforts will be made to conceal identity, but anonymity cannot be guaranteed.

Financial support and sponsorship

Nil.

Conflicts of interest

There are no conflicts of interest.

REFERENCES

- Pang D, Wilberger JE Jr. Spinal cord injury without radiographic abnormalities in children. *J Neurosurg* 1982;57:114-29.
- Martinez-Perez R, Munarriz PM, Paredes I, Cotrina J, Lagares A. Cervical spinal cord injury without computed tomography evidence of trauma in adults: Magnetic resonance imaging prognostic factors. *World Neurosurg* 2017;99:192-9.
- Machino M, Ando K, Kobayashi K, Ota K, Morozumi M, Tanaka S, *et al.* MR T2 image classification in adult patients of cervical spinal cord injury without radiographic abnormality: A predictor of surgical outcome. *Clin Neurol Neurosurg* 2019;177:1-5.
- Asan Z. Spinal cord injury without radiological abnormality in adults: Clinical and radiological discordance. *World Neurosurg* 2018;114: e1147-51.
- Qi C, Xia H, Miao D, Wang X, Li Z. The influence of timing of surgery in the outcome of spinal cord injury without radiographic abnormality (SCIWORA). *J Orthop Surg Res* 2020;15:223.
- Fehlings MG, Vaccaro A, Wilson JR, Singh A, W Cadotte D, Harrop JS, *et al.* Early versus delayed decompression for traumatic cervical spinal cord injury: Results of the Surgical Timing in Acute Spinal Cord Injury Study (STASCIS). *PLoS One* 2012;7:e32037.
- Yelamarty PKK, Chhabra HS, Vaccaro A, Vishwakarma G, Kluger P, Nanda A, *et al.* Management and prognosis of acute traumatic cervical central cord syndrome: Systematic review and Spinal Cord Society-Spine Trauma Study Group position statement. *Eur Spine J* 2019;28:2390-407.
- Roy-Camille R, Saillant G, Laville C, Benazet JP. Treatment of lower cervical spinal injuries—C3 to C7. *Spine (Phila Pa 1976)* 1992;17 Suppl 10:S442-6.
- Brodkey JS, Miller CF Jr., Harmody RM. The syndrome of acute central cervical spinal cord injury revisited. *Surg Neurol* 1980;14:251-7.
- Fehlings M, Sekhon L, editors. *Cellular, Ionic and Biomolecular Mechanisms of the Injury Process*. Chicago: American Association of Neurologic Surgeons; 2000. p. 33-50.
- Tator C, Fehlings M Review of the secondary injury theory of acute spinal cord trauma with emphasis on vascular mechanisms. *J Neurosurg* 1991;75:15-26.
- Amar AP, Levy ML. Pathogenesis and pharmacological strategies for mitigating secondary damage in acute spinal cord injury. *Neurosurgery* 1999;44:1027-39.
- Panjabi MM, White AA 3rd. Basic biomechanics of the spine. *Neurosurgery* 1980;7:76-93.
- Schneider RC, Cherry G, Pantek H. The syndrome of acute central cervical spinal cord injury; with special reference to the mechanisms involved in hyperextension injuries of cervical spine. *J Neurosurg* 1954;11:546-77.
- Schneider RC, Thompson JM, Bebin J. The syndrome of acute central cervical spinal cord injury. *J Neurol Neurosurg Psychiatry* 1958;21:216-27.
- Goel A, Shah A. Facetal distraction as treatment for single-and multilevel cervical spondylotic radiculopathy and myelopathy: A preliminary report. *J Neurosurg Spine* 2011;14:689-96.
- Goel A. Facet distraction spacers for treatment of degenerative disease of the spine: Rationale and an alternative hypothesis of spinal degeneration. *J Craniovertebr Junction Spine* 2010;1:65-6.
- Goel A. Vertical facet instability: Is it the point of genesis of spinal spondylotic disease? *J Craniovertebr Junction Spine* 2015;6:47-8.
- Goel A. Is instability the nodal point of pathogenesis for both cervical spondylotic myelopathy and ossified posterior longitudinal ligament? *Neurol India* 2016;64:837-8.
- Goel A. Only fixation for cervical spondylosis: Report of early results with a preliminary experience with 6 cases. *J Craniovertebr Junction Spine* 2013;4:64-8.
- Goel A, Dandpat S, Shah A, Rai S, Vutha R. Muscle weakness-related spinal instability is the cause of cervical spinal degeneration and spinal stabilization is the treatment: An experience with 215 cases surgically treated over 7 years. *World Neurosurg* 2020;140:614-21.
- Goel A. Role of subaxial spinal and atlantoaxial instability in multisegmental cervical spondylotic myelopathy. *Acta Neurochir Suppl* 2019;125:71-8.
- Goel A, Vutha R, Shah A, Patil A, Dhar A, Prasad A. Cervical spondylosis in patients presenting with “severe” myelopathy: Analysis of treatment by multisegmental spinal fixation – A case series. *J Craniovertebr Junction Spine* 2019;10:144-51.
- Goel A, Patil A, Shah A, More S, Vutha R, Ranjan S. Alternative technique of C1-2-3 stabilization-sectioning of muscles attached to C2 spinous process and C2-3 fixation. *J Craniovertebr Junction Spine* 2020;11:193-7.
- Goel A. Camille’s transarticular technique of spinal fixation: An underused surgical technique. *J Craniovertebr Junction Spine* 2019;10:197-8.
- Goel A, Vaja T, Shah A, Rai S, Dandpat S, Vutha R, *et al.* Outcome of osteophytes after only-fixation as treatment for multilevel cervical spondylosis – A minimum of 12 months follow-up. *World Neurosurg* 2021;146:e876-87.